

Supplementary Figures

Dynamic contrast-enhanced MRI detects acute radiotherapy-induced alterations in mandibular microvasculature: prospective assessment of imaging biomarkers of normal tissue injury

Joint Head and Neck Radiotherapy-MRI Development Cooperative.

Contributing authors:

Vlad C. Sandulache¹, Brian P. Hobbs², Abdallah S.R. Mohamed³, Steven J. Frank³, Juhee Song², Yao Ding⁴, Rachel Ger^X, Laurence E. Court^X, Jayashree Kalpathy-Cramer⁵, John D. Hazle⁴, Jihong Wang⁴, Musaddiq J. Awan⁶, David I. Rosenthal³, Adam S. Garden³, G. Brandon Gunn³, Rivka R. Colen⁷, Nabil El-shafeey⁷, Mohamed Elbanan⁷, Katherine A. Hutcheson¹, Jan Lewin¹, Mark S. Chambers¹, Theresa M. Hofstede¹, Randal S. Weber¹, Stephen Y. Lai^{1,8*}, Clifton D. Fuller^{3*}

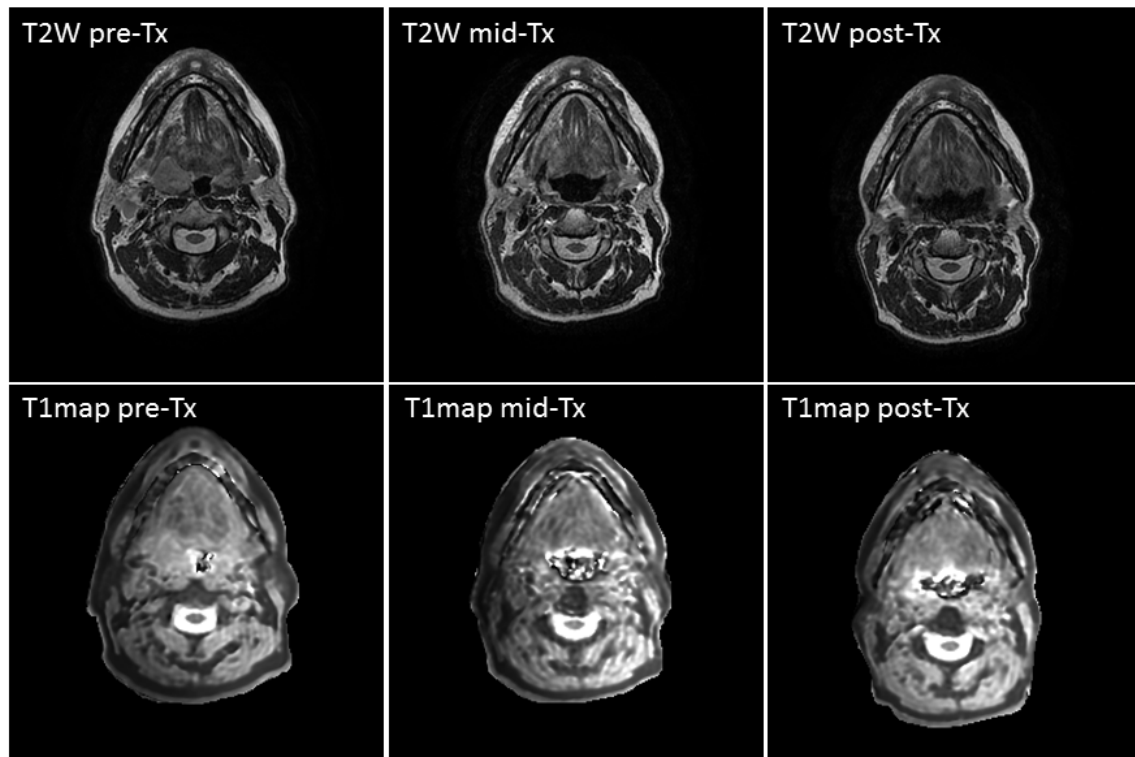
1- Department of Head and Neck Surgery, UT MD Anderson Cancer Center, Houston, TX; 2- Department of Biostatistics, UT MD Anderson Cancer Center, Houston, TX; 3- Department of Radiation Oncology, UT MD Anderson Cancer Center, Houston, TX; 4- Department of Imaging Physics, UT MD Anderson Cancer Center, Houston, TX; X- Department of Radiation Physics, UT MD Anderson Cancer Center; 5- Athinoula A. Martinos Center for Biomedical Imaging, Massachusetts General Hospital/ Division of Health Sciences & Technology, Massachusetts Institute of Technology, Charlestown, MA; 6- Department of Radiation Oncology, Case Western Reserve University, Cleveland, OH; 7- Department of Diagnostic Radiology, UT MD Anderson Cancer Center, Houston, TX; 8- Department of Molecular and Cellular Oncology, UT MD Anderson Cancer Center, Houston, TX

*Co-corresponding authors.

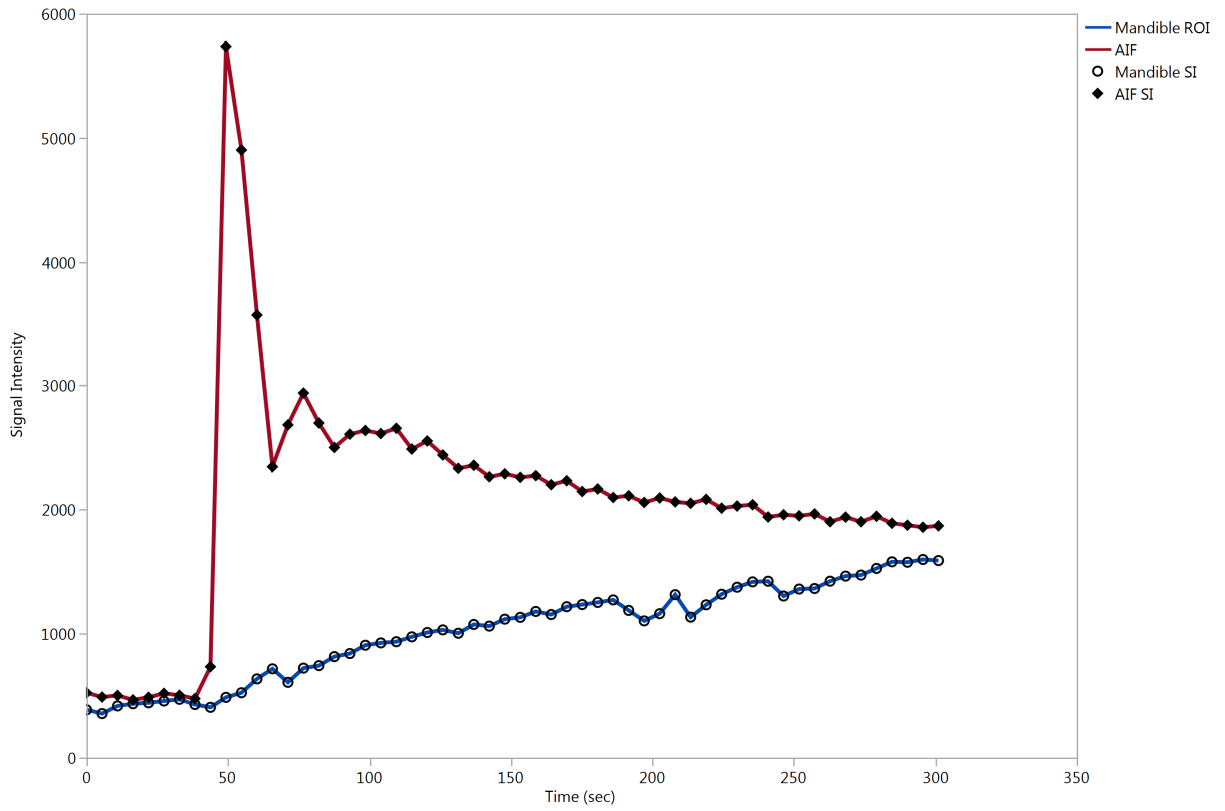
Corresponding authors:

Stephen Y. Lai MD, PhD
The University of Texas MD Anderson Cancer Center
1515 Holcombe Blvd.
Unit Number: 1445
Houston, TX 77030
Phone: (713) 792-6528
Fax: (713) 794-4662
E-mail: sylai@mdanderson.org

Clifton D. Fuller MD, PhD
The University of Texas MD Anderson Cancer Center
1515 Holcombe Blvd.
Unit Number: 0097
Houston, TX 77030
Phone: (713) 792-3471
Fax: (713) 563-2366
E-mail: CDFuller@mdanderson.org



Supplementary Figure 1. Example of pre-, mid, and post-treatment T1 map for a patient with T4, N2b, M0 tonsil squamous cell carcinoma. The upper panel shows the T2 images and the lower panel shows the T1 maps.



Supplementary Figure 2. Example of a mandibular region of interest signal intensity changes against time compared to the utilized standard arterial input function (AIF).