

Technical method

Haematoxylin counterstaining of immunofluorescence preparations

MARCO CHILOSI,* GIOVANNI PIZZOLO,† CARLO VINCENZI† **Istituto di Anatomia e Istologia Patologica* and †*Sezione di Ematologia, Università di Padova, Sede di Verona, Verona, Italy*

A major disadvantage of immunofluorescence (IF) staining applied to histological sections, referred to in the immunohistochemical literature, is its incompatibility with conventional nuclear counterstaining.¹ This is because counterstaining procedures either give autofluorescence or nearly completely abolish specific IF. Nevertheless, IF has proved to be a useful diagnostic tool when applied to tissue sections for immunological studies and is very popular in research laboratories. This is mainly because it may be used in double staining with various antibodies conjugated with different fluorochromes (fluorescein-isothiocyanate, FITC; tetraethylrhodamine isothiocyanate, TRITC).^{2,3} Alternative double immunostaining with enzyme-conjugated antibodies⁴ appears more elaborate and time-consuming although the tissue architectural picture is highly improved. On the other hand, compared to enzyme immunohistochemistry, IF gives better resolution in the demonstration of two different membrane antigens on the same cell, and can be combined to enzyme-histochemistry for detailed cell analysis.⁵

The aim of this study was to standardise a suitable nuclear counterstaining procedure which could preserve IF staining on tissue sections. We noticed in fact that immunostained cryostat sections retained their fluorescence activity for a long time and could be successfully counterstained with Gill's haematoxylin⁶ when previously mounted in glycerol-formalin (9:1). Under these conditions both IF staining and nuclear haematoxylin counterstaining could be revealed on the same cells by just changing the illumination system. However, haematoxylin staining completely removed IF when formalin was omitted in the mounting medium. On the basis of this observation we came to the conclusion that post-fixation is essential for an adequate preservation of IF staining

together with a proper nuclear counterstaining after haematoxylin. We therefore investigated several fixation procedures on immunostained preparations in order to find an optimal staining sequence.

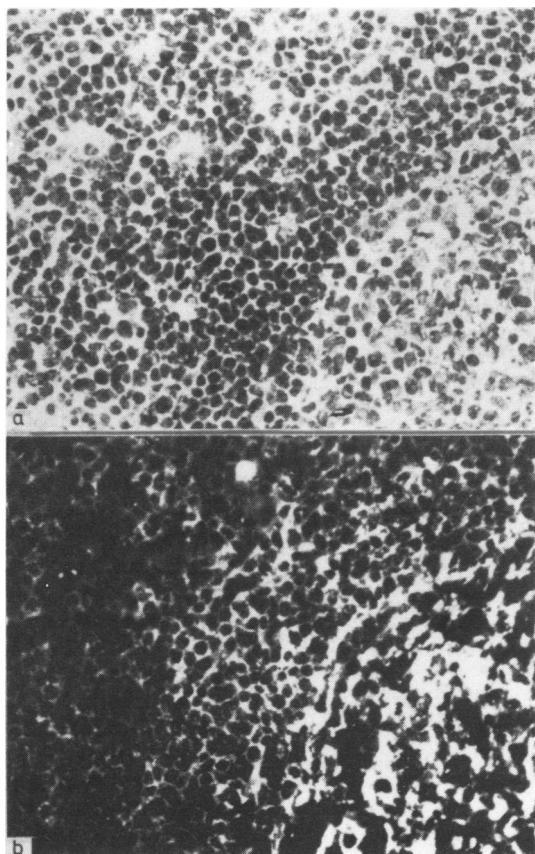
Material and methods

Cryostat sections from three reactive lymph nodes (5 µm; two sections on each side) were dried for 10 min at room temperature, fixed in chloroform-acetone mixture (1:1) for 2 min, air dried and rehydrated in phosphate-buffered saline (PBS). Immunostaining of tissue sections was performed as described previously² using goat antisera to human IgM (µ specific) labelled with TRITC and to kappa and lambda light chains labelled with FITC and TRITC respectively (from DAKO). The sections were covered with diluted antisera (1/20–1/50), incubated for 30 min and washed in PBS.

Sections were then post-fixed with various fixatives as follows: methanol, ethanol, chloroform-acetone (1:1), 10% buffered formalin, 5% buffered glutaraldehyde. Fixation times were 2, 5, 10, 30 and 60 min. In some sections, used as controls, the post-fixation step was omitted. The top section of each slide was counterstained with Gill's haematoxylin for 10–60 s and differentiated in water. The preparations were then coverslipped in PBS-glycerol and examined under a Leitz Dialux microscope equipped for epifluorescence.

Results

The complete schedule was performed on sections from all three lymph node samples. In all experiments the results were concordant and can be summarised as follows: (a) in the control sections (not post-fixed) haematoxylin staining completely abolished IF. However, in non-counterstained sections IF could be clearly demonstrated on germinal centres (as lacy deposits of IgM, kappa, and lambda), on B lymphocytes of follicular mantles (as membrane staining for IgM and kappa or lambda), and on plasma cells of medullary cords (as cytoplasmic staining restricted to a single light chain); (b) in post-fixed sections IF staining was only scarcely affected independently of the fixative used. In haematoxylin stained sections the specific fluorescence, although slightly decreased when compared to controls, could be easily demonstrated both with FITC and TRITC fluorochromes; (c) among the fixatives examined 10% buffered formalin for 30–60 min gave the best results for IF preservation and morphological detail. An example is shown in the Figure; the suggested method of haematoxylin nuclear staining for IF preparations is as follows:



Reactive lymph node. A cryostat section immunostained for IgM (TRITC) and counterstained with Gill's haematoxylin after formalin fixation. Both haematoxylin nuclear staining (a) and IgM immunofluorescence (b) are shown in the same field

- (a) Fix immunostained sections with 10% buffered formalin for 30–60 min.
- (b) Rinse in water.
- (c) Stain with Gill's haematoxylin for 10–60 s.
- (d) Differentiate in water for 10–30 min.
- (e) Mount in glycerol-formalin (9:1).

The availability of a technique for nuclear counterstaining of IF preparations represents an important step forward in immunohistology. It appears to be particularly useful in the analysis of complex tissues where phase-contrast examination reveals insufficient morphological detail.

References

- ¹ Mason DY, Biberfeld P. Technical aspects of lymphoma immunohistology. *J Histochem Cytochem* 1980;**28**:731–45.
- ² Pizzolo G, Beverley P, Sloane J, Bradstock KF, Janossy G. Differential diagnosis of lymphomas and anaplastic carcinoma with monoclonal antibodies in tissue sections. *Cancer* 1980;**46**:2640–7.
- ³ Janossy G, Thomas JA, Pizzolo G, *et al.* Immunohistological diagnosis of lymphoproliferative diseases by selected combinations of antisera and monoclonal antibodies. *Br J Cancer* 1980;**42**:224–42.
- ⁴ Mason DY, Stein H, Naiem M, Abdulaziz Z. Immunohistological analysis of human lymphoid tissue by double immunoenzymatic labelling. *J Cancer Res Clin Oncol* 1981;**101**:13–22.
- ⁵ Thomas JA, Janossy G, Chilosi M, Pritchard J, Pincott JR. Combined immunological and histochemical analysis of skin and lymph node lesions in histiocytosis X. *J Clin Pathol* 1982;**35**:327–37.
- ⁶ Gill GW, Frost JK, Miller KA. A new formula for a half oxidized hematoxylin solution that neither overstains nor requires differentiation. *Acta Cytol* 1974;**18**:300–11.

Requests for reprints to: Dr Marco Chilosi, Istituto di Anatomia e Istologia Patologica, Policlinico Borgo Roma, Verona 37100, Italy.

Letters to the Editor

Disseminated herpes simplex virus infection with misleading clinical presentation.

A young woman, born in 1950, developed chronic renal failure in 1977 for which she received a completely matched cadaver transplant later in the same year. She made an uneventful recovery and was maintained on immunosuppressive drugs (prednisolone 12 mg/bd; propranolol 10 mg/bd; azothioprine 150 mg/day; benzofluazide 5 mg/day).

Two weeks before admission she developed a cold. This appeared to resolve but four days before admission she developed a sore throat which did not respond to treatment with ampicillin. On admission she had a swinging temperature of 39.5°C. There was no evidence of jaundice, hepatomegaly, or skin lesions.

By the next day, she was very ill and her renal function began to deteriorate rapidly with the development of proteinuria and oliguria. On the third day after admission,

she developed small vesicles on the back of the left alveolar region and at the same time the liver was noted to be palpable and firm. The serum transaminase activities were grossly abnormal indicating acute hepatitis. Blood culture was negative. A throat swab failed to grow any viruses; paired sera, taken early and later during the illness indicated that there had been an infection with cytomegalovirus at some time in the past but no evidence of previous or current infection with herpes simplex