

# Patterns of chronic liver disease in Kuwait with special reference to localisation of hepatitis B surface antigen

MS AL ADNANI, SM ALI

*From the Departments of Pathology, Faculty of Medicine, University of Kuwait and Al-Sabah Hospital, Kuwait*

**SUMMARY** Two hundred and fifty six consecutive liver biopsy specimens (without secondary malignancy) collected over five years were reviewed to characterise the pattern of liver diseases encountered in the Kuwait region. A relatively high proportion of chronic active hepatitis (19%) and cirrhosis (40%) was found. Localisation of HBsAg was carried out by the histochemical orcein method and the immunohistological peroxidase-antiperoxidase (PAP) procedure. The PAP technique was superior to orcein both in quality and quantity in addition to its specificity. Three immunohistological staining patterns were observed: diffuse pancytoplasmic, partial perinuclear, and peripheral cytoplasmic. The positivity rate of HBsAg in chronic hepatitis was 29% and 27%, in all cases of cirrhosis. The results of immunohistology and serology of HBsAg were compared in 52 patients in whom both tests were carried out; almost one third of chronic active liver diseases were positive by both methods. Our data clearly show the sensitivity of immunohistology and its value in detecting HBsAg, especially in retrospective studies where serology is not always available. Additionally, the data show that hepatitis B infection is often associated with the development of chronic liver disease in Kuwait.

The special histological architecture, the unique system of blood supply, and the many functions of the liver render this organ vulnerable to numerous adverse effects of diverse noxious agents—namely, microbial, endogenous, and exogenous toxins and a wide variety of drugs and other chemicals. Histopathologically, however, several aetiological factors might lead to similar changes. The best example is chronic active hepatitis, where the main histological changes may result from several diverse aetiological entities such as hepatitis B, non-A non-B infections, autoimmune disturbances, alcohol, Wilson's disease, and certain drugs (for example, methyl dopa).<sup>1</sup>

The availability of sensitive means of serological investigation such as radioimmunoassays and enzyme linked immunoabsorbent assays has led to the elucidation of several markers in viral diseases. In addition, during the last two decades great

improvements have been achieved in immunohistological methods to localise various tissue antigens, especially by the use of the various immunoenzyme procedures<sup>2</sup> and their application on formalin fixed, paraffin embedded tissues.<sup>2-4</sup> Such procedures enable investigators to conduct retrospective studies on stored material. This is particularly important in studies of disease aetiology in developing countries where sophisticated serological analysis has not been available.

Reports from the Middle East based mainly on clinical or serological data of various liver disorders are accumulating.<sup>5-7</sup> To our knowledge, however, there is no well documented histopathological and immunohistochemical analysis of diseases of the liver in this region. We have attempted to characterise and classify histopathologically the various liver diseases in Kuwait; to study the association of liver disease with hepatitis B viral infection by localisation of at least one marker—that is, hepatitis B surface antigen (HBsAg)—histochemically and immunohistochemically; to compare the available serological results with immunohistology; and to

correlate the immunohistochemical staining patterns with the disease process.

### Material and methods

A search of the histopathological records of the departments of pathology of the Al-Sabah Hospital and Mubarak Al-Kabeer Teaching Hospital revealed 368 liver biopsy samples showing various diseases over a period of five years (January 1978 – December 1982). One hundred and two biopsy samples with diagnoses of secondary malignancies in the liver or not enough tissue available were excluded. The remaining 256 routine histological sections as well as tissue blocks were available for special staining.

### HISTOLOGICAL CHARACTERISATION

The available histological sections were routinely stained with haematoxylin and eosin, Gordon and Sweet's recticulin, Masson's trichrome, and periodic acid Schiff with and without diastase. Also, whenever indicated Van Geison's and Perl's stains were used. The histopathological diagnoses were reviewed and reclassified. Special consideration and care were taken to classify cases of chronic hepatitis and cirrhosis. The criteria used to characterise the various types of chronic hepatitis were according to those described by Scheuer<sup>8</sup> with a slight modification. For classification of cirrhosis, we followed the general criteria laid down during the Fifth Pan-American Congress of Gastroenterology<sup>9</sup> and those reported by the World Health Organisation Working Group on the morphology of cirrhosis.<sup>10</sup>

### HISTOCHEMICAL AND IMMUNOHISTOCHEMICAL LOCALISATION OF HBsAg AND EVALUATION OF THE STAINING PATTERNS

Paraffin embedded tissues were available from 256 biopsy samples. Additional consecutive sections were cut at 5  $\mu$ m thickness. Histochemical orcein staining for HBsAg was carried out according to the method of Shikata *et al*,<sup>11</sup> while immunohistochemical localisation of the same antigen was performed by the peroxidase-antiperoxidase (PAP) technique described by Sternberger *et al*<sup>12</sup> but used on paraffin embedded sections as previously described.<sup>3,4</sup>

We also attempted to describe the character of the staining of the individual cells, the distribution of positive cells in the liver lobules, and the relation of the pattern and intensity of the staining to the type of disease and its degree of activity.

### SEROLOGY OF HEPATITIS B VIRUS MARKERS

Some of the biopsied patients were studied serologically for the detection of various hepatitis B virus

Table 1 *Histological types of diseases*

Type	No cases
Resolving acute hepatitis	6
Chronic persistent hepatitis	16
Chronic active hepatitis	49
Active cirrhosis	55
Established cirrhosis	47
Hepatocellular carcinoma	32
Miscellaneous	51
Total	256

markers—namely, hepatitis B surface antigen (HBsAg), antibody to hepatitis B surface antigen (anti-HBs), antibody to hepatitis B core (anti-HBc), hepatitis Be antigen (HBe) and antibody to hepatitis Be antigen (anti-HBe) by the virology unit of the Microbiology Department, Faculty of Medicine of Kuwait University, as part of a larger series previously reported.<sup>4</sup> The results of HBsAg in sera were compared with the immunohistological results and the relation to the various types of liver diseases was also studied.

### Results

#### HISTOPATHOLOGICAL CLASSIFICATION

Table 1 shows the distribution of the various groups of liver diseases encountered. Chronic hepatitis and cirrhosis formed the majority of the cases examined. Details of the features of primary hepatocellular carcinoma have been reported elsewhere.<sup>4</sup> The miscellaneous group included heterogenous conditions—namely, the less common types of diseases in this region such as alcoholic liver disease, biliary cirrhosis, non-specific types of hepatitis where no specific aetiology could be ascertained, and a group of parasitic diseases of the liver, especially hepatic schistosomiasis, and tissues adjacent to hydatid cysts.

Table 2 *Histochemical and immunohistological distribution of hepatitis B surface antigen (HBsAg) in liver diseases*

Disease	No cases	No cases (%) HBsAg positive	
		Orcein	Immunoperoxidase
Resolving acute hepatitis	6	0	1 (17)
Chronic persistent hepatitis	16	2 (13)	4 (25)
Chronic active hepatitis	49	11 (23)	15 (31)
Active cirrhosis	55	13 (24)	18 (33)
Established cirrhosis	47	7 (15)	9 (19)
Hepatocellular carcinoma	32	6 (19)	6 (19)
Miscellaneous	51	3* (6)	3* (6)
Total	256		

\*Hepatic schistosomiasis.

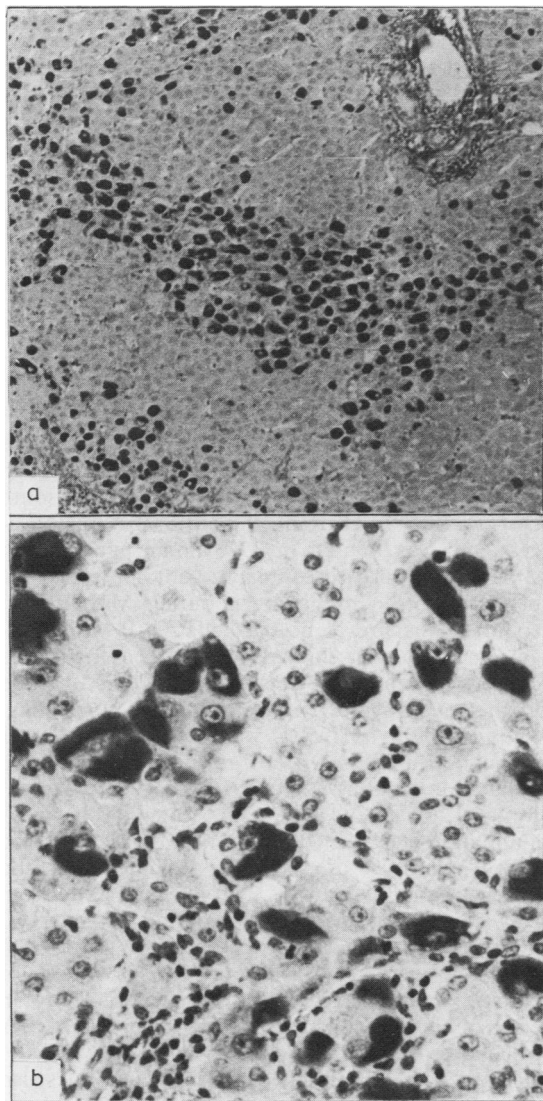


Fig. 1 *Chronic persistent hepatitis, (a) Low power view showing distribution patterns of positively stained hepatocytes for HBsAg. PAP. Original magnification  $\times 84$ . (b) Details of the diffuse pancytoplasmic staining pattern. PAP. Original magnification  $\times 420$ .*

#### HISTOCHEMICAL AND IMMUNOHISTOLOGICAL LOCALISATION OF HBsAg: STAINING PATTERNS AND RELATION TO THE DISEASE PROCESS:

The immunoperoxidase (PAP) procedure was superior to the histochemical orcein stain in its ability to demonstrate HBsAg, particularly in some sections which were equivocal or negative by the orcein method. Table 2 shows the incidence of

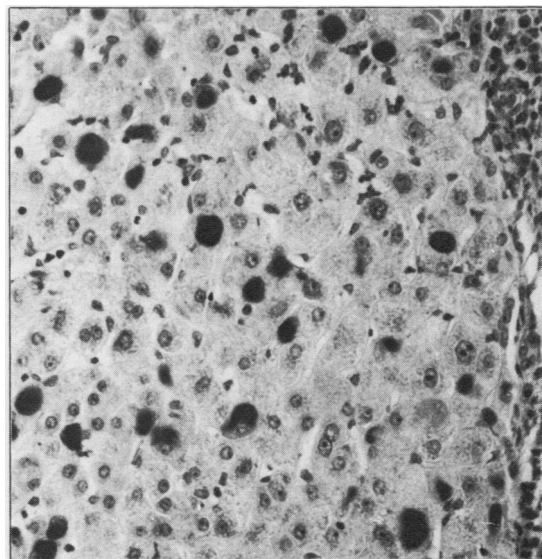


Fig. 2 *Chronic active hepatitis with randomly distributed hepatocytes bearing HBsAg showing the globular perinuclear staining pattern. PAP. Original magnification  $\times 360$ .*

HBsAg localisation by both methods in various diseases. The highest positivity rate was in active cirrhosis (33%), the positivity rate in inactive cirrhosis being 19%. In chronic hepatitis 29% were positive for HBsAg. The three positive cases in the miscellaneous group were hepatic schistosomiasis.

Three main patterns of staining of the hepatocytes bearing HBsAg were observed by the PAP method. Each pattern was more predominant in one or two types of disease, although more than one pattern was seen in few specimens. The three main staining patterns were as follows.

*Diffuse pancytoplasmic.* The entire cytoplasm was diffusely stained and the brown reaction product was usually granular. The number of positive cells varied from an individual cell randomly distributed in the lobules to a group of clustered positive hepatocytes (Fig. 1). This pattern was mainly seen in chronic persistent hepatitis and well established cirrhosis. The positive hepatocytes corresponded to the cells with "ground glass" cytoplasm seen by conventional staining methods.

*Perinuclear.* The reaction was either in the form of a crescent or a globule of positive reaction in the inner cytoplasm, usually close to the nucleus. It was usually dense and granular. The positive cells were randomly distributed in a single cell fashion (Fig. 2). This pattern was seen mainly in chronic active hepatitis with early cirrhotic changes and active cirrhosis.

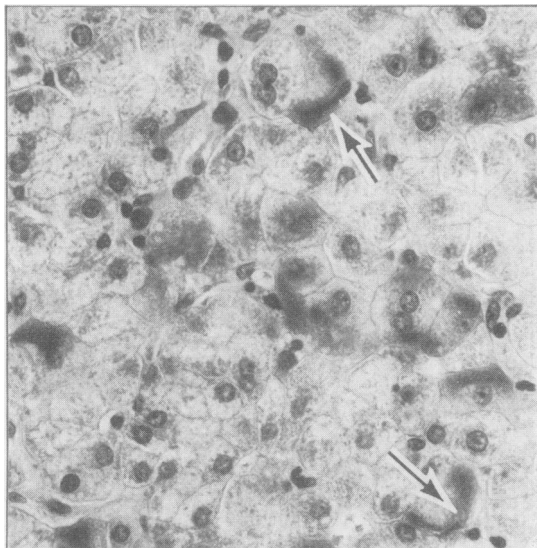


Fig. 3 Acute resolving hepatitis showing scattered hepatocytes with peripheral cytoplasmic staining for HBsAg (arrows). PAP. Original magnification  $\times 420$ .

*Peripheral cytoplasmic.* The peripheries of a few individual hepatocytes showed faint staining; usually single cells were stained with an irregular distribution in the lobules (Fig. 3). This pattern was only seen in one acute resolving hepatitis and in a few cases of the very aggressive chronic active hepatitis. It occurred in the surviving cells and was never seen in morphologically damaged ("ballooned") hepatocytes.

No nuclear staining or staining of Kupffer cells was shown. Pretreatment of sections with trypsin before the immunohistochemical staining did not increase the quality or quantity of the staining reactions.

Table 3 Immunohistology and serology of hepatitis B surface antigen (HBsAg) in liver diseases

Disease	No cases	No cases (%) HBsAg positive	
		Immunohistology (PAP)	Serology (RIA)
Chronic persistent hepatitis	6	1 (17)	1 (17)
Chronic active hepatitis and active cirrhosis	17	5 (29)	6 (35)
Established cirrhosis	14	3 (22)	5 (38)
Hepatocellular carcinoma	5	1 (20)	3 (60)
Others	10	3* (33)	5 (50)
Total	52		

\*Hepatic schistosomiasis  
RIA = radioimmunoassay; PAP = peroxidase-antiperoxidase

#### SEROLOGY VERSUS IMMUNOHISTOLOGY OF HBsAg

Table 3 shows the incidence of HBsAg positivity in 52 cases where both serology and immunohistology were carried out. Almost one third of the cases of chronic active liver disease (chronic active hepatitis and active cirrhosis) were positive by the two techniques. Although serology was not available in all the cases studied immunohistologically, no positive reaction by the PAP method was encountered in any of the seronegative patients' specimens examined by both methods.

#### Discussion

The prevalence of hepatitis B virus antigenaemia in the Middle East falls between the low prevalence areas such as Europe and the USA and the high prevalence zones such as central Africa and south east Asia.<sup>13</sup> In Kuwait hepatitis B virus antigenaemia was found to be 37% among patients with chronic liver disease compared with 4% in normal blood donors.<sup>7</sup> In the neighbouring Middle East countries the prevalence of hepatitis B virus antigenaemia, though similarly high, varies from one country to another.<sup>5,6</sup> This variability could be due to the sensitivity of the methods used for testing. Thus in Iran HBsAg was detected by agar immunodiffusion in 1.4% of rural and 2% of urban populations and in 70% of cases of acute hepatitis.<sup>5</sup> In Iraq, however, HBsAg was found by haemagglutination tests in 0.66% of volunteer blood donors,<sup>14</sup> in 50% of cases of chronic hepatitis, and 40% of cases of cirrhosis.<sup>6</sup> In a recent study from Kuwait using radioimmunoassay and detecting all hepatitis B virus markers the prevalence was as high as 4% in volunteer blood donors, 37% in cases of chronic active liver disease and cirrhosis, 60% in cases of hepatocellular carcinoma, and 50% in cases of hepatosplenic schistosomiasis.<sup>7</sup>

The reported prevalence of HBsAg in tissues also varies according to the method used and the type of material studied—such as needle biopsy, operative wedge biopsy, and necropsy specimen. In Belgium, using the immunofluorescence technique, HBsAg has been found in 55% of cases of chronic persistent hepatitis, 70% of cases of chronic aggressive hepatitis, 45% of cases of cirrhosis with little activity, and 79% of cases of cirrhosis.<sup>15</sup> Ulich *et al*<sup>16</sup> in the USA, using the PAP procedure, reported the tissue localisation of HBsAg in 77% of cases of seropositive chronic active hepatitis and in 34% of cases of chronic hepatitis in general and none in the seronegative chronic hepatitis.

In the present study we compared the less sensitive and non-specific histochemical stain—that is

orcein—with the more sensitive and specific immunoperoxidase (PAP) procedure on 256 biopsy samples of various liver diseases. The PAP method proved to be superior to orcein both in quality and quantity (Table 2). HBsAg was localised in 25% of cases of chronic persistent hepatitis, 31% of cases of chronic active hepatitis, 33% of cases of active cirrhosis, and 19% of cases of established cirrhosis as well as in hepatocellular carcinoma and in three cases of hepatic schistosomiasis. When we compared the immunohistological localisation of HBsAg with serological results in a group of patients (Table 3) almost one third of the patients with chronic active liver disease were positive by both techniques. Thus our data indicate that immunohistology is as good and is very valuable in retrospective studies especially in developing countries. All our material was fixed in 4% formalin, which is routinely used for conventional histopathological preparation. Trypsin digestion, which often un.masks antigens,<sup>17</sup> did not improve the detection rate in this study.

Three patterns of immunoperoxidase staining were seen in our study which were almost similar to those in previous reports,<sup>15,16</sup> with the exception of the membranous pattern which was first reported by Ray<sup>15</sup> using the immunofluorescence technique and later immunoperoxidase. The membranous pattern which has been seen in the very aggressive type of liver disease,<sup>16,18</sup> was not detected in our material either because the lesions were less aggressive or because the antigen occurred as part of an immunocomplex on the cell membrane rather than as free antigen. The main staining patterns correlated well with the disease activity in general. Hence, the pancytoplasmic pattern was observed mainly in the less active disease—that is, chronic persistent and well established cirrhosis—while the partial cytoplasmic perinuclear staining was seen in the conditions with intermediate activity—for example, chronic active hepatitis passing into cirrhosis. The peripheral cytoplasmic pattern occurred in the more active states of liver disease. Several previous studies have shown an inverse relation between the degree of inflammation reflecting the disease activity and the number of HBsAg positive hepatocytes regardless of the pattern of staining and density of the reaction.<sup>16,19</sup> We did not attempt to quantify the inflammatory cells since we believe that more meaningful results will be obtained by studying all parameters such as the study of all hepatitis B virus markers in serum, the histopathological changes, and the cell mediated immunity, which is believed to play a major role in the progress of the disease in hepatitis B virus infection.<sup>20,21</sup> Of course, all these parameters should be correlated with clinical progress.

In conclusion, our data are the first of their kind from the Gulf region which document the histological pattern of liver disease and demonstrate the prevalence of HBsAg in chronic liver conditions. They clearly show the value of the immunohistological localisation of HBsAg and its sensitivity in contrast to serology, especially in retrospective studies where serological results are not always available. Both serology and immunohistology may be of value in elucidating the variable progress of certain chronic liver diseases such as hepatic schistosomiasis with concomitant hepatitis B infection.<sup>22</sup>

This work was supported in part by grant MG 002, from the Research Council, University of Kuwait. We are grateful to Dr Widad Al-Nakib, Chairman of the Department of Microbiology for the serology results, his encouragement, and his valuable suggestions and to Dr A Bayoumi, Department of Community Medicine and Behavioural Sciences, for the constructive advice during the preparation of the manuscript. The excellent technical assistance of Mr Salah Badawi and secretarial help of Mr James Luke is greatly appreciated.

#### References

- 1 Sherlock S. Chronic hepatitis, progress report. *Gut* 1974;15:581-97.
- 2 Burns J. Immunohistological methods and their application in routine laboratory. In: Anthony PP, Woolf N, eds. *Recent advances in histopathology*, Vol 10. Edinburgh: Churchill Livingstone, 1978:337-50.
- 3 Burns J. Immunoperoxidase localisation of hepatitis B antigen (HB) in Formalin—paraffin processed liver tissue. *Histochemistry* 1975;44:133-5.
- 4 Al Adnani MS, Ali SM. Primary hepatocellular carcinoma in Kuwait; histopathological and immunohistochemical appraisal. *Journal of the Kuwait Medical Association* 1983;17:61-9.
- 5 Saidi S, Farrohi KH, McCollum RW, LeBouvier GL. Hepatitis B antigen in Iran: frequency and subtype. *Lancet* 1972;ii:1377-8.
- 6 Al-Balaghi SMA, Kassir Z, Thewani AL. Hepatitis B surface antigen in various liver diseases in Iraq. *J Trop Med Hyg* 1977;80:248-51.
- 7 Al-Nakib B, Al-Nakib W, Bayoumi A, Al-Liddawi H, Bashir AA. Hepatitis B virus (HBV) markers among patients with chronic liver disease in Kuwait. *Trans R Soc Trop Med Hyg* 1982;76:348-50.
- 8 Scheur PJ. Chronic hepatitis. In: MacSween RNM, Anthony PP, Scheur PJ, eds. *Pathology of the liver*. Edinburgh: Churchill Livingstone, 1979:248-57.
- 9 Fifth Pan-American Congress of Gastroenterology: Report of the board for classification and nomenclature of cirrhosis of the liver. *Gastroenterology* 1956;31:213-6.
- 10 Anthony PP, Ishak KG, Nayak NC, Poulsen EH, Sheuer PJ, Sobin LH. The morphology of cirrhosis: definition, nomenclature and classification. *Bull WHO* 1979;55:521-40.
- 11 Shikata T, Uzawa T, Yoshiwara W, Akatsuka T, Yamazaki S. Staining method of Australia antigen in paraffin section. Detection of cytoplasmic inclusion bodies. *J Exp Med* 1974;44:25-36.

- <sup>12</sup> Sternberger LA, Hardy PH, Cuculis JJ, Meyer HG. The unlabelled antibody—enzyme method of immunohistochemistry—preparation and properties of the soluble antigen—antibody complex (horseradish peroxidase—antihorseradish peroxidase) and its use in identification of spirochets. *J Histochem Cytochem* 1970;**18**:315–33.
- <sup>13</sup> Szmunes W, Harley EJ, Ikarm H, Stevens CE. Sociodemographic aspects of the epidemiology of hepatitis B. In: Vyas GN, Cohen SH, Schid R, eds. *Viral hepatitis*. Philadelphia: Franklin Institute Press, 1978:298–320.
- <sup>14</sup> Al Adnani MS Al-Kasab FM, Al-Alusi FA. Hepatitis Bs antigenaemia in sickle cell disease. *Lancet* 1982;ii:1286.
- <sup>15</sup> Ray MB. Hepatitis B surface antigen in the liver and serum of patients with hepatitis. In: Ray MB, ed. *Hepatitis B virus antigen in tissue*. Lancaster: MTP Press, 1979:49–68.
- <sup>16</sup> Ulich TR, Thorne CA, Cheng L, Lewin KJ, Gitnick GL. Chronic active hepatitis of hepatitis B and non-A, non-B etiology. *Am J Surg Pathol* 1982;**6**:33–9.
- <sup>17</sup> Curran RC, Gregory J. The unmasking of antigens in paraffin sections of tissue by trypsin. *Experientia* 1977;**33**:1400–1.
- <sup>18</sup> Huang S, Neurath AR. Immunohistologic demonstration of hepatitis B viral antigens in liver with reference to its significance in liver injury. *Lab Invest* 1979;**40**:1–17.
- <sup>19</sup> Deodar K, Tapp E, Scheuer P. Orcein staining of hepatitis B antigen in paraffin section of liver biopsies. *J Clin Pathol* 1975;**28**:66–70.
- <sup>20</sup> Dudley FJ, Giustino V, Sherlock S. Cell-mediated immunity in patients positive for hepatitis—associated antigen. *Br Med J* 1972;iv:754–6.
- <sup>21</sup> Nowoslawski A, Krawczynski K, Nazarewicz T, Slusarczyk J. Immunological aspects of hepatitis type B. *Am J Med Sci* 1975;**270**:229–39.
- <sup>22</sup> Bassily S, Farid Z, Higashi GI, Kamel IA, El-Masry NA, Watten RH. Chronic hepatitis B antigenaemia in patients with hepatosplenic schistosomiasis. *J Trop Med Hyg* 1979;**82**:248–51.

Requests for reprints to: Dr MS Al Adnani, Associate Professor of Pathology, Faculty of Medicine, PO Box 24923, Safat, Kuwait.