

Severe xanthomatosis associated with familial apolipoprotein E deficiency

Giso Feussner

Abstract

Aim—To present the clinical, dermatological, and histological features of a patient with generalised xanthomatosis, familial apolipoprotein (apo) E deficiency, and unusual type III hyperlipoproteinaemia (HLP).

Methods—The underlying molecular defect was disclosed using molecular biological techniques. The unusual xanthomas were histologically analysed and the morphology of the abnormal lipoprotein particles examined using electron microscopy.

Results—A 10 base pair deletion in exon 4 of the proband's apo ϵ gene (base pairs 4037–4046 coding for amino acids 209–212 of the mature protein) was identified. This is predictive for a reading frameshift encoding a premature stop (TGA) in codon 229. The mutation is responsible for delayed catabolism of atherogenic lipoprotein remnants, lipid storage in monocyte/macrophages, and phenotypic expression of xanthomatosis early in life.

Conclusions—Familial apo E deficiency is a rare genetic disease which offers the unique opportunity to study the impact of apo E on lipoprotein metabolism and development of atherosclerosis in humans.

(J Clin Pathol 1996;49:985–989)

Keywords: apolipoprotein E, familial apolipoprotein E deficiency, type III hyperlipoproteinaemia.

Type III hyperlipoproteinaemia (HLP) is a disturbance of the metabolism of triglyceride and cholesterol rich remnants of chylomicrons, very low density lipoproteins (VLDL), and intermediate density lipoproteins (IDL), collectively referred to as β -VLDL. Affected subjects develop accelerated atherosclerosis involving both coronary and peripheral arteries.^{1–3} Typical (and nearly pathognomonic) findings are palmar xanthomas (orange-yellowish discolourations of the palmar creases) which have been reported to occur in these patients at a rate of 39%.³ However, the proportion of type III HLP cases with xanthomas might be overestimated as this is a clinical criterion of diagnosis. The most common underlying genetic defect for the lipoprotein abnormalities in type III HLP is the synthesis of an abnormal isoform of apolipoprotein (apo) E, apo E2, which does not bind normally to lipoprotein receptors.⁶ About 1% of the population are homozygous for apo E2, but

only about 2% of these genetically predisposed individuals develop type III HLP at some stage of their lives. Hence the prevalence of this lipoprotein disorder is estimated to be around 1 in 5000 in the general population. Therefore, apo E2 homozygosity is a necessary but not sufficient condition for the development of the disorder. This suggests that type III HLP is a multifactorial disease—that is, additional factors, either genetic or environmental, are required for its phenotypic expression.⁷ A severe form of type III HLP is caused by complete or relative lack of functionally active apo E (familial apo E deficiency). This, however, is a rare genetic condition, and so far only four independent cases have been reported.^{8–12} In only two of the analysed patients have the underlying molecular defects been disclosed.^{12,13} Recently, we identified a further subject with familial apo E deficiency and xanthomatosis.¹⁴ The molecular defect was a 10 base pair deletion in exon 4 of the proband's apo ϵ gene. We now describe in detail the clinical, dermatological, and histological features of this person. Characterisation of such cases is mandatory, as apo E deficiency offers the unique opportunity to study and assess the impact of apo E on lipoprotein metabolism and development of atherosclerosis in human subjects.

Methods

Venous blood samples were obtained in the morning after a fast of at least 12 hours. Serum was extracted for analysis of total cholesterol, triglycerides, and high density lipoprotein (HDL) cholesterol, which were measured using enzymatic kits from Boehringer Mannheim, Mannheim, Germany.

Genomic DNA was isolated from nucleated blood cells contained in 10 ml of EDTA blood according to the method of Miller *et al.*¹⁵

The 3' part of exon 4 of the apo ϵ gene¹⁶ from the patient and control subjects was amplified using the polymerase chain reaction (PCR) in an automated DNA thermocycler exactly as described elsewhere.¹⁴ Amplified DNA products were analysed for size on a 2% agarose gel. PCR products were subcloned via "TA cloning into pCR II-vector" (Invitrogen, Heidelberg, Germany). Several clones were used for DNA sequence analysis, which was carried out using T7 DNA polymerase (Pharmacia, Freiburg, Germany).

Apo E phenotypes were determined using one dimensional isoelectric focusing (IEF) of plasma, as described before.¹⁷

Department of
Internal Medicine I,
Endocrinology and
Metabolism,
University of
Heidelberg,
Bergheimer Strasse 58,
69115 Heidelberg,
Germany
G Feussner

Correspondence to:
Dr G Feussner.

Accepted for publication
11 September 1996

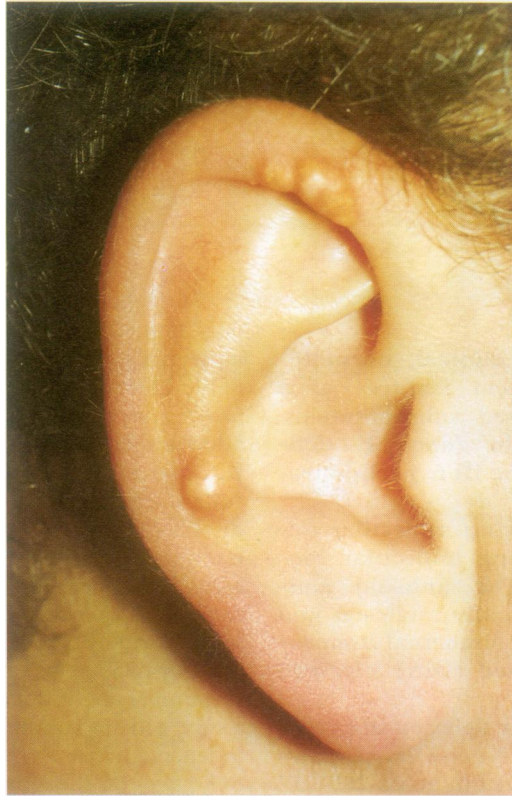

Figure 1 Xanthomas on the ears in the patient with apo E deficiency.

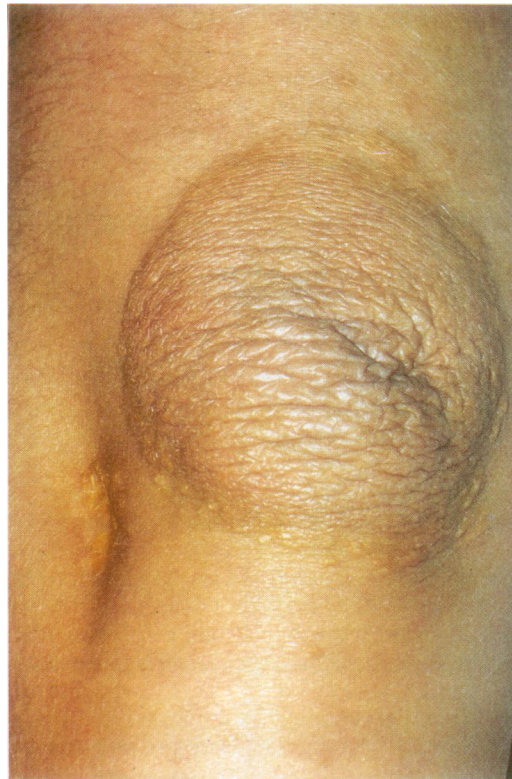

Figure 2 Tubero-eruptive xanthomas on the elbows of the patient with apo E deficiency.

Lipoproteins were separated by sequential ultracentrifugation into VLDL ($d < 1.006$ g/ml), IDL ($d, 1.006-1.019$ g/ml), LDL ($d, 1.019-1.063$ g/ml), and HDL ($d, 1.063-1.21$ g/ml), as described before.¹⁸

Negative staining for electron microscopy was performed as described.¹⁹ In short, a drop of each lipoprotein specimen (20 μ l) was care-

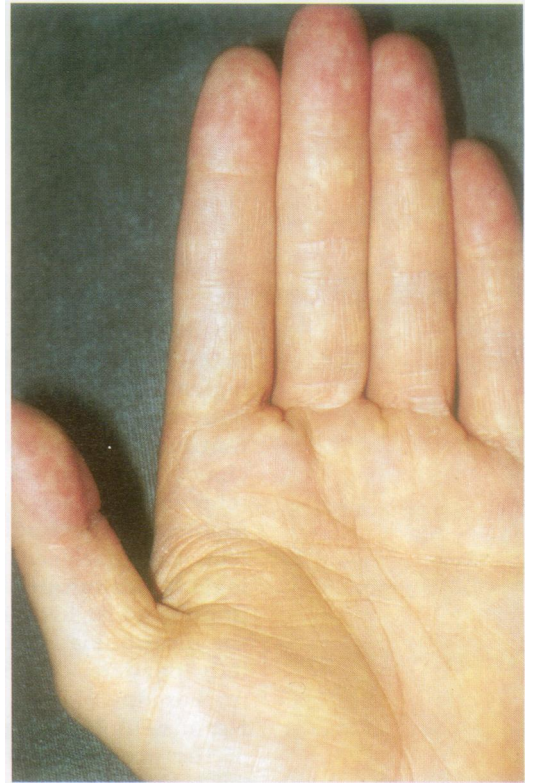

Figure 3 Orange-yellowish discolorations of the palmar creases (xanthoma striata palmaris) in apo E deficiency.

fully pipetted on a copper grid covered with a thin film of polyvinyl formaldehyde. After a short drying period (60 seconds) phosphotungstic acid (4% in 0.4% saccharose solution, pH 7.0) was used for negative staining of the lipoprotein particles for 15 minutes. The grids were dried and examined with an electron microscope (Zeiss TEM 109 T, Oberhochen, Germany).

Results

While screening hyperlipidaemic subjects for apo E phenotypes, a patient with apo E deficiency was identified. The proband (BG) was a slightly obese (weight 78 kg, height 171 cm, body mass index 26.3 kg/m^2) 30 year old German man of Hungarian ancestry. He had had a history of xanthomas and hyperlipidaemia since about five years of age. Physical examination (at age 30) revealed unusual xanthomas on the ears (fig 1), numerous tubero-eruptive xanthomas on his knees and elbows (fig 2), and orange-yellowish discolorations in the creases of the palms (palmar xanthomas) (fig 3), soles, armpits, and in the joints of the hands. The proband did not show any clinical and laboratory evidence of cardiovascular, renal, hepatic or endocrine disorders, except hyperlipidaemia. Lipid values at the time of the initial examination (at age 30) were total cholesterol 11.4 mmol/l; triglycerides 3.7 mmol/l; VLDL cholesterol 7.2, LDL cholesterol 3.2, and HDL cholesterol 1.1 mmol/l, respectively. At the time of writing the patient currently follows a low fat, low cholesterol diet and is being treated with micronised fenofibrate (200 mg/day). Recent serum cholesterol and triglyceride values were 6.5 and 1.2 mmol/l (12 months after start of

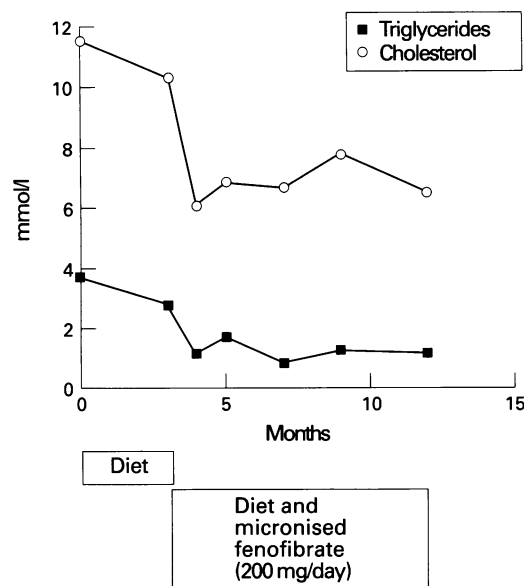


Figure 4 Time course of serum lipids (cholesterol and triglycerides) during lipid lowering treatment in the patient with apo E deficiency.

treatment) (fig 4). VLDL cholesterol was 2.1, LDL cholesterol 3.1, and HDL cholesterol 1.4 mmol/l, respectively. The skin changes regressed slightly with treatment but are still distinctly prevalent. At the patient's request his ear xanthomas were removed surgically. Histological examination revealed numerous benign, histiocytic, lipid laden foam cells (fig 5).

Particle size distribution of plasma lipoproteins obtained in the fasting state from the proband, a subject with "classic" type III HLP, with the homozygous apo E2/2 phenotype, and a healthy control with the heterozygous apo E3/2 phenotype, were analysed electron microscopically (fig 6). In the proband electron microscopy showed VLDL, IDL, and LDL particles all of which were heterogeneous in size, and smaller HDL particles than those seen in the controls.

Discussion

Xanthomas have been reported to occur in type III HLP at certain exposed locations of the body, such as tubero-eruptive xanthomas on

the elbows or knees and typical orange-yellowish discolourations of the palmar creases (xanthoma striata palmaris).¹⁻³ However, the process of xanthoma formation in the proband began early in life at different unrelated locations and had been clinically manifest since about five years of age. Xanthomatosis in children or adolescents is rather rare in "classic" type III HLP where xanthomas do not usually develop before the fourth or fifth decade of life.¹⁻⁴ Apo E deficiency inducing type III HLP is a genetic condition that has been described in only four unrelated kindreds in different parts of the world.⁸⁻¹² The patient reported here synthesised a truncated and functionally defective form of apo E due to a 10 base pair deletion in the fourth exon of his apo ϵ gene.¹⁴ This molecular defect leads to severe generalised atypical xanthomatosis. Only in two other patients with familial apo E deficiency have the underlying molecular defects been described.^{12, 13} In one case a point mutation in the 3' splice junction of the third intron of the apo ϵ gene was found.¹³ As a consequence, apo E mRNA species of this subject contained chain termination codons within the intronic sequence coding for short apo E peptides that were not detectable by gel electrophoretic techniques.¹³ In the other case a single nucleotide substitution of an A for a G was identified, which converted amino acid 210 of the mature protein, tryptophan (TGG), to a premature chain termination codon (TAG), thus leading to the synthesis of a truncated apo E peptide of 209 instead of the normal 299 amino acids.¹² The proband was homozygous for this mutation, leading to a moderate form of type III HLP. Our patient, however, expressed a severe clinical phenotype of the disease. Western blot analysis, following sodium dodecyl sulphate polyacrylamide gel electrophoresis (SDS-PAGE) and immunochemical visualisation by chemiluminescence, demonstrated the presence of minimal amounts of a truncated apo E (molecular weight \approx 30 kilodaltons) in his plasma and $d > 1.21$ g/ml ultracentrifugation fraction, but not in the different lipoprotein fractions (VLDL, IDL, LDL, and HDL, respectively).¹⁴ This indicates the presence of a functionally inactive apo E fragment with reduced affinity for lipoproteins. However, it does not preclude the proband's truncated apo E peptide preserving some of its physiological functions.

The occurrence of atypical xanthomas in apo E deficient mice has been described recently.²⁰ With a hypercholesterolaemic diet apo E "knockout" mice rapidly developed massive xanthomatous lesions in various tissues. It was suggested, therefore, that the lack of apo E, and not the hypercholesterolaemia itself, was the reason for the atypical xanthomatosis in these animals. Thus apo E obviously has an important role in tissue distribution of cholesterol deposition²⁰ and cutaneous foam cell formation.²¹ The underlying pathophysiological mechanism(s) might be similar in our proband. Hence these observations in human apo E deficiency and in apo E deficient mice²² document the essential role of apo E in

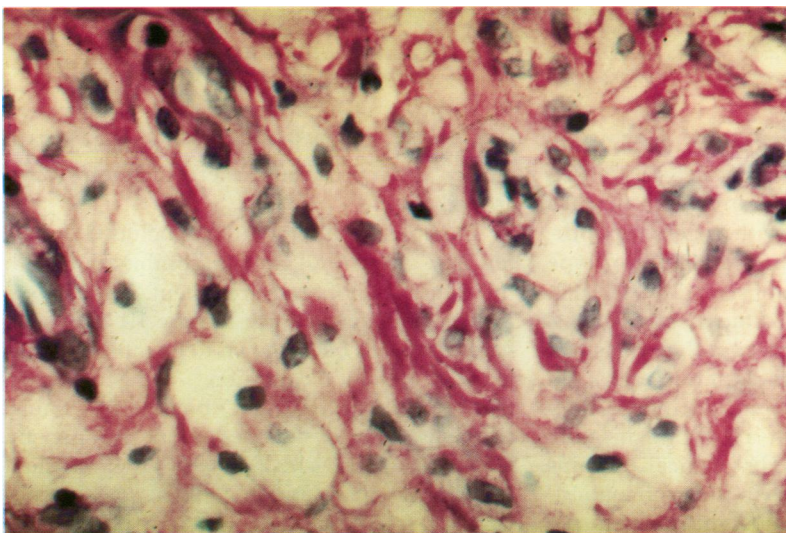


Figure 5 Histological examination of the ear xanthomas in the patient with apo E deficiency. Note extensive accumulation of lipid laden histiocytes (mainly foam cells).

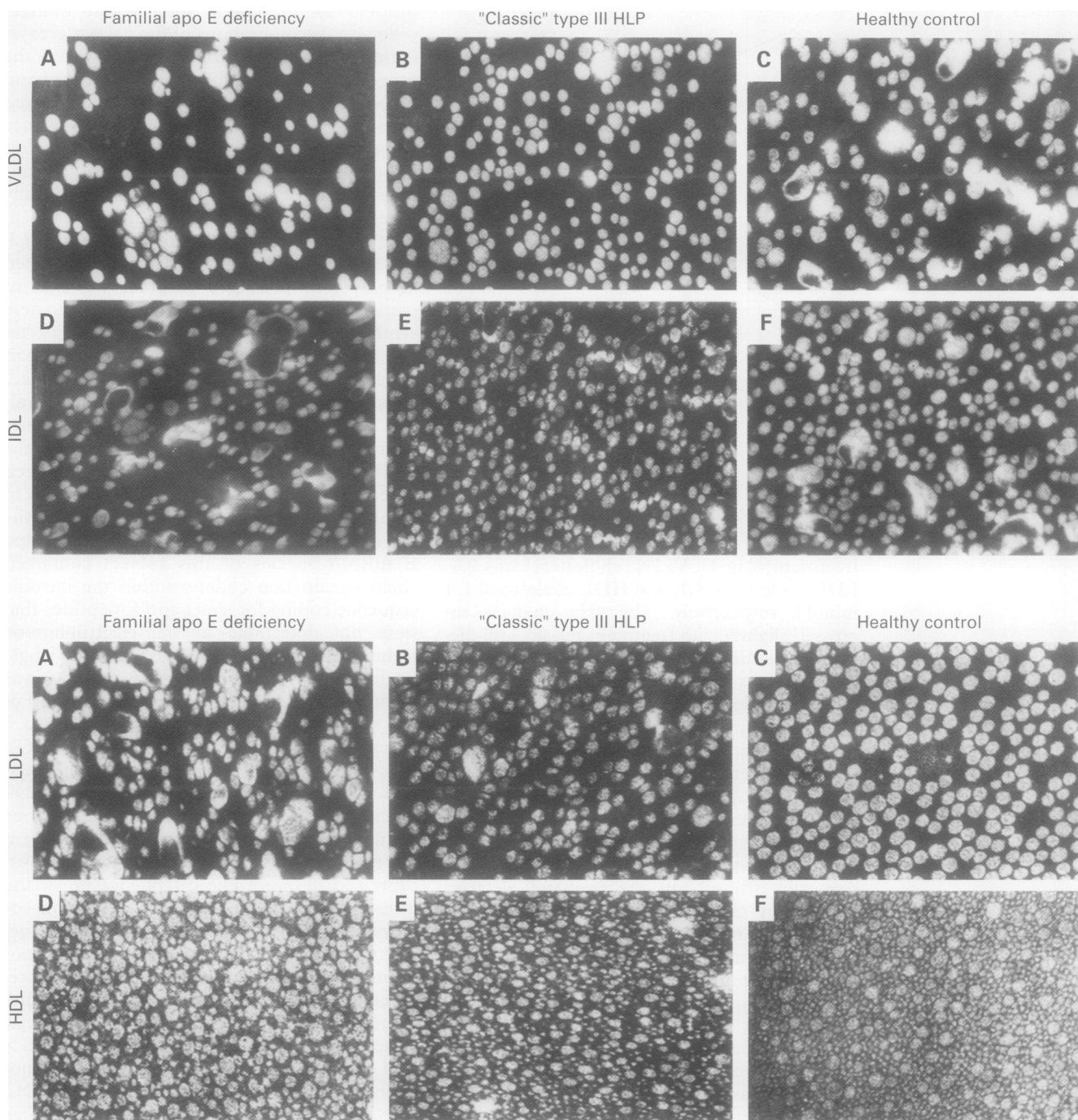


Figure 6 Analysis of VLDL ($d < 1.006$ g/ml) and IDL ($d, 1.006\text{--}1.019$ g/ml) fractions (top) and LDL ($d, 1.019\text{--}1.063$ g/ml) and HDL ($d, 1.063\text{--}1.21$ g/ml) fractions (bottom) of the proband with apo E deficiency (A and D), a patient with "classic" type III HLP with the homozygous apo E2/2 phenotype (B and E), and a normal control with the heterozygous apo E3/2 phenotype (C and F) by electron microscopy, indicating the presence of heterogeneous VLDL, IDL, and LDL, and small HDL in the proband.

chylomicron and VLDL remnant metabolism. In vivo the slow catabolism of triglyceride rich lipoprotein particles results in the occurrence of an abnormal and highly atherogenic lipoprotein fraction (β -VLDL) in the plasma of type III HLP subjects. We also observed β -VLDL in our proband (not shown). One metabolic consequence of β -VLDL accumulation is an increased storage of cholesterol esters in macrophages.^{23–25} These lipid laden cells then become foam cells which are found in early atherosclerotic lesions.²⁶ Histological examination of the ear xanthomas in the proband also showed massive foam cell accumulation (fig 5). This, however, has also been described in homozygous apo E deficient mice²¹ but has not

been shown before in humans with apo E deficiency, and is proof of accelerated atherosclerosis early in life.

Therapeutic interventions included a low fat, low cholesterol diet in combination with micronised fenofibrate treatment. Fibrates are the drugs of first choice in type III HLP and fenofibrate has been shown to be most effective in this genetic condition.²⁷ This regimen distinctly improved (fig 4) but did not totally normalise the dyslipidaemia in the patient. However, this is the first report of efficient fenofibrate treatment in familial apo E deficiency.

In conclusion, apo E deficiency results in severe type III HLP and generalised atypical

xanthomatosis. The underlying metabolic defect is an accumulation of atherogenic lipoprotein remnants, probably as a result of reduced affinity of these (apo E depleted) particles to lipoprotein receptors. The disturbances of lipoprotein metabolism created by the lack of a functionally active apo E seem to be even more pronounced than those caused by structural variants of apo E. Hence apo E deficiency is a rare but unique human model system that permits the study of the effects of apo E on lipoprotein metabolism and the subsequent development of atherosclerosis.

Electron microscopy was kindly done by Professor H-J Gröne, Medizinisches Zentrum für Pathologie, Marburg, Germany.

- Mahley RW, Rall SC Jr. Type III hyperlipoproteinemia (dysbetalipoproteinemia): the role of apolipoprotein E in normal and abnormal lipoprotein metabolism. In: Scriver CR, Beaudet AL, Sly WS, Valle D, eds. *The metabolic and molecular bases of inherited disease*. 7th Edn. New York: McGraw-Hill Book Co., 1995:1953-80.
- Brewer HB Jr, Zech LA, Gregg RE, Schwartz D, Schaefer EJ. Type III hyperlipoproteinemia: diagnosis, molecular defects, pathology, and treatment. *Ann Intern Med* 1983;**98**: 623-40.
- Feussner G, Wagner A, Kohl B, Ziegler R. Clinical features of type III hyperlipoproteinemia: analysis of 64 patients. *Clin Invest* 1994;**71**:362-6.
- Feussner G, Wagner A, Ziegler R. Relation of cardiovascular risk factors to atherosclerosis in type III hyperlipoproteinemia. *Hum Genet* 1993;**92**:122-6.
- Davignon J, Gregg RE, Sing CF. Apolipoprotein E polymorphism and atherosclerosis. *Arteriosclerosis* 1988;**8**: 1-21.
- Schneider WJ, Kovanen PT, Brown MS, Goldstein JL, Utermann G, Weber W, et al. Familial dysbetalipoproteinemia: abnormal binding of mutant apolipoprotein E to low density lipoprotein receptors of human fibroblasts and membranes from liver and adrenals of rats, rabbits and cows. *J Clin Invest* 1981;**68**:1075-85.
- Utermann G. Apolipoprotein E polymorphism in health and disease. *Am Heart J* 1987;**113**:433-40.
- Ghiselli G, Schaefer EJ, Gascon P, Brewer HB Jr. Type III hyperlipoproteinemia associated with apolipoprotein E deficiency. *Science* 1981;**214**:1239-41.
- Schaefer EJ, Gregg RE, Ghiselli G, Forte TM, Ordovas JM, Zech LA, Brewer HB Jr. Familial apolipoprotein E deficiency. *J Clin Invest* 1986;**78**:1206-19.
- Mabuchi H, Itoh H, Takeda M, Kajinami K, Wakasugi T, Koizumi J, et al. A young type III hyperlipoproteinemic patient associated with apolipoprotein E deficiency. *Metabolism* 1989;**38**:115-19.
- Kurosaka D, Teramoto T, Matsushima T, Yokoyama T, Yamada A, Aikawa T, et al. Apolipoprotein E deficiency with depressed mRNA of normal size. *Atherosclerosis* 1991;**88**:15-20.
- Lohse P, Brewer III HB, Meng MS, Skarlatos SI, LaRosa JC, Brewer HB Jr. Familial apolipoprotein E deficiency and type III hyperlipoproteinemia due to a premature stop codon in the apolipoprotein E gene. *J Lipid Res* 1992;**33**:1583-90.
- Cladaras C, Hadzopoulos-Cladaras M, Felber BK, Pavlakis G, Zannis VI. The molecular basis of a familial apo E deficiency. An acceptor splice site mutation in the third intron of the deficient apo E gene. *J Biol Chem* 1987;**262**:2310-15.
- Feussner G, Dörmeyer J, Gröne H-J, Lohmer S, Wohlfeil S. A 10-bp deletion in the apolipoprotein E gene causing apolipoprotein E deficiency and severe type III hyperlipoproteinemia. *Am J Hum Genet* 1996;**58**:281-91.
- Miller SA, Dykes DD, Polesky HF. A simple salting out procedure for extracting DNA from human nucleated cells. *Nucleic Acids Res* 1988;**16**:1215.
- Paik YK, Chang DJ, Reardon CA, Davies GE, Mahley RW, Taylor JM. Nucleotide sequence and structure of the human apolipoprotein E gene. *Proc Natl Acad Sci USA* 1985;**82**:3445-9.
- Luley C, Baumstark MW, Wieland H. Rapid apolipoprotein E phenotyping by immunofixation in agarose. *J Lipid Res* 1991;**32**:880-3.
- Havel RJ, Eder HA, Bragdon JH. The distribution and chemical composition of ultracentrifugally separated lipoproteins in human serum. *J Clin Invest* 1955;**34**:1345-53.
- Robinson DG, Ehlers U, Herken R, Herrmann B, Mayer F, Schürmann F-W. *Methods of preparation for electron microscopy*. Berlin: Springer Verlag, 1987:76-80.
- van Ree JH, Gijbels MJJ, van den Broek WJAA, Hofker MH, Havekes LM. Atypical xanthomatosis in apolipoprotein E-deficient mice after cholesterol feeding. *Atherosclerosis* 1995;**112**:237-43.
- Feingold KR, Elias PM, Mao-Qiang M, Fartasch M, Zhang SH, Maeda N. Apolipoprotein E deficiency leads to cutaneous foam cell formation in mice. *J Invest Dermatol* 1995;**104**:246-50.
- Ishibashi S, Herz J, Maeda N, Goldstein JL, Brown MS. The two-receptor model of lipoprotein clearance: tests of the hypothesis in "knockout" mice lacking the low density lipoprotein receptor, apolipoprotein E, or both proteins. *Proc Natl Acad Sci USA* 1994;**91**:4431-5.
- Brown MS, Goldstein JL. Lipoprotein metabolism in the macrophage: implications for cholesterol deposition in atherosclerosis. *Ann Rev Biochem* 1983;**52**:223-61.
- Fainaru M, Mahley RW, Hamilton RL, Innerarity TL. Structural and metabolic heterogeneity of β -very low density lipoproteins from cholesterol-fed dogs and humans with type III hyperlipoproteinemia. *J Lipid Res* 1982;**23**: 702-14.
- Mahley RW. Development of accelerated atherosclerosis: concepts derived from cell biology and animal studies. *Arch Pathol Lab Med* 1983;**107**:393-9.
- Brown MS, Basu SK, Falck JR, Ho YK, Goldstein JL. The scavenger cell pathway for lipoprotein degradation: specificity of the binding site that mediates the uptake of negatively-charged LDL by macrophages. *J Supramol Struct* 1980;**13**:76-81.
- Fruchart F, Davignon J, Bard JM, Grothe AM, Richard A, Fievet C. Effect of fenofibrate treatment in type III hyperlipoproteinemia. *Am J Med* 1987;**83**(Suppl 5B):71-4.