

Cytokeratin positive T cell malignant lymphoma

W G McCluggage, M El-Agnaff, M D O'Hara

Abstract

A high grade T cell malignant lymphoma is described in which weak staining of tumour cells for leucocyte common antigen and T cell markers coexisted with strong positive cytoplasmic staining with the anticytokeratin marker CAM 5.2. This is the first report of non-CD30 positive T cell lymphoma showing cytokeratin positivity. On ultrastructural examination there was no evidence of epithelial differentiation or of accumulation of cytokeratin-type intermediate filaments. The case adds to the range of malignant lymphomas which can, on rare occasions, show cytokeratin positivity. Pathologists should be aware of this potential diagnostic pitfall if inappropriate investigations and therapeutic regimens are to be avoided.

(*J Clin Pathol* 1998;51:404-406)

Keywords: malignant lymphoma; immunohistochemistry; cytokeratin intermediate filaments

In the differential diagnosis of an undifferentiated large cell tumour, histopathologists often rely on immunohistochemistry for a definitive diagnosis. Antibodies against cytokeratin intermediate filaments and leucocyte common antigen (LCA) are among those most commonly employed and usually result in a definitive diagnosis of either carcinoma (cytokeratin positive, LCA negative) or malignant lymphoma (LCA positive, cytokeratin negative). We describe a high grade T cell malignant lymphoma in which strong cytoplasmic staining with the anticytokeratin marker CAM 5.2 and weak staining for LCA initially suggested a diagnosis of metastatic carcinoma. A diagnosis of T cell lymphoma was confirmed by positive immunohistochemical staining for T cell markers. Anticytokeratin positivity has not previously been described in non-CD30 positive T cell lymphoma. Awareness that malignant lymphoma can occasionally show positivity with anti-cytokeratin antibodies is important since, if not appreciated, an erroneous diagnosis of metastatic carcinoma may result, with instigation of inappropriate investigations and therapeutic regimens.

Case report

A 68 year old man presented with a three month history of upper abdominal pain, anorexia, and weight loss of 14 lb (6.4 kg). He also complained of night sweats and lethargy and in the previous few weeks had noticed a swelling in the left side of the neck. On examination a firm, non-tender mass was palpable in the left lower cervical region. There

was no other palpable lymphadenopathy. Abdominal examination revealed a palpable liver, 6 cm below the right costal margin. The spleen was not palpable.

A full blood picture revealed normal red cell, white cell, and platelet indices. His erythrocyte sedimentation rate was 25 mm in the first hour. Liver function tests showed a moderate rise in serum alkaline phosphatase, aspartate transaminase, γ glutaryl transferase, and lactate dehydrogenase.

Ultrasound and computerised tomography of chest and abdomen revealed focal lesions within both lobes of liver and in the spleen. There were multiple enlarged lymph nodes in the para-aortic region and around the porta hepatis. Bone marrow aspirate and trephine were unremarkable, with no evidence of lymphomatous infiltration. Excision biopsy of the left cervical lymph node was performed and this revealed a non-Hodgkin's malignant lymphoma, the histology of which is described below. This was clinical stage IIIB.

Methods

The excised lymph node was fixed in formalin and routinely processed in paraffin wax for histological examination. Sections were stained with haematoxylin and eosin (H&E), mucicarmine, and periodic acid Schiff (PAS) before and after diastase predigestion. Immunohistochemical staining was performed using a standard streptavidin biotin peroxidase method (Dako, Copenhagen, Denmark). The following monoclonal antibodies were used: CD45 (leucocyte common antigen, LCA) (Dako), CD20 (L26) (Dako), CD3 (Dako), CD45R0 (UCHL1) (Dako), CD43 (MTI) (Biotest, Munich, Germany), CD30 (Ki-1) (Dako), CD15 (Leu M1) (Dako), CAM 5.2 (Becton Dickinson, Sunnyvale, California, USA), AE1/AE3 (ICN-Flow, Aurora, Ohio, USA), epithelial membrane antigen (EMA) (Dako), vimentin (Dako), and S100 protein (Diagnostic Products, Abingdon, UK). Immunostaining was carried out using appropriate positive and negative controls.

Representative areas of paraffin wax embedded tissue were processed routinely for electron microscopy. Ultrathin sections were stained with uranyl acetate and lead citrate.

Results

PATHOLOGICAL FINDINGS

The surgical specimen consisted of multiple fragments of lymph node, the largest measuring 15 mm in maximum diameter.

Histology of haematoxylin and eosin stained sections showed the normal nodal architecture to be totally effaced. The node was diffusely infiltrated by a monomorphic population of

Department of
Pathology, Royal
Group of Hospitals
Trust, Belfast, UK
W G McCluggage
M D O'Hara

Department of
Haematology, Ulster,
North Down and Ards
Hospital Trust, UK
M El-Agnaff

Correspondence to:
Dr W G McCluggage,
Department of Pathology,
Royal Group of Hospitals
Trust, Grosvenor Road,
Belfast BT12 6BL, Northern
Ireland, UK.

Accepted for publication
5 February 1998

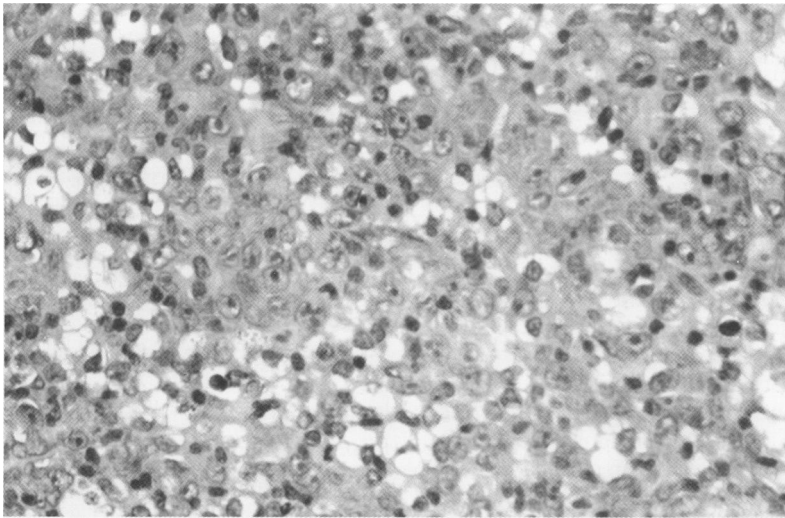


Figure 1 Node is diffusely infiltrated by tumour cells with vesicular nuclei containing small nucleoli.

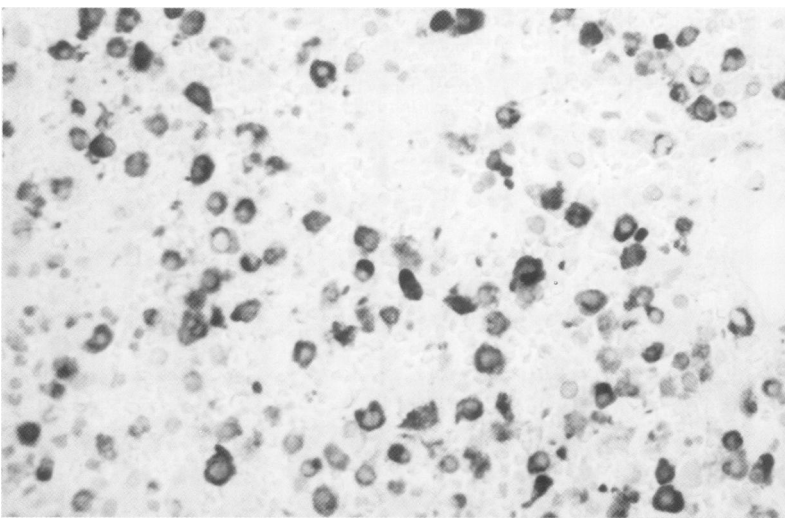


Figure 2 Positive immunohistochemical staining of tumour cells with CAM 5.2.

tumour cells with round to oval nuclei and a moderate amount of eosinophilic cytoplasm (fig 1). Tumour cell nuclei were vesicular, with one or more small nucleoli. Admixed with the tumour cells were reactive small mature lymphocytes. Histochemical stains for mucin (PAS diastase and mucicarmine) showed no intracytoplasmic accumulation.

IMMUNOHISTOCHEMISTRY

Tumour cells showed weak positive membrane staining for CD45 (LCA), CD3, CD45R0 (UCHL1), and CD43 (MT1) but were negative for CD20 (L26), CD30 (Ki-1), CD15 (Leu M1), EMA, AE1/AE3, vimentin, and S100 protein. With lymphoid markers there was strong membrane staining of the small reactive lymphocytes. There was focal strong positive granular cytoplasmic staining of tumour cells with CAM 5.2 (fig 2), but no staining of small lymphocytes.

ELECTRON MICROSCOPY

Ultrastructural examination showed tumour cells intimately admixed with small lymphocytes. Tumour cells had central nuclei with prominent nucleoli and sometimes deep intranuclear clefts. There was a moderate amount of cytoplasm with a range of cell organelles. Adja-

cent cells were not joined by adhesion specialisations, and no cytoplasmic accumulations of intermediate filaments were identified.

Discussion

The strong positive staining of tumour cells in the present case with the anticytokeratin intermediate filament antibody CAM 5.2, performed as part of the initial immunohistochemical work up, suggested a diagnosis of metastatic carcinoma and could have resulted in inappropriate investigations and therapeutic regimens being introduced. Further diagnostic confusion resulted from the fact that LCA and T cell markers stained tumour cells only weakly.

Haemopoietic neoplasms expressing cytokeratin positivity have occasionally been described.¹⁻⁷ Anticytokeratin positivity appears to be most common in plasma cell neoplasms.¹⁻⁴ This is important since reactivity for LCA is often lost in the terminal stages of B cell maturation, and plasma cells can show EMA positivity. If these pitfalls are not recognised plasma cell neoplasms, especially when tumour cells are poorly differentiated, may be misdiagnosed as carcinoma, with serious consequences for the patient.

Ki-1 (CD30) positive anaplastic large cell lymphoma (Ki-1 ALCL) morphologically may resemble metastatic carcinoma because the tumour cells are large and anaplastic, often with multinucleate forms. This resemblance may be heightened by a growth pattern which is akin to metastatic carcinoma, specifically a sinusoidal pattern of nodal involvement. Ki-1 ALCL commonly fails to express LCA or B and T cell markers and may be positive for EMA. Cytokeratin positivity has been described in these lymphomas,⁵⁻⁷ and Gustmann *et al* found positivity in five of 18 tumours,⁵ all of which were of T cell phenotype. The lymphoma in our case does not fall into the category of Ki-1 ALCL as there was no staining for CD30.

Cytokeratin positivity has recently been described in five cases of clinically aggressive B cell malignant lymphoma, all of which were extranodal.⁸ Two of the cases were LCA negative, three were negative for B cell markers, and all were positive for EMA. Although immunohistochemical evidence of B cell lineage was present in only two cases, the authors demonstrated clonal immunoglobulin heavy chain gene rearrangement by PCR in all. One lymphoma was CD30 positive, representing Ki-1 ALCL of B cell type. Anticytokeratin positivity has also been described in a single case of common acute lymphoblastic leukaemia-lymphoma which was negative for LCA.⁹

As far as we are aware, ultrastructural examination has not previously been performed in any case of cytokeratin positive malignant lymphoma. Electron microscopy in the present case did not show evidence of epithelial differentiation and no cytoplasmic accumulation of cytokeratins or other intermediate filaments was identified. We can think of no convincing biological explanation for the observed expression of cytokeratins.

In cultured malignant melanoma models, keratin reactivity has a positive correlation with metastatic potential.¹⁰ This is of interest since in the four cases where clinical follow up was available in the series of Lasota *et al*,⁸ the lymphomas showed aggressive behaviour. Similarly, in our case the lymphoma was stage IIIB at diagnosis, implying aggressive behaviour. It is possible that cytokeratin reactivity may identify a small subset of malignant lymphomas with an aggressive clinical course.

Our case, together with those previously reported, shows that cytokeratin positivity may rarely be present in a variety of malignant lymphomas. As far as we are aware, our case is the first non-CD30-positive T cell malignant lymphoma described showing cytokeratin positivity. Histopathologists should be aware of this diagnostic pitfall and, in doubtful cases, a panel of immunohistochemical stains should be performed. This panel should include a combination of different antibodies against cytokeratins since in our case an absence of staining with AE1/AE3 assisted in excluding a diagnosis of metastatic carcinoma.

- 1 Petrucci UR, Horny HP, Kaiserling E. Frequent expression of haemopoietic and non-haemopoietic antigens by neoplastic plasma cells: an immunohistochemical study using formalin-fixed, paraffin-embedded tissue. *Histopathology* 1992;20:35-40.
- 2 Wotherspoon AC, Norton AJ, Isaacson PG. Immunoreactive cytokeratins in plasmacytomas. *Histopathology* 1989; 14:141-50.
- 3 Sewell HF, Thompson WD, King DJ. IgD myeloma/immunoblastic lymphoma cells expressing cytokeratin. *Br J Cancer* 1986;53:695-6.
- 4 de Mascarel A, Merlio JP, Coindre JM, *et al*. Gastric large cell lymphoma expressing cytokeratin but no leukocyte common antigen. *Am J Clin Pathol* 1989;91:478-81.
- 5 Gustmann C, Altmannsberger M, Osborn M, *et al*. Cytokeratin expression and vimentin content in large cell anaplastic lymphomas and other non-Hodgkin's lymphomas. *Am J Pathol* 1991;138:1413-22.
- 6 Frierson HF, Bellafiore FJ, Gaffey MJ, *et al*. Cytokeratin in anaplastic large cell lymphoma. *Mod Pathol* 1994;7:317-21.
- 7 Ross CW, Hanson CA, Schnitzer B. CD30 (Ki-1)-positive, anaplastic large cell lymphoma mimicking gastrointestinal carcinoma. *Cancer* 1992;70:2517-23.
- 8 Lasota J, Hyjek E, Koo CH, *et al*. Cytokeratin-positive large-cell lymphomas of B-cell lineage. *Am J Surg Pathol* 1996;20:346-54.
- 9 Menestrina F, Lestani M, Scarpa A, *et al*. Common acute lymphoblastic leukaemia-lymphoma expressing cytokeratin: a case report. *Virchows Arch* 1994;425:83-7.
- 10 Hendrix MJC, Safor GA, Chu YW, *et al*. Co-expression of vimentin and keratins by human melanoma tumor cells: correlation with invasive and metastatic potential. *J Natl Cancer Inst* 1992;84:165-74.