

Leader

Pathology of silicone leakage from breast implants

Paul J van Diest, Werner H Beekman, Joris J Hage

Silicone breast prostheses have been widely used for several decades. Until recently, about 150 000 women received these implants annually in the United States—80% for breast augmentation and the others almost exclusively for reconstruction after cancer surgery.¹ There is little doubt about the beneficial psychological effects of breast implants, but there is increasing awareness of alleged adverse effects of implants containing silicone. These mainly concern local reactions to silicone “sweating” from the implants (gel bleed) and frank rupture, but silicone leakage has also been associated with locoregional effects such as histiocytic necrotising lymphadenitis and with systemic disorders such as autoimmune and connective tissue diseases. These side effects have led to discussion about whether silicone breast implants should be removed from the market.^{1,2} In this leader we review the specific pathological locoregional aspects of (leakage from) silicone breast implants. It is beyond the scope of this paper to discuss the pathology of silicone leakage in other parts of the body.

Silicones

Silicones are a family of polymers that comprise an alternating silicon–oxygen atom backbone. Medical silicones, or polydimethylsiloxane, can be formulated in different ways resulting in materials of varying structures and properties, such as rubbers, gels, or oils. Sometimes silicones are directly injected into the breast tissue. Mostly, silicone containing implants are used. These may be divided into four main types³: (1) silicone rubber envelopes filled with saline; (2) silicone rubber envelopes filled with silicone gel; (3) silicone rubber envelopes covered with a polyester polyurethane foam coating; and (4) dual silicone rubber envelopes, the inner envelope containing silicone gel and the outer envelope filled with saline. Many variants exist, including differences in the outer envelope such as assorted surface textures and various chemical side groups bonded to the envelope.³ Most silicone breast implants that have been implanted up to now contain silicone gel,⁴ but there is a clear trend towards implants that do not contain silicones.

Silicone oils, gels, and rubbers are potentially bioactive agents that may induce host reactions, but there are many questions as to the exact biological activity of the different sili-

cones and its long term significance. Commonly, a fibrous capsule forms around silicone breast implants. There is, however, *in vitro*⁵ and *in vivo* evidence⁶ that silicones may migrate into and through these capsules. On the other hand, rupture of the capsules may occur by accident, mammography, or closed capsulotomy (squeezing until the capsule ruptures, a once accepted method of disrupting a hard tissue capsule) which may facilitate migration of silicones into the surrounding breast. The frequency of asymptomatic rupture of silicone rubber envelopes has been estimated to be between 0.2% and 4%,³ and increases with aging of the implant.^{6,7} Once outside the envelope, silicones may disperse through soft tissue,⁸ lymph nodes,⁹⁻¹² or the vasculature¹³ to distant sites.¹⁴⁻¹⁷

Silicones are easily detected in tissue^{3,6,18} as small round to irregular translucent droplets of amorphous refractile non-polarising material.^{6,12,18} Sections thicker than 4 μm (for example 10–30 μm thick) prevent the loss of silicone droplets during tissue processing. Adding stamp pad ink to the mounting medium permits the detection of silicones through negative staining. Non-Koehler, phase contrast, and darkfield microscopy help to highlight silicones.¹⁹ Although the picture of silicones in tissue sections is rather typical, the chemical identity can be confirmed by infrared imaging spectroscopy²⁰ or Fourier transform infrared spectroscopy,²¹ electron microscopy coupled with energy dispersive *x* ray analysis, or even more complicated techniques.^{19,22} There is no consensus about the usefulness of fat stains to visualise silicones.¹⁹

Pathology

FIBROUS CAPSULE

A fibrous capsule usually forms around silicone breast implants. This is a relatively hypocellular membrane of rather uniform thickness, rich in collagen. Directly next to where the implant was situated there may be a thin discontinuous layer of activated, sometimes epithelioid, myofibroblasts,¹⁸ and a thin acellular protein film between implant and capsule has also been described.³ In this membrane and directly below it there are usually foam cells and lymphocytes, often in large numbers. Figure 1 shows a typical example of a capsule surrounding a silicone breast implant. In our own series of 71 implants (table 1), only five showed no

University Hospital
Vrije Universiteit,
Amsterdam, The
Netherlands:
Department of
Pathology
P J van Diest

Department of Plastic
and Reconstructive
Surgery
JJ Hage

Department of Plastic
Surgery, Hospital
Hilversum, Hilversum,
The Netherlands
W H Beekman

Correspondence to:
Dr Paul J van Diest,
Department of Pathology,
University Hospital Vrije
Universiteit, PO Box 7057,
1007 MB Amsterdam, The
Netherlands; email:
pj.vandiest@azvu.nl

Accepted for publication
11 March 1998

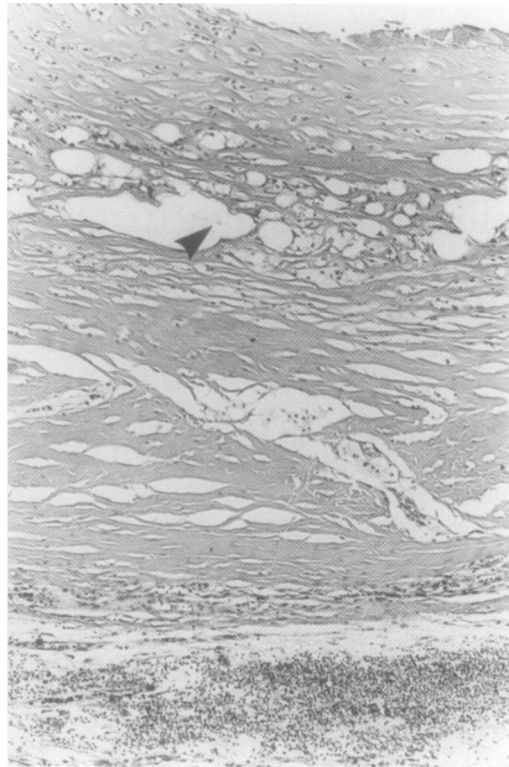


Figure 1 Typical example of a capsule surrounding a silicone breast implant. Note the typical pattern of oval to round holes, which are only partly filled with silicones, recognisable as small round to irregular translucent droplets of amorphous refractile non-polarising material (arrow). Throughout the capsule, foam cells are present. At the bottom (outside the capsule), there is a prominent lymphocytic infiltrate.

foam cells in the material examined. Thirty nine showed some foam cells, while 27 showed many. Four capsules showed no inflammation, 65 some, and two extensive lymphocytic infiltration. Plasma cells are only rarely observed in the inflammatory infiltrate.³ Calcification of the capsule is common around implants that have been in situ for many years,^{6, 23} and extensive calcification seems to be somewhat protective against silicone leakage.⁶

Silicone leakage into the capsule is characterised by a typical pattern of oval to round holes, which are only partly filled with silicones, recognisable as small round to irregular translucent droplets of amorphous refractile non-polarising material (fig 1). In our series,⁶ we have classified the degree of leakage through the capsule into four stages. In stage I, there are no signs of silicone leakage; in stage II, there are evident silicone particles in the capsule, confined to the inner half of the capsule; in stage III, silicone leakage into the outer half of the capsule is observed; and in stage IV, there is transmural leakage (fig 2). This staging system appeared to be correlated with the duration of implantation.⁶

In case of silicone leakage, giant cells of the foreign body type may be found (fig 3), although they are found in a minority of cases (35% in our series). They are most common in cases with advanced leakage (stage III and IV).

In contrast to the regular capsules bordering smooth surfaced implants, capsules around textured implants have an irregular inner surface festooned with small knob-like projec-

Table 1 Histological changes in fibrous capsules surrounding 71 mammary silicone prostheses*

Feature	Number of cases
Stage of silicone migration	
None	4
≤ 1/2	26
> 1/2	24
Foam cells	
None	5
Some	39
Many	27
Inflammation	
None	4
Some	65
Much	2
Giant cells	
None	46
Some	20
Many	5
Calcification	
None	56
Some	12
Much	3
Synovial metaplasia	
Absent	64
Present	7

*For a description of patient data, see reference 6. Since these patients had had their implants removed, the data probably reflect the worst case scenario.

tions with trapped irregular solid silicone elastomer fragments.¹⁸

The capsules around saline filled implants, on the other hand, show a predominantly fibroblastic reaction, with macrophages primarily occupying the interfacial zone between the fibrous scar and the silicone rubber surface.³ The typical partly silicone filled, round to oval vacuoles are lacking, but a few fragments of solid silicone elastomer may be found.¹⁸ The capsule around implants coated with polyurethane foam seems to show a similar pattern, although giant cells may be more prevalent and lymphocytes and plasma cells are scarcer.^{3, 24} Kasper¹⁸ found the inflammatory reaction in such capsules to be sarcoidal in nature with asteroid bodies containing epithelioid histiocytes. Polyurethane is non-polarising or partially polarising and shows an unusual geometric crystalline substructure.¹⁸

GRANULOMAS

Granulomas as a reaction to silicone (sometimes referred to as "siliconomas") will mainly be found after extracapsular rupture of an implant and after injections with silicones.^{13, 25} Such silicone granulomas may present as a tumour, sometimes some distance from the implant.¹⁸ In case of injections with liquid silicones, the histological pattern seems to be numerous cystic spaces and vacuoles partly filled with silicones surrounded by a thin layer of fibrous tissue, with only minimal foreign body giant cell reaction.¹³ In case of extracapsular rupture, there may be many giant cells of the foreign body type, often containing silicones, and foam cells as well as lymphocytes.

SYNOVIAL METAPLASIA

After surgical implantation, breast implants move about to a varying degree. The continuous presence of this gliding foreign object induces changes in the innermost layer of fibroblastic cells surrounding the implant

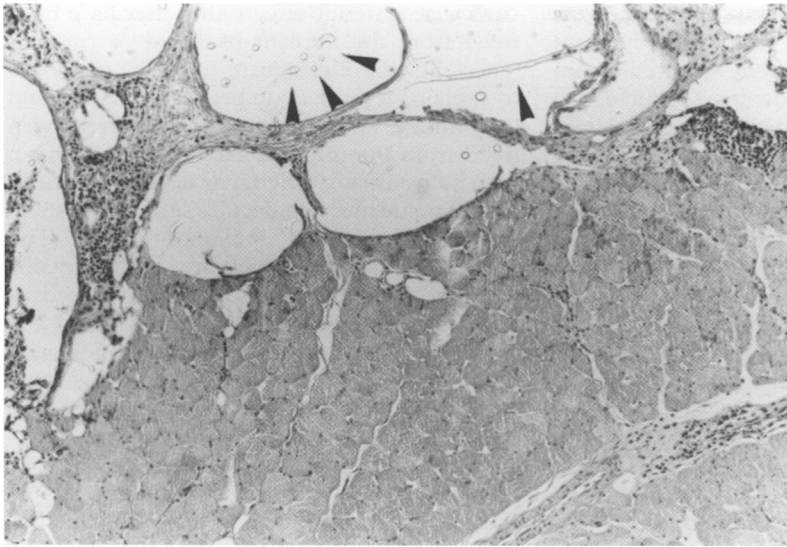


Figure 2 Extensive transmural silicone leakage (arrows) next to striated muscle.

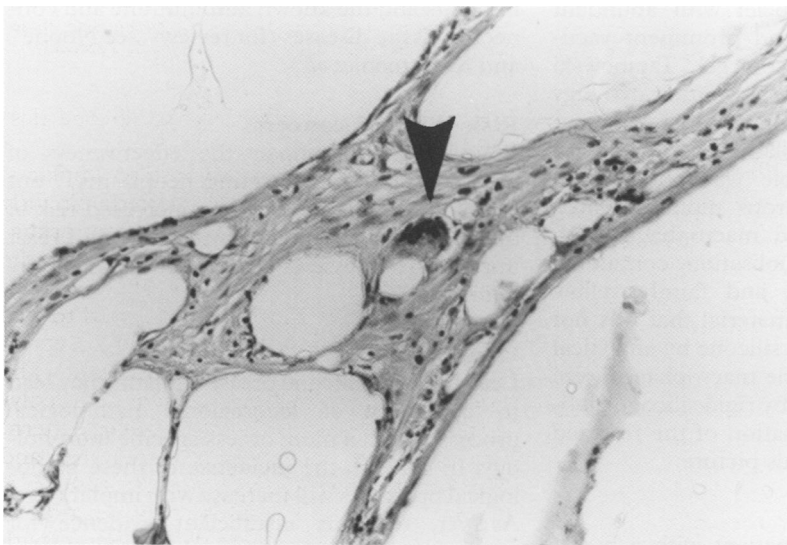


Figure 3 Silicone particles (in cystic spaces and inside a foreign body type giant cell (arrow)).

resembling normal joint synovium.²⁶ A layer one to seven cells thick of large, mostly polygonal epithelioid cells of various sizes is seen, oriented perpendicular to the surface, thus forming a palisade. These cells have round to oval nuclei with inconspicuous nucleoli and abundant eosinophilic cytoplasm. They are surrounded by a prominent network of reticulin fibres, there is abundant Alcian blue positive material, and there is no basement membrane. Immunohistochemically, the cells are only positive for vimentin. On electronmicroscopic examination, there are two main cell types. Phagocytic cells characterised by prominent mitochondriae, many phagocytic vacuoles, intermediate filaments, and filopodia predominate. The other cell type seems to be of secretory nature with prominent endocytosomal reticulum, fewer phagocytic vacuoles, occasional vesicles and Golgi complexes, intermediate filaments, and more developed nucleoli.²⁶ These changes are usually called synovial metaplasia.^{23 26 27} Synovial metaplasia has especially been reported around implants with a textured surface.²⁸ In our own series of 71 capsules around smooth breast implants, synovial

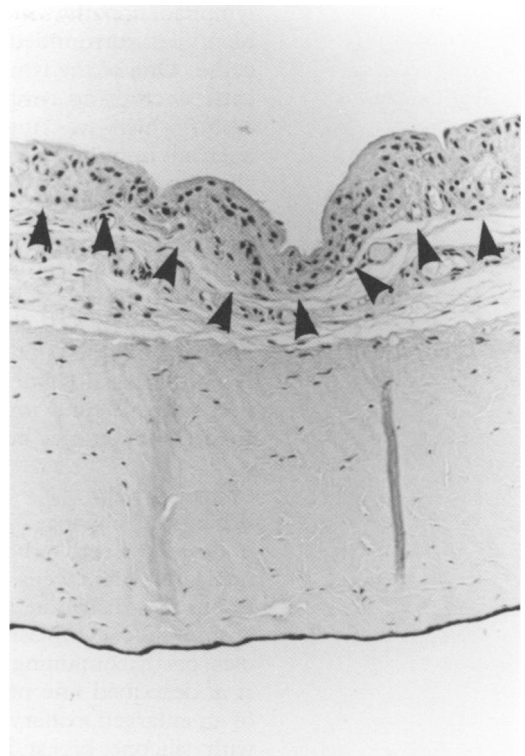


Figure 4 Synovial metaplasia on the inner side of a fibrous capsule surrounding a silicone breast implant. Note a several cells thick layer of large, mostly polygonal epithelioid cells of various sizes.

metaplasia was seen seven times (10%). Figure 4 shows an example of synovial metaplasia.

SQUAMOUS METAPLASIA AND CARCINOMA

Kitchen *et al* described a case with a thin lining of squamous epithelium around a breast implant.²⁹ A second case^{29 30} showed focally acanthotic and hyperkeratotic squamous epithelial lining around a breast implant, but much of the capsular wall surrounding the implant was lined by strands and nests of cells with pleomorphic and hyperchromatic nuclei, and individual cell dyskeratosis and atypical mitotic figures, which infiltrated the stroma around the capsule but not the surrounding breast tissue. Immunohistochemistry showed strong reactivity for cytokeratin. This lesion was therefore interpreted as a poorly differentiated squamous cell carcinoma. There were no lymph node metastases on mastectomy with axillary dissection.

It was hypothesised that there may occasionally be a proliferation of ductal cells around implant capsules that develop squamous metaplasia in response to chronic irritation from the indwelling breast implant. Squamous cell carcinoma has been known to arise in long standing chronic inflammation in other sites. Squamous metaplasia may only be focally present and it may thus be missed on routine investigation. Still, squamous cell carcinoma seems to be a very rare complication. The extent to which the silicones themselves play a role in the oncogenesis of such squamous cell carcinomas was felt to be unclear.²⁹

KIKUCHI DISEASE

Sever *et al* described a patient with a leaky silicone breast implant with homolateral axillary

lymphadenopathy in which silicones were identified surrounded by foreign body giant cells.¹⁰ One of the lymph nodes showed histiocytic necrotising lymphadenitis (Kikuchi disease), which was interpreted as a localised aberrant immune response, related to a sudden challenge of the macrophage system posed by large amounts of silicones. Three years later, the patient was still free of any evidence of systemic immune disorders. So far, no other cases have been described, but a causal relation is not unlikely since Kikuchi disease has also been associated with systemic lupus erythematosus. Nevertheless, if Kikuchi disease occurs in relation with silicone implant leakage, this case suggests that it may be a transient reaction.

LYMPH NODES

Whenever silicones have reached the lymph nodes, they seem to be phagocytosed by multinucleated giant cells. These giant cells have uniformly distributed nuclei with abundant eosinophilic cytoplasm and prominent vacuoles, partly containing silicone gel.⁹ Tatabowski *et al* described fine needle aspiration cytology of an enlarged axillary lymph node in a patient with silicone breast implants *in situ* for 14 years.¹¹ A cellular sample was obtained in which there were numerous mononucleated and giant multinucleated macrophages with striking cytoplasmic vacuolisation, containing refractile, homogeneous, and faintly yellow (Papanicolaou staining) material that was not birefringent, identified as silicone by analytical electron microscopy. Some macrophages were asymmetrically distorted by rigid silicone globules. Histological examination of the resected lymph node confirmed this picture.

LYMPHOMA

Cook *et al* described a patient with a breast implant for reconstruction after mastectomy for breast cancer, who developed a small palpable nodule next to the contracted and ruptured capsule.³¹ On microscopy, the capsule showed a foreign body giant cell reaction to silicone and polyurethane.³²⁻³³ The nodule showed a similar reaction, with an adjacent well delineated nodular proliferation of neoplastic B lymphocytes, a mixture of centrocytes and centroblasts. Bcl-2 staining was positive in the neoplastic follicles, and polymerase chain reaction showed gene rearrangement of the JH immunoglobulin heavy chain gene, indicating a clonal proliferation of B cells. This led to the diagnosis of extranodal follicular mixed (centroblastic/centrocytic) B cell non-Hodgkin lymphoma, which was found also in the bone marrow. The proximity of this lymphoma to a silicone induced granulomatous reaction suggests a relation between the development of lymphoma and rupture and leakage of the silicone breast implant. However, coincidence cannot be excluded as only one case has been described so far.

Systemic effects

Earlier reports that silicone is biologically relatively inert have recently been challenged, and the question has arisen as to whether silicones

can cause systemic effects after they have been freed from the implant by bleed or rupture. The following mechanism has been proposed to explain an interaction between silicones and the immune system.³ After silicones have been freed from the implant, they come in contact with native tissue, which may lead to denaturation of tissue macromolecules such as fibronectin, fibrinogen, and apolipoprotein B. The denatured macromolecules are sufficiently different from native tissue to be recognised as foreign, which may trigger activation of the immune system and lead to generation of antibodies against them. These antibodies may cross react with native tissue, generating an autoimmune response.

Anecdotal case reports and case series have reported autoimmune and connective tissue diseases in patients with breast implants, but large epidemiological studies have failed to support an association between silicone breast implants and the known autoimmune and connective tissue diseases (for reviews, see Noone³⁴ and Silverman *et al*⁴).

Risk of breast cancer

Breast implants impair the effectiveness of mammography in detecting neoplasms,³⁵ but there does not seem to be an increased risk of breast cancer in patients with silicone breast implants (for reviews see Noone³⁴ and Silverman *et al*⁴).

Conclusion

Leakage from silicone breast implants may lead to a variety of locoregional pathological processes with a more or less specific morphology. In general, the incidence of these pathological processes will increase with implant age. As yet, there is insufficient evidence for systemic effects of silicone leakage such as autoimmune and connective tissue diseases, and there does not seem to be an increased risk of breast cancer in patients with silicone breast implants.

- 1 Angell M. Breast implants—protection or paternalism? *N Engl J Med* 1992;326:1695–6.
- 2 Kessler DA. The basis for the FDA's decision on breast implants. *N Engl J Med* 1992;326:1713–35.
- 3 Kossovsky N, Freiman CJ. Silicone breast implant pathology. Clinical data and immunologic consequences. *Arch Pathol Lab Med* 1994;118:686–93.
- 4 Silverman BG, Brown SL, Bright RA, *et al*. Reported complications of silicone gel breast implants: an epidemiologic review. *Ann Intern Med* 1996;124:744–56.
- 5 Bergman RB, van der Ende AE. Exudation of silicone through the envelope of gel-filled breast prostheses: an *in vitro* study. *Br J Plast Surg* 1979;32:31–4.
- 6 Beekman WH, Feitz R, van Diest PJ, *et al*. Migration of silicone through the fibrous capsule around silicone mammary prosthesis following intracapsular failure. *Ann Plast Surg* 1997;38:441–5.
- 7 Camara DL de, Sheridan JM, Kammer BA. Rupture and aging of silicone breast implants. *Plast Reconstr Surg* 1993;91:828–34.
- 8 Thomsen JL, Christensen L, Nielsen M, *et al*. Histologic changes and silicone concentrations in human breast tissue surrounding silicone breast prostheses. *Plast Reconstr Surg* 1990;85:38–41.
- 9 Hausner RJ, Schoen FJ, Pierson KK. Foreign-body reaction to silicone gel in axillary lymph nodes after an augmentation mammoplasty. *Plast Reconstr Surg* 1978;62:381–4.
- 10 Sever CE, Leith CP, Appenzeller J, *et al*. Kikuchi's histiocytic necrotizing lymphadenitis associated with ruptured silicone breast implant. *Arch Pathol Lab Med* 1996;120:380–5.
- 11 Tatabowski K, Elson DCE, Johnson W. Silicone lymphadenopathy in a patient with a mammary prosthesis: fine needle aspiration cytology, histology, and analytical electron microscopy. *Acta Cytol* 1990;34:10–14.

- 12 Truong LD, Cartwright J, Goodman MD, *et al.* Silicone lymphadenopathy associated with augmentation mammoplasty. Morphologic features of nine cases. *Am J Surg Pathol* 1988;12:484-91.
- 13 Travis WD, Balogh K, Abraham JL. Silicone granulomas: report of three cases and review of the literature. *Hum Pathol* 1985;16:19-27.
- 14 Capozzi A, Du Bou R, Pennisi VR. Distant migration of silicone gel from a ruptured breast implant. *Plast Reconstr Surg* 1978;62:302-3.
- 15 Celli B, Textor S, Kovnat DM. Adult respiratory distress syndrome following mammary augmentation. *Am J Med Sci* 1978;275:81-5.
- 16 Huang TT, Blackwell SJ, Lewis SR. Migration of silicone gel after the squeeze technique to rupture a contracted breast capsule. *Plast Reconstr Surg* 1978;61:277-80.
- 17 Silver RM, Sahn EE, Allen JA, *et al.* Demonstration of silicon in sites of connective-tissue disease in patients with silicone-gel breast implants. *Arch Dermatol* 1993;129:63-8.
- 18 Kasper SC. Histologic features of breast capsules reflect surface configuration and bad composition of silicone bag implants. *Am J Clin Pathol* 1994;102:655-9.
- 19 Raso DS, Greene WB, Veseley JJ, *et al.* Light microscopic techniques for the demonstration of silicone gel. *Arch Pathol Lab Med* 1994;118:984-7.
- 20 Kidder LH, Kalasinsky VF, Luke JL, *et al.* Visualization of silicone gel in human breast tissue using new infrared imaging spectroscopy. *Nature Med* 1997;3:235-7.
- 21 Hardt NS, Yu LT, La Torre G, *et al.* Fourier transform microspectroscopy used to identify foreign materials related to breast implants. *Mod Pathol* 1994;7:669-76.
- 22 Roggli VL, McDonald JW, Shelburne JD. The detection of silicone within tissues. *Arch Pathol Lab Med* 1994;118:963-4.
- 23 Emery JA, Spanier SS, Kasnic G, *et al.* The synovial structure of breast-implant-associated bursae. *Modern Pathol* 1994;7:728-33.
- 24 Cocke WM, Leathers HK, Lynch JB. Foreign body reactions to polyurethane covers of some breast prostheses. *Plast Reconstr Surg* 1975;56:527-30.
- 25 Padadopoulos T. The silicone-injected breast and its dilemmas. *Breast* 1997;6:51-3.
- 26 Raso DS, Greene WB, Metcalf JS. Synovial metaplasia of a periprosthetic breast capsule. *Arch Pathol Lab Med* 1994;118:249-51.
- 27 Raso DS, Crymes LW, Metcalf JS. Histological assessment of fifty breast capsules from smooth and textured augmentation and reconstruction mammoplasty prostheses with emphasis on the role of synovial metaplasia. *Mod Pathol* 1994;7:310-16.
- 28 Bleiweiss IJ, Copeland M. Capsular synovial metaplasia and breast implants [letter]. *Arch Pathol Lab Med* 1995;119:115.
- 29 Kitchen SB, Paletta CE, Shehadi SI, *et al.* Epithelialization of the lining of a breast implant capsule. Possible origin of squamous cell carcinoma associated with a breast implant capsule. *Cancer* 1994;73:1449-52.
- 30 Paletta C, Paletta FX. Squamous cell carcinoma following breast augmentation. *Ann Plast Surg* 1992;29:425-32.
- 31 Cook PD, Osborne BM, Connor RL, *et al.* Follicular lymphoma adjacent to foreign body granulomatous inflammation and fibrosis surrounding silicone breast prosthesis. *Am J Surg Pathol* 1995;19:712-17.
- 32 Bleiweiss IJ, Copeland M. Breast prosthesis reaction [letter]. *Am J Surg Pathol* 1996;20:505-6.
- 33 Fitzgibbons PL. Breast prosthesis reaction [letter]. *Am J Surg Pathol* 1996;20:505.
- 34 Noone RB. A review of the possible health implications of silicone breast implants. *Cancer* 1997;79:1747-56.
- 35 Carlson GW, Curley SA, Martin JE, *et al.* The detection of breast cancer after augmentation mammoplasty. *Plast Reconstr Surg* 1993;91:837-40.