

# Effect of embolisation of meningioma on Ki-67 proliferation index

W Paulus, J Meixensberger, E Hofmann, W Roggendorf

## Abstract

The proliferation indices (PIs) were determined in 33 meningiomas using two monoclonal antibodies to the Ki-67 antigen (Ki-67 and MIB1). PIs obtained using Ki-67 on frozen material were intermediate between the lowest and highest MIB1 PIs determined in paraffin wax sections. Preoperative embolisation did not influence Ki67 PI, but four of the 15 embolised tumours showed substantially increased MIB1 PIs around embolisation necroses.

Proliferation can be reliably assessed in routinely processed meningioma tissues using MIB1; and increased perinecrotic PIs may occur in embolised meningiomas without being an indication of malignancy.

(J Clin Pathol 1993;46:876-877)

The monoclonal antibody Ki-67, which reacts selectively with the nuclei of proliferating cells, has been used to assess the proliferation of many tumours, including meningiomas.<sup>1,2</sup> Because the epitope is destroyed by routine processing, the application of Ki-67 is restricted to fresh tissues. Recently, the monoclonal antibody MIB1 was developed. This has been raised to the recombinant Ki-67 gene product and shown to work with routinely processed tissues.<sup>3,4</sup> To evaluate the usefulness of MIB1, we compared Ki-67 and MIB1 in a series of meningiomas; in addition, we examined the effect

of preoperative embolisation on the proliferation rate.

## Methods

Fresh frozen and formalin fixed, paraffin wax embedded biopsy specimens from 33 meningiomas were studied. Histological subtypes are shown in fig 1. Not included were malignant meningiomas, (tumours showing necrosis as well as at least two additional histological features of malignancy, such as increased number of mitoses, increased cellular density, dedifferentiation, brain infiltration, and nuclear pleomorphism). Fifteen tumours had been embolised two to 36 days before surgical resection to reduce blood loss and to facilitate surgical removal. Superselective embolisation was performed through meningeal branches, mainly of the external carotid artery. Polyvinyl alcohol particles of 150-250  $\mu\text{m}$  in diameter were used (Contour, Interventional Therapeutics Corporation, San Francisco, California, USA).

Immunohistochemical staining of frozen sections (5  $\mu\text{m}$ ) using the Ki-67 antibody (Dianova, Hamburg, Germany; dilution 1 in 30 for 1 hour at room temperature, including negative and positive controls) has been described before.<sup>1</sup> Immunostaining of paraffin wax sections (5  $\mu\text{m}$ ) on slides coated with 3-aminopropyltriethoxysilane (APES) using MIB1 (Dianova; diluted 1 in 10 for 24 hours at 4°C) was performed according to the method of Cattoretti *et al*<sup>4</sup> and the manufacturer's protocol. In particular, after being dewaxed sections were cooked four times for 5 minutes each in citrate buffer (pH 6.0) in a microwave oven at 600 Watts. The alkaline phosphatase-antialkaline phosphatase (APAAP) technique with neofuchsin development was used for both antibodies.

The percentage of positive nuclei—the proliferation index (PI)—was determined at a magnification of  $\times 250$  (Ki-67) or  $\times 200$  (MIB1) using an ocular grid. All nuclei from the frozen section were counted, amounting to 1300-41 000 nuclei (mean 11 425 nuclei) per case. Two areas each comprising the total ocular grid and at least 1000 nuclei were evaluated in the paraffin wax sections. One area exhibited the lowest PI and the other the highest PI (unrelated to embolisation necrosis) of the entire paraffin wax section.

## Results

Unequivocal and strong labelling was obtained using both the Ki-67 and the MIB1 antibodies. Weak and questionable positivity was seen in only a few nuclei (less than 10% of unequivocally positive nuclei, but more often with MIB1 than with Ki-67) and was scored as negative. Scattered mitoses present

Department of Pathology (Neuropathology)  
W Paulus  
W Roggendorf

Department of Neurosurgery  
J Meixensberger

Department of Neuroradiology  
E Hofmann

University of Würzburg School of Medicine, Würzburg, Germany

Correspondence to:  
Dr Werner Paulus, Institute of Pathology, University of Würzburg, Josef-Schneider-Str. 2, D-97080 Würzburg, Germany.

Accepted for publication  
22 April 1993

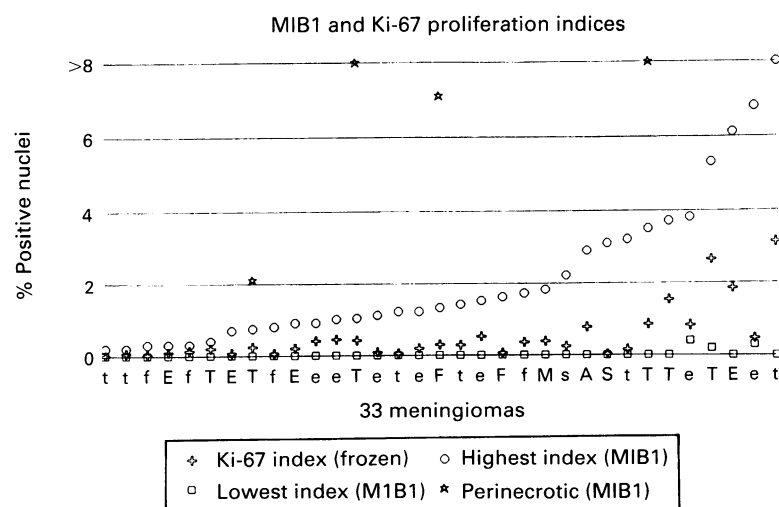


Figure 1 Ki-67 index (frozen sections), lowest and highest MIB1 index (paraffin wax sections) in 33 meningiomas. The Ki-67 index ranges between the two other indices in all tumours. Note the four tumours with relatively low Ki-67 proliferation index, but high MIB1 indices in areas around embolisation necrosis (asterisks). t/T: transitional; e/E: endotheliomatous; f/F: fibroblastic; M: microcystic; s/S: secretory; A: angiomatous. Capital letters symbolise embolised tumors, lower case letters non-embolised tumours. The three values above 8 are 18.5%, 10.2%, and 11.5% (left to right).

in a few tumours were always positive. Results using both antibodies are shown in fig 1. In all tumours, the Ki-67 PI obtained on frozen sections was intermediate between the lowest and the highest MIB1 PI on paraffin wax sections where larger areas could be examined. The lowest MIB1 PI was 0% except for three cases (0.2%, 0.3%, 0.4%). On the other hand, compared with the Ki-67 PI, the highest MIB1 PI was more than twice as high in 31 of 33 cases, and more than five times as high in 18 cases.

In 10 of 15 embolised tumours either large necroses or necrobiotic areas characterised by pyknotic nuclei, eosinophilic cytoplasm, and microcystic degeneration were observed in the paraffin wax section, but not in the frozen section. PIs were the same in embolised and non-embolised tumours (fig 1). Four of 10 cases with necroses, however, showed strongly and focally increased MIB1 PIs (2.1%, 7.1%, 10.2%, 18.5%) in some perinecrotic areas (fig 2), but not in areas unaffected by embolisation.

### Discussion

We found similar PIs in frozen and paraffin wax sections from the same meningiomas using the Ki-67 and MIB1 monoclonal antibodies, respectively. The Ki-67 PIs we obtained in the relatively small frozen sections were intermediate between lowest and highest MIB1 PIs in paraffin wax sections. Our results confirm that proliferation can be reliably assessed in routinely processed tissues using MIB1, provided that sections are adequately pretreated, in particular by microwave cooking in citrate buffer.<sup>3,4</sup> In addition, MIB1 showed pronounced intratumoral heterogeneity. Compared with previous Ki-67 data in meningiomas,<sup>1,2,5</sup> the PIs were relatively low in our series, because we did not evaluate foci of highest density of labelled cells or "representative" areas, but the entire frozen section.

Antibodies to proliferating cell nuclear antigen (PCNA) have also been applied to

paraffin wax sections of brain tumours to assess proliferation.<sup>5</sup> PCNA antibodies, however, produce a broad spectrum of staining intensities, including many equivocally positive nuclei leading to a PI dependent on the sensitivity of the immunohistochemical technique used<sup>6</sup>; MIB1 staining generally shows either negative or clearly positive nuclei. Furthermore, both downregulation of PCNA by dexamethasone<sup>7</sup> and deregulated PCNA expression with high scores unrelated to proliferative activity<sup>6</sup> have been described in meningiomas. Therefore, MIB1 seems to be more suitable than PCNA antibodies for the assessment of proliferation, at least in meningiomas.

The appearance of artificial necrobiotic or necrotic areas due to preoperative arterial embolisation has been described before.<sup>8</sup> These areas could be differentiated from tumour necroses unrelated to embolisation by the presence of several of the following four features: (1) a histological pattern composed of eosinophilic cytoplasm, small nuclei with condensed chromatin and microcystic degeneration; (2) large necroses with indistinct borders; (3) presence of embolisation material in large adjacent blood vessels; and (4) lack of additional histological criteria of malignancy.

While Ki-67 PIs did not differ between embolised and non-embolised tumours, we found substantially increased MIB1 PIs around necroses in four of 15 embolised tumours. The increased perinecrotic proliferation in meningiomas might be related to deliberation of growth factors within or around necroses.<sup>9</sup> Alternatively, tumour cells could be induced to enter the cell cycle by the abnormal metabolism around necroses. In any case necroses and increased perinecrotic PIs, which are usually correlated with meningioma malignancy and recurrence,<sup>10</sup> should be carefully interpreted after embolisation, because they may be artificially induced.

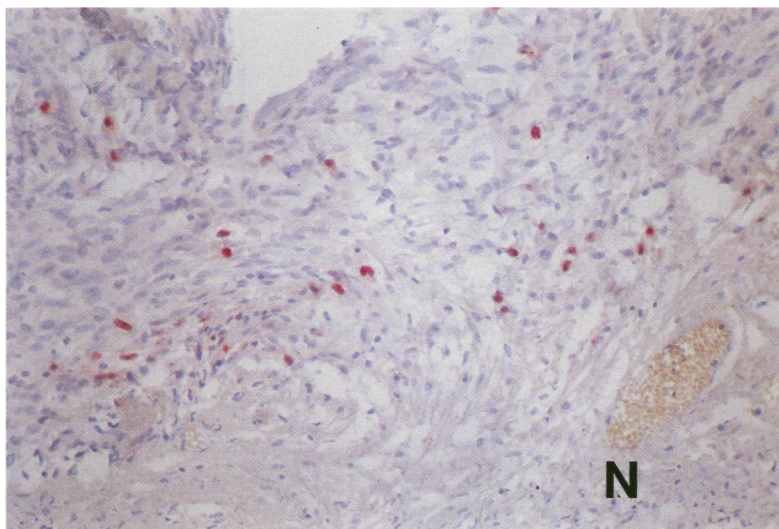


Figure 2 Increased number of positive nuclei around embolisation necrosis (MIB1 immunostaining, paraffin wax section).

- 1 Roggendorf W, Schuster T, Peiffer J. Proliferative potential of meningiomas determined with the monoclonal antibody Ki-67. *Acta Neuropathol* 1987;73:361-4.
- 2 Kleihues P, Kiessling M, Janzer RC. Morphological markers in neuro-oncology. Morphological tumor markers. *Current Topics in Pathology* 1987;77:307-38.
- 3 Gerdes J, Becker MHG, Key G, Cattoretti G. Immunohistochemical detection of tumour growth fraction (Ki-67 antigen) in formalin-fixed and routinely processed tissues. *J Pathol* 1992;168:85-6.
- 4 Cattoretti G, Becker MHG, Key G, et al. Monoclonal antibodies against recombinant parts of the Ki-67 antigen (MIB1 and MIB3) detect proliferating cells in microwave-processed formalin-fixed paraffin sections. *J Pathol* 1992;168:357-63.
- 5 Allegranza A, Giraldo S, Arrigoni GL, et al. Proliferating cell nuclear antigen expression in central nervous system neoplasms. *Virchows Arch (Pathol Anat)* 1991;419:417-23.
- 6 Khoshyomn S, Maier H, Morimura T, Kitz K, Budka H. Immunostaining for proliferating cell nuclear antigen (PCNA): its role in determination of proliferation in routinely processed human brain tumor specimens. *Acta Neuropathol* 1993;(in press).
- 7 Gottschalk J, Goebel S, Jautzke G, et al. Influence of preoperative dexamethasone therapy on proliferating cell nuclear antigen (PCNA) expression in comparison to other parameters in meningiomas. *Histol Histopathol* 1992;7:653-61.
- 8 Richter HP, Schachenmayr W. Preoperative embolization of intracranial meningiomas. *Neurosurg* 1983;13:261-8.
- 9 Paulus W, Grothe C, Sensenbrenner M, et al. Localization of basic fibroblast growth factor, a mitogen and angiogenic factor, in human brain tumors. *Acta Neuropathol* 1990;79:418-23.
- 10 Shibuya M, Hoshino T, Ito S, et al. Meningiomas: clinical implications of a high proliferative potential determined by bromodeoxyuridine labeling. *Neurosurg* 1992;30:494-8.