

Fatal infection associated with group C streptococci

A C Bateman, A D Ramsay, A P Pallett

Abstract

Serious infection caused by Lancefield group C streptococci is unusual in man. Two unrelated deaths associated with these organisms in a 55 year old woman who died after three days of diarrhoea and vomiting, and in a 65 old man who died after a week of non-specific symptoms, are presented. Post mortem examination showed septicaemia in the former and severe aortic stenosis with widespread septic emboli and probable meningitis in the latter. Lancefield group C streptococci were isolated from both cases. These organisms may be carried asymptotically and usually cause disease in animals but cases of serious human infection have recently been described, mainly in elderly patients or those with other predisposing factors.

(J Clin Pathol 1993;46:965-967)

Case reports

CASE 1

A 55 year old woman was seen at home by her general practitioner on the third day after developing symptoms of vomiting and diarrhoea. There were no special features in the history. Examination showed that she was obese, febrile (38°C), tachycardic (pulse 120/minute), and hypotensive (80/50 mm Hg). Auscultation indicated scattered crepitations at the left lung base and normal heart sounds. Her abdomen was soft. The general practitioner gave an initial dose of penicillin, but thirty minutes later the patient collapsed and died at home. Her medical history included appendectomy in 1953 and hypertension diagnosed in May 1992, controlled with Tritace (ramipril).

At post mortem examination no anaemia, jaundice, finger clubbing or splinter haemorrhages were seen. Internal examination showed haemolytic staining of the aortic intima, pale swollen kidneys, adrenal haemorrhage, and a soft spleen. These features are characteristic of septicaemia. The bowel was dilated and contained fluid. The lungs were congested and there was mild left ventricular hypertrophy consistent with a history of hypertension. The cardiac valves were normal with no vegetations.

Post mortem culture of blood, endocardium, and spleen revealed a heavy growth of a Lancefield group C β haemolytic strepto-

cocci sensitive to penicillin, erythromycin, and ampicillin.

CASE 2

A previously fit 65 year old man developed general malaise, joint pain and stiffness, headaches, and rigors. One week after the onset of symptoms he could not be roused from bed. On admission to hospital he was hypotensive (80 mm Hg systolic) and tachycardic (pulse 150/minute), with mild neck stiffness, decreased movement on the left side, abdominal distension, and absent bowel sounds. Other physical signs were unremarkable. Initial investigations showed a normocytic normochromic anaemia (haemoglobin 94 g/l), a raised total white cell count ($14.3 \times 10^9/l$) with neutrophilia ($13.3 \times 10^9/l$), and a low platelet count ($42 \times 10^9/l$). He was also in renal failure (urea 65.6 mmol/l, creatinine 446 μ mol/l). The differential diagnosis included sepsis or internal haemorrhage and he was given an initial intravenous dose of cefuroxime and metronidazole. A computed tomogram of the brain and lumbar puncture were planned after initial resuscitation. Three hours after admission, while still being investigated, he sustained a cardiac arrest from which resuscitation was unsuccessful.

Post mortem examination showed left-sided fibrinous pleuritis and there were widespread petechial haemorrhages over the visceral pleura, kidneys, and bowel mucosa. Both lungs were congested and oedematous and histological examination showed chronic obstructive airways disease with possible resolving viral pneumonia. There was severe calcific aortic stenosis with associated left ventricular hypertrophy but no evidence of infective endocarditis. The liver had a nutmeg appearance due to venous congestion and the spleen was soft, consistent with a septicaemic process. The stomach and bowel contained a large volume of altered blood and melaena. The brain contained a 2×1 cm softening in the right occipital lobe and although the cerebrospinal fluid was cloudy there was no purulent exudate in the subarachnoid space. Histological examination showed septic emboli in the coronary, cerebral, and renal vasculature, associated with an acute vasculitis with destruction of blood vessel walls. This had resulted in widespread focal glomerular necrosis and a suppurative myocarditis (figs 1 and 2).

A single blood culture bottle taken before death grew a group C *Streptococcus* sensitive to penicillin, erythromycin, and ampicillin,

Department of
Histopathology,
Southampton General
Hospital
A C Bateman
A D Ramsay

Department of
Microbiology,
Southampton General
Hospital
A P Pallett

Correspondence to:
Dr A C Bateman,
Department of
Histopathology, Level E,
South Block, Southampton
General Hospital,
Southampton SO9 4XY
Accepted for publication
5 May 1993

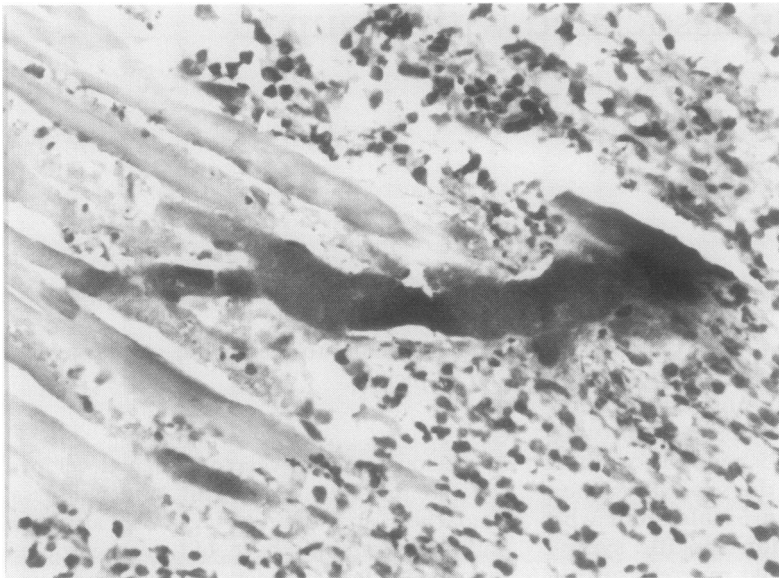


Figure 1 Myocardium showing bacteria between myocardial fibres and associated inflammation (haematoxylin and eosin).

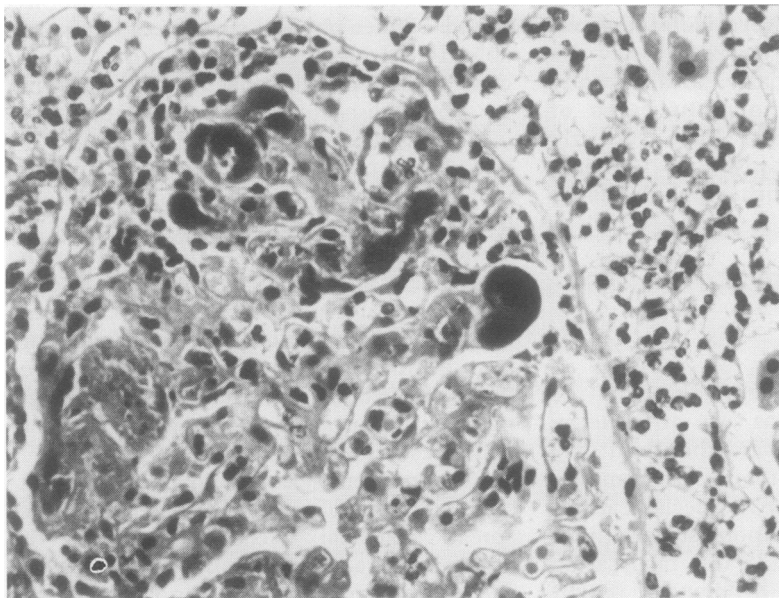


Figure 2 Glomerulus showing bacteria within glomerular capillary loops, inflammatory cells, and debris within Bowman's space, and surrounding inflammation (haematoxylin and eosin).

with a coagulase negative *Staphylococcus*. Swabs taken after death from the pharynx, lungs, and spleen were negative. Post mortem cerebrospinal fluid examination showed substantially raised red and white cell counts (6.8 and $3.1 \times 10^9/l$, respectively) and numerous Gram positive cocci with the morphology of streptococci. Subsequent culture was negative.

The group C isolates from these patients did not survive transit to the reference laboratory, hence further identification was not possible.

Discussion

Lancefield group C streptococci are an uncommon cause of human infection, but are more commonly pathogenic in animals.^{1,2} In a

retrospective study at the Mayo Clinic 150 000 blood cultures between 1968 and 1977 yielded streptococci on 2660 occasions. Only eight were group C, of which two were probably contaminants.¹ They usually form β haemolytic colonies on blood agar, but all patterns of haemolysis are reported, and they may be sensitive to bacitracin, thus leading to confusion with pneumococci during identification.³

Four species of *Streptococcus* are recognised within group C. The most frequently isolated is *Streptococcus equisimilis*, which produces streptokinase and streptolysin O. Bradley *et al* found that this organism was identified in 19.3% of speciated isolates from 88 patients with group C streptococcal infection.² *S. equisimilis* and *S. zooepidemicus* may infect a variety of animals, including cattle, swine, horses, sheep, foxes, and guinea pigs. *S. equi* causes strangles in horses, and *S. dysgalactiae* causes mastitis in cows but rarely affects humans.³ Other streptococci, such as *S. milleri* may possess group C antigens but are not usually recognised as members of the group. Patients with group C streptococcal infection may have a history of contact with animals or consumption of unpasteurised milk.²

Group C streptococci are found as normal pharyngeal flora in up to 8% of healthy adults.² They also colonise the skin, nose, vagina, rectum, and in newborns, the umbilicus.¹ They are an unusual cause of pharyngitis, particularly in school children, where most infections are caused by group A streptococci.

Recently there have been increasing reports of serious infections associated with group C streptococci, including endocarditis, meningitis, pneumonia, septic arthritis, acute epiglottitis, cellulitis, and puerperal fever.²⁻⁴ Many of the patients are elderly, and most have other illnesses or predisposing factors. Bradley *et al* found underlying disease in 72.7% of patients, of which 20.5% was cardiovascular, and 20.5% was malignant.²

Infections may occur in more unusual sites, particularly in patients with impaired immunity. Nitta *et al* described a case of pyomyositis associated with a group C streptococcus in a 41 year old man with AIDS.⁵ In some immunocompromised patients group C streptococci may be associated with septicaemia without identification of a primary infective focus. Bradley *et al* described bacteraemia in a 49 year old woman with rectal carcinoma.²

Group C streptococci are characteristically fully sensitive to penicillin, erythromycin, and ampicillin, although tolerance to penicillin is documented.² Previous reports have concluded that prompt antibiotic treatment is usually associated with a favourable outcome.^{1,4} Group C streptococci may cause serious disease in young people without obvious predisposition to infection, despite apparently adequate treatment with the correct antibiotics.^{3,6} These infections may follow a fulminant course with progressive multiple organ failure, and can be fatal. Stamm and

Cobbs describe a 22 year old man who initially presented with tonsillitis associated with *S. equisimilis*. Despite appropriate antibiotic treatment he developed pneumonia, empyema, septicaemia, and septic arthritis, and died after a protracted illness. The *Streptococcus* was isolated from his throat, left hip, and blood.³ In a similar fatal case Barnham *et al* described a 38 year old woman who presented with haematuria, oedema, and dyspnoea. Despite prompt antibiotic treatment she developed severe renal failure and disseminated intravascular coagulation. Post mortem examination showed lobar pneumonia and diffuse proliferative glomerulonephritis.⁶ It is not clear why some infections with these organisms follow a particularly virulent course, although one explanation is that the organism may become more virulent during an infective episode.³

Environmental factors may be important in the transmission of hospital acquired group C streptococcal infection. Teare *et al* report an outbreak of 33 cases of puerperal fever in three geographically close hospitals. The causative organism was isolated from the showers, toilets, and from the throat swabs of seven nurses on the ward where most cases had originated.⁴

The two cases reported here presented in the same month, but there was no evidence that they were related and no increase in the isolation of group C streptococci occurred in the six months before or after isolation. These cases are unusual for several reasons. Both had infections severe enough to cause death shortly after initial presentation, and there was no history of previous domestic or occupational contact with animals in either case. The first patient had no major underlying illnesses that would predispose to infection. Despite careful examination there was no evidence of an unequivocal primary site for the infection. The isolation of group C streptococci from several tissues, including the endocardium, reflected the severity of the septicaemia but there was no evidence of infective endocarditis. Severe streptococcal infection may result in diarrhoea and this has been described in septicaemia due to group A streptococci.⁷ The mechanism of this observation is unclear, but the authors considered it a secondary phenomenon due to severe infection rather than the result of primary bowel infection.

The second patient had chronic lung and cardiac valve disease before group C streptococcal infection developed and the findings after death suggested viral pneumonia. Several predisposing factors were therefore present, in contrast to the first case. This

patient showed evidence of particularly severe infection with septicaemia and early meningitis, but as with the first case there was no evidence of infective endocarditis. The clinical and pathological picture in both cases was that of a rapidly progressive fatal illness. This may have resulted from toxin production by the infecting organisms, a feature that has not been described in group C streptococcal infection. The toxic shock syndrome was first reported in relation to staphylococci and more recently it has become apparent that certain strains of Lancefield group A streptococcus can produce exotoxins.⁸ Toxin production may be mediated by a bacteriophage virus and these toxins may stimulate tumour necrosis factor release from macrophages as a "final common pathway" of tissue damage.^{8,9} Toxin producing group A streptococci may cause a variety of infections, such as peritonitis and severe necrotising fasciitis, and these infections are characteristically associated with profound, frequently fatal septicaemic shock.¹⁰

Group C streptococci rarely cause human infection and usually affect patients in contact with animals or with impaired immunity, although they may cause serious disease in the absence of these predisposing factors. The cases presented in this report show that life threatening infections may be caused by unusual organisms and that virulent strains may be rapidly fatal. Both patients presented at an advanced stage and died soon afterwards. A primary infective site may not always be apparent, and if patients present when already seriously ill, they may die despite prompt and appropriate antibiotic treatment.

- Mohr DN, Feist DJ, Washington JA, Hermans PE. Infections due to Group C streptococci in man. *Am J Med* 1979;66:450-6.
- Bradley SF, Gordon JJ, Baumgartner DD, Marasco WA, Kauffman CA. Group C streptococcal bacteremia: analysis of 88 cases. *Rev Infect Dis* 1991;13:270-80.
- Stamm AM, Cobbs CG. Group C streptococcal pneumonia: Report of a fatal case and review of the literature. *Rev Infect Dis* 1980;2:889-98.
- Teare EL, Smithson RD, Efstratiou A, Devenish WR, Noah ND. An outbreak of puerperal fever caused by group C streptococci. *J Hosp Infect* 1989;13:337-47.
- Nitta AT, Kuritzkes DR. Pyomyositis due to group C streptococci in a patient with AIDS (letter). *Rev Infect Dis* 1991;13:1254-5.
- Barnham M, Ljunggren A, McIntyre M. Human infection with *Streptococcus zooepidemicus* (Lancefield group C): three case reports. *Epidemiol Infect* 1987;98:183-90.
- Teall A, Visuvanathan S, Payne A, Silverstone A. Unsuspected streptococcal infection presenting with diarrhoea in late pregnancy. *J Infect* 1987;14:185-6.
- Sanderson P. Do streptococci cause toxic shock? *BMJ* 1990;301:1006-7.
- Cohen J, Bayston K, Tomlinson M. Do streptococci cause toxic shock? *BMJ* 1990;301:1277-8.
- Goepel JR, Richards DG, Harris DM, Henry L. Fulminant streptococcus pyogenes infection. *Br Med J* 1980;281:1412.