

Coexpression of intercellular adhesion molecule-1 and class I major histocompatibility complex antigens on hepatocyte membrane in chronic viral hepatitis

C M Chu, Y F Liaw

Abstract

Aims—To evaluate the role of hepatocyte expression of leucocyte adhesion molecules and major histocompatibility complex (MHC) antigens in the pathogenesis of chronic viral hepatitis.

Methods—The expression of intercellular adhesion molecule 1 (ICAM-1), lymphocyte function associated antigen 3 (LFA-3), and MHC class I and II antigens on hepatocyte membrane in relation to the histological and biochemical activities was studied in patients with chronic B hepatitis, chronic persistent hepatitis (CPH) $n = 23$; chronic active hepatitis (CAH) $n = 20$; chronic D hepatitis (CAH) $n = 6$; and chronic non-A, non-B hepatitis (CPH $n = 4$, CAM $n = 6$). Six of the latter were hepatitis C virus antibody positive.

Results—In chronic B hepatitis ICAM-1 and MHC-I were expressed significantly more in patients with CAH than in those with CPH ($p < 0.001$), while the expression of LFA-3 and MHC-II showed no significant difference, irrespective of serum HBeAg or hepatitis B virus DNA. Similar findings were noted in non-A, non-B hepatitis. Regardless of the viral aetiology, patients with CAH had a significantly higher degree of ICAM-1 and MHC-I expression than LFA-3 ($p < 0.001$ *v* ICAM-1 and MHC-I, respectively) and MHC-II ($p < 0.001$ *v* ICAM-1 and MHC-I, respectively) expression. Those with CPH showed little or no difference in the expression of these four molecules. Furthermore, serum ALT values positively correlated with the hepatocyte expression of ICAM-1 ($p < 0.001$) and MHC-I ($p < 0.001$), but not LFA-3 ($p > 0.05$) and MHC-II ($p > 0.05$).

Conclusions—In chronic viral hepatitis hepatocyte expression of ICAM-1 and MHC-I might be important for immunosurveillance against virally infected hepatocytes, while the expression of LFA-3 and MHC-II does not seem to have a role in the pathogenesis of chronic viral hepatitis.

(J Clin Pathol 1993;46:1004-1008)

It has been suggested that hepatitis B virus (HBV) is not directly cytopathic and that liver injury is mediated by cytotoxic T lymphocytes.¹⁻⁵ The generation of cytotoxic T

lymphocyte killing requires interaction between effector cytotoxic T lymphocytes and target cells.⁶ The specificity of the cellular immune response is determined by the T cell receptors interacting with the antigen and the major histocompatibility complex (MHC) antigens,⁷ but other T cell and target cell surface molecules are required before T cell adhesion can occur.^{8,9} Two leucocyte adhesion pathways have been characterised that are essential for T cell adhesion to several other cell types. The first includes the lymphocyte function associated antigen 1 (LFA-1), present on almost all leucocytes¹⁰ and its major target cell ligand, the intercellular adhesion molecule 1 (ICAM-1), expressed on many cell types. The second adhesion pathway involves the interaction of the T cell surface molecule CD2 with its specific ligand, the lymphocyte function associated antigen 3 (LFA-3), which is expressed on a wide variety of cells.^{11,12} Recent evidence suggests that these two leucocyte adhesion pathways are important not only in regulating antigen independent adhesion but also in delivering costimulatory signals to amplify T cell activation.¹³⁻¹⁵ It seems that in chronic HBV infection the expression of ICAM-1 and LFA-3 adhesion molecules by hepatocytes in inflammatory sites may be an important initiator for hepatocyte T lymphocyte interaction; the expression of MHC antigens may be more important in postadherence antigenic recognition.

Methods

Fifty nine patients with chronic viral hepatitis confirmed histopathologically were studied. All had increased serum alanine aminotransferase values for more than six months before the histological examination, and drugs or alcohol misuse was excluded as a likely cause. Their detailed clinical and laboratory data are listed in the table. Forty three patients were hepatitis B surface antigen (HBsAg) positive and antibody against hepatitis delta virus (anti-HDV) negative. HBV DNA was positive in 12 hepatitis Be antigen (HBeAg) positive patients with chronic persistent hepatitis (CPH), 14 HBeAg positive patients with chronic active hepatitis (CAH), and two anti-HBe positive patients with CAH. Six patients had chronic D hepatitis as they were HBsAg and anti-HDV positive and had hepatitis delta antigen (HDAg) detectable in the liver. Ten patients were HBsAg negative and were presumed to have chronic non-A, non-B

Liver Unit, Chang Gung Memorial Hospital & Chang Gung Medical College, Taipei, Taiwan
C M Chu
Y F Liaw

Correspondence to:
Dr Chia-Ming Chu,
Liver Unit, Chang Gung
Memorial Hospital, 199
Tung Hwa North Road,
Taipei, Taiwan, 10591.

Accepted for publication
7 July 1993

Clinical and laboratory data of patients studied

Category	Cases (n)	Age* (yr)	Sex (M:F)	AST (IU/l) (n < 40)	*ALT (IU/l) (n < 40)
Chronic B hepatitis					
HBeAg positive CPH	14	24 (2)	10:4	61 (5)	115 (23)
HBeAg positive CAH	16	27 (2)	13:3	128 (15)	268 (36)
anti-HBe positive CAH	4	33 (5)	4:0	142 (39)	303 (130)
anti-HBe positive CPH	9	36 (3)	8:1	31 (5)	46 (5)
Chronic D hepatitis					
Anti-HBe positive CAH	6	35 (3)	6:0	131 (30)	261 (64)
Chronic non-A, non-B hepatitis†					
CPH	4	29 (4)	2:2	41 (6)	55 (7)
CAH	6	31 (3)	3:3	129 (34)	266 (72)

CPH: Chronic persistent hepatitis; CAH: Chronic active hepatitis.

*Data are mean (SEM).

†6 were antibody against hepatitis C virus positive.

(NANB) hepatitis. Of these, six were seropositive for antibodies against hepatitis C virus (anti-HCV).

Serum HBsAg, HBeAg, and anti-HDV were assayed using radioimmunoassay kits (Ausria-II, HBe-RIA and anti-delta, Abbott Laboratories, Chicago, Illinois). Serum anti-HCV was assayed using a second generation enzyme immunoassay with synthetic peptides from both structural and non-structural regions of HCV (UBI HCV EIA, United Biochemical, New York). Serum HBV DNA was assayed by spot hybridisation with ³²P-labelled cloned HBV-DNA, and hepatocyte expression of HDAg was studied by direct immunofluorescence using fluorescein isothiocyanate-labelled anti-delta, as reported before.¹⁶

Liver specimens were obtained by percutaneous needle biopsy with a Menghini needle. Fragments of specimens were snap frozen in liquid nitrogen cooled isopentane and stored at -70°C until use. Samples of the same biopsy specimens were also fixed in 10% formaldehyde and embedded in paraffin wax for routine histological diagnosis. Cryostat sections (5 µm) were dried overnight at room temperature and fixed in carbon tetrachloride at 4°C for 10 minutes, followed by extensive washing with phosphate buffered saline (pH 7.2) before staining. The expression of LFA-1, CD2, ICAM-1, LFA-3, MHC class I and class II antigens in liver was studied using a three step immunoalkaline-phosphatase (APAAP) method. Briefly, sections were incubated for 45 minutes at room temperature with the following mouse monoclonal antibodies: Dako-CD11a (Dakopatts, working dilution 1 in 50) reacting with the α -chain of LFA-1; Dako-T11 (Dakopatts, working dilution 1 in 50) specific for CD2; antibodies against CD54 and CD58 (Immunotech, SA, working dilution 1 in 50) specific for ICAM-1 and LFA-3, respectively; Dako-HLA-ABC (Dakopatts, working dilution 1 in 50) specific for MHC class I antigens; and Dako-HLA-DR (Dakopatts, working dilution 1 in 50) specific for MHC class II antigens. After a wash in TRIS-buffered saline (TBS), sections were reincubated for 30 minutes with rabbit anti-mouse immunoglobulin (Dako; working dilution 1 in 20). After a further wash in TBS, APAAP immune complexes (Dako; working dilution 1 in 30) were applied to the

sections for 30 minutes. The last two steps were repeated for 10 minutes each and finally the alkaline phosphatase reaction was developed using the hexazotised new fuchsin procedure. Endogenous alkaline phosphatase activity was blocked by adding levamisole to the substrate solution at a concentration of 1 mmol/l. Control tests consisted of omission of the primary antibody or substitution with non-immune mouse immunoglobulins (Dako) and incubation with alkaline phosphatase substrate alone.

The expression of ICAM-1, LFA-3, MHC class I and class II antigens on the hepatocyte membrane was scored on a scale of 0 to 3+:(0) undetectable, when they were present on the sinusoidal lining cells but absent on the hepatocyte membrane; (1+) positive staining on the hepatocyte membrane in only small clusters (<10%) of hepatocytes; (2+) positive staining on the hepatocyte membrane in 10–50% of hepatocytes; and (3+) positive staining on the hepatocyte membrane in more than half of the hepatocytes with honeycomb appearance.

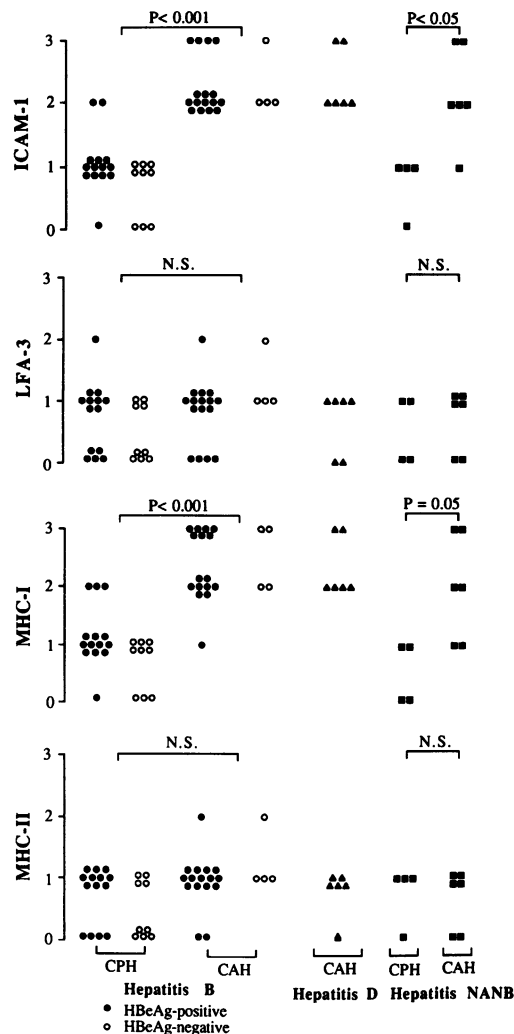
Results were analysed using Wilcoxon's non-parametric rank sum test and Spearman's rank correlation test.

Results

LFA-1 was expressed on most of the inflammatory infiltrates as well as on the sinusoidal lining cells. Serial sections showed CD2 expression on the same cells positive for LFA-1. ICAM-1, LFA-3, MHC class I and class II antigens were expressed on the sinusoidal lining cells and on a variable proportion of mononuclear inflammatory cells throughout the portal areas and lobular parenchyma.

Among 43 patients with chronic type B hepatitis, the expression of ICAM-1 on the hepatocyte membrane was similar to that of MHC class I antigens. The degree of ICAM-1 expression was significantly higher than that of LFA-3 ($p < 0.001$) and MHC class II antigens ($p < 0.001$), as was the expression of MHC class I antigens ($p < 0.001$ v LFA-3 and MHC class II antigens, respectively). The expression of ICAM-1 and MHC class I antigens on the hepatocyte membrane correlated well with the site and the extent of the inflammatory infiltrates in liver tissue as well as the histological activity. Figure 1 shows that patients with CAH had a significantly higher degree of ICAM-1 and MHC class I antigen expression than those with CPH, irrespective of serum HBeAg or HBV-DNA. An example of ICAM-1 expression on hepatocyte membrane in patients with CPH v CAH is shown in fig 2. In contrast, the expression of LFA-3 and MHC class II antigens showed no significant difference between patients with CAH and those with CPH. Similar observations were seen in patients with chronic NANB hepatitis. In general, regardless of the viral aetiology, patients with CAH had a significantly higher degree of expression of ICAM-1 and MHC class I antigens than

Figure 1 Expression of ICAM-1, LFA-3, MHC-I and MHC-II on the hepatocyte membrane in chronic hepatitis type B, D, and non-A, non-B (NANB). Hepatocyte expression of ICAM-1, LFA-3, MHC-I and MHC-II antigens is semiquantitatively scored on a scale of 0 to 3+. CPH: chronic persistent hepatitis; CAH: chronic active hepatitis.



that of LFA-3 ($p < 0.001$ v ICAM-1 and MHC class I antigens, respectively) and MHC class II antigens ($p < 0.001$ v ICAM-1 and MHC class I antigens, respectively), while patients with CPH had little or no difference in the expression of these four molecules.

Among a total of 59 controls with chronic viral hepatitis, ALT values correlated positively with the expression of ICAM-1 ($p < 0.001$) and MHC class I antigens ($p < 0.001$) on the hepatocyte membrane, but not with that of LFA-3 ($p > 0.05$) and MHC class II antigens ($p > 0.05$) (fig 3).

Discussion

The expression of ICAM-1 and MHC class I antigens, but not LFA-3 and MHC class II antigens, on the hepatocyte membrane correlated significantly with the histological and biochemical activities in chronic HBV infection (figs 1 and 3). These findings suggest that hepatocyte expression of ICAM-1 and MHC class I antigens might be important for immune surveillance against virus infected hepatocytes in chronic HBV infection, while hepatocyte expression of LFA-3 and MHC class II antigens does not seem to have a role in the pathogenesis of chronic B hepatitis. Similar findings were found in patients with

chronic C and D hepatitis (figs 1 and 3). The pathogenesis of liver cell damage in chronic HCV and HDV infection remains unknown, but recent studies have shown that there was a prominent CD8 positive T lymphocyte infiltration in the area of liver cell necrosis in chronic C and D hepatitis,^{17,18} similar to those observed in chronic B hepatitis.^{2,3} The present findings thus suggest that an immunological mechanism might also be involved in the pathogenesis of chronic C and D hepatitis, though the possibility of the direct cytopathic effect of HCV and HDV still cannot be excluded.

Previous studies have shown enhanced expression of ICAM-1¹⁹⁻²² as well as MHC class I antigens²³⁻²⁹ on the target structures in a number of inflammatory liver diseases. The mechanisms leading to their enhanced expression, however, remain to be elucidated. The present results indicated that hepatocyte expression of ICAM-1 and MHC class I antigens in chronic B hepatitis did not seem to be upmodulated by active HBV replication itself. Studies on cultured cells have shown that both ICAM-1 and MHC class I antigen expression is induced on many cell types in response to inflammatory lymphokines, such as interleukin-1, tumour necrosis factor and γ -interferon.³⁰⁻³⁴ The observation of an enhanced expression of ICAM-1 and MHC class I antigens simultaneously on the hepatocyte membrane at the site of necroinflammation and active cellular infiltration is thus consistent with the presence of inflammatory lymphokines at such sites, and with the induction of ICAM-1 and MHC class I antigens by such mediators. It is therefore suggested that the release of the inflammatory lymphokines by virus sensitised T lymphocytes around the area of virally infected hepatocytes will enhance hepatocyte expression of ICAM-1 and MHC class I antigens. The upmodulated expression of ICAM-1 on the hepatocyte membrane might facilitate movement of, and possibly "guiding", more T lymphocytes toward virally infected hepatocytes, but it might also serve as an important initiator for hepatocyte/T lymphocyte interaction. The latter then will maintain a broad area of approximation between cells so that MHC class I antigen-restricted, T lymphocyte mediated killing of infected hepatocytes can occur.

Coexpression of ICAM-1 and MHC class II antigens by hepatocytes, which correlated positively with the site and extent of the inflammatory infiltrates, has recently been reported in chronic B hepatitis by Volpes *et al.*²⁰ In keeping with many previous observations, however,^{24,27-29} our study showed that hepatocyte expression of MHC class II antigens was negligible, if any, regardless of liver inflammatory activity in chronic HBV infection. As many inflammatory lymphokines, including interferon, are potent inducers for cell surface expression of both class I and class II MHC antigens on many cell types,³⁵⁻³⁷ it remains unclear why the hepatocyte expression of MHC class II antigens is minimal at

Figure 2 In chronic persistent hepatitis, the expression ICAM-1 on the hepatocyte membrane is (A) negative or (B) positive only in small clusters of hepatocytes (large arrow heads). Note strong staining of ICAM-1 on the sinusoidal lining cells (small arrows). In chronic active hepatitis, in addition to the staining on the sinusoidal lining cells (small arrows), the expression of ICAM-1 on the hepatocyte membrane is (C) prominent in the periportal hepatocytes (large arrow heads) or (D) diffuse over the whole liver parenchyma with honeycomb appearance. P indicates portal tract.

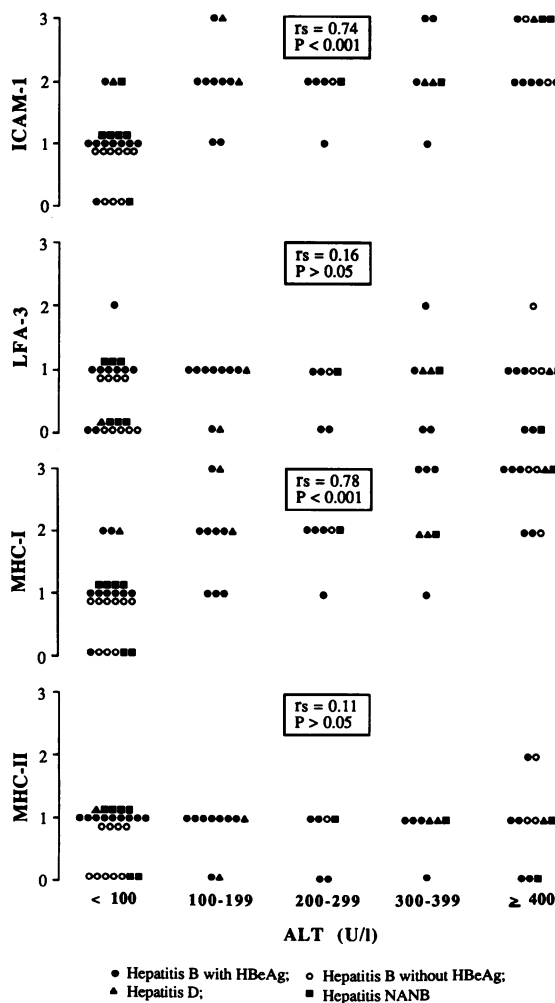
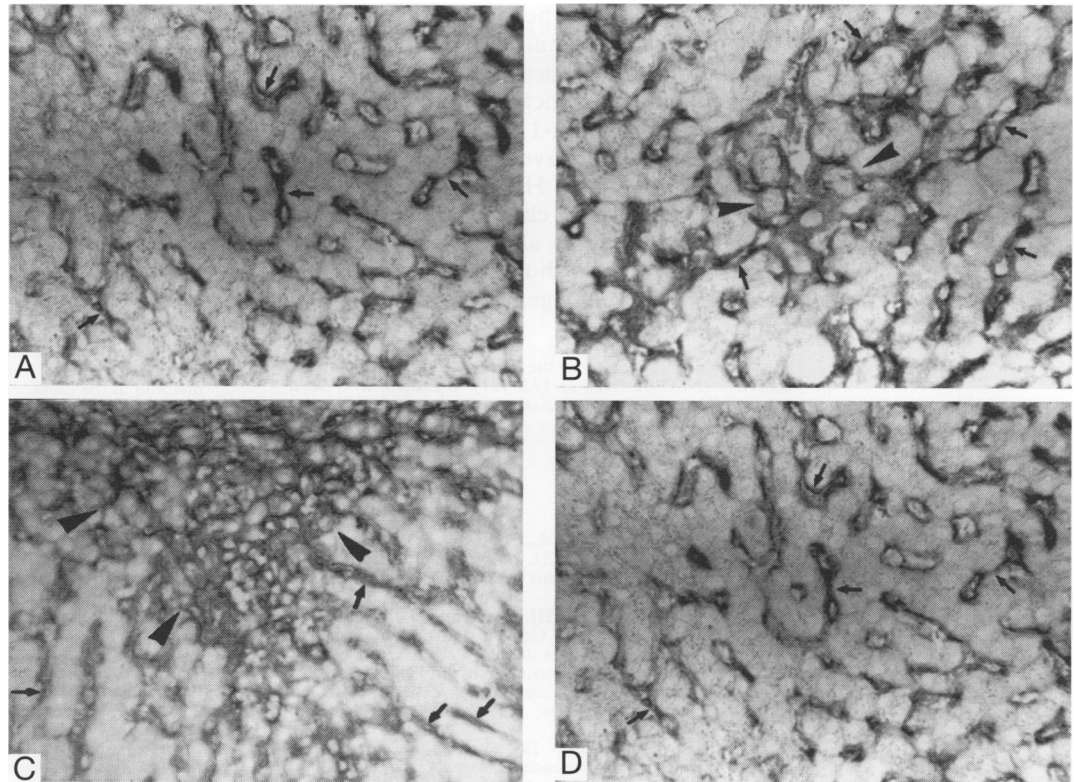


Figure 3 Correlation of serum ALT values with hepatocyte membrane expression of ICAM-1, LFA-3, MHC-I and MHC-II in chronic viral hepatitis. Hepatocyte expression of ICAM-1, LFA-3, MHC-I and MHC-II antigens is semiquantitatively scored on a scale of 0 to 3+. *r_s* indicates correlation coefficient using Spearman's rank correlation coefficient.

the site of inflammatory response, where there is increased expression of MHC class I antigens. Of note is that interferon treatment in chronic B or C hepatitis enhanced hepatocyte expression of MHC class I antigens with little or no effect on the expression of MHC class II antigens.²⁷⁻³⁷ One of the possibilities is that the effects of interferon or other inflammatory lymphokines on cell surface expression of MHC antigens depend on the type and origin of the cells.³⁸ Further studies are needed to investigate the in vitro effect of different inflammatory lymphokines on hepatocyte expression of MHC antigens.

Although most inflammatory infiltrates express CD2 molecules in chronic viral hepatitis, the present study showed that LFA-3, the ligand for CD2, was usually expressed only in a small cluster of hepatocytes, regardless of the biochemical or histological activity. These findings argue against the CD2/LFA-3 leucocyte adhesion pathway in the pathogenesis of chronic viral hepatitis.²¹⁻³⁹ This discrepancy may be because of the differences in the choice of antisera, tissue manipulation, or staining protocols. Of note is that the regulation of cell surface expression of LFA-3 is different from that of ICAM-1. Studies on certain cell type have shown that LFA-3 expression was specifically induced by interleukin-4, but not by other inflammatory lymphokines, including interleukin-1 and γ -interferon.⁴⁰ It remains unclear whether interleukin-4 is produced locally by the inflammatory infiltrates in chronic viral hepatitis. In addition, further study on the effect of various lymphokines on hepatocyte expression of LFA-3 is also mandatory.

In conclusion, in chronic viral hepatitis ICAM-1 and MHC class I antigens are

coexpressed on the hepatocyte membrane, which correlated significantly with the biochemical and histological results. These data indicated the significance of hepatocyte expression of ICAM-1 and MHC class I antigen in immune surveillance against virally infected hepatocytes. Hepatocyte expression of LFA-3 and MHC class II antigens correlated little or not at all with inflammatory activity in liver, and thus did not seem to be involved in the pathogenesis of chronic viral hepatitis.

This study was supported by the National Science of Council of R.O.C. (NSC 81-0419-B-182-521). We thank W C Shyu and C C Wang for their technical assistance and L F Yao for her secretarial help.

- 1 Thomas HC, Montano L, Goodall A, deKoning R, Oladapo J, Wiedman KH. Immunological mechanisms in chronic hepatitis B virus infection. *Hepatology* 1982;2:116S-21S.
- 2 Eggink HF, Houthoff HJ, Huitema S, Wolters G, Poppema S, Gips CH. Cellular and humoral immune reactions in chronic liver disease. I. lymphocyte subsets in liver biopsies of patients with untreated idiopathic autoimmune hepatitis, chronic active hepatitis B and primary biliary cirrhosis. *Clin Exp Immunol* 1982;50:17-24.
- 3 Page GR, Rieber EP, Eisenburg J, Hoffmann R. Involvement of cytotoxic/suppressor T-cell subset in liver tissue injury of patients with acute and chronic liver disease. *Gastroenterology* 1983;85:657-62.
- 4 Eddleston ALWF, Mondelli M, Mieli-Vergani G, Williams R. Lymphocyte cytotoxicity to autologous hepatocytes in chronic hepatitis B virus infection. *Hepatology* 1982;2:122S-7S.
- 5 Pignatelli M, Waters J, Lever A, Iwarson S, Gerety R, Thomas HC. Cytotoxic T cell responses to the nucleocapsid proteins of HBV in chronic hepatitis: Evidence that antibody modulation causes protracted infection. *J Hepatol* 1987;4:15-21.
- 6 Shaw S, Luce GEG, Quinones R, Gress RE, Springer TA, Sanders ME. Two antigen-independent adhesion pathways used by human cytotoxic T-cell clones. *Nature* 1986;323:262-4.
- 7 Meuer SC, Acuto O, Hercend T, Schlossman SF, Reinherz EL. The human T-cell receptor. *Ann Rev Immunol* 1984;2:23-50.
- 8 Shaw S, Luce GEG. The lymphocyte function-associated antigen (LFA)-1 and CD2/LFA-3 pathway of antigen-independent human T cell Adhesion. *J Immunol* 1987;139:1037-45.
- 9 Springer TA, Dustin ML, Kishimoto TK, Marlin SD. The lymphocyte function associated LFA-1, CD2 and LFA-3 molecules: Cell adhesion receptors of the immune system. *Ann Rev Immunol* 1987;5:233-52.
- 10 Kurzinger K, Reynolds T, Germain SD, Springer TA. A novel lymphocyte function-associated antigen (LFA-1): Cellular distribution, quantitative expression and structure. *J Immunol* 1981;127:596-602.
- 11 Kreusky AM, Sanchez-Madrid F, Robbins E, Nagy J, Springer TA, Burakoff SJ. The functional significance, distribution and structure of LFA-1, LFA-2 and LFA-3: Cell surface antigens associated with CTL-target interaction. *J Immunol* 1983;131:611-6.
- 12 Selvaraj P, Plunkett MJ, Dustin ML, Sanders ME, Shaw S, Springer TA. T lymphocyte glycoprotein CD2 binds to the cell surface ligand LFA-3. *Nature* 1987;326:400-3.
- 13 Wacholtz MC, Patel SS, Lipsky PE. Leukocyte function-associated antigen 1 is an activation molecule for human T cells. *J Exp Med* 1989;170:431-48.
- 14 Bierer BA, Peterson A, Gorga J, Hermann SH, Burakoff SJ. Synergistic T cell activation via the physiological ligands for CD2 and the T cell receptor. *J Exp Med* 1988;168:1145-56.
- 15 Moingeon P, Chang HC, Wallner BP, Stebbins C, Frey AZ, Reinherz EL. CD2-mediated adhesion facilitates T lymphocyte antigen recognition function. *Nature* 1989;339:312-4.
- 16 Chu CM, Liaw YF. Intrahepatic expression of pre-S1 and pre-S2 antigens in chronic hepatitis B virus infection in relation to hepatitis B virus replication and hepatitis delta virus superinfection. *Gut* 1992;33:1544-8.
- 17 Onji M, Kikuchi T, Kumon I, et al. Intrahepatic lymphocyte subpopulations and HLA class I antigen expression by hepatocytes in chronic hepatitis C. *Hepato-gastroenterol* 1992;39:340-3.
- 18 Chu CM, Liaw YF. Studies on the composition of the mononuclear cell infiltrates in liver from patients with chronic active delta hepatitis. *Hepatology* 1989;10:911-5.
- 19 Adams DH, Hubscher SG, Shaw J, Rothlein R, Neuberger JM. Intercellular adhesion molecule on liver allografts during rejection. *Lancet* 1989;ii:1122-5.
- 20 Volpes R, Van den Oord JJ, Desmet VJ. Hepatic expression of intercellular adhesion molecule-1 (ICAM-1) in viral hepatitis B. *Hepatology* 1990;12:148-54.
- 21 Malizia G, Dino O, Pisa R, et al. Expression of leukocyte adhesion molecules in the liver of patients with chronic hepatitis B virus infection. *Gastroenterology* 1991;100:749-55.
- 22 Burra P, Hubscher SG, Shaw J, Elias E, Adams DH. Is the intercellular adhesion molecule-1/leukocyte function associated antigen 1 pathway of leukocyte adhesion involved in the tissue damage of alcoholic hepatitis? *Gut* 1992;33:268-71.
- 23 Barbatis C, Woods J, Morton JA, Fleming KA, McMichael A, O'McGee G. Immunohistochemical analysis of HLA (A, B, C) antigens in liver disease using a monoclonal antibody. *Gut* 1981;22:985-91.
- 24 Fukusato T, Gerber MA, Thung SN, Ferrone S, Schaffner F. Expression of HLA class I antigens on hepatocytes in liver disease. *Am J Pathol* 1986;123:264-70.
- 25 Franco A, Barnaba V, Natali PG, Balsano C, Musca A, Balsano F. Expression of class I and class II major histocompatibility antigens on human hepatocytes. *Hepatology* 1988;8:449-54.
- 26 Nagafuchi Y, Hobbs KEF, Thomas HC, Scheuer PJ. Expression of β_2 -microglobulin on hepatocytes after liver transplantation. *Lancet* 1985;ii:551-4.
- 27 Pignatelli M, Waters J, Brown D, et al. HLA class I antigens on the hepatocyte membrane during recovery from acute hepatitis B virus infection and during interferon therapy in chronic hepatitis B virus infection. *Hepatology* 1986;6:349-53.
- 28 Ballardini G, Bianchi FB, Mirakian R, Fallani M, Pisi E, Bottazzo GF. HLA-A, B, C, HLA-D/DR and HLA-D/DQ expression on unfixed liver biopsy sections from patients with chronic liver disease. *Clin Exp Immunol* 1987;70:35-46.
- 29 Chu CM, Shyu WC, Kuo RW, Liaw YF. HLA class I antigen display on hepatocyte membrane in chronic hepatitis B virus infection its role in the pathogenesis of chronic type B hepatitis. *Hepatology* 1988;8:712-7.
- 30 Dustin ML, Rothlein R, Bhan AK, Dinarello CA, Springer TA. Induction by IL-1 and interferon- γ : Tissue distribution, biochemistry, and function of a natural adherence molecule (ICAM-1). *J Immunol* 1986;137:245-53.
- 31 Rothlein R, Czajkowski M, O'Neill MM, Marlin SD, Mainolfi E, Merluzzi VJ. Induction of intercellular adhesion molecule 1 on primary and continuous cell lines by proinflammatory cytokines. *J Immunol* 1988;141:1665-9.
- 32 Basham TY, Bourgeade MF, Creasey AA, Merigan TC. Interferon increases HLA synthesis in melanoma cells: interferon-resistant and sensitive cell lines. *Proc Natl Acad Sci USA* 1982;79:3265-9.
- 33 Collins T, Lapiere LA, Fiers W, Strominger JL, Pober JS. Recombinant human tumor necrosis factor increases mRNA levels and surface expression of HLA-A, B, antigens in vascular endothelial cells and dermal fibroblasts in vitro. *Proc Natl Acad Sci USA* 1986;83:446-50.
- 34 Peizesmaier K, Scheurich P, Schluter C, Kronke M. Tumor necrosis factor enhances HLA-A, B, C and HLA-DR gene expression in human tumor cells. *J Immunol* 1987;138:975-80.
- 35 Durandy A, Virelizier, Griscelli C. Enhancement by interferon of membrane HLA antigens in patients with combined immunodeficiency with defective HLA expression. *Clin Exp Immunol* 1983;52:173-8.
- 36 Halloran PF, Wadgymar A, Autenried P. The regulation of expression of major histocompatibility complex products. *Transplantation* 1986;41:413-20.
- 37 Pescarmona E, Gandin C, Monardo F, et al. MHC-class I and class II antigen expression in anti-HCV positive chronic hepatitis: effect of IFN-alpha and IFN-alpha plus ursodeoxycholic acid. *J Hepatol* 1992;17:S37.
- 38 Billard C, Febus D, Kolb JP, et al. Qualitative differences in effects of recombinant α -, β - and γ -interferons in human peripheral blood leukocytes in vitro. *Ann Inst Pasteur/Immunol* 1986;137c:259-72.
- 39 Autschbach F, Meuer SC, Moebius U, et al. Hepatocellular expression of lymphocyte function-associated antigen 3 in chronic hepatitis. *Hepatology* 1991;14:223-30.
- 40 Rousset F, Billand M, Blanchard D, et al. IL-4 induces LFA-1 and LFA-3 expression on Burkitt's lymphoma cell lines. *J Immunol* 1989;143:1490-8.