

Expression of interleukin-6 by intestinal enterocytes

S C Jones, L K Trejdosiewicz, R E Banks, P D Howdle, A T R Axon, M F Dixon, J T Whicher

Abstract

Aims—To investigate the cellular source of the cytokine interleukin-6 (IL-6) in the small and large intestines of patients with inflammatory bowel disease, coeliac disease, and in controls.

Methods—IL-6 was detected in frozen sections of bowel by single and double label indirect immunofluorescence using rabbit polyclonal and murine monoclonal anti-IL-6 antibodies. The murine monoclonal antibodies RFDR1 (anti-MHC class II) and UCHT1 (anti-CD3) were used to localise macrophages and T lymphocytes, respectively. Lipopolysaccharide stimulated peripheral blood monocytes were used as positive control cells for IL-6 protein.

Results—IL-6 was demonstrated in the small and large intestine of patients with inflammatory bowel disease, coeliac disease, and in controls. The protein was present predominantly in enterocytes and colocytes in normal and inflamed mucosa, but not in the infiltrating inflammatory cells of the lamina propria. There were no discernable differences between patients with inflammatory bowel disease or coeliac disease and controls, nor between small and large bowel mucosa. Incubation of antibody with recombinant human IL-6 protein abolished the labelling. IL-6 protein was also present in lipopolysaccharide stimulated peripheral blood monocytes.

Conclusions—The data suggest that enterocytes and colocytes may play an active part in the immune response of the gut. The presence of IL-6 in both inflamed and non-inflamed small and large intestine requires further investigation into the function of this cytokine in the gut.

(J Clin Pathol 1993;46:1097-1110)

Interleukin-6 (IL-6) is considered to be a key cytokine mediator of the inflammatory response. Several studies have shown that patients with active inflammatory bowel disease, particularly those with Crohn's disease, have raised concentrations of IL-6 in the circulation.¹⁻⁴ There have been no such reports concerning patients with coeliac disease. We have shown that colonic biopsy specimens from patients with inflammatory bowel dis-

ease secrete significantly more IL-6 in vitro than those of control,⁵ and a recent report showed increased amounts of IL-6 mRNA in homogenised mucosa from patients with active inflammatory bowel disease.⁶

At present, the source of mucosally produced IL-6 is unclear: Shirota *et al*⁷ showed the immunolocalisation of IL-6 in small intestinal enterocytes, although they reported less expression in the epithelial cells of normal colonic mucosa. Stevens *et al*,⁸ however, identified infiltrating leukocytes as sources of IL-6 in inflammatory bowel disease. In this study we investigated the immunolocalisation of IL-6 in the small and large intestines of patients with inflammatory bowel disease and coeliac disease and in controls.

Methods

Mucosal samples from 45 patients were studied. Patients were recruited from the endoscopy lists, surgical lists, and colitis clinic of the Leeds General Infirmary and St James's University Hospital. All required endoscopic examination for clinical reasons and gave informed consent for additional biopsy specimens to be taken.

Colonic samples were taken from 10 patients with active ulcerative colitis and nine with active Crohn's disease. Inflammatory bowel disease had already been diagnosed on histological grounds and biopsy specimens were taken from macroscopically normal and abnormal areas. Biopsy specimens from the second part of duodenum were taken from six patients with coeliac disease (three untreated and three who had responded symptomatically and histologically to a gluten free diet). Control samples of the second part of duodenum, ileum, and colon were taken from 20 patients with histologically normal mucosa.

Biopsy specimens were embedded in OCT compound (Cellpath, Hemel Hempstead, Herts) and immediately snap frozen in thawing isopentane. Cryostat sections were fixed in acetone-methanol (1:1).

A rabbit anti-IL-6 antibody was prepared by immunisation with recombinant human IL-6 derived from *Escherichia coli* transfected with IL-6 gene (British Biotechnology). This antibody was specific for IL-6 by enzyme linked immunosorbent assay (ELISA) and shown to have IL-6 neutralising activity in bioassays using the IL-6 dependent B9 cell line.⁹ The antibody was used at a final dilution of 1 in 1000, determined by pre-titration. A mouse monoclonal anti-IL-6 antibody

Centre for Digestive Diseases, The General Infirmary, Leeds, LS1 3EX

S C Jones
A T R Axon
M F Dixon

Department of Clinical Medicine
Institute for Cancer Studies, St James's University Hospital, Leeds

L K Trejdosiewicz
R E Banks
J T Whicher

Correspondence to:
Dr S C Jones

Accepted for publication
1 June 1993

(α -BSF2-166, gift of T Hirano¹⁰ was also used on some sections for comparison purposes.

Single and double label immunofluorescence was performed, as described before.¹¹ Sections were incubated for one hour with either the rabbit or mouse monoclonal antibody, washed in phosphate buffered saline

(PBS) and incubated for a further hour with species specific goat anti-rabbit or anti-mouse IgG fluorescein isothiocyanate (FITC) or Texas Red conjugate (Sera-Lab Ltd, Crawley Down, Sussex) diluted in PBS containing normal goat serum. After a further wash, sections were visualised using a Zeiss Axioplan microscope fitted with epifluorescence illumination and selective filters. To localise macrophages and T lymphocytes, respectively, some sections were double labelled with the murine monoclonal antibodies RFDR1 (anti-MHC class II)² and UCHT1 (CD3), together with the rabbit anti-IL-6 antibody. Control sections in which the first antibody was omitted were performed for each section.

Absorption specificity controls were also performed: sections were incubated with the rabbit antibody premixed with recombinant IL-6 protein (20 μ g/ml) or with 1% bovine serum albumin as a control irrelevant protein.

Peripheral blood monocytes stimulated with lipopolysaccharide were used as a positive control for cytoplasmic IL-6 labelling with the rabbit polyclonal IL-6 antibody. Peripheral blood mononuclear cells were separated from the whole blood of a normal donor by density barrier centrifugation over "Lymphoprep" (Nycomed Pharma AS, Oslo, Norway). Monocytes were isolated by adhesion to glass slides and incubated for four, six or 24 hours with culture medium alone (RPMI 1640 supplemented with 10% fetal calf serum, penicillin 100 U/ml, and streptomycin 100 μ g/ml) or medium containing 10 μ g/ml lipopolysaccharide, before fixation. Double layer immunofluorescence was performed as described above using the rabbit polyclonal IL-6 antibody and RFDR1 antibodies to co-localise IL-6 and monocytes, respectively.

Results

All sections showed intense epithelial labelling for IL-6, irrespective of whether from small or large bowel. There was no difference in the intensity of the labelling between mucosa derived from small and large bowel, or between mucosa derived from inflamed and non-inflamed areas in patients with inflammatory bowel disease, from treated or untreated coeliac disease, or from control patients (figs 1 and 2).

The reactivity patterns of the monoclonal and polyclonal anti-IL-6 antibodies were similar, although the monoclonal antibody produced a less intense reaction. Both antibodies showed a cytoplasmic labelling pattern, with a stronger reaction in cell apices being apparent with the rabbit antibody. Any weak labelling observed in the lamina propria cells was comparable with background labelling in control sections. IL-6 was not specifically detected in T lymphocytes or macrophages which were labelled by the CD3 and HLA-DR antibodies, respectively (figs 1 and 2).

Labelling was also present in the cells of

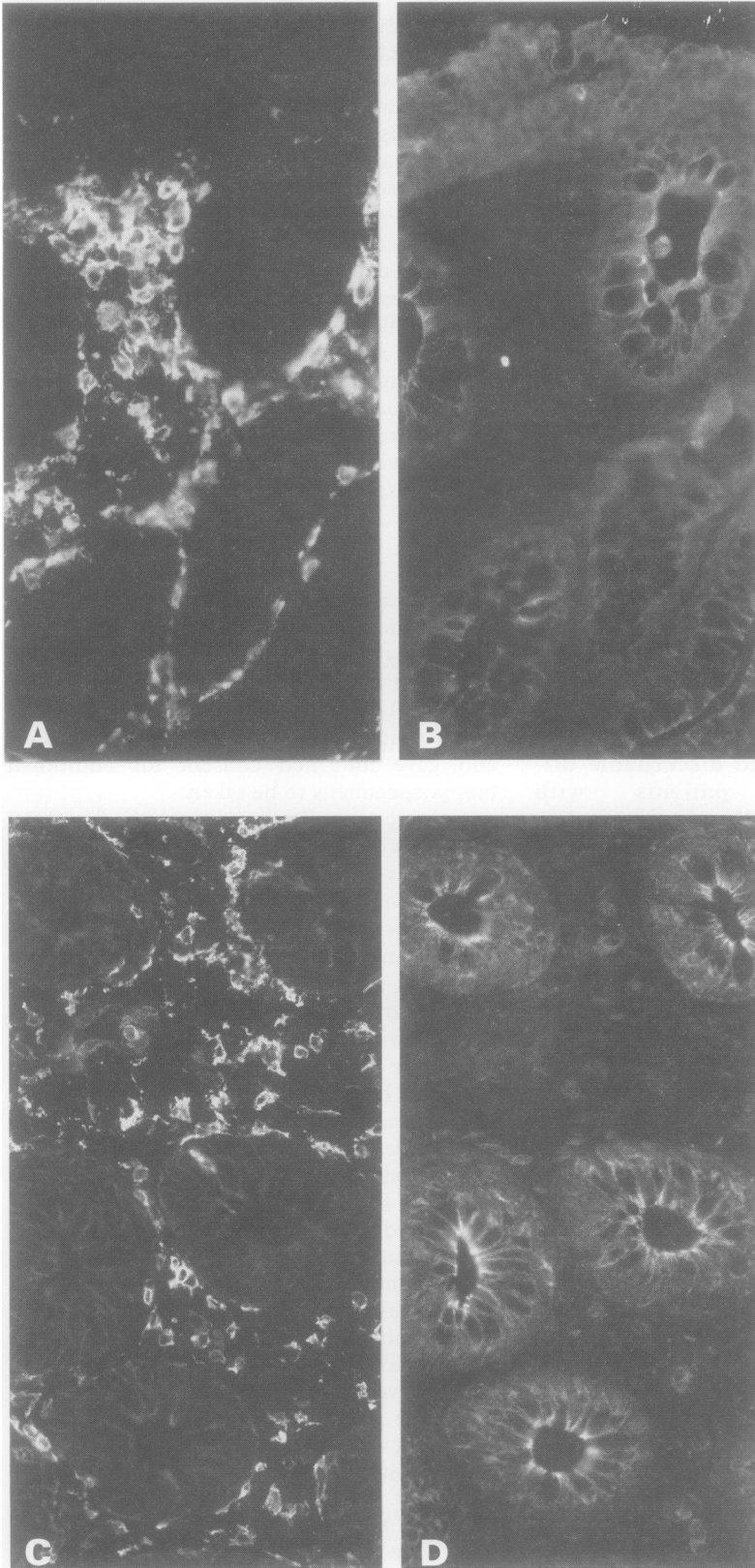


Figure 1 Paired double-label immunofluorescence with anti-HLADR (A), with anti-IL-6 (B), CD3 (C) and with anti-IL-6 (D).

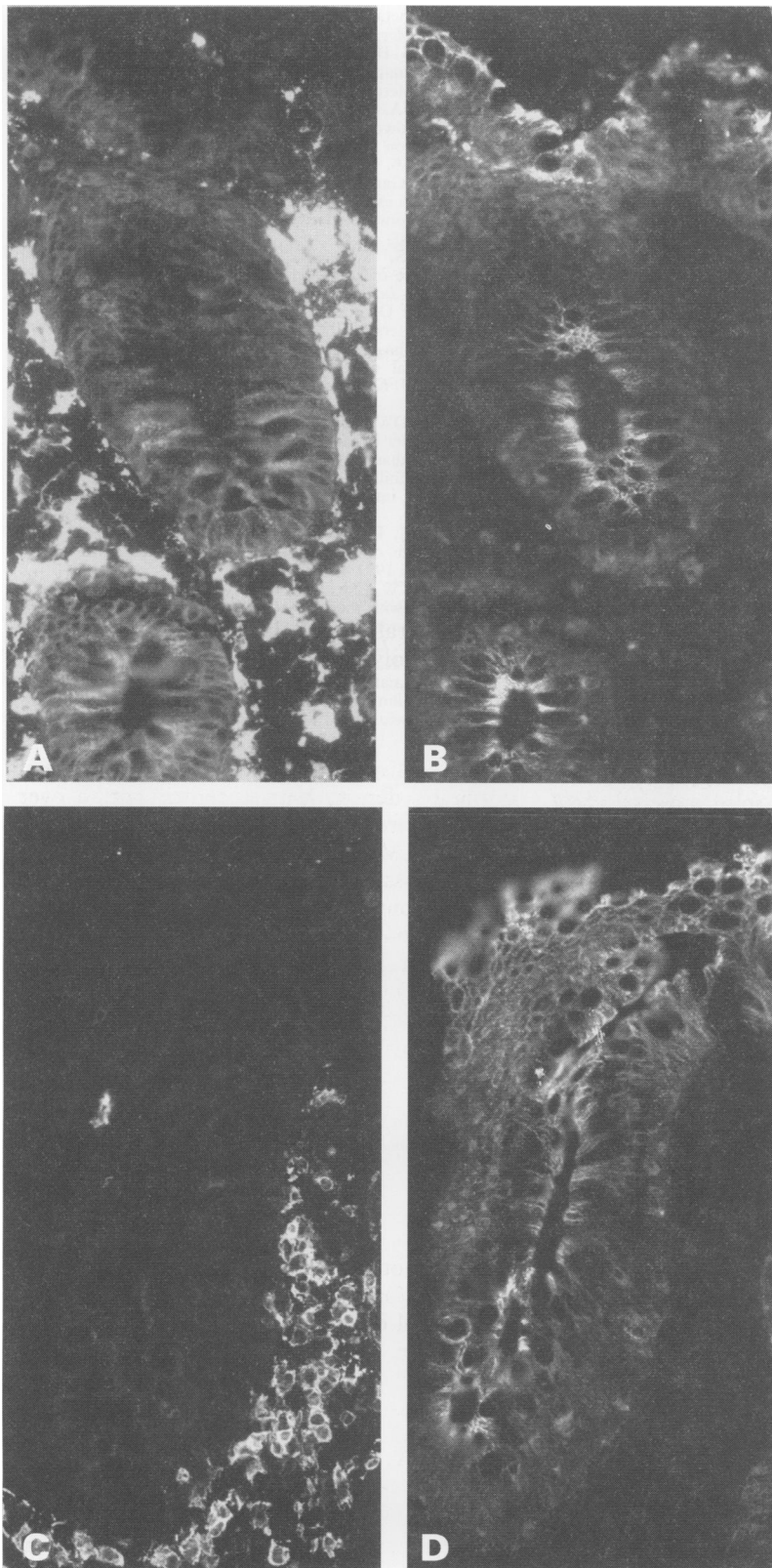


Figure 2 Colon of patient with active ulcerative colitis: strong HLADR expression can be seen by macrophages and other stromal cell types with weaker expression by enterocytes (A), which do not co-localise with IL-6 reactivity (B). Numerous lamina propria T cells (C) are not major expressors of IL-6 (D).

glands showing pyloric metaplasia, the so-called "ulcer associated cell lineage",¹³ which was present in a section of caecal Crohn's disease, but was considerably less intense than that seen in the surface epithelium.

Absorption of the rabbit IL-6 antibody with IL-6 completely abolished the labelling; bovine serum albumin had no effect.

Cytoplasmic labelling for IL-6 protein was present in stimulated monocytes after four and six hours' incubation, but not after 24 hours. The timing of IL-6 protein expression by monocytes which we observed is similar to that found in previous studies.¹⁴ Unstimulated monocytes showed very weak labelling for IL-6.

Discussion

This study shows that IL-6 protein is localised in small and large bowel enterocytes in both histologically normal mucosa and inflamed mucosa. The labelling was shown to be specific by complete abolition of immunofluorescence after absorption of the antibody with IL-6.

IL-6 may be synthesised elsewhere, but taken up by the epithelial cells, but an epithelial source for IL-6 is likely as several epithelial cell lines secrete IL-6 *in vitro*^{15,16} and the inflammatory cells did not contain it. The absence of IL-6 labelling in the inflammatory cells in patients with active inflammatory bowel disease was surprising in view of our previous observation that colonic mucosa from inflamed tissue secreted much greater amounts of IL-6 in culture than control mucosa, and secretion correlated with the degree of inflammatory cell infiltration.⁵ Mucosal macrophages and lymphocytes may secrete IL-6, but at a rate that does not permit cytoplasmic accumulation. The demonstration of cytoplasmic IL-6 in activated peripheral blood monocytes, however, suggests that its absence in macrophages in tissue sections is probably real. Another possibility is that the epithelium in inflamed mucosa secretes more IL-6 than normal mucosa, but this excessive secretion is not detected by immunolocalisation techniques. Increased IL-6 production previously shown in inflammatory bowel disease¹⁻⁵ may be due to stimulation of enterocytes by increased mucosal cytokine release from macrophages and lymphocytes. Such cytokines have been shown to upregulate IL-6 in epithelial cells *in vitro*,¹⁴ including intestinal epithelial cells.¹⁷

IL-6 affects the proliferation rate of several epithelial cell types¹⁸ and it may act as an autocrine growth factor for enterocytes. IL-6 secretion by normal epithelium may also have a role in inducing synthesis of IgA. IL-6 induces the rapid differentiation of sIgA⁺ memory cells into plasma cells in Peyer's patches¹⁹ and human appendix B cells naturally express receptors for, and respond to, IL-6 with selective IgA₁ and IgA₂ synthesis.²⁰ Enterocytes may play an important part in the immune response of the gut. Certainly the function of IL-6 in the normal small and large intestinal mucosa requires elucidation.

We thank Dr Eileen Ingham for collaboration in making the rabbit polyclonal anti-IL-6 antibody and Margaret Longfellow and Jane Oakes for their help in cutting sections. We acknowledge Professors PCL Beverley and G Janossy for the generous gifts of antibodies UCHT1 and RFDR1.

- 1 Mahida YR, Kurlac L, Gallagher A, Hawkey CJ. High circulating concentrations of interleukin-6 in active Crohn's disease but not ulcerative colitis. *Gut* 1991;32:1531-4.
- 2 Gross V, Andus T, Caesar I, Roth M, Scholmerich J. Evidence for continuous stimulation of interleukin-6 production in Crohn's disease. *Gastroenterology* 1992;102:514-9.
- 3 Lobo AJ, Evans SW, Jones SC, et al. Plasma interleukin-6 in inflammatory bowel disease. *Eur J Gastroenterol Hepatol* 1992;4:367-72.
- 4 Mitsuyama K, Sata M, Tanikawa K. Significance of interleukin-6 in patients with inflammatory bowel disease. *Gastroenterologica Japonica* 1991;26:20-8.
- 5 Jones SC, Haidar A, Crabtree JE, et al. Mucosal interleukin-6 production in inflammatory bowel disease. *Gut* 1992;33:S8.
- 6 Isaacs KL, Sartor RB, Haskill S. Cytokine messenger RNA profiles in inflammatory bowel disease mucosa detected by polymerase chain reaction amplification. *Gastroenterology* 1992;103:1587-95.
- 7 Shirota K, DeGuy L, Yuan S, Jothy S. Interleukin-6 and its receptor are expressed in human intestinal epithelial cells. *Virchows Arch (Cell Pathol)* 1990;58:303-8.
- 8 Stevens C, Walz G, Singaram C, et al. Tumour necrosis factor-alpha, interleukin-1-beta and interleukin-6 expression in inflammatory bowel disease. *Dig Dis Sci* 1992;37:818-26.
- 9 Helle M, Boeije L, Aarden LA. Functional discrimination between interleukin-6 and interleukin-1. *Eur J Immunol* 1988;18:1535-40.
- 10 Matsuda T, Hirano T, Kisimoto T. Establishment of an interleukin-6 (IL-6)/B cell stimulatory factor 2-dependent cell line and preparation of anti-IL-6 monoclonal antibodies. *Eur J Immunol* 1988;18:951-6.
- 11 Trejdosiewicz LK, Smart CJ, Oakes DJ, Howdle PD, Malizia G, Campana D, Boylston AW. Expression of T cell receptors TcR1 (gamma/delta) and TcR2 (alpha/beta) in the human intestinal mucosa. *Immunology* 1989;68:7-12.
- 12 Janossy G, Bofill M, Poulter LW, et al. Separate ontogeny of two macrophage-like accessory cell populations in the human fetus. *J Immunol* 1986;136:4354-61.
- 13 Wright NA, Pike C, Elia G. Induction of a novel epidermal growth factor-secreting cell lineage by mucosal ulceration in human gastrointestinal cells. *Nature* 1990;343:82-5.
- 14 Bauer J, Ganter U, Geiger T, et al. Regulation of interleukin-6 expression in cultured human blood monocytes and monocyte-derived macrophages. *Blood* 1988;72:1134-40.
- 15 Hedges S, Svensson M, Svanborg C. Interleukin-6 response of epithelial cell lines to bacterial stimulation in vitro. *Infect Immun* 1992;60:1295-301.
- 16 Cromwell O, Hamid Q, Corrigan CJ, et al. Expression and generation of interleukin-8, IL-6 and granulocyte-macrophage colony-stimulating factor by bronchial epithelial cells and enhancement by IL-1 beta and tumour necrosis factor-alpha. *Immunology* 1992;77:330-7.
- 17 McGee DW, Aicher WK, Eldridge JH, Peppard JV, Mestecky J, McGhee JR. Transforming growth factor-beta enhances secretory component and major histocompatibility complex class I antigen expression on rat IEC-6 intestinal epithelial cells. *Cytokine* 1991;3:543-50.
- 18 Krueger J, Ray A, Tamm I, Seghal P. Expression and function of interleukin-6 in epithelial cells. *J Cell Biochem* 1991;45:327-34.
- 19 Beagley KW, Eldridge JH, Aicher WK, et al. Peyer's patch B cells with memory cell characteristics undergo terminal differentiation within 24 hours in response to interleukin-6. *Cytokine* 1991;3:107-16.
- 20 Fujihashi K, McGhee JR, Lue C, et al. Human appendix B cells naturally express receptors for and respond to interleukin-6 with selective IgA1 and IgA2 synthesis. *J Clin Invest* 1991;88:248-52.