

Cytological changes preceding cervical cancer

J H Robertson, B Woodend, H Elliott

Abstract

Cervical smears were reviewed from 62 women who developed squamous carcinoma of the cervix up to 18 years later. The findings indicate that the prevention of cervical cancer by screening depends very largely on the detection of severe dyskaryosis. In this series there was no evidence that mild dyskaryosis was a forerunner of invasive disease. Cytology during the evolution of squamous carcinoma is not characterised by a dyskaryosis which progressively increases in severity. Instead the findings support new concepts that cervical cancer generally arises from an aggressive CIN 3 lesion widely present in the cervix, and in our series, established years before invasion occurs. It would be more useful to report cytology as showing either a low or high grade abnormality rather than distinguishing between different degrees of dyskaryosis.

(*J Clin Pathol* 1994;47:278-279)

Varied patterns of dyskaryosis are encountered during cervical cancer screening. The relation of these to squamous carcinoma of the cervix remains uncertain, this being especially so for mild dyskaryosis.¹ The uncertainty about mild dyskaryosis is compounded by the difficulty cytologists have in distinguishing it from the cellular changes of papillomavirus (HPV) infection.² The grading of dyskaryosis into mild, moderate, or severe suggests an epithelial lesion which progresses in severity, eventually resulting in

invasive disease. However, recent studies of cervical intraepithelial neoplasia (CIN), the histological counterpart of dyskaryosis, cast doubt on this concept of the evolution of cancer.¹

To investigate the relation between carcinoma and dyskaryosis we report a study based on 62 women with cervical cancer, describing the cytology of positive smears taken up to 18 years before diagnosis of the disease.

Methods

Most of these 62 patients had been given false negative smear reports by a number of laboratories at varying intervals before the development of carcinoma. The method of tracing the patients and their smears has been described before.³ The present study also includes patients who had positive smear reports but who were lost to follow up and later presented with invasive cancer. Only patients with fully invasive tumours were studied, microinvasive disease being excluded, as were smears taken less than one year before diagnosis. Some of the patients were found to have had more than one smear, but we describe here only the findings in the earliest smear showing any abnormality. Of the 62 patients, 60 had squamous and two adenosquamous carcinoma, their ages ranging from 27 to 74 years, 12 being less than 35 years of age at the time of diagnosis of the cancer.

Almost all of the smears were reviewed by the authors, the remainder by the original pathologist. Initially, they were examined by the first two authors (JHR, BW) independently to determine if dyskaryosis was present, and its degree. Evidence of papillomavirus infection was also noted. They were then re-examined, with control smears by the third author (HE) who at that time was unconnected with the study and unaware of the patients' histories. The final opinion was reached by consensus among the reviewers.

Results

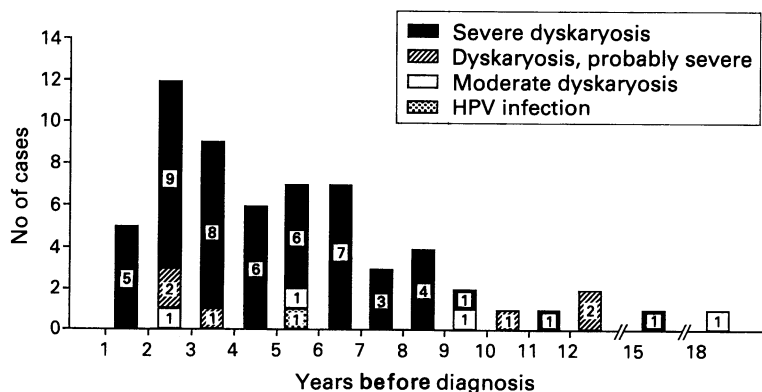
The figure illustrates the findings on review of the 62 smears taken from these patients at intervals over a period of 18 years before the diagnosis of carcinoma. In 51 of the smears there was unequivocal severe dyskaryosis even many years before the cancer was diagnosed. In six smears the dyskaryosis was more difficult to grade because fewer dyskaryotic

Department of
Cytopathology, Belfast
City Hospital, Belfast
BT9 7AD

J H Robertson
B Woodend
H Elliott

Correspondence to:
Dr J H Robertson

Accepted for publication
7 September 1993



Results of review of cervical smears from 62 patients who subsequently developed carcinoma of the cervix.

cells were present and interpretation was hindered by inflammatory changes. It was considered by the reviewers, however, that in each smear the dyskaryosis was probably severe. Dyskaryosis of moderate degree was present in the smears of four patients. No instance of mild dyskaryosis was found.

Only one smear showed the changes of HPV infection without associated dyskaryosis. In view of the current prevalence of HPV infection the smears were re-examined to determine whether evidence of it had been overlooked in the presence of dyskaryosis, but it could not be detected in any of the other smears.

Discussion

In these patients there was a predominance of severe dyskaryosis in smears taken up to 18 years before the diagnosis of carcinoma. In contrast, we found little or no evidence of HPV infection or mild dyskaryosis. As noted by others,⁴ it was difficult to compare our results with some previous studies because of variable nomenclature. Paterson *et al* (1984)⁵ described 34 smears taken up to eight years before a carcinoma as containing either malignant cells, cells suspicious of malignancy, or severe dyskaryosis. No mention was made of mild dyskaryosis or HPV infection. Stanbridge *et al* (1992)⁴ included in their study 43 smears taken up to 10 years before diagnosis of fully invasive carcinoma. Six showed mild dyskaryosis or evidence of HPV infection. These were all found in younger women, however, many of whom had smears taken while attending maternity clinics and at an age when these mild abnormalities are most common. Of those who developed carcinoma when over 40 years of age, all except one, whose dyskaryosis was difficult to grade, showed evidence of a high grade abnormality as in the Bethesda classification.⁶

Our study suggests that mild dyskaryosis in a cervical smear must be a very rare forerunner of invasive disease. The prevention of cervical cancer depends on the detection and

treatment of severe dyskaryosis and, to a lesser extent, of moderate dyskaryosis. The predominance of severe dyskaryosis even in smears taken many years before the cancer develops is also difficult to reconcile with CIN lesions which gradually progress in severity. This correlates with recent histological studies which have found that severely dyskaryotic smears are associated with extensive CIN 3 lesions in the cervix. It was found that squamous carcinoma arises from these rather than from the smaller CIN 3 lesions which are sometimes associated with mildly dyskaryotic smears.¹⁷ It was considered that these pre-cancers arise not from progression of low grade CIN, but from expansion of a high grade lesion. Our cytological findings are in keeping with the evolution of squamous carcinoma in this manner. They suggest that the phase of expansion of aggressive CIN lesions often occurs many years before invasive disease arises. If these findings are confirmed it would be more logical to report cervical smear abnormalities as being either of low or high grade as in the Bethesda system,⁶ rather than to distinguish between different degrees of dyskaryosis and HPV infection as is the current practice.

We are grateful to all the pathologists who submitted or reviewed cervical smears for this study.

- 1 Tidbury P, Singer A, Jenkins D. CIN 3: The role of lesion size in invasion. *Br J Obstet Gynaecol* 1992;99:583-6.
- 2 Richart RM, Wright TC. Controversies in the management of low-grade cervical intraepithelial neoplasia. *Cancer* 1993;71:1413-20.
- 3 Robertson JH, Woodend B. Negative cytology preceding cervical cancer: causes and prevention. *J Clin Pathol* 1994;47:700-2.
- 4 Stanbridge CM, Suleman BA, Persad RV, El-Khatib S. A cervical smear review in women developing cervical carcinoma with particular reference to age, false negative cytology and the histologic type of the carcinoma. *Int J Gynecol Cancer* 1992;2:92-100.
- 5 Paterson MEL, Peel KR, Joslin CAF. Cervical smear histories of 500 women with invasive cervical cancer in Yorkshire. *Br Med J* 1984;289:896-8.
- 6 National Cancer Institute Workshop, Bethesda (1989). The 1988 Bethesda system for reporting cervical/vaginal diagnoses. *Acta Cytol* 1989;33:567-71.
- 7 Jarmulowicz MR, Jenkins D, Barton SE, Goodall AL, Hollingworth A, Singer A. Cytological status and lesion size: a further dimension in cervical neoplasia. *Br J Obstet Gynaecol* 1989;96:1061-6.