

## c-erbB-2 overexpression in the dysplasia/carcinoma sequence of Barrett's oesophagus

R H Hardwick, N A Shepherd, M Moorghen, P V Newcomb, D Alderson

### Abstract

**Aims**—To investigate overexpression of the oncoprotein c-erbB-2 in the dysplasia/carcinoma sequence of Barrett's columnar-lined oesophagus (CLO).

**Methods**—Immunohistochemical staining was performed using the monoclonal antibody NCL-CB-11 on formalin fixed tissue from 31 cases of Barrett's carcinoma, 20 cases of cancer associated dysplastic CLO, seven cases of dysplastic CLO without cancer, and 20 cases of non-dysplastic CLO. Membranous staining was regarded as positive for c-erbB-2 overexpression; cytoplasmic staining was recorded separately as its significance is uncertain.

**Results**—Membranous c-erbB-2 overexpression was observed in eight of 31 (26%) carcinomas and in none of the cases of dysplastic CLO. Variable cytoplasmic staining was seen in four of 31 (13%) tumours and seven of 27 (26%) cases of dysplastic CLO. No staining was observed in non-dysplastic CLO.

**Conclusions**—C-erbB-2 overexpression is a relatively late event in the development of some Barrett's carcinomas and is unlikely to be involved in the early stages of neoplastic transformation of CLO.

(J Clin Pathol 1995;48:129-132)

Keywords: Barrett's oesophagus, adenocarcinoma, c-erbB-2.

Patients with Barrett's columnar-lined oesophagus (CLO) are at increased risk of developing oesophageal adenocarcinoma, although the exact degree of risk is still uncertain.<sup>1-3</sup> The incidence of oesophageal and gastro-oesophageal junctional adenocarcinoma is rising in some countries<sup>4,5</sup> and most of these tumours arise in CLO.<sup>6</sup> There is strong evidence for a dysplasia/carcinoma sequence in CLO, with invasive tumours arising in areas of high grade dysplasia.<sup>7,8</sup>

C-erbB-2 is a 185 kilodalton, type 1 growth factor receptor, with many similarities to the epidermal growth factor receptor (EGFr).<sup>9,10</sup> A transmembrane region connects the glycosylated extracellular domain with an intracellular domain which has inherent tyrosine kinase activity. C-erbB-2 is expressed by normal gastrointestinal epithelial cells<sup>11</sup> and has multiple ligands, including Neu-differentiating factor and heregulin.<sup>12,13</sup> Overexpression of c-erbB-2 in human and rodent cell lines is associated with neoplastic transformation<sup>14,15</sup> and has been detected in various types of

human adenocarcinomas.<sup>16</sup> In rats the oncogenic properties of c-erbB-2 seem to be principally related to point mutations<sup>17</sup> whereas in humans these are caused by overexpression, frequently, but not necessarily, as a result of gene amplification.<sup>18,19</sup> This overexpression is predominantly membranous and although cytoplasmic staining has been observed its significance is less certain.<sup>20,21</sup> C-erbB-2 overexpression can be detected immunohistochemically with antibodies such as NCL-CB-11, a mouse monoclonal antibody raised against an epitope at the C terminus of the internal domain.<sup>22</sup> This can be used on routinely fixed archival tissue, although sensitivity may be reduced compared with optimally fixed or frozen tissue.<sup>22,23</sup>

The importance of c-erbB-2 overexpression in the aetiology of oesophageal adenocarcinoma and in particular the neoplastic transformation of CLO remains unclear. Some studies suggest that it is a frequent and early event,<sup>24,25</sup> while others show it to be much less common and relatively late.<sup>26</sup> To investigate further the correlation between c-erbB-2 expression in Barrett's carcinoma and associated CLO, an immunohistochemical study of c-erbB-2 expression was undertaken in patients with non-dysplastic and dysplastic CLO, and with Barrett's adenocarcinoma.

### Methods

Thirty one patients with oesophageal adenocarcinoma arising in Barrett's oesophagus (mean age 68 years; M:F ratio 23:8) were identified from the Histopathology computer records of The Bristol Royal Infirmary, Gloucestershire Royal Hospital, and Frenchay Hospital. These were defined as adenocarcinomas arising in the tubular oesophagus associated with specialised intestinal-type Barrett's mucosa.<sup>27</sup> Tumour differentiation was as follows: good in four patients, moderate in 15, poor in 11, and signet ring in one. Staging data were not available for all patients as only 22 of 31 had had an oesophagectomy, but as expected, most of these had stage III disease (only two of 22 had T1/T2 lesions). Sections stained with haematoxylin and eosin were graded for dysplasia<sup>28,29</sup> by two consultant histopathologists (NAS and MM) independently, with consensus scoring for those sections about which there was initial disagreement.

Twenty patients had dysplastic Barrett's mucosa adjacent to their tumour. This comprised a mixture of high and low grade dysplasia in nine, high grade dysplasia in a further nine, and low grade dysplasia in two. Patients with

University  
Department of  
Surgery, Bristol Royal  
Infirmary, Bristol  
BS2 8HW  
R H Hardwick  
P V Newcomb  
D Alderson

University  
Department of  
Pathology  
M Moorghen

Department of  
Histopathology, Royal  
Gloucestershire Royal  
Hospital, Gloucester  
N A Shepherd

Correspondence to:  
Mr R H Hardwick,  
3 Orchard Close,  
Woodbury,  
Exeter EX5 1ND.

Accepted for publication  
7 June 1994

Table 1 NCL-CB-11 immunoreactivity in Barrett's oesophagus

Immunoreactivity	Barrett's adenocarcinoma	Cancer associated dysplastic CLO	Dysplastic CLO without cancer	Non-dysplastic CLO
Membranous	8	0	0	0
Cytoplasmic	4	3 HGD	1 HGD&LGD <10%	0
		2 LGD	1 LGD	
None	19	15	5	20
Total	31	20	7	20

HGD = high grade dysplasia; LGD = low grade dysplasia.

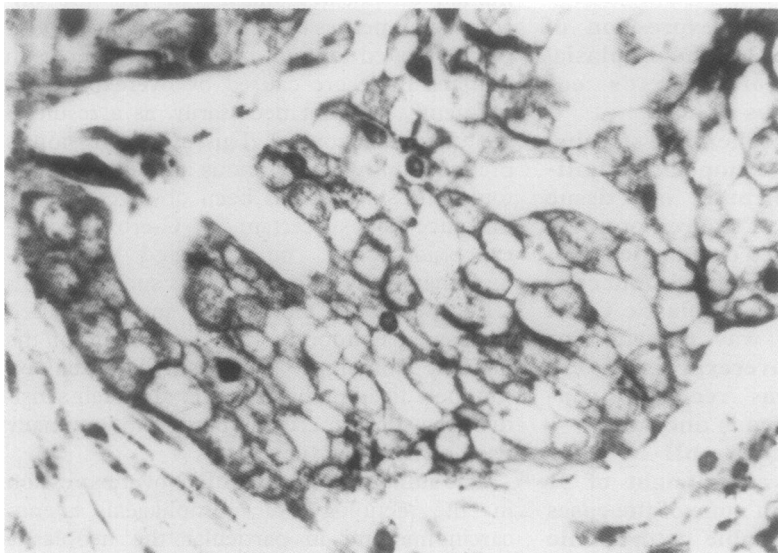


Figure 1 NCL-CB-11 staining of Barrett's adenocarcinoma showing predominantly membranous c-erbB-2 overexpression (original magnification  $\times 1000$ ).

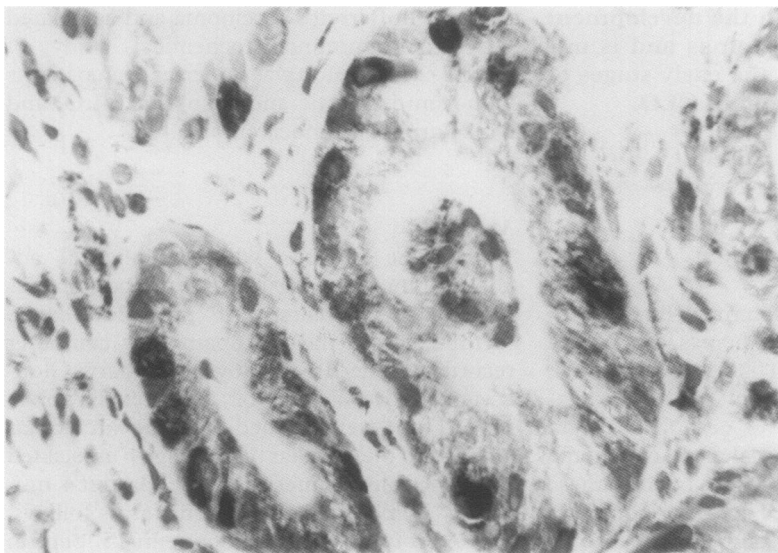


Figure 2 Variable cytoplasmic NCL-CB-11 staining in Barrett's oesophagus with high grade dysplasia (original magnification  $\times 1000$ ).

Table 2 Correlation between NCL-CB-11 immunoreactivity of Barrett's carcinoma and cancer associated dysplastic CLO. It should be noted that only two of four cytoplasmic and four of eight membranous staining carcinomas had associated dysplastic CLO

Immunoreactivity of Barrett's cancer	n	Immunoreactivity of cancer associated dysplastic CLO		
		Membranous	Cytoplasmic	None
Membranous	8	0	1 HGD	2 HGD/1 LGD
Cytoplasmic	4	0	1 HGD/1 LGD	0
None	19	0	1 HGD/1 LGD	12
Total	31	0	3 HGD/2 LGD	15

HGD = high grade dysplasia; LGD = low grade dysplasia.

Barrett's oesophagus without carcinoma involved in a prospective endoscopic surveillance programme were also investigated. They included 20 patients with non-dysplastic CLO (mean age 62 years; M:F ratio 14:6) and seven (mean age 59 years; M:F ratio 6:1) with dysplastic CLO (two with high and low grade dysplasia, one with high grade dysplasia and four with low grade dysplasia). All patients had specialised intestinal-type Barrett's mucosa.

#### IMMUNOHISTOCHEMISTRY

Formalin fixed, paraffin wax embedded tissue sections (5  $\mu$ m) were cut and dewaxed in Histoclear (Cell Path, Hemel Hempstead, UK) before rehydration in graded alcohols. Sections were treated with 3% hydrogen peroxide in water for five minutes before being washed in TRIS buffered saline (TBS). Normal rabbit serum (Dako, High Wycombe, UK) was applied at a dilution of 1 in 5 for 20 minutes to block non-specific antigens and the monoclonal antibody NCL-CB-11 (Novacastra, Newcastle upon Tyne, UK), diluted 1 in 40, was applied for one hour at room temperature. After washing in TBS, biotinylated rabbit antimouse antibody (Dako), diluted 1 in 500, was applied for 30 minutes. Further washing in TBS was followed by the application of avidin-biotin complex (Dako) for 30 minutes before a final TBS wash and visualisation of bound antibody with 3,3 diaminobenzene (0.6 mg/ml) for 10 minutes. A light haematoxylin counterstain was applied before dehydration in graded alcohols. Positive and negative controls were stained with each batch of slides, comprising c-erbB-2 overexpressing breast tissue processed with and without the primary antibody.

Staining was reviewed independently on two separate occasions by two of the authors (RHH and PVN) and a semiquantitative assessment of membranous staining made. Sections were considered to overexpress c-erbB-2 if at least 10% of cells showed unequivocal membranous staining. Staining intensity varied slightly between batches and no formal assessment was attempted. Cytoplasmic staining was recorded separately and not considered to be positive for c-erbB-2 overexpression.

#### Results

Eight of 31 (26%) carcinomas showed membranous c-erbB-2 overexpression (table 1). Figure 1 shows an example of widespread membranous c-erbB-2 overexpression in biopsy material from a Barrett's carcinoma. When present, heterogeneous membranous staining was typically observed in at least 50% of cells. Of these c-erbB-2 positive tumours, differentiation was good in one, moderate in five, and poor in two. Four of the eight c-erbB-2 positive tumours had areas of associated dysplastic CLO (two with high grade dysplasia, one with low grade dysplasia, one with high and low grade dysplasia); none of these demonstrated membranous c-erbB-2 staining. No membranous staining was seen in any cancer associated dysplastic CLO. One area of high

grade dysplasia adjacent to a c-erbB-2 positive tumour, however, did show cytoplasmic staining. Four tumours showed cytoplasmic staining, two of which had adjacent dysplastic CLO (one with high and one with low grade dysplasia); both of these also showed cytoplasmic staining (fig 2). Of the remaining cases of cancer associated dysplastic CLO, two (one with high and one with low grade dysplasia) showed cytoplasmic c-erbB-2 over-expression. Table 2 summarises the association between NCL-CB-11 staining of Barrett's carcinomas and cancer associated dysplastic CLO.

#### DYSPLASTIC AND NON-DYSPLASTIC CLO

None of the seven patients with dysplastic CLO without cancer showed membranous c-erbB-2 overexpression. One had less than 10% focal staining in both the low and high grade dysplasia and another had widespread cytoplasmic staining in low grade dysplasia. The latter patient had biopsy specimens taken two years before and one year after those showing cytoplasmic staining; both of these contained low grade dysplasia but lacked cytoplasmic or membranous NCL-CB-11 staining. None of the biopsy specimens from 20 patients with non-dysplastic CLO without cancer showed membranous or cytoplasmic staining.

#### INTER- AND INTRA-OBSERVER VARIATION

To quantitate interobserver variation, initial scores given to each of 100 consecutive sections by the two observers were compared. Four slides were scored differently, giving an interobserver variation of 4%. Each observer reviewed the first 50 slides twice to assess intraobserver variation. The first observer changed the score of two slides and the second of one slide, giving an intraobserver variation of 4 and 2%, respectively.

#### Discussion

The prevalence of c-erbB-2 overexpression in this group of patients with Barrett's adenocarcinoma was 26% (eight of 33), higher than the 11% (seven of 66) reported by Flejou *et al*<sup>26</sup> but considerably lower than the 73% (11 of 15) and 60% (six of 10) found by Jankowski *et al*<sup>24</sup> and Al-Kasspoles *et al*,<sup>25</sup> respectively. As in the study by Flejou *et al*,<sup>26</sup> no membranous overexpression was seen in this study in dysplastic or non-dysplastic CLO. This is in contrast to Jankowski *et al*,<sup>24</sup> who found weak membranous c-erbB-2 expression in 60% (nine of 15) of cases of CLO (one with "mild dysplasia"), and Al-Kasspoles *et al*,<sup>25</sup> who demonstrated "moderate overexpression" in three cases of non-dysplastic CLO, but not in a fourth "dysplastic" case. The most likely explanations for these differences are the greater sensitivity of c-erbB-2 detection in frozen tissue compared with fixed archival material<sup>23</sup> and perhaps the greater concentration of primary antibody used<sup>24</sup> (1 in 5 *v* 1 in 20 in this study). C-erbB-2 expression in CLO is not unexpected as this receptor is widely expressed by other epithelial

cells of the gastrointestinal tract.<sup>11</sup> The crucial question is whether the increased sensitivity of immunohistochemistry on frozen tissue results in the detection of pathological levels of c-erbB-2 immunoreactivity (that is, overexpression), or simply demonstrates physiological levels of the receptor in these tissues. Paradoxically, studies of c-erbB-2 immunoreactivity on fixed rather than frozen tissue may actually give a more accurate representation of pathological receptor overexpression because of their higher threshold for positivity. If this is true, the lack of membranous c-erbB-2 immunoreactivity in dysplastic CLO in this and the study by Flejou *et al*<sup>26</sup> suggests that c-erbB-2 overexpression is unlikely to be involved in the early stages of neoplastic transformation of CLO. To answer this question definitively, however, c-erbB-2 protein concentrations must be quantified in dysplastic and non-dysplastic CLO. This cannot be achieved using immunohistochemistry.

Similar observations concerning c-erbB-2 expression in dysplasia have been made in other tissues. Kamel *et al*,<sup>30</sup> studying gall bladder carcinoma, found c-erbB-2 overexpression in 10% of tumours, but not in adjacent dysplastic mucosa. In bladder Coombs *et al*<sup>21</sup> found no c-erbB-2 immunoreactivity in areas of high grade dysplasia or carcinoma *in situ*. D'Emilia *et al*<sup>31</sup> have studied c-erbB-2 expression in the adenoma/carcinoma sequence of the colon, a system that might be expected to share some similarities with the dysplasia/carcinoma sequence of Barrett's oesophagus. They found membranous immunoreactivity in 20% of colon carcinomas, 62% of adenomas, and in non-neoplastic mucosa adjacent to tumours and adenomas.

There is uncertainty as to the significance of cytoplasmic c-erbB-2 staining. An immunoreactive cytoplasmic protein with a molecular weight of 155 kilodaltons (30 kilodaltons smaller than c-erbB-2) has been identified, but it is unclear whether this is a c-erbB-2 precursor molecule<sup>19</sup> or a mitochondrial membrane protein.<sup>32</sup> Ohguri *et al*<sup>33</sup> found only a 185 kilodalton immunoreactive protein in the cytoplasm of gastric cancer cells, suggesting that c-erbB-2 itself can be found in this location. Immunoblotting studies in bladder cancer have shown an association in some tumours between overexpression of both the 185 and 155 kilodalton proteins and c-erbB-2 gene amplification.<sup>21</sup> In view of the uncertain significance of cytoplasmic c-erbB-2 immunoreactivity, we have scored only membranous staining as representative of c-erbB-2 overexpression. If, however, cytoplasmic staining was to be included in the c-erbB-2 positive group, the number of positive tumours would rise from 26 to 39% and only three of these would have c-erbB-2 positive dysplastic CLO associated with them. This would not, therefore, fundamentally change the overall conclusions of this study.

Although c-erbB-2 overexpression appears to have no potential as a marker in dysplastic CLO, it may identify patients with Barrett's adenocarcinoma who have a particularly aggressive tumour.<sup>26</sup> In gastric carcinoma the

prognostic significance of c-erbB-2 expression is less certain.<sup>33-35</sup> In breast cancer it has been known for some time that c-erbB-2 is an independent marker of poor prognosis.<sup>18 36 37</sup>

In conclusion, membranous c-erbB-2 overexpression was found in eight of 31 Barrett's adenocarcinomas, but in none of 27 areas of dysplastic CLO, 20 of which were associated with Barrett's carcinoma. When present, c-erbB-2 overexpression appears to be a late event in the dysplasia/carcinoma sequence of Barrett's oesophagus, although further confirmation of this observation is needed in light of the discrepancies between studies using frozen versus fixed tissue. Unlike p53, which is overexpressed in CLO associated high grade dysplasia,<sup>38 39</sup> and which may have prognostic significance,<sup>40</sup> c-erbB-2 does not appear to have any potential role in identifying patients at risk of developing oesophageal carcinoma.

The authors are grateful to MWL Gear, SP Wilkinson, and CP Armstrong for their assistance with this study. RH Hardwick is supported by the Carey Coombs Research Fellowship.

- Spechler SJ, Robbins AH, Rubins HB, Vincent ME, Heeren T, Doos WG, *et al.* Adenocarcinoma and Barrett's esophagus. An overrated risk? *Gastroenterology* 1984;87:927-33.
- Spechler SJ. Endoscopic surveillance for patients with Barrett's esophagus: Does the cancer risk justify the practice? *Ann Intern Med* 1987;106:902-4.
- Hameeteman W, Tytgat GNJ, Houthoff HJ, Van Den Tweel JG. Barrett's oesophagus: development of dysplasia and adenocarcinoma. *Gastroenterology* 1989;96:1249-56.
- Blot WJ, Devesa SS, Kneller RW, Fraumani JF. Rising incidence of adenocarcinoma of the esophagus and gastric cardia. *JAMA* 1991;265:1287-9.
- Pera M, Cameron AJ, Trastek VF, Carpenter HA, Zinsmeister AR. Increasing incidence of adenocarcinoma of the esophagus and esophagogastric junction. *Gastroenterology* 1993;104:510-13.
- Hamilton SR, Smith RRL, Cameron JL. Prevalence and characteristics of Barrett's esophagus in patients with adenocarcinoma of the esophagus or esophagogastric junction. *Hum Pathol* 1988;19:942-8.
- Tytgat GNJ, Hameeteman W. The neoplastic potential of columnar-lined (Barrett's) esophagus. *World J Surg* 1992;16:308-12.
- Miros M, Kerlin P, Walker N. Only patients with dysplasia progress to adenocarcinoma in Barrett's oesophagus. *Gut* 1991;32:1441-66.
- Schechter AL, Stern DF, Validyanthan L, Decker SJ, Drebin JA, Greene MI, *et al.* The neu oncogene: an erb-B-regulated gene encoding a 185,000-Mw tumour antigen. *Nature* 1984;312:513-16.
- Akiyama T, Sudo C, Ogawara H, Toyoshima K, Yamamoto T. The product of the c-erbB-2 gene: a 185-kilodalton glycoprotein with tyrosine kinase activity. *Science* 1986;232:1644-6.
- Cohen JA, Weiner DB, More KF, Kokai Y, Williams WV, Maguire HC Jr, *et al.* Expression pattern of the neu (NGL) gene-encoded growth factor receptor protein (p185neu) in normal and transformed epithelial tissues of the digestive tract. *Oncogene* 1989;4:81-8.
- Wen D, Peles E, Cupples R, Suggs SV, Bacus SS, Luo Y, *et al.* Neu-differentiating factor: a transmembrane glycoprotein containing an EGF domain and an immunoglobulin homology unit. *Cell* 1992;69:559-72.
- Holmes WE, Sliwkowski MX, Akita RW, Henzel WJ, Lee J, Park JW, *et al.* Identification of heregulin, a specific activator of p185<sup>erbB2</sup>. *Science* 1992;256:1205-10.
- Pierce JH, Arnstein P, DiMarco E, Artrip J, Kraus MH, Lonardo F, *et al.* Oncogenic potential of erbB-2 in human mammary epithelial cells. *Oncogene* 1993;6:1189-94.
- Di Fiore PP, Pierce JH, Kraus MH, Segatto O, King CR, Aaronson SA. erbB-2 is a potent oncogene when overexpressed in NIH/3T3 cells. *Science* 1987;237:178-82.
- Yokota J, Yamamoto T, Toyoshima K, Terada M, Sugimura T, Battifora H, *et al.* Amplification of c-erbB-2 oncogene in human adenocarcinoma in vivo. *Lancet* 1986;i:765-7.
- Bargmann CI, Hung MC, Wenberg RA. Multiple independent activations of the neu oncogene by a point mutation altering the transmembrane domain of p185. *Cell* 1986;45:649-57.
- Slamon DJ, Clark GM, Wong SG, Levin WJ, Ullrich A, McGuire WL. Human breast cancer: correlation of relapse and survival with amplification of the HER-2/neu oncogene. *Science* 1987;235:177-82.
- Coombs LM, Pigott DA, Sweeney E, Proctor AJ, Eydmann ME, Parkinson C, *et al.* Amplification and over-expression of c-erbB-2 in transitional cell carcinoma of the urinary bladder. *Br J Cancer* 1991;63:601-8.
- Gusterson BA, Gullick WJ, Venter DJ, Powles TJ, Elliott C, Ashley S, *et al.* Immunolocalisation of c-erbB-2 in human breast carcinomas. *Mol Cell Probes* 1988;2:283-91.
- Coombs LM, Oliver S, Sweeney E, Knowles M. Immunocytochemical localization of c-erbB-2 protein in transitional cell carcinoma of the urinary bladder. *J Pathol* 1993;169:35-42.
- Corbett IP, Henry JA, Angus B, Watchorn CJ, Wilkinson L, Hennessy C, *et al.* NCL-CB11, a new monoclonal antibody recognizing the internal domain of the c-erbB-2 oncogene protein effective for use on formalin-fixed, paraffin-embedded tissue. *J Pathol* 1990;161:15-25.
- Chiu KY, Loke SL, Ho FCS. Immunohistochemical demonstration of c-erbB-2 oncoprotein in gastric adenocarcinoma: Comparison of cryostat and paraffin wax sections and effect of fixation. *J Clin Pathol* 1994;47:117-21.
- Jankowski J, Coghill G, Hopwood D, Wormsley KG. Oncogenes and onco-suppressor genes in adenocarcinoma of the oesophagus. *Gut* 1992;33:1033-8.
- Al-Kasspoles M, Moore JH, Orringer MB, Beer DG. Amplification and over-expression of the EGFR and erbB-2 genes in human esophageal adenocarcinoma. *Int J Cancer* 1993;54:213-19.
- Flejou J-F, Paraf F, Fekete F, Henin D, Jothy S, Potet F. Expression of c-erbB-2 oncogene product in Barrett's adenocarcinoma: Pathological and prognostic correlations. *J Clin Pathol* 1994;47:23-6.
- Spechler S, Goyal R. Barrett's oesophagus. *N Engl J Med* 1986;6:362-71.
- Riddell RH, Goldman H, Ransohoff DF, Appelman HD, Fenoglio CM, Haggitt RC, *et al.* Dysplasia in inflammatory bowel disease: standardized classification with provisional clinical applications. *Hum Pathol* 1983;14:931-68.
- Riddell RH. Dysplasia and regression in Barrett's epithelium. In: Spechler SJ, Goyal RK, eds. *Barrett's esophagus: pathophysiology, diagnosis and management*. New York: Elsevier, 1985:143-52.
- Kamel D, Paakko P, Nuorva K, Vahakangas K, Soini Y. p53 and c-erbB-2 protein expression in adenocarcinoma and epithelial dysplasia of the gall bladder. *J Pathol* 1993;179:67-72.
- D'Emilia J, Bulovas K, D'Ercole K, Wolf B, Steele G, Summerhayes IC. Expression of the c-erbB-2 gene product (p185) at different stages of neoplastic progression in the colon. *Oncogene* 1989;4:1233-9.
- De Potter CR, Quatacker J, Maertens G, Van Daele S, Pauwels C, Verhofstede C, *et al.* The subcellular localization of the neu protein in human normal and neoplastic cells. *Int J Cancer* 1989;44:969-74.
- Ohguri T, Sato Y, Koizumi W, Saigenji K, Kameya T. An immunohistochemical study of c-erbB-2 protein in gastric carcinomas and lymph-node metastases: is the c-erbB-2 protein really a prognostic indicator? *Int J Cancer* 1993;53:75-9.
- Yonemura Y, Ninomiya I, Ohoyama S, Kimura H, Yamaguchi A, Fushida S, *et al.* Expression of c-erbB-2 oncoprotein in gastric carcinoma. Immunoreactivity for c-erbB-2 protein is an independent indicator of poor short-term prognosis in patients with gastric carcinoma. *Cancer* 1991;67:2914-18.
- Jain S, Filipe MI, Gullick WJ, Linehan J, Morris RW. c-erbB-2 proto-oncogene expression and its relationship to survival in gastric carcinoma: an immunohistochemical study on archival material. *Int J Cancer* 1991;48:668-71.
- Gullick WJ, Love SB, Wright C, Barnes DM, Gusterson B, Harris AL, *et al.* c-erbB-2 protein overexpression in breast cancer is a risk factor in patients with involved and uninvolved lymph nodes. *Br J Cancer* 1991;63:434-8.
- Dykens R, Corbett IP, Henry JA, Wright C, Yuan J, Hennessy C, *et al.* Long-term survival in breast cancer related to overexpression of the c-erbB-2 oncoprotein: an immunohistochemical study using monoclonal antibody NCL-CB11. *J Pathol* 1991;163:1-6.
- Hardwick RH, Shepherd NA, Moorghen M, Newcomb PV, Alderson D. Adenocarcinoma arising in Barrett's oesophagus: evidence for involvement of p53 dysfunction in the dysplasia/carcinoma sequence. *Gut* 1994;35:764-8.
- Ramel S, Reid BJ, Sanchez CA, Blount PL, Levine DS, Neshat K, *et al.* Evaluation of p53 protein expression in Barrett's esophagus by two-parameter flow cytometry. *Gastroenterology* 1992;102:1220-8.
- Younes M, Lebovitz RM, Lechago LV, Lechago J. p53 protein accumulation in Barrett's metaplasia, dysplasia and carcinoma: A follow-up study. *Gastroenterology* 1993;105:1637-42.