

# Incidence of thin membrane nephropathy: morphometric investigation of a population sample

F E Dische, V E R Anderson, S J Keane, D Taube, M Bewick, V Parsons

### Abstract

To explore the incidence of thin membrane nephropathy (thin basement membrane syndrome, benign familial haematuria), glomerular basement membrane thickness was assessed by light and electron microscopy and by morphometry in a series of newly transplanted allograft kidneys, in lieu of normal kidney specimens. Five of the 76 donors possessed an abnormally thin basement membrane, similar to that observed in thin membrane nephropathy, while in two others the measurements fell in the overlap range between thin and normal. Seven donors therefore had a definite or possible basement membrane lesion. After taking account of an additional series of controls, unrelated to transplantation, it is suggested that the incidence of this abnormality in the general population lies between 5.2% and 9.2%. Circumstances did not allow any association between a thin basement membrane and haematuria or other clinical manifestations to be detected.

of isolated haematuria or haematuria with proteinuria in adults,<sup>3-13</sup> with impairment of renal function in a small minority of patients.<sup>3</sup> Electron microscopical examination is necessary for the diagnosis, which may explain why TMN is identified rather infrequently, whereas epidemiological studies suggest that as a cause of microscopic haematuria it is common, ranking with IgA nephropathy.<sup>12,13</sup> Our own experience makes us believe that TMN occurs even more often than this.

The aim of this investigation was to explore the absolute incidence of the lesion in the population, using the measured mean thickness as a yardstick. Lacking access to an adequate number of ideally normal kidney specimens, we used a series of newly transplanted allografts as a representative sample.

### Methods

Needle biopsy at Dulwich Hospital of the donor kidney is carried out as a routine investigation during transplantation. Biopsy samples taken between 1985-9 were used, provided there were sufficient clinical data as well as technically satisfactory resin embedded tissue. With few exceptions, the kidneys were taken from donors among the population of South East England, and their clinical details are outlined in table 1. Nearly all were cadaveric donors. Mean blood pressures recorded in those dying of cerebrovascular accident were significantly higher than those in all the other groups combined ( $p < 0.02$ ). One hundred kidneys from 76 patients were examined, but, where both kidneys from one person were transplanted, results for the pair were counted as one. Sections contained two to 41 glomeruli, mean 13.

A condition characterised by a glomerular basement membrane (GBM) that is extensively thinner than normal was first reported by Rogers *et al*<sup>1</sup> in four generations of one family, under the title "familial benign essential hematuria". Other synonyms include "thin basement membrane syndrome"<sup>2</sup> and "thin membrane nephropathy" (TMN).<sup>3</sup> At first recognised mainly in children,<sup>4-7</sup> the lesion has recently become known as a cause

Table 1 Sources of donor material

Group	Diagnosis	Numbers	Age (years)		Sex		Blood pressure mm Hg	
			Range	Mean	M	F	Range	Mean
Trauma (n = 36)	RTA or head injury	33	9-64	24.9	31	5	60/0-170/100	118/71
	Gunshot wounds	1						
	Suicide (hanging)	1						
	Burns	1						
CVA (n = 30)	Subarachnoid haemorrhage	20	23-67	41.7	12	18	60/0-190/105	131/78
	"CVA", intracerebral haemorrhage	9						
	Carotid artery occlusion	1						
Other diseases (n = 7)	Epilepsy	2	22-66	38.7	4	3	90/70-140/100	111/71
	Asthma	3						
	Cardiac arrest (? cause)	1						
	Meningitis	1						
Living (n = 3)	Living donor, related to recipient	2	41-68	53	2	1	130/90 (1)	—
	Living, unrelated to recipient (kidney became available unexpectedly as a result of nephrectomy during ureteric surgery)	1						
Total (n = 76)		76	9-68	33.9	49	27		

RTA, road traffic accident; CVA, cerebrovascular accident.

Department of Histopathology, Northwick Park Hospital, Harrow, Middlesex  
F E Dische

Department of Histopathology, Dulwich Hospital, London SE22  
V E R Anderson  
S J Keane

Renal Unit, Dulwich Hospital  
D Taube  
M Bewick  
V Parsons

Correspondence to: Dr F E Dische, 60 Burbage Road, London SE24 9HE.

Accepted for publication 15 February 1990

A separate series of control specimens, unrelated to transplantation and previously collected to establish a normal range of GBM thickness for use in clinical diagnosis, consisted of 12 biopsy, four nephrectomy, and four fresh post mortem needle samples from 11 men and nine women in whom it was thought that the GBM should be normal (normal histology, minimal lesion or minimal change disease  $n = 8$ ; kidney tumour  $n = 4$ ; fatal acute liver failure  $n = 4$ ; acute tubular necrosis  $n = 2$ ; others  $n = 2$ ). These 20 subjects were aged 15–57, mean 35.4 years.

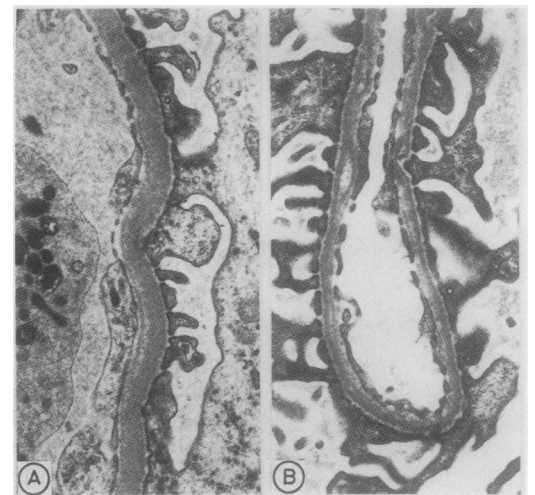
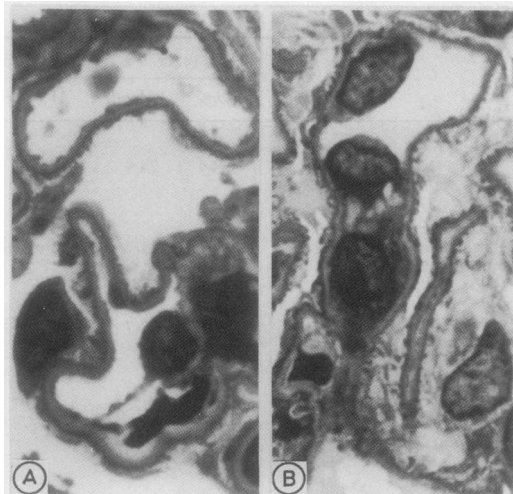
Clinical cases of TMN,<sup>3</sup> diagnosed by biopsy between 1978 and 1989, totalled 53 (21 males and 32 females). Their ages ranged from 11 to 72 years, mean 39.5, and they had presented with asymptomatic microscopic haematuria, macroscopic haematuria, proteinuria or impaired renal function.

Needle biopsy of the graft was performed about 10 minutes after vascularisation had been established, and always within 15 minutes of this step. Tissues were fixed in McDowell and Trump's formalin-glutaraldehyde,<sup>14</sup> post-fixed in 1% osmium tetroxide, and embedded in Agar 100 low viscosity epoxy resin. Resin sections 1  $\mu\text{m}$  thick were stained with alkaline toluidine blue for light microscopy, and ultrathin sections with a silver diffraction colour were stained with lead citrate and uranyl acetate for electron microscopy.

Morphometry was performed on two or more glomeruli in each case by the electron microscopic harmonic mean thickness method of Jensen *et al*<sup>15,16</sup>; the mean number of observations made was 244. GBM thicknesses recorded in our laboratory are greater than those reported by others,<sup>17,18</sup> probably because of differences in fixation or tissue processing.

Measured thicknesses in the 20 non-transplant controls were 346–478 nm, mean (SD) 396 (31.7) nm. The "normal range" (mean  $\pm 2$  SD, rounded off), is 330–460 nm. In clinical TMN, thicknesses varied from 206 to 335 nm, mean 296 nm, SD 26.5; mean ( $\pm 2$  SD) was 243 to 349 nm. We consider a value of  $< 330$  nm, in the relevant clinical circumstances, to be diagnostic of TMN, provided that Alport's syndrome is excluded; results

**Figure 1** Light microscopy of resin sections, viewed under oil immersion objective. The GBM is seen as a pale band: (a) normal thickness (mean 371 nm); (b) abnormally thin (mean 298 nm). (Toluidine blue.)



**Figure 2** Electron microscopy of GBM: (a) normal (mean thickness 397 nm); (b) abnormally thin (mean 298 nm).

between 330 and 340 nm, a range which overlaps with normal, we also regard as presumptive evidence of the condition.

#### PROTOCOL

Sections stained with toluidine blue were screened by light microscopy under the  $\times 100$  oil immersion objective. If the GBM appeared normal in thickness (fig 1a) or thickened, examination was discontinued, but where the membrane looked possibly or definitely thinner than normal (fig 1b), including where both thick and thin segments were observed, electron microscopy was carried out (fig 2) and GBM width measured. Microscopical examination and morphometry were performed throughout by the same observer (FED).

#### Results

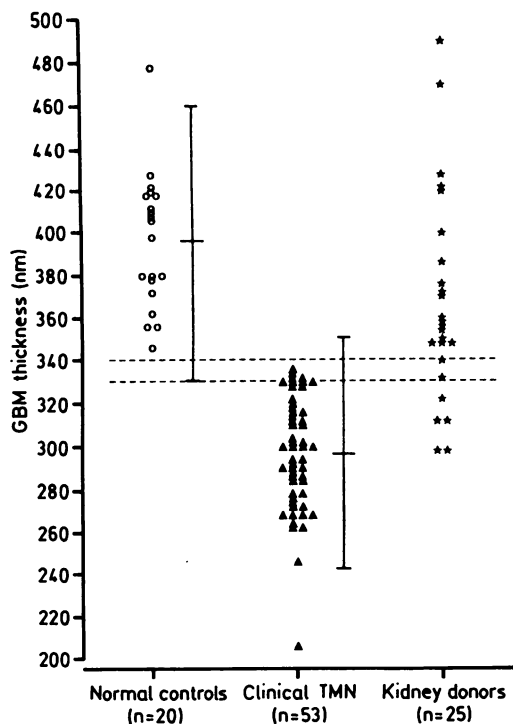
Morphometry, carried out on 13 male and 12 female donors aged 9–67 years, gave figures ranging from 297 to 489 nm. GBM width was  $\leq 330$  nm in five, and in two it lay between 330 and 340 nm, while in the remaining 69 the GBM was normal or slightly thickened by light microscopy or by measurement. The findings are summarised in figs 3 and 4, and details of subjects whose GBM thickness was  $\leq 340$  nm are given in table 2. Mean warm and cold ischaemia times for six of these grafts were 3.5 and 848 minutes, respectively, whereas for 82 of the remainder of the series the corresponding times were 2.8 and 1046 minutes.

A single case of IgA nephropathy was diagnosed incidentally.

#### Discussion

Of this series of donor kidneys, seven (9.2%) had a mean GBM thickness similar to that found in clinical TMN or in the overlap range between thin and normal. Additional structural changes (table 2), including pedicle foot process effacement and an increase in mesangial matrix, were non-specific, although they have been noted in TMN.<sup>3</sup> The spread of

Figure 3 Measurements of GBM thickness in three groups. Bars denote mean  $\pm 2SD$ , and space between dotted lines represents overlap between normal and thin ranges.



LIGHT MICROSCOPY	76
↓	
GBM normal or thick	51
GBM thin or possibly thin	25
↓	
ELECTRON MICROSCOPY, GBM MORPHOMETRY	25
↓	
>340 nm	18
330-340 nm	2 (2.6%)
<330 nm	5 (6.6%)*
Total $\leq 340$ nm	7 (9.2%)†
95% confidence interval $\pm 2.2$ to 14.7%	
† 3.8 to 18.1%	

Figure 4 Summary of procedures and results, with confidence intervals.<sup>19</sup>

results obtained in donors is attributable to the inclusion of subjects whose GBM was segmentally thick as well as segmentally thin.

The high incidence of thin basement membranes found prompted inquiry into factors that might have affected the results. Allograft GBM might have become thickened due to thrombosis<sup>20</sup> (found in 45% of the present series, unpublished data), but there was no reason to expect it to have become thinned. It was this argument that had suggested that transplant kidneys would be suitable for study in the first place. Cerebrovascular accident, which had caused death in 30, might be suspected of having a pathogenetic association with a thin GBM, but although four donors dying of cerebrovascular accident were included among the affected seven, the remaining three sustained trauma or had other disease; such a relation is therefore unlikely. As for technical factors, graft warm and cold ischaemia times were not greatly different from others in the series; tissue fixation seemed to be satisfactory, while the morphometric method has given consistent results in the hands of others,<sup>17,18</sup> as well as in our own. Light microscopical examination was used as a first screening step to reduce the need for the more laborious ultrastructural

procedures; and we are satisfied that resin section light microscopy permits identification of most cases, although electron microscopy remains essential, and morphometry useful, for confirmation and for exclusion of false positive results. Errors, if any, should therefore give a low, rather than a high, apparent incidence. We believe that the donors were representative, in terms of the variable under scrutiny, of the population from which they are drawn, and that our techniques were applied and interpreted correctly.

The separate series of "controls" fortuitously included none with a thin GBM, whereas it is now evident that one or two might have been expected among a group of 20. The controls might be combined with the donors to form a larger sample of the general population; in this case the incidence of a GBM thickness of  $< 330$  nm becomes five of 96 (5.2%, 95% confidence interval 1.7 to 11.7%), and that of a thickness of  $\leq 340$  nm, seven of 96 (7.3%, 3.0 to 14.5%). Donor kidneys may be less suitable for determining the normal range because of the potential for GBM thickening as a result of mild hypertension or harvesting or transplantation procedures. Definition of precise normal limits is not critically important for diagnosis, however, in view of the overlap between the thin and normal ranges deduced from the findings in symptomatic disease.

From the foregoing it is concluded that this GBM abnormality occurs relatively often in the general population, the incidence lying between 5.2% and 9.2%. The 95% confidence intervals are wide, yet even the lower confidence limits (1.7% and 3.8%, respectively) are more than negligible. The incidence of a thin GBM is altogether greater than that of clinically recognised TMN: according to Tiebosch *et al*,<sup>12</sup> cases of TMN are diagnosed in the Netherlands at the rate of 13 per million adults a year.

How does the thin GBM lesion found in donor kidneys relate to clinical TMN? The only two reports of affected donors that we have been able to obtain make no reference to haematuria, but in any case urinary red blood cells in a subject with a catheter may be of little clinical importance. Some other prospective way of answering this question needs to be devised. If clinical expression of the lesion were confirmed, some of the microscopic haematuria shown in population studies might

Table 2 Outline data on donors with GBM thickness of  $\leq 340$  nm

GBM width (nm)	Age (years)	Sex	Cause of death	Blood pressure mm Hg	Other structural abnormalities
297	42	F	Subarachnoid haemorrhage	140/85	Mild MM increase; moderate FP effacement; focal endothelial cell swelling, subendothelial fibrin
298	27	M	Subarachnoid haemorrhage	140/70	Nil
311	32	M	Head injury	N/A	Nil
312	29	F	Asthma, cardiac arrest	110/70	Large glomeruli; slight MM and cell increase; slight to moderate FP effacement
322	56	F	Subarachnoid haemorrhage	110/70	Mild MM increase; moderate FP effacement
331	16	M	Road traffic accident	140/60	Nil
340	30	F	Subarachnoid haemorrhage	N/A	Mild FP effacement

FP, pedicel foot process; MM, mesangial matrix (an increase was never accompanied by electron dense deposits); N/A, not available.

be explained by TMN. Haematuria is reported to occur in 3.5% of young recruits to the Armed Services,<sup>21</sup> rising to 13–14% in older groups,<sup>21,22</sup> but much of the underlying pathology remains obscure.

We are indebted to Dr Susan Snowden and Mrs Janet Cordell for obtaining clinical data, to Mr Derek Lowe for statistical advice, and to Miss Pat Fryer for generous access to electron microscope facilities. We warmly thank Messrs Ken Davies and Ron Senkus, Mrs Padmini Sarathchandra and Miss Janet MacKenzie for electron microscopical and photographic assistance.

- 1 Rogers PW, Kurtzman NA, Bunn SM, White MG. Familial benign essential hematuria. *Arch Intern Med* 1973;131:257–62.
- 2 Churg J, Sobin LH. *Renal disease. Classification and atlas of glomerular disease*. Tokyo: Igaku-Shoin, 1982:281.
- 3 Dische FE, Weston MJ, Parsons V. Abnormally thin glomerular basement membranes associated with hematuria, proteinuria or renal failure in adults. *Am J Nephrol* 1985;5:103–9.
- 4 Tina L, Jenis E, Jose P, Medani C. The glomerular basement membrane in benign familial hematuria. *Clin Nephrol* 1982;17:1–4.
- 5 Yoshikawa N, White RHR, Cameron AH. Familial hematuria: clinico-pathological correlations. *Clin Nephrol* 1982;17:172–82.
- 6 Piel CF, Biava CG, Goodman JR. Glomerular basement membrane attenuation in familial nephritis and 'benign' hematuria. *J Pediatr* 1982;101:358–65.
- 7 Yoshikawa N, Hashimoto H, Katayama Y, Yamada Y, Matsuo T. The thin glomerular basement membrane in children with haematuria. *J Pathol* 1984;142:253–7.
- 8 Yum M, Bergstein JM. Basement membrane nephropathy: a new classification for Alport's syndrome and asymptomatic hematuria based on ultrastructural findings. *Hum Pathol* 1983;14:996–1003.
- 9 Coleman M, Haynes WDG, Dimopoulos P, Barratt LJ, Jarvis LR. Glomerular basement membrane abnormalities associated with apparently idiopathic hematuria: ultrastructural morphometric analysis. *Hum Pathol* 1986;17:1022–30.
- 10 Abe S, Amagasaki Y, Iyori S, et al. Thin basement membrane syndrome in adults. *J Clin Pathol* 1987;40:318–22.
- 11 Perry GJ, George CRP, Field MJ, et al. Thin membrane nephropathy in patients with hematuria. *Kidney Int* 1988;33:137.
- 12 Tiebosch ATMG, Wolters J, Frederik PFM, van der Wiel TWM, Zeppenfeldt E, van Breda Vriesman PJC. Epidemiology of idiopathic glomerular disease: a prospective study. *Kidney Int* 1987;32:112–6.
- 13 Tiebosch ATMG, Frederik PM, van Breda Vriesman PJC, et al. Thin-basement-membrane nephropathy in adults with persistent hematuria. *N Engl J Med* 1989;320:14–8.
- 14 McDowell EM, Trump BF. Histological fixatives suitable for diagnostic light and electron microscopy. *Arch Pathol Lab Med* 1976;100:405–14.
- 15 Jensen EB, Gundersen HJ, Østerby R. Determination of membrane thickness distribution from orthogonal intercepts. *J Microsc* 1979;115:19–33.
- 16 Hirose K, Østerby R, Nozawa R, Gundersen HJG. Development of glomerular lesions in experimental long-term diabetes in the rat. *Kidney Int* 1982;21:689–95.
- 17 Steffes MW, Barbosa J, Basgen JM, Sutherland DER, Najarian JS, Mauer SM. Quantitative glomerular morphology of the normal human kidney. *Lab Invest* 1983;49:82–6.
- 18 Østerby R, Nyberg G, Andersson C, Frisk B. Glomerular structural quantities in baseline biopsies from cadaveric donor kidney pairs. *APMIS* 1988;96(Suppl):134–40.
- 19 Lentner C. *Geigy scientific tables*. Vol 2. Basel: Ciba-Geigy, 1982:89–102.
- 20 Busch GJ, Reynolds ES, Galvanek EG, Braun WE, Dammin GJ. Human renal allografts. The role of vascular injury in early graft failure. *Medicine* 1971;50:29–83.
- 21 Froom P, Gross M, Ribak J, Barzilay J, Benbassat J. The effect of age on the prevalence of asymptomatic microscopic hematuria. *Am J Clin Pathol* 1986;86:656–7.
- 22 Mohr DN, Offord KP, Owen RA, Melton J. Asymptomatic microhematuria and urologic disease. A population-based study. *JAMA* 1986;256:224–9.