

# Endothelin-1 in idiopathic pulmonary fibrosis

M Uguccioni, L Pulsatelli, B Grigolo, A Facchini, L Fasano, C Cinti, M Fabbri, G Gasbarrini, R Meliconi

## Abstract

**Aims**—To evaluate whether endothelin-1 is involved in the pathology of idiopathic pulmonary fibrosis (IPF).

**Methods**—Plasma endothelin-1 concentrations were evaluated in 37 patients with IPF and 27 normal controls by radioimmunoassay. In addition, expression of endothelin-1 in lung tissue was evaluated in biopsy specimens obtained from four patients with IPF. Three biopsy specimens of normal lung were used as controls. Endothelin-1 immunoreactivity was detected using immunohistochemistry.

**Results**—Elevated endothelin-1 plasma concentrations were found in patients with IPF compared with controls and a positive correlation was found with duration of disease. No significant difference was observed between treated and untreated patients with IPF. Increased endothelin-1 immunoreactivity was found in lungs of three of four patients with IPF. Endothelin-1 positive cells consisted mainly of small vessel endothelial cells. Some scattered macrophages were also positive.

**Conclusions**—Elevated plasma concentrations and expression of endothelin-1 in lung tissue are suggestive of increased production of endothelin-1 in at least a proportion of patients with IPF. Consequently, endothelin-1 activity could play a role in the fibrogenic process of the disease.

(J Clin Pathol 1995;48:330-334)

Keywords: Endothelin, idiopathic pulmonary fibrosis.

Idiopathic pulmonary fibrosis (IPF) is a chronic inflammatory disease which affects the interalveolar walls of the lung.<sup>1,2</sup> The two main characteristics of IPF are inflammation and fibrosis, present in both the interstitial area of the interalveolar septa and the intra-alveolar space. Inflammatory changes consist mainly of infiltration of macrophages and lymphocytes. Inflammation is accompanied by increased deposition of fibrous tissue with consequent distortion of the parenchymal architecture. These changes are associated with hyperplasia of (myo)fibroblasts and of the smooth muscle fibres.<sup>1</sup> Inflammatory cells are responsible for endothelial and alveolar epithelial cell damage and fibrogenic activity, probably by releasing a variety of cytokines and other mediators.<sup>3</sup>

A novel peptide family, the endothelins,<sup>4</sup> was identified recently which, in addition to vasoconstrictor activity, exerts a potent mitogenic effect on smooth muscle cells and fibroblasts.<sup>5-8</sup>

Of these peptides, endothelin-1 exerts the greatest effect. Endothelin-1 can be synthesised by endothelial cells, vascular smooth muscle cells, airway epithelium, granulocytes, and macrophages.<sup>9</sup> Increased concentrations and biosynthesis of endothelin-1 were demonstrated in the lungs of patients with pulmonary hypertension<sup>10</sup> and in patients with scleroderma.<sup>11</sup> As synthesis of endothelin-1 is enhanced by cytokines including transforming growth factor- $\beta$  (TGF- $\beta$ ), tumour necrosis factor- $\alpha$  (TNF- $\alpha$ ) and interleukin-1 (IL-1),<sup>12-14</sup> and hypoxia<sup>15</sup> and as endothelin-1 can induce fibroblast and smooth muscle cell proliferation, we evaluated plasma concentrations and the expression of endothelin-1 in lung tissue in patients with IPF.

## Methods

Plasma was obtained from 37 patients with IPF (29 men; mean age 61 years, range 36-82 years), 15 of whom were receiving immunosuppressive treatment.

Diagnosis of IPF was made on the basis of clinical, radiological, scintigraphic, physiological, and histological findings.<sup>16</sup> No associated well defined connective tissue disease was present in any of the patients. There was no history of exposure or of sensitivity to drugs or organic dust. No associated inflammatory conditions were reported. Disease duration was between six and 72 months (median 29 months). Dyspnoea, radiological and physiological scores were formulated as reported previously.<sup>17</sup> <sup>67</sup>Gallium scanning of lung tissue was scored as described by Nosal *et al.*<sup>18</sup> Diffusing lung CO capacity in a single breath corrected for alveolar ventilation (DLCOsb/AV per cent predicted) was scored as described by Watters *et al.*<sup>19</sup> Arterial oxygen pressures (PaO<sub>2</sub>) were measured both at resting and after exercise. Patients' lung involvement was globally quantified using a composite clinical, radiological and physiological scoring system (CRP score).<sup>19</sup>

Lung biopsy specimens were available from four IPF patients. Normal lung specimens were obtained from three patients who underwent pneumonectomy for lung cancer: the lung specimens obtained were not contiguous to the neoplastic area and were histologically normal. Plasma was also obtained from 27 elderly blood donors (mean age 59 years, range 55-65 years; 16 men).

Blood (10 ml) was obtained from each patient between 0700 and 0900 hours and centrifuged at 1000  $\times$  g at 4°C for 15 minutes. Plasma samples were stored at -70°C until analysis. Samples were thawed once just before

Laboratorio di  
Immunologia e  
Genetica, Istituto di  
Ricerca Codivilla  
Putti, Italy

M Uguccioni  
L Pulsatelli  
B Grigolo  
A Facchini

Patologia Medica I,  
Università di Bologna,  
Bologna, Italy  
G Gasbarrini  
R Meliconi

Cattedra di  
Fisiopatologia  
Respiratoria,  
Università di Bologna  
L Fasano  
M Fabbri

Presidio di  
Pneumotisiologia,  
Ospedale Malpighi,  
Bologna  
C Cinti

Correspondence to:  
Dr R Meliconi, Patologia  
Medica I, Policlinico S.  
Orsola, Via Massarenti 9,  
40138 Bologna, Italy.

Accepted for publication  
26 September 1994

use. Laboratory investigations were performed by personnel unaware of clinical data.

**ENDOTHELIN ASSAY**

Plasma samples (1 ml) were acidified with 0.25 ml 2 M HCl, centrifuged at 10 000 × g for five minutes at room temperature and loaded on C2 columns (Amprep 500 mg RPN 1913, Amersham, Little Chalfont, UK). The columns were then washed with water and 0.1% trifluoroacetic acid (TFA) and then with 80% acetonitrile in water and 0.1% TFA. The eluant was collected and dried down with nitrogen. After reconstitution, 200 µl samples were evaluated using a radioimmunoassay (Endothelin 1,2-high sensitivity-<sup>125</sup>I assay system; Amersham).

**IMMUNOHISTOCHEMISTRY**

Lung biopsy specimens were snap frozen in liquid nitrogen and stored at -70°C. Serial cryostat sections, 4 µm thick, were air-dried, fixed in acetone at 4°C for 10 minutes and stored at -70°C until analysis. Endothelin-1 immunoreactivity was tested as follows: the slides were incubated with 0.3% hydrogen peroxide in methanol to block endogenous peroxidase, washed in Tris buffered saline (TBS), pH 7.4, and then incubated overnight at 4°C with an optimal dilution (1 in 1000) of rabbit endothelin-1 antiserum (CA-08-351; Cambridge Research, Norwich, UK).<sup>20-22</sup> After washing, the sections were incubated with peroxidase conjugated swine antirabbit immunoglobulins for 30 minutes at room temperature. Reactivity to endothelin-1 was developed in 0.06% diaminobenzidine in TBS with 0.03% hydrogen peroxidase for five minutes. The slides were then washed in TBS, stained with haematoxylin for four minutes, dehydrated in graded alcohols and xylene, and permanently mounted with coverslips. Endothelin-1 staining was also performed with alkaline phosphatase conjugated swine anti-rabbit immunoglobulins. Reactivity was developed with Fuchsin Substrate solution (Dako, Glostrup, Denmark) containing levamisole. Finally, the slides were washed in TBS, contrasted with haematoxylin for four minutes and mounted with coverslips. The specificity of endothelin-1 binding was tested by adsorption of the optimally diluted antiserum with either 10 nmol human endothelin-1 (Cambridge Research) or an unrelated pep-

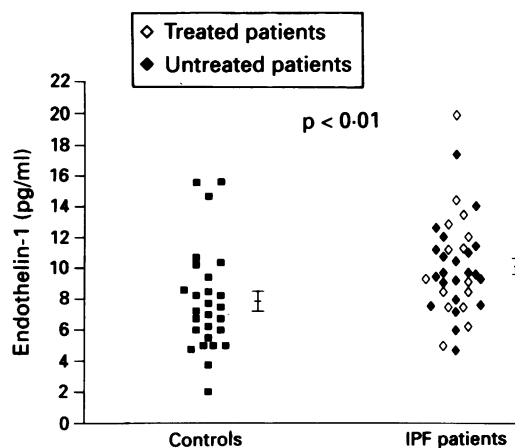


Figure 1 Endothelin-1 plasma concentrations in controls and patients with IPF. Mean and SEM of each group are also presented.

tide (serum amyloid A protein; Calbiochem, San Diego, California, USA) overnight at 4°C before staining.

Grading of endothelin-1 immunoreactivity was carried out semiquantitatively as follows: negative (-), focal/weak staining (+), moderate staining (++), and strong staining (+++). Grading was performed and independently agreed upon by three authors.

Various monoclonal antibodies were used in the indirect peroxidase or the alkaline phosphatase-antialkaline phosphatase (APAAP) methods to identify, in serial sections, the cells reacting with endothelin-1 antiserum: anti-CD3 (T lymphocytes), anti-CD68 (macrophages), anti-factor VIII (endothelial cells) (Dako); anticytokeratin 18 (epithelial cells) (Boehringer Mannheim, Mannheim, Germany); anti-HLA-DR (activated cells) (Becton Dickinson, San Jose, California, USA).

The Mann-Whitney U test for independent values and Kendall's coefficient of correlation (to compare endothelin-1 plasma concentrations and parameters of disease severity) were used for data analysis.

**Results**

**PLASMA ENDOTHELIN-1 CONCENTRATIONS**

Patients with IPF had higher plasma endothelin-1 concentrations compared with controls (patients with IPF, mean ± SEM, 10.14 ± 0.52 pg/ml; controls, 7.86 ± 0.65 pg/ml; p < 0.01) (fig 1).

No significant differences were observed between treated and untreated cases of IPF (un-

*Endothelin-1 immunostaining in lung tissue of patients with IPF and normal controls*

Group	Immunosuppressive treatment	Endothelium		Epithelium		Macrophages		T lymphocytes
		Small vessels	Arteries	Airway epithelium	Type II pneumocytes	Alveolar	Interstitial	
IPF	Yes	+++	-	-	-	-	+	-
IPF	No	+++	-	-	-	-	+	-
IPF	No	++	-	-	-	-	+	-
IPF	No	+	-	-	-	-	-	-
Controls	No	+	-	-	-	-	-	NP
Controls	No	-	-	-	-	-	-	NP
Controls	No	+	+	-	-	-	-	NP

Normal lung tissue was obtained from patients with lung cancer who underwent pneumonectomy. Lung tissue specimens used in this assay were not taken from areas next to the tumour site.

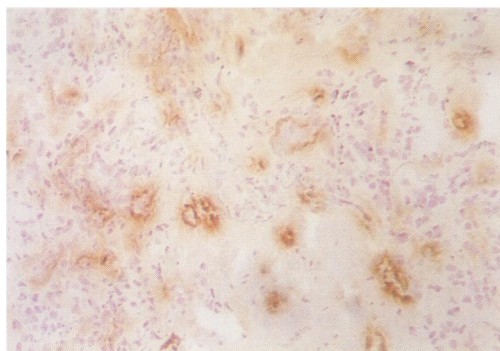
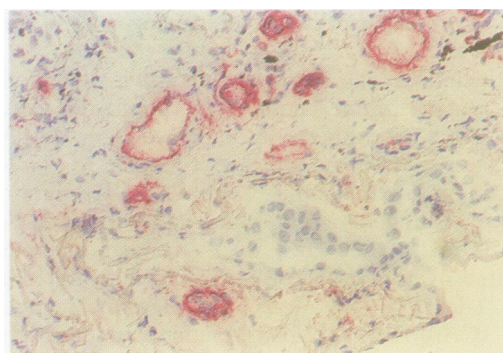
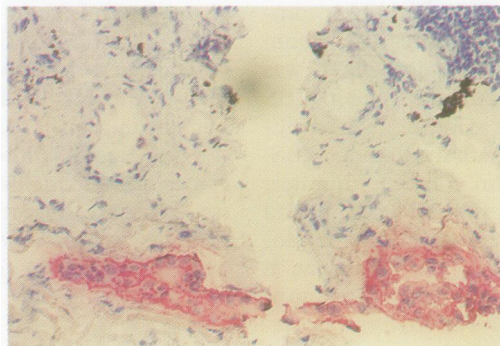


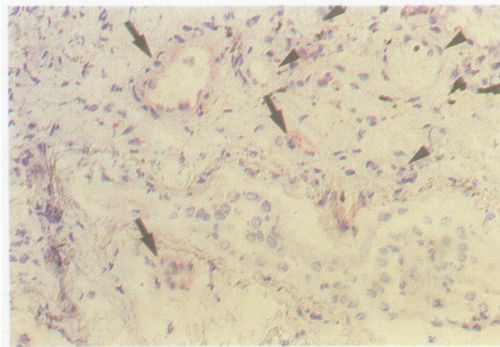
Figure 2 Endothelin-1 immunoreactivity in lung tissue from a patient with IPF (peroxidase method). Immunoreactivity was observed in the endothelial cells of several small vessels (low magnification) and in some isolated macrophages.



A



B



C

Figure 3 Endothelin-1 immunoreactivity in serial sections of lung tissue from a patient with IPF (alkaline phosphatase method). A: Endothelial cell identified by staining with antiserum to factor VIII; B: alveolar epithelial cell identified by staining with a monoclonal antibody to cytokeratin 18; C: endothelin-1 immunoreactivity in the endothelial cells of three vessels (arrows). Other vessels (arrow heads) and epithelial cells are negative.

treated cases,  $9.92 \pm 0.59$  pg/ml; treated cases,  $10.46 \pm 0.98$  pg/ml). Plasma endothelin-1 concentrations were then correlated with the following clinical and laboratory parameters in patients with IPF: age, sex, disease duration, dyspnea score, DLCO capacity, resting  $\text{PaO}_2$ ,  $\text{PaO}_2$  after exercise, vital capacity, radiological score, physiological score, and global CRP score. Endothelin-1 concentrations correlated with disease duration only ( $p < 0.01$ ).

#### ENDOTHELIN-1 IMMUNOREACTIVITY IN LUNG TISSUE

Endothelin-1 was expressed in various amounts in the biopsy specimens examined. Only a few scattered cells were positive in normal lung tissue, while an increased percentage of positive cells was present in three of four patients with IPF (table). Endothelin-1 positive cells were mainly small vessel endothelial cells and scattered macrophages (fig 2). Endothelin-1 positive small vessels were found in both inflamed and fibrous areas. Endothelin-1 positive and endothelin-1 negative vessels were often adjacent to each other. In several, but not all, endothelin-1 positive vessels staining tended to diffuse from the lumen into the surrounding tissue. Endothelin-1 positive endothelial cells were weakly positive or negative for class II antigens (HLA-DR). Definite endothelin-1 staining was not found in the endothelium of muscular pulmonary arteries, alveolar epithelial cells (type II pneumocytes) (figs 3A, 3B and 3C), or in the airway epithelium, or vascular smooth muscle cells.

Preincubation of endothelin-1 with antiserum completely abolished endothelin-1 immunostaining in all positive cells. The specificity of the reaction was confirmed by the lack of efficacy on preincubation with an unrelated peptide (serum amyloid A protein).

#### Discussion

The pathogenesis of IPF is still largely unknown. Immune mediated mechanisms seem to play a major role. Infiltration of activated macrophages, neutrophils and lymphocytes is accompanied by the release of a variety of cytokines and mediators which may be responsible for both cellular damage and fibrogenic activity. It has already been demonstrated that fibrotic lung tissue synthesises increased amounts of fibrogenic cytokines such as TGF- $\beta$  and platelet derived growth factor (PDGF).<sup>23,24</sup>

In the present study increased endothelin-1 concentrations were found in plasma and in the lung tissue of a proportion of patients with IPF. As endothelin-1 has marked mitogenic activity on fibroblasts and smooth muscle cells,<sup>5-8,11</sup> we suggest that endothelin-1 is an additional mediator of fibrogenesis in IPF.

This is the first report of plasma endothelin-1 concentrations in IPF. A previous study<sup>11</sup> reported high endothelin-1 concentrations in patients with scleroderma, particularly in those with lung involvement (diffuse scleroderma).<sup>25</sup> Elevated endothelin-1 plasma concentrations

were also found in patients with pulmonary hypertension<sup>26</sup> and in patients with arthritis.<sup>27</sup>

Our results are partially in keeping with those of Giaid *et al.*,<sup>28</sup> who reported increased endothelin-1 immunostaining and increased detection of endothelin-1 messenger RNA (mRNA) in lungs of patients with IPF. As yet, increased expression of endothelin-1 in pathological specimens was found in epithelial cells, endothelial cells, or infiltrating macrophages.<sup>10,28-30</sup> Unlike Giaid *et al.*,<sup>28</sup> we found that endothelin-1 immunoreactivity was virtually confined to small vessel endothelial cells and absent in type II pneumocytes and airway epithelium. In our lung specimens endothelin-1 staining often diffused from the endothelial cells into the surrounding tissue. This feature is in keeping with the finding by Yoshimoto *et al.*<sup>31</sup> of a major release of endothelin by cultured endothelial cells towards the basement membrane and not towards the lumen, thus confirming the paracrine activity of the peptide.<sup>9</sup> Because of this feature of staining, epithelial, vascular smooth muscle or neuroendocrine cells adjacent to endothelin-1 positive small vessels would also have stained positively for endothelin-1. We also observed some isolated endothelin-1 positive tissue macrophages; none of the alveolar macrophages were endothelin-1 positive.

There may be several reasons for the differences in immunostaining observed in this study and in that of Giaid *et al.*<sup>28</sup> Firstly, the restricted number of lung biopsy specimens examined in the present study. Endothelin-1 expression could be unevenly distributed in different areas of the lung or in different zones of the same area. Therefore, the low/normal endothelin-1 immunoreactivity found in two of our patients could be because of the sampling procedure. Secondly, discrepancies in endothelin-1 immunolocalisation could be because of the timing of lung biopsy, in either the early or the late stages of disease. Finally, the antisera used in the present study and those used by Giaid *et al.*<sup>28</sup> may be different (that is, they may recognise different epitopes) and this may explain, at least in part, the different findings.

What triggers endothelial cells to produce endothelin-1 in interstitial lung disease? Two major stimuli may be involved. Firstly, cytokines which can activate endothelial cells may also stimulate production of endothelin-1—for example, TNF- $\alpha$ , TGF- $\beta$  and IL-1 which are abundantly synthesised by lung tissue of patients with IPF.<sup>12-14</sup> Secondly, Kourembanos *et al.*<sup>15</sup> demonstrated that hypoxia induces endothelin gene expression and secretion. Hypoxia is certainly present in the affected zones in patients with IPF and is caused by a defect in the transfer of gas, as shown by the changes in the DLCO capacity. Giaid *et al.*<sup>28</sup> found a close correlation between endothelin-1 expression and pathological parameters of active disease, thus suggesting the possibility of therapeutic intervention and favourable prognosis. Our results cannot confirm this suggestion. With regard to plasma endothelin-1 concentrations we found no difference between treated and untreated patients and even if the

patients with the longest disease duration had the highest endothelin-1 concentrations, we did not find significant correlations with clinical or laboratory markers of disease severity.

In conclusion, the elevated plasma concentrations and expression of endothelin-1 in lung tissue reported in our study suggest increased production of endothelin-1 in at least a proportion of patients with IPF. Endothelin-1 production is probably enhanced by inflammatory cytokines and local hypoxia. Consequently, endothelin-1 activity could play a role in the fibrogenic process of the disease. An interesting evaluation of the role of endothelin-1 could be carried out by studying the time course and localisation of endothelin-1 expression in the lungs of animals with experimental lung fibrosis.

- Crouch E. Pathology of pulmonary fibrosis. *Am J Physiol* 1990;259:L159-84.
- Hyde DM, King TE Jr, McDermott T, Waldron JA Jr, Colby TV, Thurlbeck WM, *et al.* Idiopathic pulmonary fibrosis. Quantitative assessment of lung pathology. Comparison of a semiquantitative and morphometric histopathologic scoring system. *Am Rev Respir Dis* 1992;146:1042-7.
- McDonald JA, Kuhn C. Fibroblast and collagen deposition in interstitial lung disease. In: Schwarz MI, King TE, eds. *Interstitial lung disease*. St Louis: Mosby, 1993:45-57.
- Yanagisawa M, Kurihara H, Kimura S, Tomobe Y, Kobayashi M, Mitsui Y, *et al.* A novel potent vasoconstrictor peptide produced by vascular endothelial cells. *Nature* 1988;332:411-5.
- Bobik A, Grooms A, Millar JA, Mitchell A, Grinpukel S. Growth factor activity of endothelin on vascular smooth muscle. *Am J Physiol* 1990;258:408-15.
- Hirata Y, Takagi Y, Fukuda Y, Marumo F. Endothelin is a potent mitogen for rat vascular smooth muscle cells. *Atherosclerosis* 1989;78:225-8.
- Nakaki T, Nakayama M, Yamamoto S, Kato R. Endothelin-mediated stimulation of DNA synthesis in vascular smooth muscle cells. *Biochem Biophys Res Commun* 1989;158:880-3.
- Kusuhara M, Yamaguchi K, Ohnishi A, Abe K, Kimura S, Oono H, *et al.* Endothelin potentiates growth factor-stimulated DNA synthesis in Swiss 3T3 cells. *Jpn J Cancer Res* 1989;80:302-5.
- Haynes WG, Webb DJ. The endothelin family of peptides: local hormones with diverse roles in health and disease? *Clin Sci* 1993;84:485-500.
- Giaid A, Yanagisawa M, Langleben D, Michel RP, Levy R, Shennib H, *et al.* Expression of endothelin-1 in the lungs of patients with pulmonary hypertension. *N Engl J Med* 1993;328:1732-9.
- Bashar Kahaleh M. Endothelin, an endothelial-dependent vasoconstrictor in scleroderma. *Arthritis Rheum* 1991;34:978-83.
- Kurihara H, Yoshizumi M, Sugiyama T, Takaku F, Yanagisawa M, Masaki T, *et al.* Transforming growth factor-beta stimulates the expression of endothelin mRNA by vascular endothelial cells. *Biochem Biophys Res Commun* 1989;159:1435-40.
- Yoshizumi M, Kurihara H, Morita T. Interleukin-1 increases the production of endothelin-1 by cultured endothelial cells. *Biochem Biophys Res Commun* 1990;166:324-9.
- Orisio S, Morigi M, Zoja C, Perico N, Remuzzi G. Tumor necrosis factor stimulates endothelin-1 gene expression in cultured bovine endothelial cells. *Mediators Inflamm* 1992;1:263-6.
- Kourembanas S, Marsden PA, McQuillan LP, Faller DV. Hypoxia induces endothelin gene expression and secretion in cultured human endothelium. *J Clin Invest* 1991;88:1054-7.
- King TE. Idiopathic pulmonary fibrosis. In: Schwarz MI, King TE, eds. *Interstitial lung disease*. St Louis: Mosby, 1993:367-403.
- Meliconi R, Lalli E, Borzi RM, Sturani C, Galavotti V, Gunella G, *et al.* Idiopathic pulmonary fibrosis: can cell mediated immunity markers predict clinical outcome? *Thorax* 1990;45:536-40.
- Nosal A, Schkissner LA, Mishkin FA, Lieberman J. Angiotensin 1-converting enzyme and Gallium scan in non-invasive evaluation of sarcoidosis. *Ann Intern Med* 1979;90:328-34.
- Watters LC, King TE, Schwarz MI, Waldron JA, Stanford RE, Cherniack RM. A clinical, radiologic and physiologic scoring system for the longitudinal assessment of patients with idiopathic pulmonary fibrosis. *Am Rev Respir Dis* 1986;133:97-103.
- Giaid A, Gibson SJ, Ibrahim NBN, Legon S, Bloom SR, Yanagisawa M, *et al.* Endothelin 1, an endothelium-derived peptide, is expressed in neurons of the human spinal cord and dorsal root ganglia. *Proc Natl Acad Sci USA* 1989;86:7634-8.

- 21 Inagaki H, Bishop AE, Escrig C, Wharton J, Allen-Mersh TG, Polak JM. Localization of endothelin-like immunoreactivity and endothelin binding sites in human colon. *Gastroenterology* 1991;101:47-54.
- 22 Giaid A, Gibson SJ, Herrero MT, Gentleman S, Legon S, Yanagisawa M, et al. Topographical localisation of endothelin mRNA and peptide immunoreactivity in neurons of the human brain. *Histochemistry* 1991;95:303-14.
- 23 Broekelmann TJ, Limper AH, Colby TV, McDonald JA. Transforming growth factor  $\beta$ 1 is present at sites of extracellular matrix gene expression in human pulmonary fibrosis. *Proc Natl Acad Sci USA* 1991;88:6642-6.
- 24 Shaw RJ, Benedict SH, Clark RAF, King TE. Pathogenesis of pulmonary fibrosis in interstitial lung disease: alveolar macrophage PDGF(B) gene activation and upregulation by interferon gamma. *Am Rev Respir Dis* 1991;143:167-73.
- 25 Yamane K, Miyauchi T, Suzuki N, Yuhara T, Akama T, Suzuki H, et al. Significance of plasma endothelin-1 levels in patients with systemic sclerosis. *J Rheumatol* 1992;19:1566-71.
- 26 Stewart DJ, Levy RD, Cernacek P, Langleben D. Increased plasma endothelin-1 in pulmonary hypertension: marker or mediator of disease? *Ann Intern Med* 1991;114:464-9.
- 27 Miyasaka N, Hirata Y, Ando K, Sato K, Morita H, Shichiri M, et al. Increased production of endothelin-1 in patients with inflammatory arthritides. *Arthritis Rheum* 1992;35:397-400.
- 28 Giaid A, Michel RP, Stewart DJ, Sheppard M, Corrin B, Hamid Q. Expression of endothelin-1 in lungs of patients with cryptogenic fibrosing alveolitis. *Lancet* 1993;341:1550-4.
- 29 Springall DR, Howarth PH, Counihan H, Djukanovic R, Holgate ST, Polak JM. Endothelin immunoreactivity of airway epithelium in asthmatic patients. *Lancet* 1991;337:697-701.
- 30 Murch SH, Braegger CP, Sessa WC, MacDonald TT. High endothelin-1 immunoreactivity in Crohn's disease and ulcerative colitis. *Lancet* 1992;339:381-5.
- 31 Yoshimoto S, Ishizaki Y, Sasaki T, Murota SI. Effect of carbon dioxide and oxygen on endothelin production by cultured porcine cerebral endothelial cells. *Stroke* 1991;22:378-83.