

Cells immunoreactive for neuropeptide in human thymomas

L Lauriola, N Maggiano, L M Larocca, F O Ranelletti, R Ricci, M Piantelli, A Capelli

Abstract

The presence of opioid peptides, bombesin, and substance P was investigated by immunohistochemistry in tissue sections from six human thymomas. The number of immunoreactive cells seemed to vary from one case to another. Ultrastructural investigation, showing the presence of desmosomes in labelled cells, allowed these cells to be classified as epithelial lineage cells. The occurrence of cells containing neuropeptide in thymomas suggest that peptide molecules could have modulated the behaviour of this tumour, given the reported influence of these molecules on immune functions and their growth promoting activity on several cell types, including mesenchymal and epithelial cells.

Thymomas are neoplasms of the thymus gland, composed of a mixture of lymphocytes and epithelial cells, a relative proportion of which vary widely from one case to another and even within a single tumour. They are regarded as neoplasms of the epithelial component, the lymphoid component being regarded as secondary, either induced by epithelial cell proliferation, or reactive.¹ Many studies suggest that the lymphoid and epithelial components of thymomas mirror the phenotype of normal thymus.²⁻⁴ Cell subsets containing neuropeptide hormones have been reported in the human thymus.^{5,6} Furthermore, we recently found cells immunoreactive for anti- β -endorphin (Leu)- and (Met)-enkephalin, bombesin, and substance P, mainly distributed in the cortical area of normal thymus.⁷ In the light of this, we investigated the presence of these cells in human thymomas to verify if the neoplastic epithelial cell growth could affect the distribution of this cell subset.

Methods

Thymoma tissue from six patients, aged 45 to 70 years, with Myasthenia gravis and thymus fragments obtained during open heart surgery from five infants (aged 1 month to 4 years) were studied. All specimens were fixed in 0.4% p-benzoquinone in 0.01 M phosphate buffered saline (PBS), pH 7.3, for two to three hours. After fixation the specimens were transferred to PBS containing 15% sucrose and 0.1% sodium azide. The tissue was then

frozen for cryostat sectioning. Sections 5 μ m thick were mounted on slides coated with poly-L-lysine (Sigma, Deisenhofen, West Germany), treated with 0.03% hydrogen peroxide in methanol for 10 minutes to block endogenous peroxidase activity, and incubated for one hour with the following rabbit anti-peptide polyclonal antibodies at dilutions ranging from 1 in 400 to 1 in 800 in PBS (pH 7.6): anti β -endorphin; anti (Leu)- and (Met)-enkephalin; anti-bombesin; and anti-substance P (Amersham, England, and UCB Bioproducts, Belgium). Moreover, anti-chromogranin antiserum (Enzo Diagnostics, New York, USA) was used at dilutions ranging from 1 in 4000 to 1 in 8000. Indirect immunostaining was achieved using both the peroxidase-antiperoxidase technique (PAP) (Dako, Copenhagen, Denmark)⁸ and the avidin-biotin complex (ABC) (Vector, Burlington, Massachusetts, USA).⁹ The peroxidase was developed with 3-amino 9-ethyl carbazole following the procedure reported by Graham *et al.*¹⁰

For electron microscopical examination small fragments of thymoma were cut on a Sorvall TC-2 sectioner, fixed in 4% paraformaldehyde for two hours, and processed by the PAP method, using anti-peptide antibodies, as previously reported.¹¹ After immunoreaction the slices were post-fixed in 1% OsO₄ in 0.1 M PBS for 30 minutes, dehydrated in ethanol and propylene-oxide, and embedded in Epon 812. Sections of 80 or 90 nm in thickness were lightly counterstained with lead citrate and viewed with a Philips EM 400.

The antiserum to β -endorphin (UCB Bioproducts) was tested (immunoassay) by the manufacturer. The specificity of this antiserum, expressed as a per cent of fixation (B/T \times 100) of hormone tracers (¹²⁵I) at a 1 in 200 dilution was 59 for β -endorphin and 1 for gamma-endorphin. No fixation was observed with alpha-endorphin, Leu-enkephalin, LH-RH, TRH and corticotropin-like intermediate peptide. Anti-bombesin antiserum partially cross reacted with substance P. It was then affinity purified with substance P (Boehringer, Mannheim, West Germany) coupled to CNBr activated Sepharose 4B (1 mg peptide/ml swollen bead). Anti-substance P antiserum tested by the manufacturer did not cross react with bombesin. The specificity of the immunolabelling was tested by preabsorbing antiserum with their homologous synthetic antigens (100-fold w/w excess) (Boehringer). The immunoreaction was then abolished.

Istituto di Anatomia
Patologica, Università
Cattolica S Cuore,
Largo F. Vitto 1, 00168
Rome, Italy
L Lauriola
N Maggiano
L M Larocca
F O Ranelletti
R Ricci
M Piantelli
A Capelli

Correspondence to:
Dr Libero Lauriola
Accepted for publication
6 June 1990

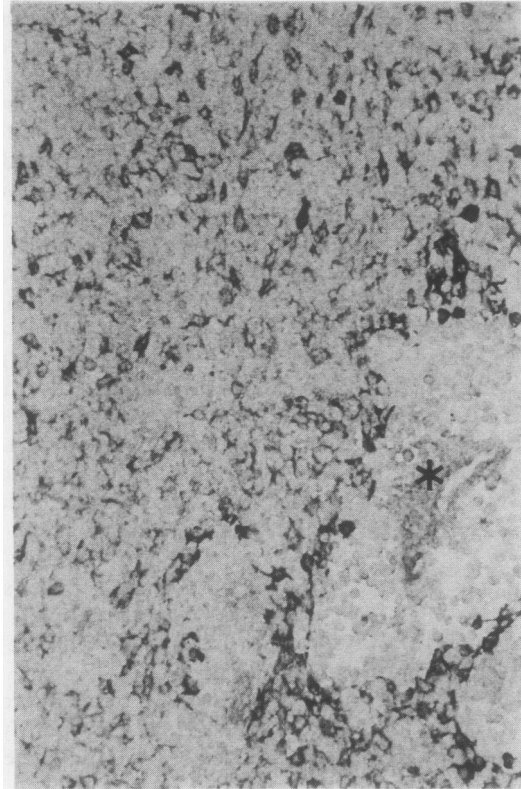
Positive controls consisted of hypothalamic tissue obtained from two necropsy cases. Negative controls consisted of normal rabbit serum or anti-thyroglobulin rabbit antibodies (Dakopatts a/s, Denmark) used in place of the primary antiserum. Negative controls were also performed by omitting either the second antiserum, or the PAP, or ABC complexes. All anti-peptide antisera were unreactive when tested on normal human skin keratin-

ocytes and on squamous cell carcinoma samples. To avoid non-specific immunocytochemical reactions all antisera were diluted in 2 mg/ml poly-L-lysine containing buffer, as suggested by Scopsi *et al.*¹²

Results

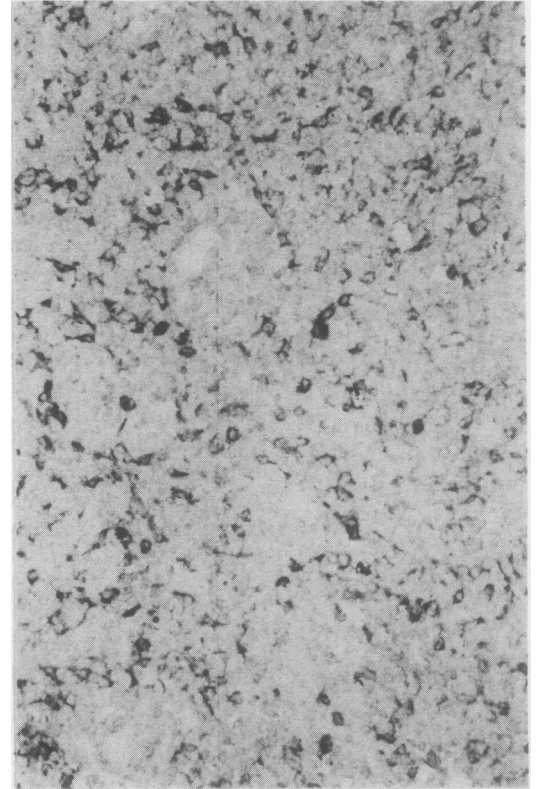
Most neoplastic epithelial cells in the thymomas studied had large round to oval

Figure 1 Thymoma treated with anti β -endorphin antiserum. A perivascular space () containing lymphoid cells seems to be well demarcated by immunoreactive cells.*



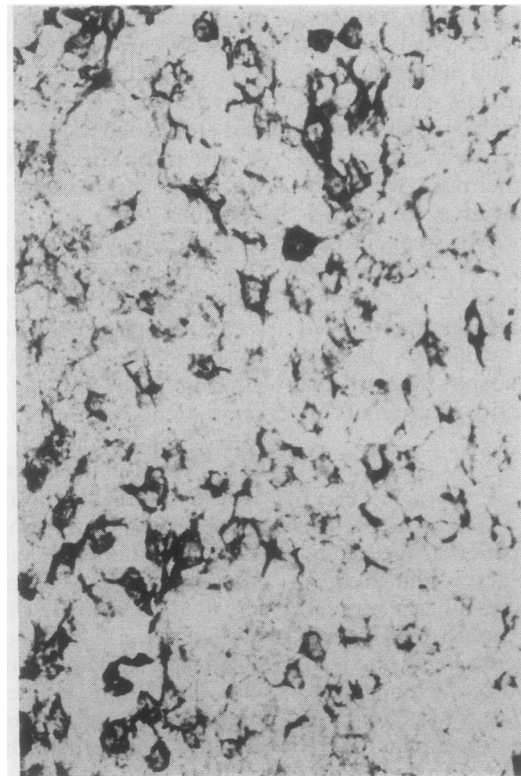
1

Figure 2 Thymoma treated with anti-met-enkephalin antiserum.



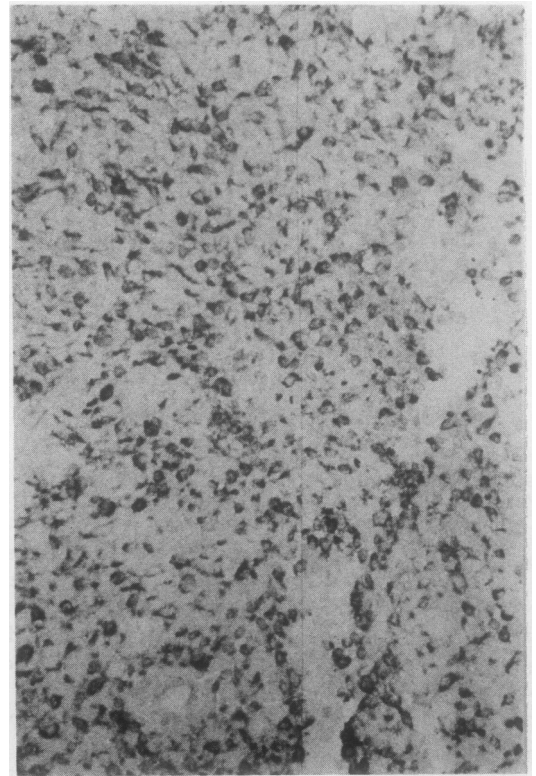
2

Figure 3 Thymoma treated with anti-bombesin antiserum.



3

Figure 4 Thymoma treated with anti-substance P antiserum.



4

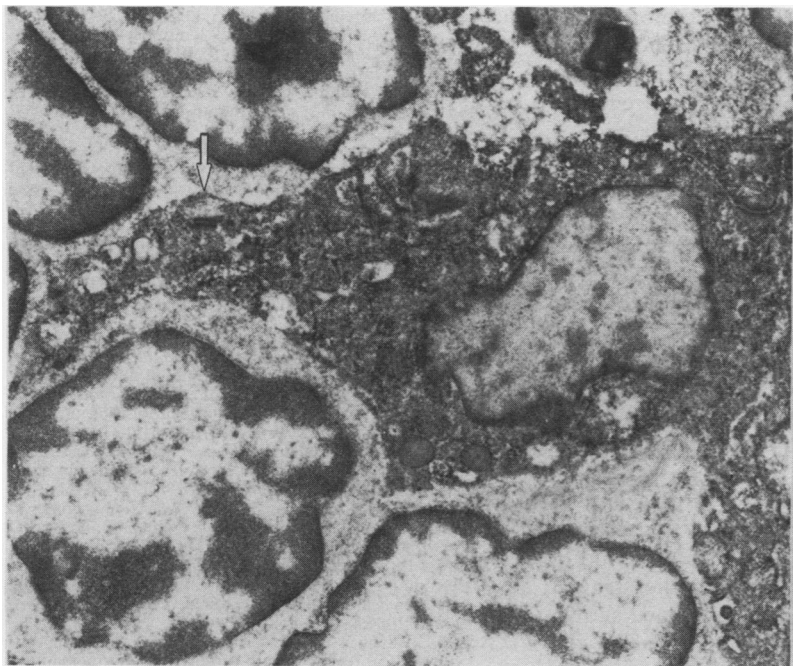


Figure 5 Electron micrograph of thymoma treated with anti Met-enkephalin antiserum. Arrowhead at a desmosome.

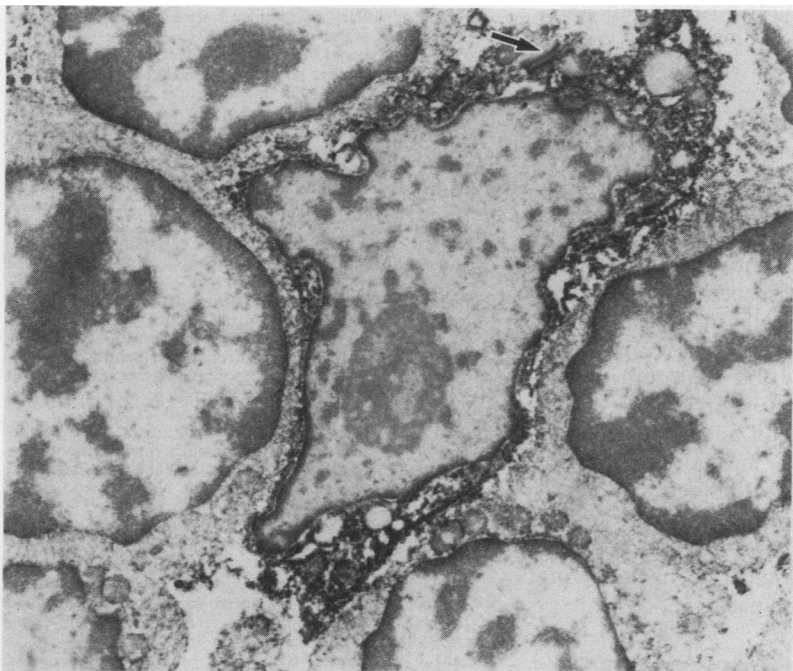


Figure 6 Electron micrograph of an immunolabelled cell after treatment with anti β -endorphin antibody. Arrowhead at a desmosome.

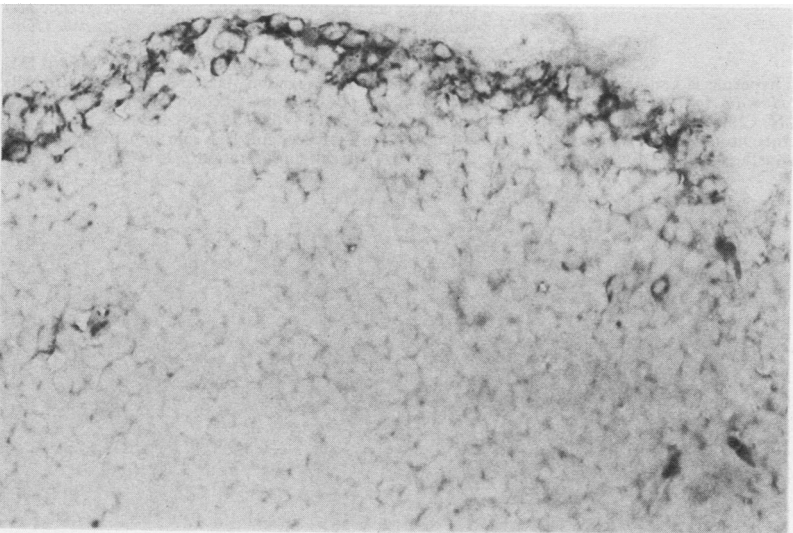


Figure 7 Normal thymus treated with anti β -endorphin antiserum. Immunolabelled cells are located at the periphery of a lobule.

nuclei with finely dispersed chromatin, often with small distinct nucleoli. The number of admixed lymphocytes was variable, ranging from abundant to moderate. Isolated areas of spindle-shaped epithelial cells were observed in only one case. Perivascular spaces were usually prominent.

When immunohistochemistry was performed, the reactivity of the antibodies tested varied widely from one case to another. Only a few isolated cells were immunoreactive for anti-Leu-, Met-enkephalin, and bombesin antibodies in one case. Samples from three tumours exhibited consistent numbers of immunoreactive cells when tested with all the antibodies. The immunostained cells seemed to be evenly distributed among the neoplastic tissue (figs 1–4). The periphery of perivascular spaces sometimes appeared well demarcated by immunoreactive cells, no labelled cells being found within this area. The remaining two cases showed a similar immunostaining pattern, although fewer cells seemed to be positive. All the thymoma cases studied were completely negative when tested with anti-chromogranin antibodies.¹³ Thymic lymphocytes obtained from fresh thymoma tissue did not react with any of the anti-peptide antisera.

Immunoelectron microscopic studies were also performed on tissue fragments from two thymomas to obtain a clearer characterisation of the immunoreactive cells. After immunostaining with each peptide antisera the immunolabelled cells displayed a rounded or oval nucleus and a cytoplasm with many projections (figs 5–6). The immunoreaction product seemed to be located in the cell cytoplasm. The immunostained cells were often linked to each other and to adjacent unlabelled cells by desmosomes. These ultrastructural findings made it possible to classify these cells as belonging to the epithelial lineage.

When immunohistochemistry was performed on sections from normal thymus, a common pattern of immunostaining was observed with all the peptide antisera. A rim of immunoreactive cells was present in the capsular cortex, while only a few, scattered positive cells were found in the remaining cortex and in the medulla (fig 7). Negative controls exhibited no reaction product either at the light or electron microscopic level (not shown).

Discussion

The presence of these immunoreactive cells in human thymoma is not unexpected, as we recently found cells immunoreactive for anti- β -endorphin, (Leu)-, (Met)-enkephalin, bombesin and substance P in normal human thymuses.⁷

Our ultrastructural findings, particularly the presence of desmosomes, confirm the epithelial nature of these immunoreactive cells. Unlike thymic carcinoid tumours, however, which express secretory granules,^{14–17} no secretory granules were found in the cases investigated. This could be explained by recent data supporting the existence in some thymic epithelial cells of a secretory system different from the usual neuroendocrine model, based on "clear

vacuoles" rather than on classic secretory granules.¹⁸ It should be noted that β -endorphin, (Leu)-, and (Met)-enkephalin could be present in a given cell as part of larger precursor molecules such as pro-opiomelanocortin or preproenkephalin. Therefore, we cannot exclude the possibility that the antibodies used, although specific, are actually detecting neuropeptides as a part of their precursor molecules. The pattern of immunoreactivity in each thymoma sample with antisera against various peptide families seemed to vary in terms of the numbers and distribution of positive cells. Double labelling experiments will be needed to show the presence of or exclude the coexpression of different peptides in the same tumour cell.

The presence in normal thymuses and in thymomas of cells immunoreactive for peptides deserves some consideration. Recent studies using a panel of monoclonal antibodies against subsets of thymic epithelial cells have shown that thymomas are composed of epithelial cell populations which often simultaneously express cortical and subcapsular markers in unusual combinations.¹⁹ One possible explanation for these findings is that neoplastic cells in thymomas are derived from a common epithelial stem cell capable of both cortical and subcapsular differentiation. There are many examples of heterogeneity in a number of neoplasias in which the variety of cell types is generated by a common ancestor cell. This has been reported for leukaemia²⁰ and for epithelial tumours.^{19, 21, 22} The occurrence of opioid peptide immunoreactivity has been reported in a few^{23, 24} scattered cancer cells in breast, lung, gastric and uterine cancer. These findings suggest that there may be neurohormonal differentiation of neoplastic stem cells.

The reported influence of neuropeptides on the immune functions²⁵ and their growth promoting activity on several cell types, including mesenchymal and epithelial cells,²⁶ could suggest a possible modulatory role for peptide molecules in the biological behaviour of tumours, including thymomas.

This work was partially supported by grants from ONR and MP (60%). RR is a recipient of a fellowship from Sclavo SpA. We thank Paolo Baldassarri for editorial assistance.

- 1 Levine GD, Rosai J. Thymic hyperplasia and neoplasia: a review of current concepts. *Hum Pathol* 1978;9:495-515.
- 2 Bofill M, Janossy G, Willcox N, Chilosi M, Trejdosiewicz LK, Newsom-Davis J. Microenvironments in the normal thymus and the thymus in myasthenia gravis. *Am J Pathol* 1985;119:462-73.

- 3 Lauriola L, Piantelli M, Carbone A, Dina MA, Scopetta C, Musiani P. Subpopulations of lymphocytes in human thymomas. *Clin Exp Immunol* 1979;37:502-6.
- 4 Mokhtar N, Hsu S-U, Lad RP, Haynes BF, Jaffe ES. Thymoma: lymphoid and epithelial components mirror the phenotype of normal thymus. *Hum Pathol* 1984;15:378-84.
- 5 Moll UM, Lane BL, Robert F, Geenen V, Legros J-J. Abundant occurrence of oxytocin-, vasopressin- and neurophysin-like peptides in epithelial cells. *Histochemistry* 1988;89:385-90.
- 6 Sundler F, Carraways RE, Hakanson R, Alumets J, Dubois MP. Immunoreactive neurotensin and somatostatin in the chicken thymus. *Cell Tissue Res* 1978;194:367-76.
- 7 Piantelli M, Maggiano N, Larocca LM, et al. Neuropeptide-immunoreactive cells in human thymus. *Brain Behaviour and Immunology* 1990 (in press).
- 8 Sternberger LA, Hardy PH Jr, Cuculis JJ, Meyer HG. The unlabelled antibody-enzyme method of immunohistochemistry. Preparation and properties of soluble antigen-antibody complex (horseradish peroxidase-anti horseradish peroxidase) and its use in identification of spirochetes. *J Histochem Cytochem* 1970;18:315-33.
- 9 Hsu SM, Raine L, Fanger H. The use of antiavidin antibody and avidin-biotin-peroxidase complex in immunoperoxidase techniques. *Am J Clin Pathol* 1981;75:816-21.
- 10 Graham RC Jr, Ludholm U, Kartnovsky MJ. Cytochemical demonstration of peroxidase activity with 3-amino 9-ethyl carbazole. *J Histochem Cytochem* 1965;13:150-2.
- 11 Lauriola L, Michetti F, Stolfi VM, Tallini G, Cocchia D. Detection by S-100 immunolabelling of interdigitating reticulum cells in human thymomas. *Virchows Arch (Cell Pathol)* 1984;45:187-95.
- 12 Scopsi L, Wang B-L, Larsson L-I. Non specific immunocytochemical reactions with certain neurohormonal peptides and basic peptide sequences. *J Histochem Cytochem* 1986;34:1469-75.
- 13 Kornstein MJ, Curran WJ, Turrisi AT, Brooks JJ. Cortical versus medullary thymomas: a useful morphologic distinction? *Hum Pathol* 1988;127:1335-9.
- 14 Baker J, Holdaway IM, Jagusch M, Kerr AR, Donald RA, Pullan PT. Ectopic secretion of ACTH and met-enkephalin from a thymic carcinoid. *J Endocrinol Invest* 1982;5:33-7.
- 15 Herbst WM, Kummer W, Hofmann W, Otto H, Heym C. Carcinoid tumors of the thymus. An immunohistochemical study. *Cancer* 1987;60:2465-70.
- 16 Penman E, Wass JAH, Besser GM, Rees LH. Somatostatin secretion by lung and thymic tumours. *Clin Endocrinol* 1980;13:613-20.
- 17 Wick MR, Scheithauer BW. Thymic carcinoid: a histologic, immunohistochemical and ultrastructural study of 12 cases. *Cancer* 1984;53:475-84.
- 18 Nabarra B, Andrianarison I. Pattern of secretion in thymic epithelial cells: ultrastructural studies of the effect of blockage at various levels. *Cell Tissue Res* 1987;249:171-8.
- 19 Willcox N, Schlupe M, Ritter MA, Schuurman HJ, Newsom-Davis J, Christensson B. Myasthenic and non myasthenic thymoma. An expansion of a minor cortical epithelial cell subset? *Am J Pathol* 1987;127:447-60.
- 20 Greaves MF. Target cells, differentiation and clonal evolution in chronic granulocytic leukaemia: a model for understanding the biology of malignancy. In: Shaw MT, ed. *Chronic granulocytic leukemia*. New York: Praeger Publishers, 1982:15-47.
- 21 Andrews PW. Retinoic acid induced neuronal differentiation of a cloned human embryonal carcinoma cell line in vitro. *Dev Biol* 1984;103:285-93.
- 22 Larsson L-I. Regulatory peptides and amines during ontogeny and in non-endocrine cancers: occurrence and possible functional significance. *Progr Histochem Cytochem* 1988a;17:89-111.
- 23 Scopsi L, Balslev E, Br nner N, et al. Immunoreactive opioid peptides in human breast cancer. *Am J Pathol* 1989;134:473-9.
- 24 Larsson L-I. Regulatory peptides and amines during ontogeny and in non-endocrine cancers: occurrence and possible functional significance. *Progr Histochem Cytochem* 1988b;17:157-69.
- 25 Pierce GB, Nakane PK, Martinez-Hernandez A, Ward JM. Ultrastructural comparison of differentiation of stem cells of murine adenocarcinomas of colon and breast with their normal counterparts. *JNCI* 1977;58:1329-45.
- 26 Zachary I, Woll PJ, Rozengurt E. A role for neuropeptides in the control of cell proliferation. *Devel Biol* 1987;124:295-308.