

LETTERS TO THE EDITOR

Primary hepatic vascular leiomyosarcoma of probable portal vein origin

Primary sarcomas of the liver comprise 1-2% of hepatic malignancies and most of these are angiosarcomas. To our knowledge only 15 cases of primary hepatic leiomyosarcoma have been reported,¹ of which only two were vascular leiomyosarcomas.^{2,3} We report a case of vascular leiomyosarcoma of the liver.

A 67 year old woman had been complaining of epigastric and right hypochondrial pain for two years. On examination she had hepatomegaly. An ultrasound scan showed a nodular vascular tumour in the left lobe of the liver and a computed tomogram showed three satellite lesions in the right lobe. All these lesions were enhanced with contrast medium in the manner of a haemangioma. At laparotomy, a large vascular tumour was found in the left lobe of the liver. Small nodules were noted in the right lobe, and a single lesion 0.8 cm in diameter was found in the small bowel mesentery. No lesion, however, was found in the gastrointestinal tract. A palliative left hepatectomy was performed. Her recovery was satisfactory.

The tumour measured 30 × 15 × 10 cm and weighed 1880 g. It was well circumscribed and grey-white in appearance, with a bossellated surface. The cut surfaces had a whorled appearance and vascular spaces were evident at the periphery. The small mesenteric nodule showed similar features. Sections were stained with haematoxylin and

eosin, elastic van Gieson, and Masson's trichrome. In addition, the unlabelled peroxidase anti-peroxidase method was used to detect desmin and vimentin (antisera from Dako Ltd), and small fragments were processed for electron microscopical examination.

The tumour and mesenteric nodule consisted of interlacing fascicles of eosinophilic spindle cells with elongated, blunt ended nuclei, and showed an intricate vascular pattern. There was pronounced nuclear pleomorphism with bizarre tumour giant cells, and numerous mitoses, many of which were abnormal. The mitotic index was 35/10 high power fields. There were areas of necrosis and hyalinisation. A medium sized vein within the tumour showed pleomorphic smooth muscle cells streaming outwards from the vessel walls (figure). Bile ducts were incorporated deep within the tumour. The tumour cells stained red with Masson's trichrome and showed desmin and vimentin positivity; electron microscopical examination showed myofilaments and pinocytotic vesicles, confirming a smooth muscle origin.

The origin of parenchymal leiomyosarcomas has been discussed; most are thought to originate from connective tissue or blood vessels. In the liver the ligamentum teres has been suggested as the origin of most of the reported cases of hepatic leiomyosarcoma.⁴

Vascular leiomyosarcomas are rare. They arise predominantly from larger or medium sized blood vessels, the inferior vena cava accounting for over 75% of these cases. The characteristic features of these tumours include proliferating atypical smooth muscle cells, some streaming out from the media of vessels, and a striking number of neoformed blood vessels of variable size and configuration intermingled among them.

The two cases described in the liver were both of hepatic vein origin, and both presented with the Budd-Chiari syndrome.^{2,3} Our

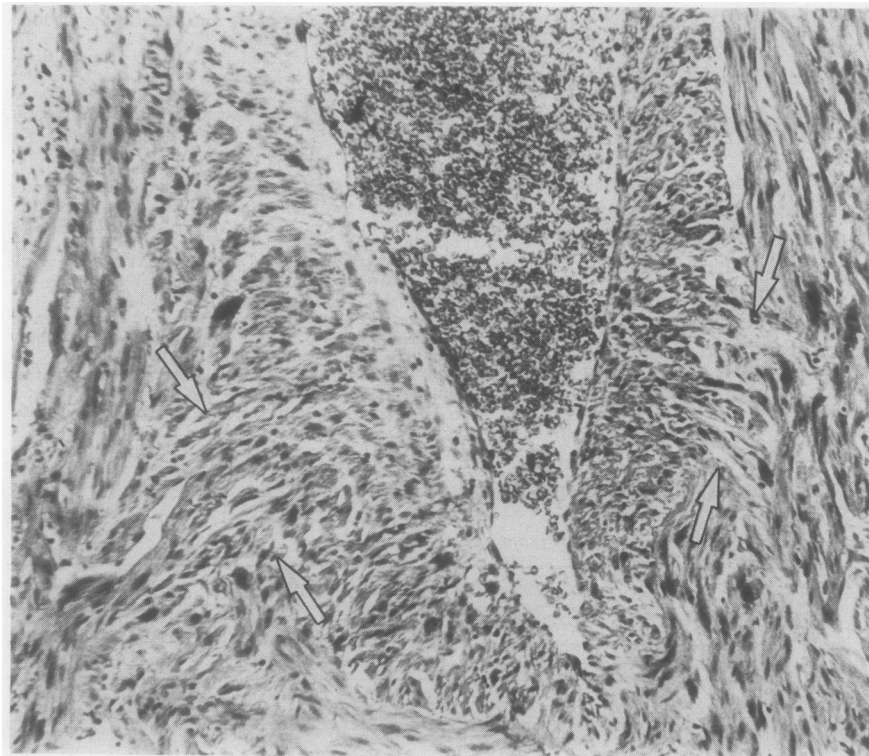
case had no evidence of the Budd-Chiari syndrome. In addition, bile ducts were present, a feature not previously described within hepatic leiomyosarcomas. A medium sized vein showed pleomorphic tumour cells streaming out from the media. The combination of these three features all suggest origin from a portal vein.

In a detailed description of vascular leiomyosarcomas⁷ it was concluded that the mitotic index was the most important pathological feature on which a prognostic evaluation for a vascular leiomyosarcoma could be based. Three of the patients with a mitotic count of greater than 35/10 high power fields had a poor prognosis. Our case had a mitotic index of 35/10 high power fields, an indication of poor prognosis, and metastases were present.

M SUNDARESAN,
SB KELLY,
IS BENJAMIN,
AB AKOSA

Departments of Histopathology and
Hepatobiliary Surgery,
Royal Postgraduate Medical School,
Hammersmith Hospital,
Du Cane Road,
London W12 0HS

- 1 Chen KTK. Hepatic leiomyosarcomas. *J Surg Oncol* 1983;24:325-8.
- 2 Koberle F, Pflieger R. Lebervenengeschwulst mit dem Symptomenbild einer Endophlebitis Obliterans Hepatica. *Wein Arch Inn Med* 1940;34:73-85.
- 3 MacMahon HE, Ball HG. Leiomyosarcomas of the hepatic vein and the Budd-Chiari syndrome. *Gastroenterology* 1971;61:239-43.
- 4 MacSween RNM, Anthony PP, Sheuer PJ. Tumours and tumour like conditions of the liver and biliary tract. *Pathology of the liver*. London: Churchill Livingstone, 1987: 574-645.
- 5 Varela-Duran J, Oliva H, Rosai J. Vascular leiomyosarcoma. *Cancer* 1979;44:1684-91.



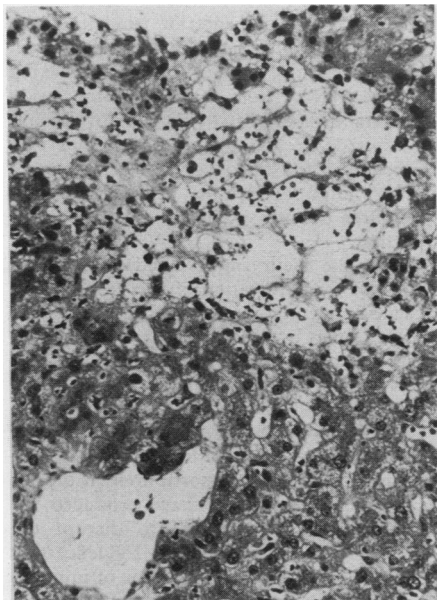
Medium sized vein in the tumour with pleomorphic tumour cells streaming out of the media (arrows).

Peliosis hepatis after liver transplantation

Peliosis hepatis is characterised by blood-filled spaces in the liver. Causes and associations identified to date include steroid hormone treatment, wasting diseases, cancer, human immunodeficiency virus disease and renal transplantation.¹⁻³ We report peliosis in a liver transplant recipient; as far as we are aware, this has not been previously recorded.

Case report

A 25 year old female factory employee developed acute hepatic failure following an overdose of paracetamol. Emergency orthotopic liver transplantation was carried out four days after the overdose. There was mismatching of blood groups (donor blood group A, recipient group O). A protocol baseline liver biopsy specimen taken at the time of revascularisation of the graft showed substantially normal liver. Four days later a second biopsy was performed because of rising serum aspartate transaminase activities. This showed no evidence of cellular rejection. Scattered acidophil bodies and increased numbers of liver cell mitoses were noted. A further biopsy specimen on day 7 showed, in addition to the above changes, portal infiltration, endotheliitis affecting portal venules and minor bile duct changes. The picture was interpreted as cellular rejection.



An irregular cystic area of liver cell loss and haemorrhage (top) is seen near a terminal hepatic venule (below) (haematoxylin and eosin).

Neutrophils and eosinophils were present in moderate numbers in the portal infiltrate in addition to lymphoid cells. Serum enzyme activities remained raised, and a biopsy specimen on day 11 showed continuing features of rejection.

At day 16, a biopsy specimen showed less rejection but some canalicular cholestasis and sinusoidal dilatation. There was a single small haemorrhagic focus in the parenchyma. By day 28, more prominent, cyst-like haemorrhagic foci were present, containing remnants of the reticulin framework (figure). Sinusoidal endothelium seemed to have been partly lost in these areas, but was present elsewhere in the hepatic acini. Features of rejection in the portal tracts were now very mild, and no endothelial lesions were identified in portal venules or terminal hepatic venules (centrilobular veins). Cholestasis persisted. The patient subsequently improved, and no further liver biopsies were performed.

The patient had received no medication in the months before overdose, nor was she taking oral contraceptives. Immediately after admission she received dopamine. After transplantation she was given methyl prednisolone (0.8 mg/kg daily from day 1, changed to prednisolone on day 4), azathioprine (about 1.5 mg/kg daily from day 11), and cyclosporine (10 mg/kg daily from day 13). Mezlocillin and metronidazole were given during the first week, and amphotericin, acyclovir, and ranitidine from day 3. Doses of dextropropoxyphene/paracetamol and dihydrocodeine were given during the first week.

Vascular lesions reported after liver transplantation include endotheliitis as part of cellular (acute) rejection,⁴ and narrowing of arteries and arterioles as part of chronic rejection.⁵ We have observed venous thrombosis leading to the Budd-Chiari syndrome in one of our patients (unpublished observation). To this list must now be added peliosis hepatis. Azathioprine has been implicated after renal transplantation, but in the patients reported² the peliosis has developed months

rather than days after beginning of treatment, although it appeared earlier after treatment with anabolic steroids.¹ We cannot entirely rule out a possible role of drugs, but all the drugs given to our patient are commonly used after transplantation. The pathogenesis of peliosis remains controversial, and venous outflow obstruction, endothelial damage, and liver cell necrosis have been implicated; the presence of reticulin strands in the lesions supports these last two factors.

We suggest that in our patient the blood cysts may have been formed during a process of liver cell loss following endothelial damage. This is usually seen in portal or hepatic veins rather than sinusoids, but it is possible that the unusual location of the damage reflects the mismatching of blood groups between graft donor and recipient.

PJ SCHEUER
LA SCHACHTER
S MATHUR

AK BURROUGHS
K ROLLES
Departments of Histopathology,
Medicine and Surgery, Royal Free Hospital
and School of Medicine,
Pond Street, London NW3 2QG

- 1 Bagheri SA, Boyer JL. Peliosis hepatis associated with androgenic-anabolic steroid therapy. *Ann Intern Med* 1987;81:610-18.
- 2 Degott C, Rueff B, Kveis H, et al. Peliosis hepatis in recipients of renal transplants. *Gut* 1978;19:748-53.
- 3 Haboubi NY, Ali HH, Whitwell HL, Ackrill P. Role of endothelial cell injury in the spectrum of azathioprine-induced liver disease after renal transplant. *Am J Gastroenterol* 1988;83:256-60.
- 4 Snover DC. The pathology of acute rejection. *Transplan Proc* 1986;18:123-7.
- 5 Grond J, Gouw ASH, Poppema S, et al. Chronic rejection in liver transplants: a histopathologic analysis of failed grafts and antecedent serial biopsies. *Transplan Proc* 1986;83:128-35.

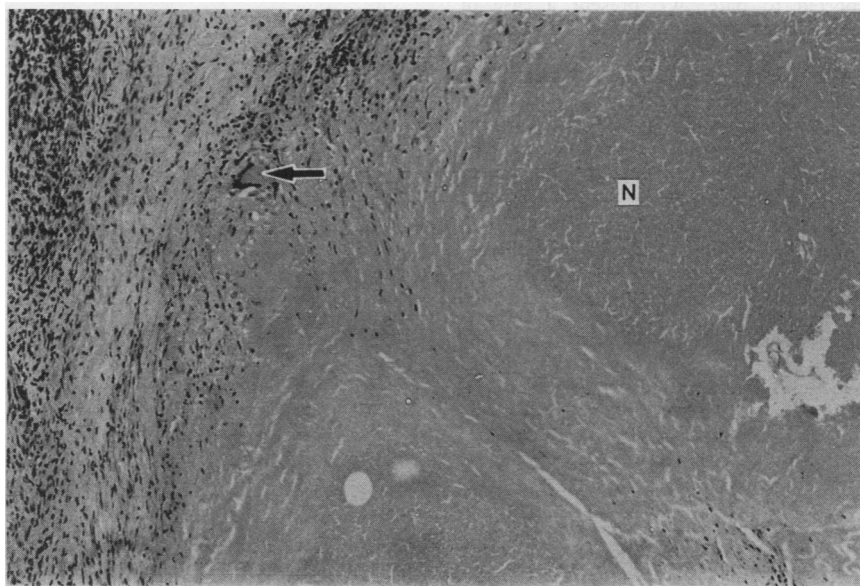
Postoperative necrotising granulomata in the cervix and ovary

Postoperative necrobiotic granulomata in the prostate and bladder have been well documented. In the female genital tract they have, more recently, been described in the fallopian tube,¹ cervix,^{2,3} and ovary.⁴ We have recently seen two such cases. In the first, necrobiotic granulomata were seen in the lower uterine segment scar of a hysterectomy specimen from a 29 year old woman who had had an uncomplicated lower uterine segment Caesarean section six months previously. In the second case, similar granulomata were present in the right ovary of a 39 year old woman who had undergone a right ovarian wedge biopsy 18 months earlier at the time of bilateral salpingectomy and left oophorectomy for lower abdominal pain. Both patients had no clinical or laboratory evidence of tuberculosis, sarcoidosis, rheumatoid arthritis, parasitic or venereal disease.

The granulomata in both cases were of similar appearance (figure). They were small in size with brightly eosinophilic staining central areas of fibrinoid necrosis around which were well defined zones of palisaded

histiocytes admixed with inflammatory cells, including plasma cells, lymphocytes, and occasional eosinophils. A few Langhans' type giant cells were also present. No birefringent material was identified in either case and staining with silver methenamine, Ziehl Neelsen, periodic acid Schiff and Gram stains was negative.

The pathogenesis of such lesions has not been well defined. No cases have so far been described in which there has not been preceding diathermy or surgery, or both, at the same site. Diathermy is particularly associated with the subsequent development of necrobiotic granulomata. The primary event may be that of traumatic tissue damage. Using x ray energy dispersive analysis, Spagnolo *et al* showed the presence of sulphur peaks in the granulomata of three out of four cases examined, but not in bladder tissue remote from the granulomata.⁵ They concluded that sulphur may have been released from damaged collagen and elastin which are rich in disulphide bands. Such damage would create tissue "foreign" to the host, thus stimulating an immune reaction of which the hypersensitivity response may at least play a part. That such granulomata are not com-



Granuloma with central area of necrosis (N) surrounded by histiocytes, lymphocytes, and occasional giant cells (arrow) (haematoxylin and eosin).