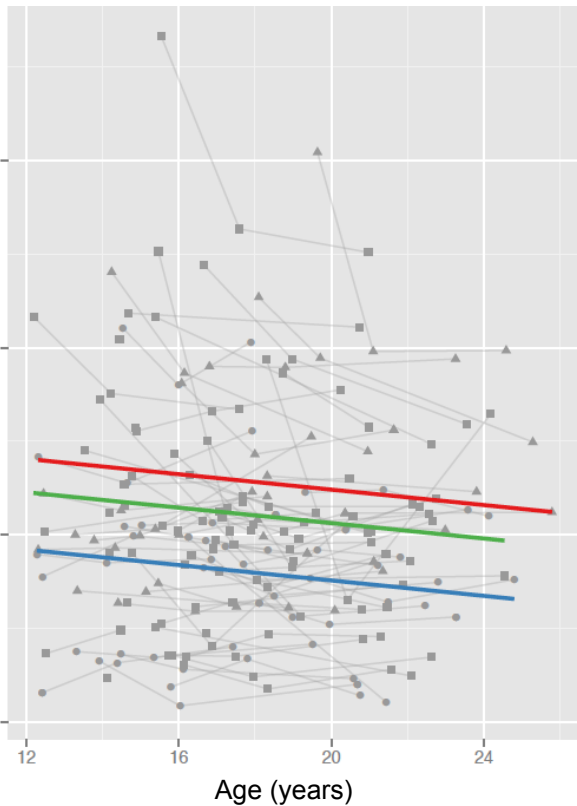
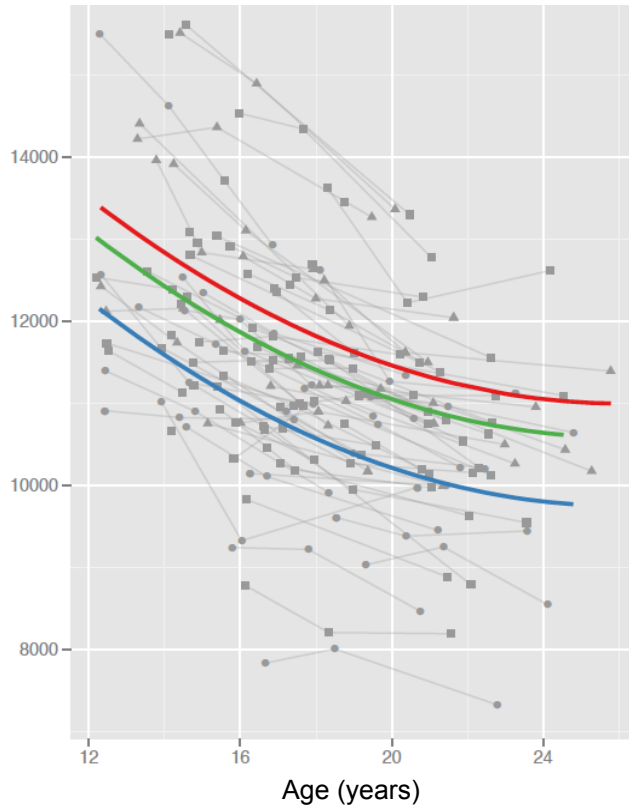


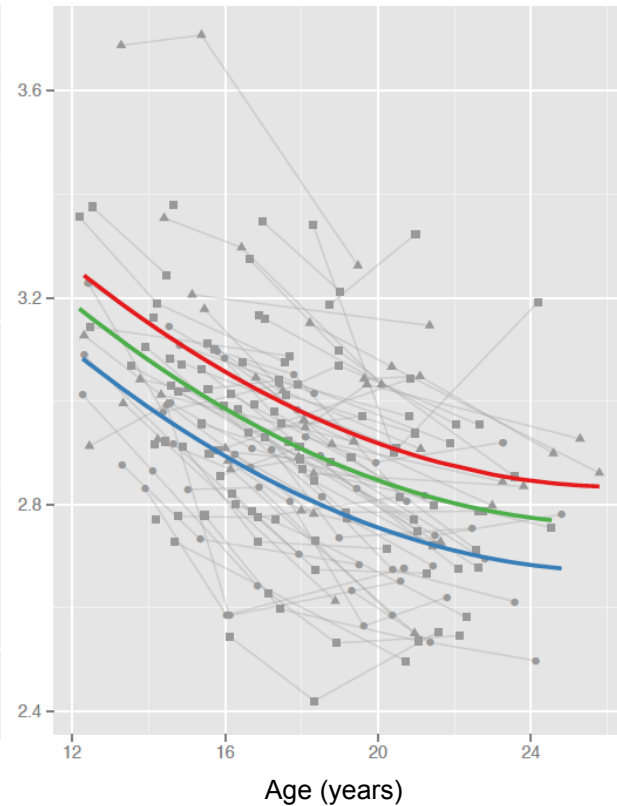
Corpus callosum – mid anterior region (volume)



Left precuneus (volume)



Inferior Frontal Gyrus - Pars Triangularis (cortical thickness)



- Non-resilient individuals
- Resilient individuals
- Typically developing controls