

# CHEST LEADS IN CLINICAL ELECTRO-CARDIOGRAPHY

BY

PAUL WOOD AND A. SELZER †

*(From the British Postgraduate Medical School, Hammersmith Hospital, and the National Hospital for Diseases of the Heart, London.)*

In a previous communication Sorsky and Wood (1937) presented the normal appearances of chest lead electrocardiograms, paying particular attention to normal variations and to the position of the proximal electrode. As the question of standardizing the technique for chest leads was then under consideration by the Cardiac Society of Great Britain and Ireland and the American Heart Association, further work was held up pending their conclusions, which have now been published (1938). On the question of polarity it was agreed that the galvanometer connections should be so arranged that relative positivity of the proximal electrode yields an upward deflection on the electrocardiogram. By lead IV is meant a chest lead in which the proximal electrode is placed upon the apex beat. When this is paired with the right arm it is called lead IV R, and when it is paired with the left leg it is called lead IV F. In all our work we have connected the proximal electrode to the left arm terminal, so that lead IV R is obtained by setting the lead selector dial on the electrocardiograph to lead I, and lead IV F by setting this dial to lead III, after interchanging the terminals in order to correct the polarity.

In our previous work on 150 normal controls, our description of the normal variations of the chest lead electrocardiogram was in terms of the opposite polarity to that now accepted, and based on chest leads paired with the left leg. It is now necessary to refer to our records of chest leads paired with the right arm, in which the accepted polarity was obtained. From an analysis of these electrocardiograms we may present the normal appearances of lead IV R as follows :

1. The P wave is upright and averages 0.14 mv. in amplitude, with a maximum of 0.25 mv.
2. A Q wave is present in 22 per cent. and averages 0.15 mv. in amplitude with a maximum of 0.5 mv.
3. The main QRS deflection is upright and is never monophasic. R is very tall and S averages 0.75 mv.
4. The RS-T segment usually lies at the iso-potential level, but it may be elevated to a maximum of 0.1 mv., or rarely it may be slightly depressed.

† Received August 26, 1938.

5. The T wave is always upright and averages 0.7 mv. in amplitude, ranging between 0.3 and 1.4 mv.

Lead IV F is similar except that the P wave is usually diphasic or inverted and is often very small. Typical records are shown in Fig. 1 (A and B).

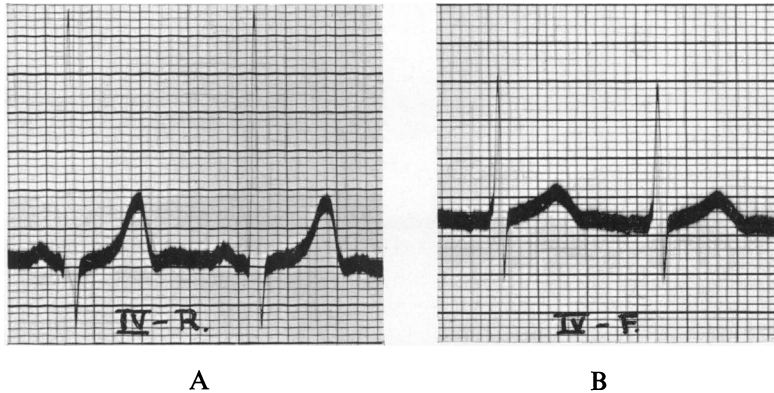


FIG. 1.—Normal chest-lead electrocardiograms. (A) Lead IV R. (B) Lead IV F.

In addition to leads IV R and F we have studied four other chest leads : (1) the left pectoral—right arm lead ; (2) the left pectoral—left leg lead ; (3) the right pectoral—right arm lead ; (4) the right pectoral—left leg lead. In the right pectoral leads the proximal electrode was placed in the fourth intercostal space at the right border of the sternum ; in the left pectoral leads it was placed midway between this point and the apex beat \* (see Fig. 2).

In normal controls it was found that in the apical leads the R deflection dominated the QRS complex, but that shifting the proximal electrode to the right favoured the S deflection, so that in the left pectoral leads R and S were more or less of equal amplitude, and in the right pectoral leads S was the dominant deflection. This phenomenon is illustrated in Fig. 3A, and was found in 75 per cent. of the controls when the proximal electrode was paired with the right arm, and in 95 per cent. when the proximal electrode was paired with the left leg.

The effect upon the T wave of shifting the proximal electrode to the right differed according to the distal electrode employed. When the right arm was used the T wave remained upright even in the right pectoral lead. But when the left leg was used the T wave often became inverted. Thus in the left pectoral—left leg lead the T wave was inverted in 21 per cent. of normal children and occasionally in slim young adults, and in the right pectoral—left leg lead it was inverted in 65 per cent. of normal children and in 58 per cent. of normal adults (see Table I). An electrocardiogram showing inversion of the T waves in the left and right pectoral—left leg leads in a normal child is shown in Fig. 3B.

\* In the terminology recommended by the American Heart Association, our right pectoral—right arm lead would be called lead CR 1, and our left pectoral—right arm lead, though it has no exact counterpart, corresponds roughly to lead CR 3.

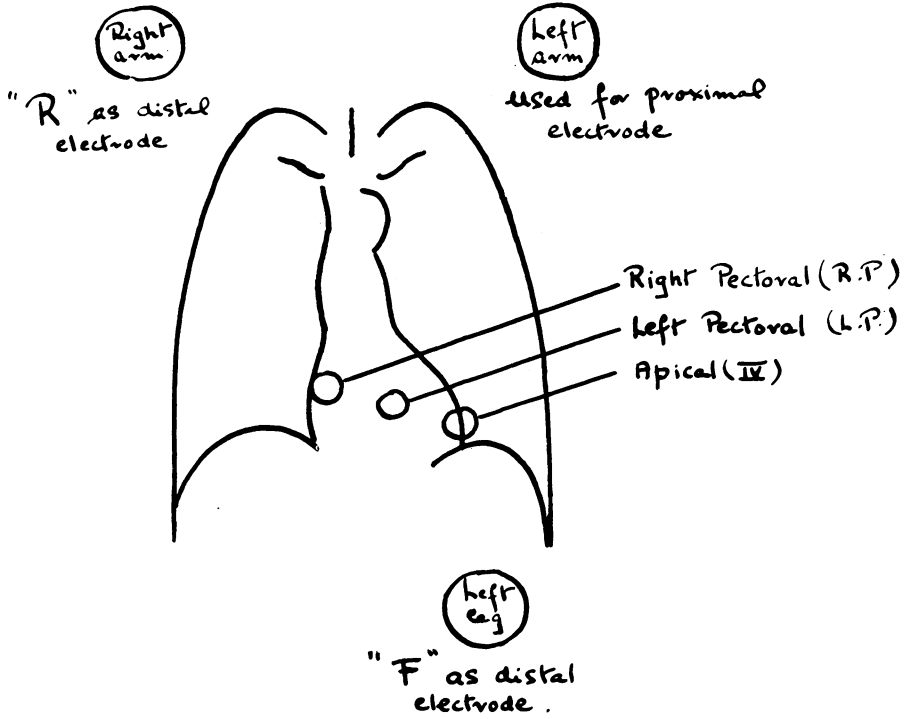


FIG. 2.—Diagram showing positions of the proximal electrode in relation to the underlying heart.

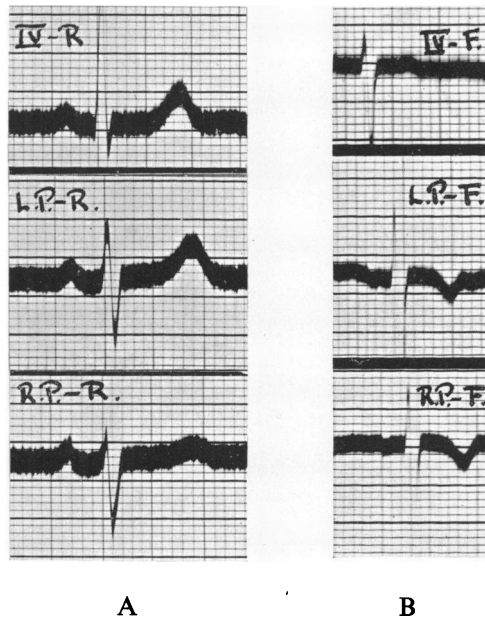


FIG. 3.—Normal chest leads showing the behaviour of the QRS complex (A), and of the T wave in a child (B), as the proximal electrode is shifted from the apical (top) to the left pectoral (middle) and to the right pectoral (bottom) position.

TABLE I  
 INVERSION of the T WAVES in PECTORAL LEADS  
 PAIRED WITH THE LEFT LEG

	LEADS		
	IV-F	L.P.-F.	R.P.-F
CHILDREN	RARE	21 %	65 %
ADULTS	NIL	RARE	58 %

The present report deals with the chest lead electrocardiograms obtained from 314 patients selected for different purposes. No case was included in which the diagnosis was in doubt. In the majority nine tracings were taken, three with limb leads and six with chest leads. Serial records were obtained in about a third of the cases, particularly in those which we thought might show transient changes. Many graphs were discarded because of uncertainty of diagnosis or because of mixed etiological factors. The total number of chest lead tracings taken has been estimated at 3,000, excluding normal controls. The object of the work was twofold : to determine the best distal electrode ; and to assess the value of multiple chest leads. This necessitated a wide investigation into the value of chest leads in general and in all types of heart disease. The material is analysed in Table II.

TABLE II  
 MATERIAL  
 314 SELECTED CASES

ACTIVE RHEUMATIC CARDITIS	30
PERICARDITIS	7
LEFT VENTRICULAR ENLARGEMENT	120
CARDIAC DISPLACEMENT	12
RIGHT VENTRICULAR ENLARGEMENT	50
BUNDLE BRANCH BLOCK	20
DIGITALIS EFFECT	15
MYOCARDIAL INFARCTION	33
ANGINA PECTORIS	27

Cases of thyrotoxicosis, bacterial endocarditis, and of congenital heart disease without cardiac enlargement produced no special electrocardiographic changes with limb or with chest leads, and have not been included in this series.

Cases of aortic valvular disease of any etiology have been grouped with cases of hypertensive heart disease under the heading of left ventricular enlargement if that was present, and cases of mitral stenosis, pulmonary stenosis, and cor pulmonale have been grouped together under the heading of right ventricular enlargement unless there was evidence to the contrary. We also studied thirty cases of severe anæmia, five of myxoedema, and one case of toxic myocarditis from pneumonia. Chest leads proved of no help in the diagnosis of these conditions, the changes in both limb leads and chest leads being of a similar order.

#### RHEUMATIC CARDITIS

Electrocardiographic evidence of rheumatic carditis is more or less confined to prolongation of the P-R interval, to nodal rhythm, heart block, and to bundle branch block, i.e. to conductive defects. Alterations in the RS-T segment or in the T wave in limb lead electrocardiograms are usually due to pericarditis. It has been stated, however, that changes in the T wave may occur with chest leads. Thus Levy and Bruenn (1935) found frequent alterations in the direction and voltage of the T wave in serial chest lead records in cases of rheumatic carditis. Their results have already been criticized (Sorsky and Wood, 1937) on the grounds that normal children frequently show reversal of the T wave in the lead which they used. Robinow, Katz, and Bohning (1936) made a more careful study of cases of rheumatic carditis, checking their findings against a group of normal controls, and they concluded that reversal of the T wave in chest leads was more common in children with rheumatic carditis than in normal children.

It must be remembered that reversal of the T wave is found in the left pectoral—left leg lead in 21 per cent. of normal children, and that the T wave is diphasic in this lead in another 18 per cent. (Sorsky and Wood, 1937). We wish to emphasize the fact that such reversal of the T wave rarely occurs if the proximal electrode is paired with the right arm, or if it is placed on the apex beat and not within it.

Bearing these facts in mind we have analysed the chest-lead electrocardiograms of thirty cases of active rheumatic carditis, excluding those with pericarditis. In many serial records were obtained.

The QRS complex was always normal. The RS-T segment did not deviate from the iso-potential level. There were, however, changes in the direction of the T wave in some instances. When the proximal electrode was paired with the right arm the T wave was inverted in three cases in the apical lead, in three cases in the left pectoral lead, and in ten cases in the right pectoral lead ; when the proximal electrode was paired with the left leg the T wave was inverted in five instances in the apical lead, in ten instances in the left pectoral lead, and in twenty in the right pectoral lead. These figures are expressed per cent. in Table III. If the T wave was inverted in the apical or in the left pectoral lead, it was also inverted, and usually more so, when the proximal electrode was shifted to the right. This rule is always obeyed by normal controls, and it will

be shown later that it also holds good for cases with right ventricular stress or enlargement. The above figures show that the T wave is more often inverted in children with rheumatic carditis than in normal children. When the proximal electrode is paired with the right arm inversion of the T wave is more significant though less common than when it is paired with the left leg.

It is concluded that chest leads may be of value as an aid in the diagnosis of active rheumatic carditis ; that this value is enhanced if the proximal electrode is paired with the right arm, and is reduced if it is paired with the left leg ; that the changes consist of inversion of the T wave, and occur least in the apical lead and most frequently in the right pectoral lead ; that if there is inversion of the T wave in any lead there is usually less inversion if the proximal electrode is shifted to the left and more inversion if it is shifted to the right ; and finally that, as will be shown subsequently, these changes are similar to those produced by stress or enlargement of the right ventricle from any cause, so that it is possible that the changes of rheumatic carditis merely represent right ventricular stress.

TABLE III  
INVERSION of the T WAVE  
IN CASES of RHEUMATIC CARDITIS

CHEST LEAD	R.	F.
IV	10 %	16.6 %
LEFT PECTORAL	10 %	33.3 %
RIGHT PECTORAL	33.3 %	66.6 %

#### PERICARDITIS

Wood (1937) has recently described the changes in limb lead electrocardiograms in cases of pericarditis as being of a  $T_2$  pattern, both the early elevation of the RS-T segment and the later inversion of the T wave being maximum in lead II.

Vander Veer and Norris (1937) showed illustrations of chest lead tracings in four cases of pericarditis which exhibited typical changes of a  $T_2$  pattern in serial limb leads. For some reason these chest lead tracings were quite normal, and the authors concluded that the electrocardiographic changes of pericarditis could be distinguished from those of myocardial infarction by the fact that the former did not occur in chest leads. At the time of their publication we knew that this conclusion was incorrect, and since then Bellet and McMillan (1938) have reported marked changes in chest leads in cases of pericarditis. Using the old polarity they found initial depression of the RS-T segment and later reversal of the T wave. These changes often lasted longer than those in the limb leads. In some cases they found that the abnormality in the chest lead

only appeared when the proximal electrode was placed over the area of pericardial friction.

We used chest leads in seven cases of pericarditis, six of which exhibited limb lead changes of the  $T_2$  pattern. Two were rheumatic, two malignant, on tuberculous, one infective, and one was a case of chronic constrictive pericarditis. An effusion was present in five of them. Only one showed elevation of the RS-T segment in the early phase in limb leads, and this elevation was more evident in the chest leads. Inversion of the T wave occurred in all cases in the apical and in the left pectoral leads, and usually in the right pectoral leads as well, and were equally evident with either distal electrode. Of the seven cases, two came to autopsy and two were chronic, so that the changes during the period of recovery were only studied in three; limb leads were normal in one, and inverted T waves persisted longer in chest than in limb leads in the other two. The degree of T wave inversion was greater in chest leads, and the form of the QRS complex was always normal. These facts are illustrated in Figs. 4 and 5.

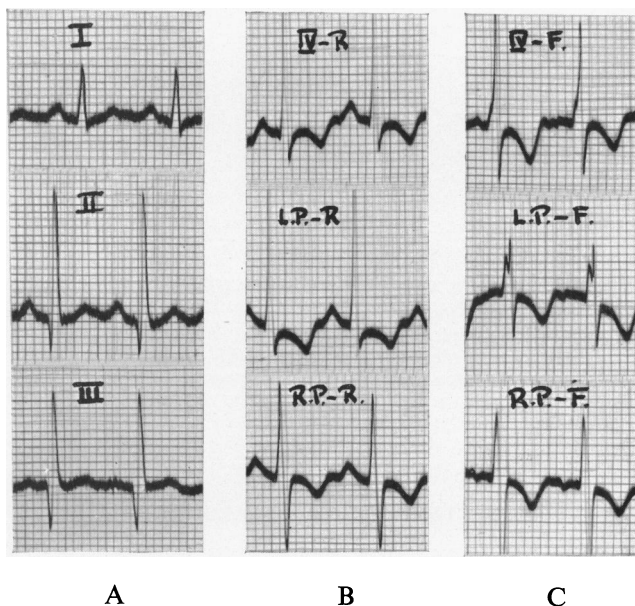


FIG. 4.—Electrocardiograms from a case of rheumatic pericarditis with effusion, showing normal limb leads (A), and inversion of the T wave in all chest leads whether paired with the right arm (B), or with the left leg (C).

It is concluded that in cases of pericarditis changes in the RS-T segment and in the T wave are well shown in chest leads; that these changes may last longer than the changes in limb leads, and that they may occur in association with normal limb leads. Chest leads may therefore be of value. Multiple leads may be useful to distinguish pericarditis from rheumatic carditis, for in the former the right pectoral lead may be normal, whereas in the latter if the T wave is inverted in the apical or in the left pectoral lead it will also be

inverted in the right pectoral lead. To distinguish pericarditis from anterior myocardial infarction attention should be paid to the QRS complex rather than to the T wave. For the distal electrode we prefer the right arm in children, but the left leg is equally suitable in adults.

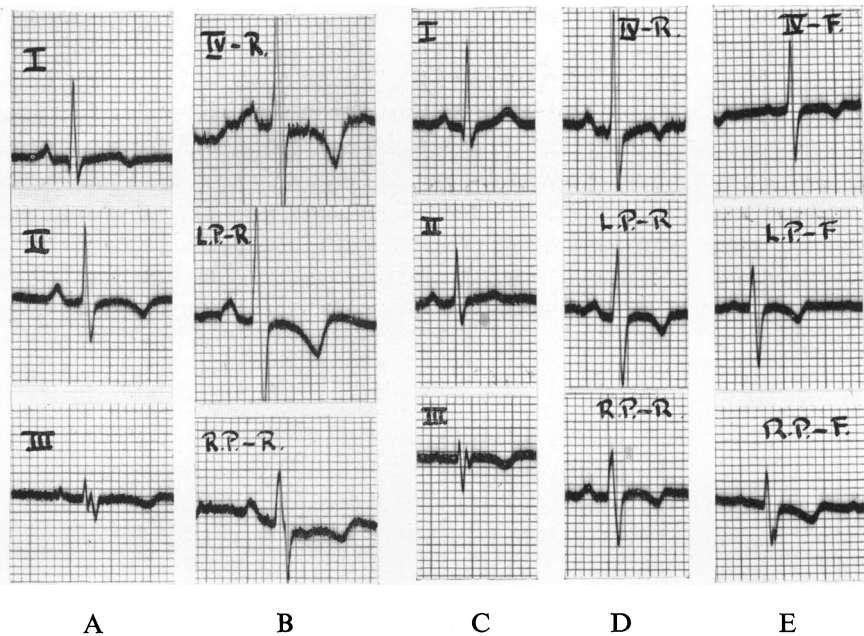


FIG. 5.—Electrocardiograms from a case of rheumatic pericarditis without effusion, showing how changes in chest leads may outlast those in limb leads.

- (A) Limb leads showing a typical  $T_2$  pattern.
- (B) Chest leads paired with the right arm (same date).
- (C) Limb leads ten weeks later showing normal T waves.
- (D) Chest leads paired with the right arm (same date as C).
- (E) Chest leads paired with the left leg (same date as C).

#### LEFT VENTRICULAR ENLARGEMENT

There have been but few reports on the appearance of chest lead electrocardiograms in cases of left ventricular enlargement. Van Nieuwenhuizen and Hartog (1937b), using a left pectoral—left leg lead, found that there was a decrease in voltage of the R wave and an increase in voltage of the S wave in cases of hypertensive heart disease, so that R often measured less than 2 mm. and S more than 17 mm. In some cases they found absence of the R wave altogether. (To avoid confusion their terminology has been translated into the current one). Their left pectoral lead was taken from a fixed point on the chest wall close to the left border of the sternum, and was therefore very far to the right of the apex beat in cases with considerable left ventricular enlargement.

Hecht (1936), employing Wilson's neutral electrode (Wilson and others, 1934d), considered that inversion of the T wave in the apical lead in cases with



enlargement of the left ventricle indicated serious damage to the myocardium. His proximal electrode was placed in the anterior axillary line.

Roth (1937), using the old polarity, found reversal of the T wave in lead IV F, but not in the left pectoral—left leg lead, in some cases of hypertensive heart disease in which the apex beat was considerably displaced to the left. He concluded that lead IV F was simply lead III in such cases, and that the left pectoral lead was therefore the better chest lead. We find this argument a little difficult to follow. If the proximal electrode is placed over a heaving cardiac impulse in the anterior axillary line or thereabouts, the electrocardiogram so obtained cannot be very different from one obtained by a direct lead from the surface of the apex of the left ventricle (Wilson and others, 1932 b). Considering the position of the left ventricle in these cases it is likely that similar changes of potential will be found in the left arm, which because of its proximity will dominate the limb leads. In short, in such cases, lead III (and lead I) are almost semi-direct leads, the left arm acting almost as a proximal electrode. We fail to see that this detracts from the importance of lead IV, except that by examining the limb leads we might predict the appearance of lead IV.

Holzmann (1937), using an anterior-posterior lead and the new polarity, showed many examples of very small R waves and deep S waves in cases with considerable enlargement of the left ventricle. The T wave remained upright, for the proximal electrode was close to the sternum.

We have studied the chest lead electrocardiograms in 120 cases of left ventricular enlargement. The behaviour of the QRS complex was interesting. In the apical leads R was usually very tall, but in the left pectoral leads it often measured less than 2 mm. in height, and in the right pectoral leads it was even less conspicuous. In the right pectoral—right arm lead S was the dominant deflection in 97 per cent. of the cases compared with the 75 per cent. figure for normal controls. A monophasic downward deflection was rare in the left pectoral leads, occurring in two cases of syphilitic aortic incompetence and in one case of hypertensive heart disease, but in the right pectoral leads it occurred in three cases of syphilitic aortic incompetence and in four cases of hypertensive heart disease. There was no evidence of myocardial infarction in any of these cases.

Our findings with regard to the QRS complex are therefore in agreement with those of Van Nieuwenhuizen and Hartog (1937b), and with those of Holzmann (1937), and we conclude that very small R waves in the left or right pectoral leads cannot be accepted as evidence of myocardial infarction in cases with left ventricular enlargement, and that, in the presence of the latter, even monophasic downward deflections in the left pectoral lead must be interpreted with caution.

In studying the behaviour of the RS-T segment and of the T wave, we divided the cases into three groups according to the degree of enlargement of the left ventricle. This was always estimated radiologically by the same observer, P. W., throughout this work.

Group I consisted of fifty cases of slight left ventricular enlargement, most from hypertension, a few from aortic valvular disease. In some there was mild

to moderate breathlessness on exertion, and in others there were no cardiac symptoms. Limb leads showed left axis deviation with an upright T wave in lead I. Chest leads paired with the right arm yielded normal curves in every instance, wherever the proximal electrode. Chest leads paired with the left leg, however, showed a decrease in the incidence of an inverted T wave in the right pectoral lead from 58 per cent. in the controls to 14 per cent.

Group II consisted of fifteen cases with moderate left ventricular enlargement, mostly from hypertension. Effort was more limited by dyspnoea than in the previous group, but there was no orthopnoea or other evidence of left ventricular failure. Limb lead electrocardiograms showed left axis deviation with an upright T wave in lead I, some with and some without depression of the RS-T segment in that lead. In the former cases leads IV R and F showed a similar depression of the RS-T segment. Otherwise, and apart from the QRS changes previously mentioned, chest leads paired with the right arm were normal, but chest leads paired with the left leg showed an even lower incidence (one case only) of inversion of the T wave in the right pectoral lead than occurred in group I.

In group III there were fifty-five cases with considerable left ventricular enlargement, thirty-nine from hypertension, fifteen from aortic incompetence (mostly syphilitic), and one from aortic stenosis. Most had some evidence of left ventricular failure, and some had right ventricular failure also. Cases with angina pectoris or with a history of myocardial infarction were excluded. With limb leads there was inversion of the T wave in lead I only in thirty-three instances, in leads I and II but not in lead III in eleven instances, and in all three leads in five. In nearly all of these there was associated depression of the RS-T segment in the lead or leads in which the T wave was inverted. Depression of the RS-T segment in lead I without inversion of the T wave occurred in five of the remaining six cases, and a flat T wave in lead I was found in the sixth. Left axis deviation was always present except in those cases with inversion of the T wave in all leads.

With chest leads there was inversion of the T wave with associated depression of the RS-T segment in the apical leads alone in twenty-five instances, in both the apical and left pectoral leads but not in the right pectoral leads in three instances, and in all leads in two. When inversion of the T wave was confined to lead I in the limb leads, it was also confined to leads IV R and F in the chest leads ; when it occurred in leads I and II, it was found in three out of eleven such cases in both the apical and left pectoral leads ; and when it happened in all three limb leads it also happened in two out of five such cases in all three chest leads. These findings are illustrated in Fig. 6. When depression of the RS-T segment in lead I was the only change in limb leads, a similar depression of the RS-T segment was found in leads IV R and F but not in the other chest leads. The majority of cases in group III exhibited slight elevation of the RS-T segment in the pectoral leads, and it was this group especially which showed the small R waves and the large S waves previously described. Finally, it should be noted that of the fifty-five cases in this group only two showed inversion of the

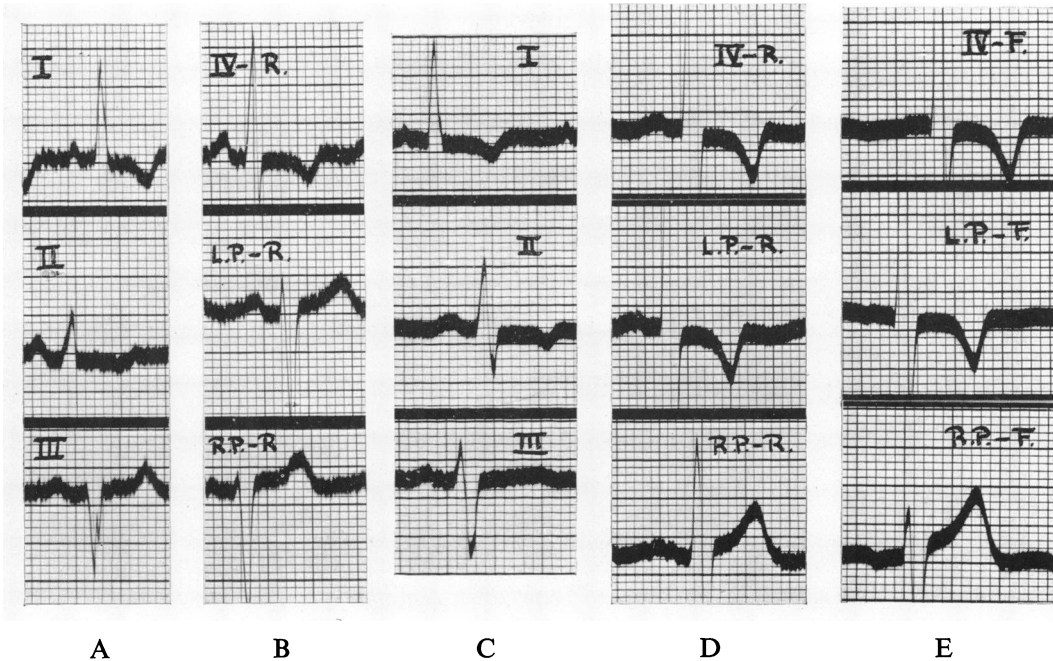


FIG. 6.—Electrocardiograms from two cases of hypertension with considerable enlargement of the left ventricle.

A and B. Limb leads (A), and chest leads paired with the right arm (B), in a case in which inversion of the T wave is confined to leads I and IV.

C, D and E. Limb leads (C), and chest leads paired with the right arm (D), and with the leg (E), in a case in which inversion of the T wave has extended to lead II and to the left pectoral leads in addition to leads I and IV.

T wave in the right pectoral—left leg lead, and in these two the T wave was inverted in every other lead including the three limb leads.

From a consideration of the facts which we have presented certain points arise which merit further attention.

First, the facts summarized in Table IV show that with progressive enlargement of the left ventricle the incidence of inversion of the T wave in the right pectoral—left leg lead fell from the normal figure of 58 per cent. to nil (excluding rare cases in which the T wave was inverted in all leads). In other words, if the left ventricle was significantly enlarged the T wave was upright in the right pectoral—left leg lead; if the T wave was inverted in this lead, the left ventricle was not significantly enlarged. We wondered whether displaced hearts due to a high diaphragm, which gave rise to left axis deviation in the standard leads, would produce an upright or an inverted T wave in this lead. To determine the answer to this question we studied normal pregnant women just before labour. We found twelve cases with left axis deviation in the limb leads. Of these, ten showed inversion of the T wave in the right pectoral—left leg lead, and two showed a diphasic T wave. In addition the T wave was inverted in four instances in the left pectoral—left leg lead, and in two instances in lead IV F. We conclude that in the right pectoral—left leg lead we have a means of distin-

TABLE IV  
LEFT VENTRICULAR ENLARGEMENT

INVERSION OF THE T WAVE IN THE RIGHT PECTORAL—LEFT LEG LEAD

	No. of cases	Percentage with inverted T wave
NORMAL ADULTS	50	58 %
LEFT VENTRICLE +	50	14 %
LEFT VENTRICLE ++	15	7 %
LEFT VENTRICLE +++	55	0 %*

\* Excluding two cases with inverted T waves  
in all leads

guishing enlargement of the left ventricle from displacement of the heart due to a high diaphragm. If the T wave is upright no inference can be drawn, but if it is inverted significant enlargement of the left ventricle is unlikely. We have found this rule of value in attempting to assess the size of the left ventricle in cases of obesity. When the proximal electrode is paired with the right arm the results are far less helpful because the T wave is very rarely inverted in this lead. Electrocardiograms showing the absence of significant left ventricular enlargement in a case of obesity with hypertension are illustrated in Fig. 7.

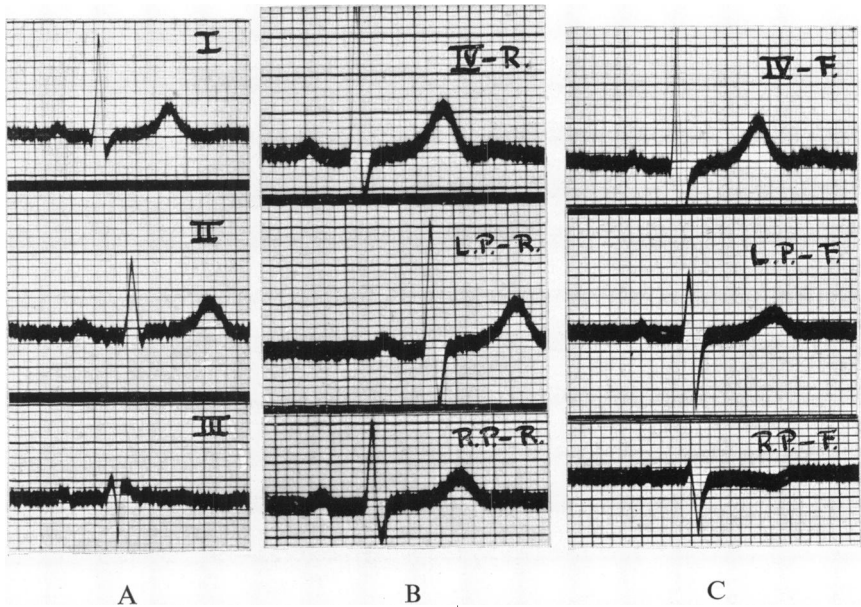


FIG. 7.—Limb leads (A), and chest leads paired with the right arm (B), and with the left leg (C), in a case of obesity. Note the inverted T wave in the right pectoral—left leg lead.

Secondly, the point arises as to why the T wave should be inverted in lead IV in only eighteen out of thirty-three cases of considerable left ventricular enlargement in which it was inverted in lead I. On re-examining these records we found that when the T wave was inverted in lead IV the R deflection dominated the QRS complex, whereas when the T wave was upright the S deflection dominated. This was clear evidence that the proximal electrode had been placed within the apex beat in these latter cases, so that the leads were more left pectoral than apical. We have since re-investigated a few of these patients and have found that great care had to be taken in placing the proximal electrode, but that when this was placed truly upon the apex beat the T wave became inverted and the R deflection dominated the QRS complex as expected.

Thirdly, the facts show that in cases of left ventricular enlargement if the T wave is inverted in any chest lead, it is also inverted (and usually more so) in leads in which the proximal electrode is shifted to the left. This is the reverse of what happens in normal children and in cases of rheumatic carditis, and, as will be shown subsequently, in cases of right ventricular enlargement.

Fourthly, it is evident that depression of the RS-T segment and inversion of the T wave in lead IV R or F do not indicate myocardial infarction in the presence of sufficient enlargement of the left ventricle.

*Summary of the effects of left ventricular enlargement on the chest lead electrocardiogram*

1. Though the R deflection is often exceedingly tall in leads IV R and F, there is an increased incidence of small R waves and deep S waves in the pectoral leads.
2. With progressive enlargement of the left ventricle the incidence of inversion of the T wave in the right pectoral—left leg lead falls steadily from 58 per cent. in the controls to nil in the cases with considerable enlargement. Patients with cardiac displacement due to a high diaphragm usually exhibit an inverted T wave in this lead.
3. In the lesser degrees of left ventricular enlargement the RS-T segment and the T wave are normal in the apical and left pectoral leads.
4. In the greater degrees of left ventricular enlargement the RS-T segment is depressed and the T wave is inverted in leads IV R and F, and occasionally in the left pectoral leads.

#### RIGHT VENTRICULAR ENLARGEMENT

Groedel (1934) maintains that deformities in the QRS complex and inversion of the T wave in right ventricular semi-direct leads indicate disease of the right ventricle. Hecht (1936), using Wilson's neutral distal electrode, found that right ventricular enlargement caused inversion of the T wave in the right pectoral lead, and sometimes a large Q wave.

To determine the effect of right ventricular enlargement upon the chest

lead curves we investigated thirty-five cases of mitral stenosis, six of chronic cor pulmonale, five of acute cor pulmonale following pulmonary embolism, and four of congenital pulmonary stenosis, making a total of fifty cases with right ventricular enlargement or stress. Patients with aortic valvular disease or with hypertension in addition were excluded.

The QRS complex was usually normal in the apical and in the left pectoral leads, but in the right pectoral leads the main QRS deflection was upright in about a third of the cases, rather more than a third when the proximal electrode was paired with the right arm, and rather less than a third when it was paired with the left leg. Pronounced notching of the R wave was sometimes observed associated with delay in the onset of the intrinsic downward deflection, and occasionally there was prominent Q wave, both these abnormalities being confined to the right pectoral leads. These features are illustrated in Fig. 8.

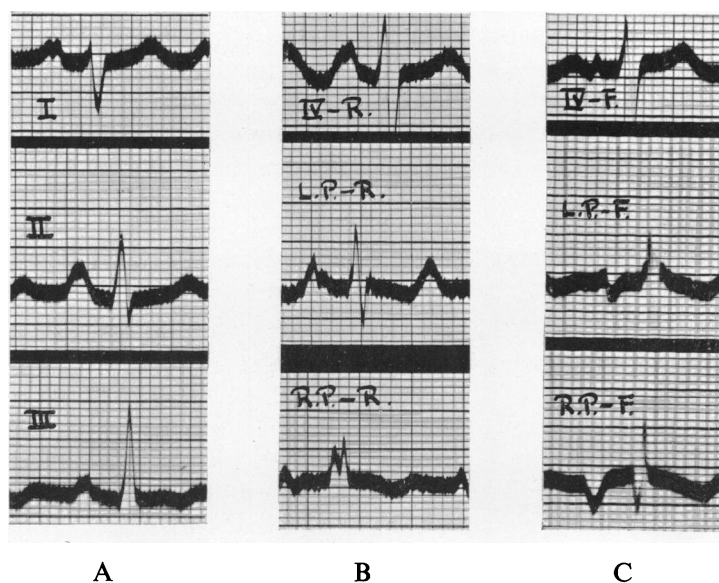


FIG. 8.—Limb leads (A), and chest leads paired with the right arm (B), and with the left leg (C), in a case of mitral stenosis with enlargement of the right ventricle. Note the absence of S waves and the inverted T waves in the right pectoral leads, and the Q wave in the right pectoral—left leg lead.

The frequency of inversion of the T wave in leads paired with the left leg is shown in Table V. (The incidence was somewhat lower in leads paired with the right arm.) It was found in 20 per cent. in lead IV, in 35 per cent. in the left pectoral lead, and in 75 per cent. in the right pectoral lead. As in normal children and as in cases of rheumatic carditis, if the T wave was inverted in any lead it was also inverted, and usually more so, when the proximal electrode was shifted to the right. In table V the incidence of inversion of the T wave in right ventricular enlargement is compared with that in normal adults, in normal children and in rheumatic carditis. This comparison suggests that the cause of inversion of the T wave in normal children and in rheumatic carditis is relative

TABLE V  
**RIGHT VENTRICULAR ENLARGEMENT**

INVERSION of the T WAVE in LEFT LEG paired LEADS

	LEAD		
	TV-F	L.P.-F	R.P.-F
NORMAL ADULTS	0 %	2 %	58 %
NORMAL CHILDREN	0 %	21 %	65 %
RHEUMATIC CARDITIS	16.6 %	33.3 %	66.6 %
R.V. ENLARGEMENT	20 %	35 %	75 %

right ventricular dominance, and this finds support in the fact that increased left ventricular dominance has an opposite effect upon the T wave. It will be remembered that when the left ventricle is considerably enlarged the T wave is never inverted in the right pectoral—left leg lead (except in rare cases in which T is inverted in all leads including the three limb leads). With moderate left ventricular enlargement the T wave is inverted in 7 per cent. in this lead ; with slight left ventricular enlargement it is inverted in 14 per cent. ; in normal adults in 58 per cent. ; in normal children in 65 per cent. ; in cases of rheumatic carditis in 66.6 per cent. ; and finally in cases of right ventricular enlargement in 75 per cent. We have expressed these facts altogether in Table VI. This shows clearly the influence of right ventricular enlargement upon the direction of the T wave in the chest lead electrocardiograms employed.

TABLE VI  
THE INFLUENCE OF VENTRICULAR ENLARGEMENT  
UPON THE DIRECTION OF THE T WAVE

Percentage of cases with inversion of the T wave

	lead TV-F	lead L.P.-F	lead R.P.-F
L.V. ENLARGEMENT +++	58	9	4
L.V. ENLARGEMENT ++	0	0	7
L.V. ENLARGEMENT +	0	0	14
NORMAL ADULTS	0	2	58
NORMAL CHILDREN	0	21	65
RHEUMATIC CARDITIS	16.6	33.3	66.6
R.V. ENLARGEMENT	20	35	75

In general, the extent of T wave inversion was parallel to the degree of right ventricular enlargement, and when the T wave was inverted in lead IV the right ventricle was usually considerably enlarged. Illustrations of inverted T waves in cases of right ventricular enlargement are shown in Fig. 9.

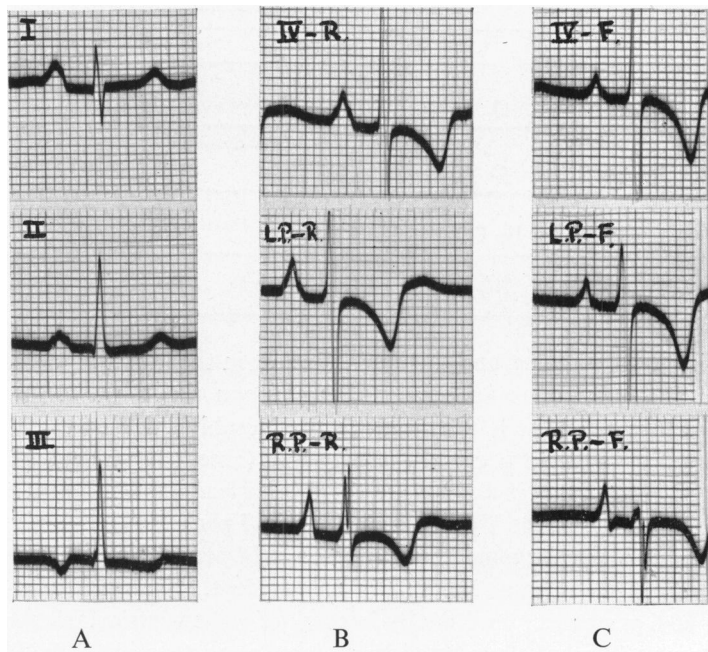


FIG. 9.—From a case of mitral stenosis with considerable enlargement of the right ventricle.

- (A) Limb leads.  
 (B) Chest leads paired with the right arm.  
 (C) Chest leads paired with the left leg.

Note inversion of the T wave in all chest leads (the tall spiked P wave in the right pectoral leads probably indicates right auricular hypertrophy).

Special attention must be paid to the cases of acute cor pulmonale following pulmonary embolism. In these, inversion of the T wave was transient, and was most marked and lasted longest in the right pectoral leads. The sequence of events was remarkably similar in all five cases. The first record, obtained within twenty-four hours from the onset, showed inversion of the T wave in both pectoral leads and sometimes in the apical leads as well; the first change occurred two or three days later when the T wave in lead IV became upright if it had been previously inverted; the second change, after a few more days, occurred when the T wave became upright in the left pectoral lead; and finally, the T wave became upright in the right pectoral lead. The usual sequence of events is illustrated in Fig. 10.

These findings are important for two reasons: first, because they suggest that inversion of the T wave of the type described may occur from right ventricular stress quite apart from hypertrophy; and secondly, because they may be of great help in the differential diagnosis of pulmonary embolism from posterior myocardial infarction.



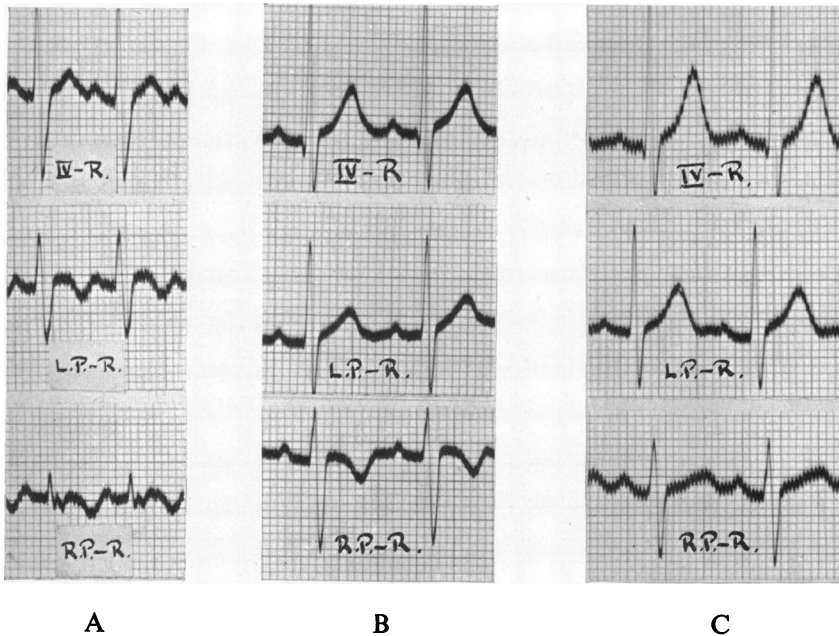


FIG. 10.—Serial chest lead electrocardiograms paired with the right arm from a case of acute cor pulmonale following pulmonary embolism.

- (A) Within twenty-four hours of the onset, showing inversion of the T wave in the left and right pectoral leads.  
 (B) A week later, showing inversion of the T wave in the right pectoral lead only.  
 (C) Eighteen days after the onset, showing upright T waves in all leads.

*Summary of the effects of right ventricular enlargement upon the chest lead electrocardiogram*

1. The main QRS deflection is upright in the right pectoral leads in about a third of the cases. Such curves are especially significant when the proximal electrode is paired with the left leg.

2. Marked notching of the R wave associated with a late intrinsic downward deflection may sometimes occur in the right pectoral lead, and occasionally there may be a prominent Q wave.

3. Inversion of the T wave is common and obeys the rule which may be applied to normal children and to cases of rheumatic carditis, i.e. if the T wave is inverted in any lead, it is also inverted (and usually more so) in leads in which the proximal electrode is shifted to the right.

4. Transient T wave changes of the same type are seen in cases of acute cor pulmonale following pulmonary embolism, and may be of considerable help in diagnosing the condition from posterior basal myocardial infarction.

5. The incidence of inversion of the T wave is greater when the proximal electrode is paired with the left leg; but its significance is greater when the proximal electrode is paired with the right arm.

These findings are in contrast to those of left ventricular enlargement.

## BUNDLE BRANCH BLOCK

The form of the chest lead electrocardiogram in cases of bundle branch block in human beings was originally worked out by Wilson, Macleod and Barker (1932 b), their publication appearing one month after the original article by Wolferth and Wood (1932 a) recommending the use of chest leads as an aid in the diagnosis of myocardial infarction. Wilson, Macleod and Barker (1932 b) used multiple chest leads paired with the left leg, and these would now be called leads CF 1, 2, 3 and 4 (*Standardization of Präcordial Leads*, 1938). The object of their paper was to show that what was then called right bundle branch block was in reality left bundle branch block and vice versa. Using the old polarity they determined that "when bundle branch block is present the chief upstroke of the ventricular complex in semi-direct leads is early when the exploring electrode is placed close to the ventral surface of the contralateral ventricle and late when this electrode is placed close to the surface of the homolateral ventricle. In the former case the fibre usually remains above, in the latter case it usually remains below the base line throughout the greater part of the QRS interval." They also stated that the right ventricle was favourably situated for semi-direct leads from its ventral surface, but that the left ventricle was not so favourably situated.

Wilson, Johnston, Hill, Macleod and Barker (1934 c), using similar multiple leads but paired with a neutral indifferent electrode, showed that an abnormally long QRS interval and a broad S deflection in lead I signified right bundle branch block. Chest leads V1, V2 and V3 exhibited a late chief upstroke (old polarity) and leads V4 and V5 an early one.

In certain cases of septal infarction with bundle branch block, Wilson, Hill and Johnston (1934 a) advise the use of chest leads for proper interpretation. They described the production of right bundle branch block of the type just mentioned by experimental infarction of the interventricular septum in three dogs. Wilson, Johnston and Barker (1934 b) also advise the use of chest leads in order to interpret limb lead electrocardiograms which exhibit a bizarre form of bundle branch block. In three such cases the limb lead electrocardiograms were illustrated and were thought to be suggestive of left rather than right bundle branch block, but chest leads showed clearly that they signified right bundle branch block.

Our series includes twenty cases of bundle branch block, ten left and ten right. We found that the appearances in the left and right pectoral leads were consistent in all cases. In left bundle branch block (new terminology) the main QRS deflection was downwards with an early intrinsic downward deflection, followed by a large upright T wave; in right bundle branch block of the type described by Wilson and his associates (1934 c), and by Evans and Turnbull (1937) in this country, the main QRS deflection was upwards with a late intrinsic downward deflection and the T wave was inverted. The appearances in the apical leads were less consistent, no doubt depending upon whether the proximal electrode represented a left or a right ventricular or a septal contact. Thus in left bundle branch block seven cases presented similar features to those in the

pectoral leads, and only three showed a late intrinsic downward deflection with an upright QRS complex and inversion of the T wave. In right bundle branch block the intrinsic downward deflection was early in lead IV in seven cases, followed by a broad sluggardly S deflection and an upright T wave, but in the other three cases the appearances were similar to those in the pectoral leads (see Figs. 11 and 12).

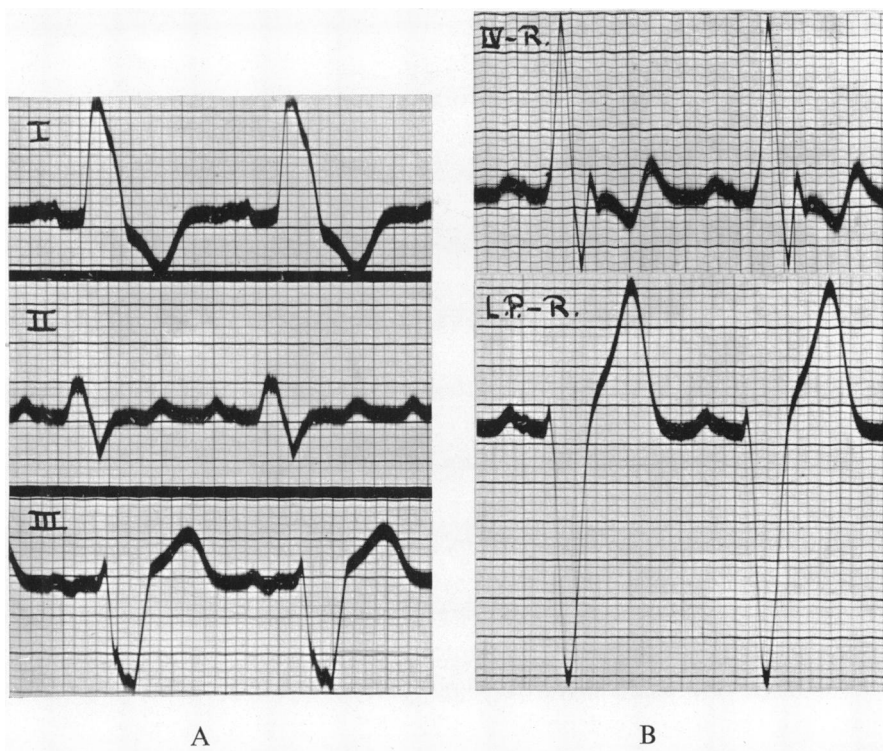


FIG. 11.—Left bundle branch block (new terminology).

(A) Limb leads.

(B) Chest leads paired with the right arm.

Above : lead IV R showing a somewhat delayed intrinsic downward deflection and a diphasic T wave.

Below : the left pectoral lead (the right pectoral lead was similar) showing an early intrinsic downward deflection, a very deep S wave, and a very tall T wave.

It is, therefore, clear that for clinical work the pectoral leads are more valuable than lead IV for interpreting doubtful or bizarre forms of bundle branch block, and that the choice of distal electrode is a matter of indifference. It should be noted that when there is difficulty in distinguishing left bundle branch block from left axis deviation with inversion of T, no help can be obtained from chest leads ; but that when there is difficulty in distinguishing right bundle branch block from right axis deviation with inversion of T<sub>3</sub>, the left pectoral lead usually makes correct interpretation easy. Reference to the findings in cases of considerable left and right ventricular enlargement will clarify these remarks.

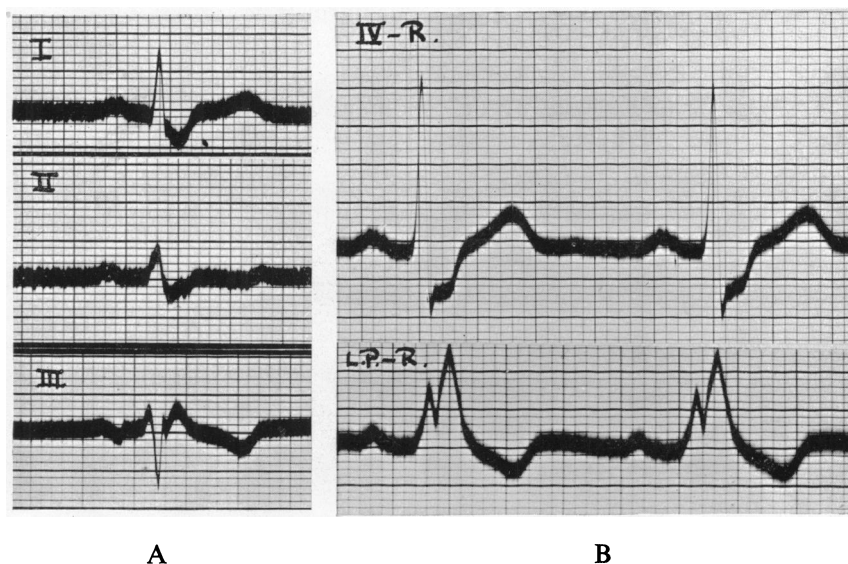


FIG. 12.—Right bundle branch block—common type (new terminology).

(A) Limb leads.

(B) Chest leads paired with the right arm.

Above : lead IV R showing a normally timed intrinsic downward deflection and gross slurring of S. The appearances are similar to those in lead I.

Below : the left pectoral lead (the right pectoral lead was similar) showing a notched upright QRS complex with a late intrinsic downward deflection, and an inverted T wave.

#### DIGITALIS

The effect of digitalis upon the limb lead electrocardiogram is well known. There is a characteristic depression of the RS-T segment. Strauss and Katz (1935) using chest leads came to the conclusion that either elevation or depression of the RS-T segment might occur. They used the old polarity. Their illustrations of elevation of the RS-T segment were convincing, but the same cannot be said of their example of depression of that segment.

Stewart and Watson (1938) have also investigated the effect of digitalis upon the chest lead electrocardiogram. Using an anterior-posterior lead and the old polarity they found that elevation of the RS-T segment occurred in the majority of cases, but that occasionally there were other effects. The electrocardiograms showing these other effects, which included depression of the RS-T segment, were bizarre.

Holzmann (1937), using an anterior-posterior chest lead and the new polarity, found that digitalis commonly caused depression of the RS-T segment similar in character to that seen in limb lead electrocardiograms. Occasionally, however, especially when there was eccentric hypertrophy of the left ventricle or of both ventricles, digitalis produced a dome shaped RS-T segment which was elevated to a maximum of 0.2 mv. above the iso-potential level. These curves resembled those of myocardial infarction, and correct interpretation

was sometimes difficult. When elevation exceeded 0.2 mv., a digitalis effect could be excluded.

We have used chest leads in fifteen cases treated with digitalis. Depression of the RS-T segment, similar in character to that seen with limb leads, and often in an exaggerated form, was found in every instance. It was most pronounced in lead IV except in those cases with marked right ventricular dominance when it was most evident in the right pectoral lead (see Fig. 13). It was shown rather

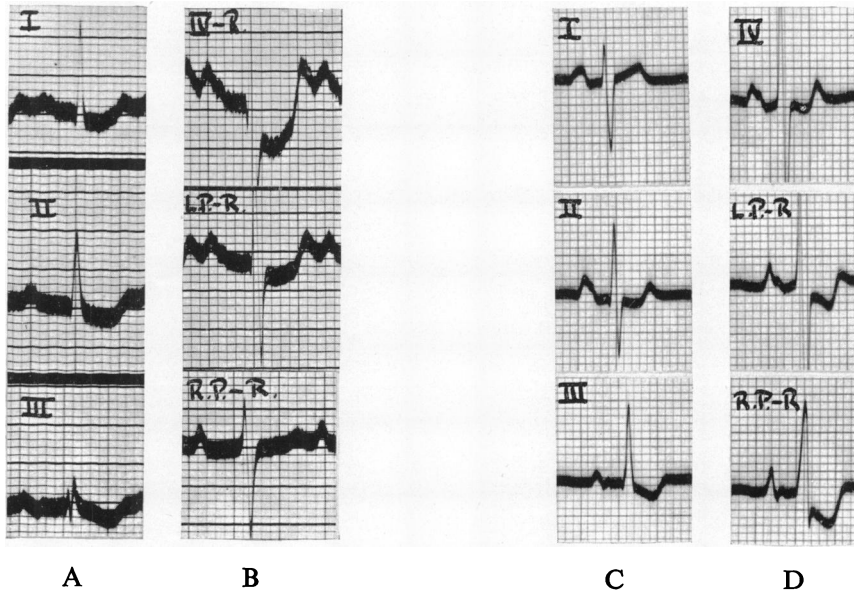


FIG. 13.—Limb leads (A), and chest leads paired with the right arm (B), in a case of digitalis intoxication. There is very marked depression of the RS-T segment in lead IV, but none in the right pectoral lead. Case of thyrotoxicosis.

(C), (D) Limb leads, and chest leads paired with the right arm, in a case of marked right ventricular dominance due to mitral stenosis, pulmonary hypertension and probable pulmonary embolism. The digitalis effect is most marked in the right pectoral lead.

better when the proximal electrode was paired with the right arm than when it was paired with the left leg.

It is concluded that lead IV R is suitable for showing the effect of digitalis except in cases with marked right ventricular dominance when the right pectoral lead should be used, and that when there is doubt as to the proper interpretation of a possible digitalis effect with limb leads, chest leads may be helpful by showing this effect in an exaggerated form.

#### MYOCARDIAL INFARCTION

Wood and Wolferth (1932, 1933) showed that an anterior-posterior chest lead electrocardiogram would produce typical changes in the RS-T segment after experimental ligation of the anterior descending branch of the left coronary artery of the dog, when the limb lead electrocardiogram was normal. They concluded that this might also apply to certain cases of myocardial infarction in

man. An opportunity to test this suggestion soon presented itself. A case, clinically diagnosed as myocardial infarction, failed to show changes with the limb leads. An anterior-posterior chest lead was employed, and the electrocardiogram so obtained showed a remarkable deviation of the RS-T segment from the iso-potential level. This case subsequently exhibited diagnostic changes in the limb leads. To it was added another case which showed typical RS-T changes in both limb and chest leads, and then with thirty-three controls the facts were published (Wolferth and Wood, 1932 a) prior to the experimental reports given above. Shortly afterwards they published a short article (1932 b) describing three cases of myocardial infarction in which the changes were more evident in limb than in chest leads. One of these cases exhibited a typical T1 type of coronary curve, but the other two were probably both posterior infarctions.

Several hasty reports by other authors followed and have been sharply criticized by Roth (1935). But in the last six years certain facts have become established. In anterior myocardial infarction changes occur in the QRS complex, in the RS-T segment and in the T wave, and any one of these changes may be shown only or best in one particular lead either limb or præcordial. Wilson and his associates have made a special study of the behaviour of the QRS complex with limb (Wilson and others, 1932 a, 1933) and with semi-direct leads (Johnston and others, 1935; Wilson and others, 1932 a, 1935 a, 1935 b, 1933), both in the dog and in man. They have shown experimentally that monophasic downward deflections (new polarity) are obtained from areas underlying which there is infarction of the whole thickness of the ventricular wall, but that at the edges of the infarct where there is living tissue, or over the centre of the infarct if it only involves part of the thickness of the ventricular wall, a W complex is usual. Semi-direct leads taken from points overlying healthy muscle away from the infarct yield normal QRS complexes. These QRS changes may be transient or permanent according to the degree of recovery of the muscle deprived of its blood supply. In clinical cases they found that QRS changes were more likely to be permanent than T wave changes.

The occurrence of a monophasic downward deflection in the chest lead in cases of anterior myocardial infarction has been well established (Bohning and Katz, 1938; Donzelot and Pelaez, 1938; Faulkner, 1936; Feinstein and Lieberman, 1937; Freeman, 1937; Goldbloom, 1934; Holzmans, 1937; Jervell, 1935; Master and other, 1937; Wood and others, 1933), but little attention has been paid to the W complex. Amongst the authors who stress the importance of a monophasic downward deflection are Master, Dack, Kalter and Jaffe (1937) who also state that a very small R wave is significant. They found it in 37 per cent. of cases with ischæmic heart disease compared with the figure of 7.5 per cent. for normal controls. When one considers that about 30 per cent. of cases with ischæmic heart disease have considerable enlargement of the left ventricle from hypertension or from syphilitic aortic incompetence, it is seen that the figure of 37 per cent. is exactly what one would predict, for we have already shown that cases with considerable enlargement of the left ventricle

ordinarily have a very small R wave in the left pectoral lead which is more or less the lead they used.

We have analysed the QRS complex in eighteen cases of anterior myocardial infarction. In lead IV R or F we found a W complex in no less than twelve cases, and a monophasic downward deflection in only three. The shape of the W varied considerably, but so long as there were three conspicuous deflections, Q, R and S, we included it. In the left and right pectoral leads QRS was represented by a monophasic downward deflection in fifteen cases. Eight patients were followed for periods of six months to two and a half years : the W complex was permanent in three and transient in two ; the monophasic downward deflection was permanent in five and transient in two.

The finding of W complexes in apical leads and monophasic downward deflections in the pectoral leads, which have also been recorded by Kossmann and de la Chapelle (1938), is a little difficult to understand. According to the experimental work of Wilson and his associates already mentioned, monophasic downward deflections might be expected in lead IV over the site of the infarct, and W complexes in the left pectoral lead at the edge of the infarct, in the common cases of anterior apical myocardial infarction. If the infarct should involve only the inner part of the muscle wall, the W complex would be understood at the apex, but in that case why should there be a monophasic downward deflection in the left pectoral lead ?

Elevation of the RS-T segment is commonly seen in the early stages of anterior myocardial infarction, and has frequently been described (Bohning and Katz, 1938 ; Donzelot and Pelaez, 1938 ; Feinstein and Lieberson, 1937 ; Freeman, 1937 ; Holzmann, 1937 ; Jervell, 1935 ; Lieberson and Liberson, 1933 ; Swan, 1937 ; Van Neiuwenhuizen and Hartog, 1937 a ; Willcox and Lovibond, 1937 ; Wilson, 1936) since the article by Wolferth and Wood (1932). In our series elevation of the RS-T segment occurred in nine out of twelve cases which were investigated sufficiently early. It was always evident in lead IV and in the left pectoral leads, but it only occurred in the right pectoral lead in four cases. The choice of distal electrode was a matter of indifference. As with limb leads this change was always transient.

Subsequent inversion of the T wave has been described by practically all authors on the subject of chest leads in myocardial infarction, and Wolferth and Wood (1933) have reported seven cases in which these T waves were " huge." All our cases showed subsequent inversion of the T wave in the apical leads, and all but three in the left pectoral leads. In the right pectoral—right arm lead the T wave was inverted in five cases, and in the right pectoral—left leg lead in seven. Of eight cases followed for a sufficient period of time the inversion of the T wave was permanent in four cases in the apical leads, in three cases in the left pectoral leads, and in four cases it was transient.

Characteristic curves showing the W complex, the monophasic downward deflection, the elevation of the RS-T segment, and the inverted T wave are shown in Fig. 14.

There have been different reports concerning the findings with chest leads in cases of posterior myocardial infarction. All are agreed that the QRS

complex is not affected, and that the T wave is not inverted. Though some (Jervell, 1935 ; Swan, 1937 ; Wood and others, 1933) have concluded that the RS-T segment is usually unaffected, others have shown that there may be marked depression of this segment in the early stage of posterior infarction (Bohning

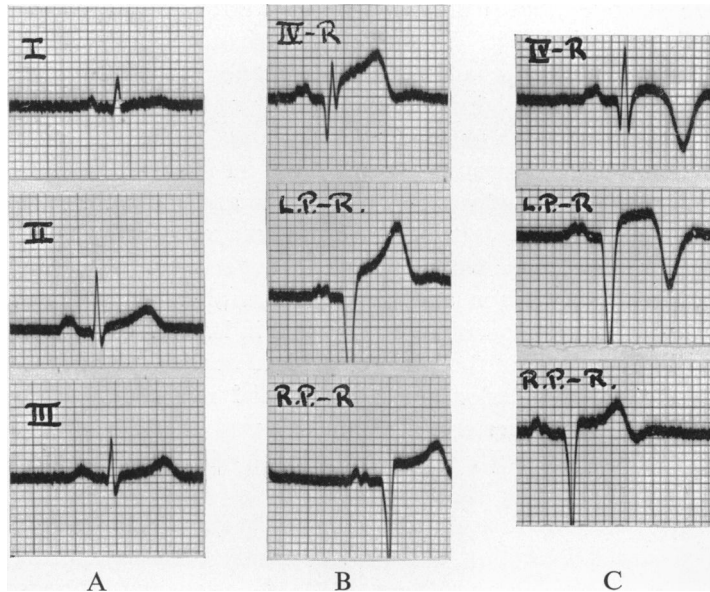


FIG. 14.—From a case of anterior myocardial infarction.

Limb leads (A), and chest leads paired with the right arm (B), showing a deformed W complex in lead IV, monophasic downward deflections in the pectoral leads, and elevation of the RS-T segment in all chest leads.

Chest leads paired with the right arm (C), a week later, showing a typical W complex in lead IV, monophasic downward deflections in the pectoral leads, somewhat less elevation of the RS-T segment in all chest leads, and sharp inversion of the T wave in lead IV and in the left pectoral lead.

and Katz, 1938 ; Feinstein and Lieberson, 1937 ; Holzmänn, 1937 ; Willcox and Lovibond, 1937 ; Wilson and others, 1932 a). It has also been shown that as the RS-T segment approaches or resumes the iso-potential level, the T wave may become very tall (Bohning and Katz, 1938 ; Feinstein and Lieberson, 1937 ; Willcox and Lovibond, 1937 ; Wilson and others, 1932 a).

Fifteen cases of posterior myocardial infarction were included in our series. QRS was normal in all instances. The RS-T segment was depressed in the apical leads in eight out of ten cases which were investigated sufficiently early. This depression was not so evident in the left pectoral leads and did not occur at all in the right pectoral leads. Inversion of the T wave did not occur, but in three instances an upright T wave of very high voltage succeeded the early depression of the RS-T segment. The distal electrode did not materially influence any of these findings (see Fig. 15).

The characteristic electrocardiographic changes of anterior myocardial infarction are very rarely restricted to chest leads if serial records are obtained,



but they may occur earlier in chest leads, where they may be diagnostic when still of doubtful significance in limb leads, and they may last longer in chest leads. Very occasionally an infarct may affect lead I and not the chest leads.

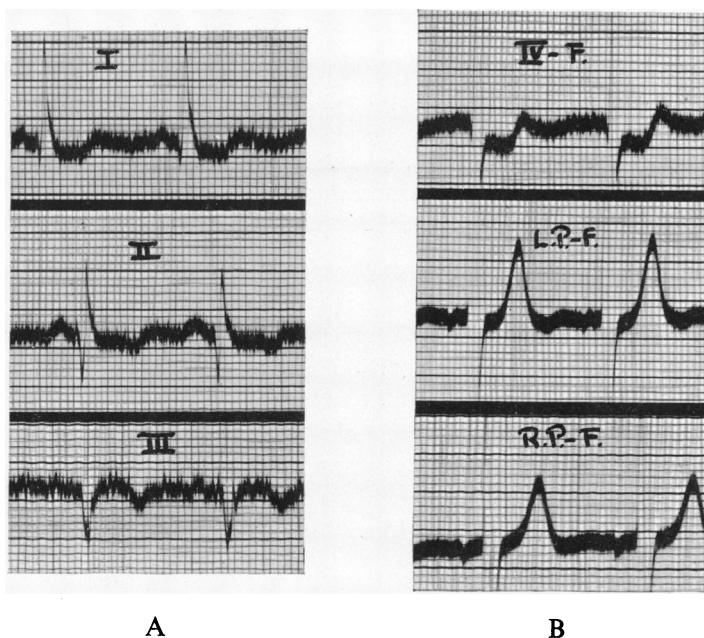


FIG. 15.—From a case of posterior myocardial infarction.

- (A) Limb leads.  
 (B) Chest leads paired with the left leg, showing depression of the RS-T segment in lead IV, and tall T waves in the pectoral leads.

Wolferth and Wood (1932 b) reported such a case, and we have recently seen an example.

In our series of thirty-three cases of myocardial infarction serial limb leads were diagnostic of the condition in all but one instance, but in four others the changes occurred earlier in the chest lead graphs so that a correct diagnosis was made sooner. We derived no help from the chest leads in the cases of posterior myocardial infarction, for in these the limb leads required no support, and the chest leads had but little to give.

Before concluding, reference must be made to the value of chest leads in cases of multiple infarction. Wolferth and Wood (1935), and Feinstein and Lieberson (1937) have drawn attention to this.

A combination of anterior and posterior myocardial infarction may give rise to an atypical limb lead electrocardiogram which causes difficulty in diagnosis. In this event, chest leads may prove of use by unmasking the anterior infarct. The atypical electrocardiograms of the two cases which came to autopsy in the paper by Wolferth and Wood (1935) were examples of the  $T_2$  pattern described by Wood (1937) in cases of pericarditis and hæmopericardium, and it is therefore unfortunate that no statement was made as to the

presence or absence of pericarditis in the two cases mentioned. However, there can be little doubt as to the truth of their contention, and we have recently seen a good example in which limb leads were atypical but suggested posterior myocardial infarction, whereas chest leads were diagnostic of anterior infarction. Autopsy showed a large infarct at the apex of the left ventricle anteriorly, but spreading round to involve a considerable portion of the posterior wall.

*Summary of the Effects of Myocardial Infarction on the Chest Lead  
Electrocardiogram*

*A. In anterior myocardial infarction*

1. QRS is often represented by a W complex in the apical leads, and by a monophasic downward deflection in the pectoral leads.

2. Initial elevation of the RS-T segment and subsequent inversion of the T wave commonly occur in both apical and left pectoral leads but are less evident in the right pectoral leads.

3. Any one of these changes, except elevation of the RS-T segment which is always transient, may or may not be permanent.

4. Both the right arm and the left leg are entirely satisfactory distal electrodes for the demonstration of these changes.

*B. In posterior myocardial infarction*

1. The QRS complex is normal.

2. Initial depression of the RS-T segment is common, and is most evident in the apical leads.

3. Very tall upright T waves are sometimes seen in the later stage either in the apical or in the left pectoral leads or in both.

For clinical work, chest leads are of undoubted value in cases of suspected myocardial infarction, especially by enabling one to make an earlier diagnosis in acute cases, and a correct diagnosis in cases seen for the first time some months after the event.

#### ANGINA PECTORIS

Chest leads have been considered helpful in the diagnosis of angina pectoris. Thus H. D. and S. A. Levine (1936), using a left para-sternal—left leg lead in addition to lead IV F, found that 16 per cent. of their cases of angina pectoris lacked an R wave. In another series of forty-four autopsy cases they showed that an absent R wave in lead IV F was associated with myocardial infarction in twelve out of fifteen cases. Two of the other three had bundle branch block, and the third had tuberculous pericarditis. (To avoid confusion we have translated their nomenclature into the current terminology.) They concluded that an absent R wave in the leads they used was important evidence of ischæmic heart disease.

Willcox and Lovibond (1937), preferred a left para-sternal—right arm lead. They investigated sixty-two cases of angina pectoris. In thirty-four the

electrocardiogram was normal ; in eleven both limb and chest leads were abnormal ; in nine the limb leads were abnormal, but the chest lead was normal ; and in eight the limb leads were normal, but the chest lead abnormal. The abnormalities in the chest leads consisted of very small or absent R waves and inversion of the T waves.

Edeiken, Wolfert and Wood (1936) considered that reversal of the T wave in their antero-posterior chest lead should be considered pathological when it was the only abnormality of the adult electrocardiogram. In such cases they suspected coronary artery disease.

The chest lead electrocardiograms in cases of angina pectoris must be interpreted with caution. For if there is associated hypertensive heart disease or aortic valvular disease with much enlargement of the left ventricle, an inverted T wave in the apical leads and a very small R wave in the pectoral leads are only to be expected, and cannot be used to support the diagnosis of angina pectoris. There were twenty-seven cases of angina pectoris in our series. Only three of these showed chest lead abnormalities which could not be accounted for by the known underlying condition, and in these three there was inversion of the T wave in leads IV R and F but not in the pectoral leads. The limb leads of these three cases were normal.

It is concluded that chest leads may be of service in giving support to the diagnosis of angina pectoris by revealing the presence of previous myocardial infarction. Both lead IV and the left pectoral leads are therefore advised, the former to show W complexes, the latter monophasic downward deflections, and either or both, inverted T waves.

## DISCUSSION

### THE DISTAL ELECTRODE

The choice of distal electrode lies between the dorsal electrode originally used by Wolfert and Wood (1932 a), the neutral electrode devised by Wilson and his associates (1934 d), and one of the limb electrodes. Because the dorsal electrode is inconvenient to apply, and because it has not been shown to have any advantage over the others, it seems wise to discard it. We have had no experience of Wilson's neutral electrode, but because it requires additional apparatus it is unlikely to meet with much favour in clinical work unless it proves to have definite advantages, and so far there is little evidence of this. Keller (1937), after comparing the neutral electrode with the right arm electrode used by Groedel (1934), came to the conclusion that the latter was preferable both on theoretical and practical grounds. The majority of workers now use one of the limb electrodes, and the most favoured are the left leg and the right arm. The left leg has been more widely used for two reasons : first, because the technique was simpler with the old polarity, and secondly because more work had been done with this electrode on normal controls. Neither of these reasons is now valid. With the new polarity the technique is simpler with the right arm electrode, and adequate work has now been done with this electrode

on normal controls. The choice between these two electrodes should be made on their respective merits.

If only one chest lead is used, lead IV (the apical lead) has been recommended by the Cardiac Society of Great Britain and Ireland and by the American Heart Association. Now in lead IV, there is only one difference between the distal electrodes under consideration: in young children lead IV F may occasionally show a diphasic T wave (Sorsky and Wood, 1937), and if the proximal electrode is placed slightly inside the apex beat the T wave may be inverted, whereas lead IV R exhibits an upright T wave in normal controls of any age, and the proximal electrode may be placed well inside the apex beat without altering the direction of the T wave. Since lead IV R is the simpler lead with the new polarity, it has two advantages and no disadvantages, and we, therefore, recommend it without hesitation.

If multiple chest leads are used the problem becomes more complicated. The left leg has the advantage when chest leads are used to distinguish left ventricular enlargement from cardiac displacement due to a high diaphragm, for we have shown that in the right pectoral—left leg lead an inverted T wave is incompatible with considerable left ventricular enlargement, but is common in normal controls and in cases of cardiac displacement due to a high diaphragm. The right arm distal electrode is useless for this purpose. We have found no other major advantage in the left leg distal electrode, but there is one other minor advantage: if R is taller than S in the right pectoral—left leg lead, it may be concluded that there is dominance of the right ventricle. A similar finding in the right pectoral—right arm lead is suggestive but less certain.

The right arm distal electrode has been used extensively by Groedel (1934), was independently suggested by Roth (1935), advised by Larsen (1937), and favoured by Willcox and Lovibond (1937). Apart from its convenience it has two considerable advantages: first, normal standards are more uniform in that the T wave remains upright in all leads in adults, and is only rarely inverted in children and then only in the right pectoral lead; as a corollary, inversion of the T wave in the pectoral leads has much more significance with the right arm distal electrode than it has with the left leg; secondly, the P wave is upright and of adequate dimensions in leads paired with the right arm, whereas it is usually inverted and is very small in leads paired with the left leg. Although we have not drawn attention to the value of the right pectoral lead in studying disorders of rhythm, it may be remembered that Lewis (1909–10) found it expedient to use such a lead in his study of auricular fibrillation. Holzmann (1937) found that abnormalities of the P wave could be well shown by placing the exploring electrode over the right auricle, and we have been using the right pectoral—right arm lead to demonstrate the tall sharp P wave associated with right auricular enlargement. There can be little doubt that the right arm is the better distal electrode for these purposes.

We conclude that the right arm is the distal electrode of choice for single or multiple chest leads for routine purposes, but for the special purpose of distinguishing left ventricular enlargement from cardiac displacement due to a high diaphragm we recommend the right pectoral—left leg lead.

## MULTIPLE CHEST LEADS

The Cardiac Society of Great Britain and Ireland recommended a single chest lead, lead IV, for routine use, because it was considered that there was insufficient evidence upon which to recommend multiple chest leads.

Wilson and his associates, who have employed the multiple chest leads recommended by the American Heart Association, have concluded that anterior myocardial infarction will rarely escape detection if multiple chest leads are used in addition to the limb leads.

Holzmann (1937) used the chest leads in all types of heart disease, and found them useful in conditions other than myocardial infarction and angina pectoris. He advised the use of both the apical and the right pectoral lead, the latter being of aid in the diagnosis of right ventricular enlargement. Hecht (1936) came to a similar conclusion.

Groedel (1934) claims to have isolated the lævocardiogram and the dextrocardiogram. The former is obtained with lead IV R, and the latter with a left sternal—right arm lead. Whether his theoretical considerations are right or wrong it is clear that considerable information may be gained by employing both these leads.

There can be no doubt that lead IV is an essential chest lead because it may be the only one to show evidence of myocardial infarction, especially by exhibiting a W complex or an inverted T wave. It is also certain that a monophasic downward initial ventricular complex indicating myocardial infarction may be restricted to the pectoral leads, and that, therefore, the left pectoral or *a* left pectoral lead is essential because this finding loses some of its significance in the right pectoral lead. In acute anterior myocardial infarction elevation of the RS-T segment is usually seen in both apical and left pectoral leads, but may be restricted to one or the other. If chest leads were only used in cases of possible ischæmic heart disease it is clear that both lead IV and a left pectoral lead should be employed.

But chest leads may be of value in other conditions such as rheumatic carditis, pericarditis, acute cor pulmonale from pulmonary embolism, left and right ventricular enlargement, bundle branch block, and for studying the form of the P wave and certain abnormalities of rhythm. For these purposes the right pectoral lead, or a combination of the right pectoral lead and one or both of the others, is required.

It is concluded that at least three chest leads may be used with advantage, not only because each has a function not shared by the others, but also because additional information may be gained by studying them in relation to one another.

The three chest leads which we have used were suggested by Roth (1935), and we have found them satisfactory. There are, however, two other favoured combinations of leads : the first is that used by Groedel (1934) and by Hecht (1936), and consists of two leads, one apical, the other basal, either just to the left of, or just to the right of the sternum, in the fourth intercostal space ; the second is that recommended by the American Heart Association and consists

of a series of leads from the following points—the right border of the sternum in the fourth intercostal space, the left border of the sternum at the same level, midway between the latter and the point next to be described, the mid-clavicular line in the fifth intercostal space, the anterior axillary line at the same horizontal level, and the mid-axillary line, these leads being numbered from 1 to 6 with their appropriate prescript according to the distal electrode employed. The pre-scripts used to denote the distal electrode employed are : for the right arm—CR, for the left leg—CF, for the neutral electrode devised by Wilson and his associates—V. Thus the right pectoral lead which we have used would be called lead CR 1 when it is paired with the right arm, and CF 1 when it is paired with the left leg ; our left pectoral leads would be called leads CR or CF 3 approximately ; and our apical leads would be usually leads CR or CF 4 or 5. The letter C stands for “ chest.”

The choice between these three different combinations of multiple chest leads is no easy one. We have sufficient evidence to justify the use of three rather than two chest leads as a routine procedure when chest leads are requested. Because we have only used three chest leads we are unable to express an opinion as to the value of more. When the apex beat is within the anterior axillary line it is probable that three leads would be sufficient ; when it is further to the left there may be some advantage in four or even five leads. When only three leads are used it would seem more rational to employ the three suggested by Roth (1935), as described in this paper, rather than to lead from three fixed points on the chest wall.

#### SUMMARY AND CONCLUSIONS

1. The normal appearances of electrocardiograms obtained with lead IV R have been presented.
2. Five other chest leads were investigated : lead IV F ; the left pectoral—right arm lead ; the left pectoral—left leg lead ; the right pectoral—right arm lead ; and the right pectoral—left leg lead.
3. Limb lead and multiple chest lead electrocardiograms were obtained from 302 selected cases of heart disease, and from twelve cases of cardiac displacement due to a high diaphragm.
4. In addition to their value as an aid in the recognition of ischæmic heart disease, chest leads have been found of service in the diagnosis of rheumatic carditis, pericarditis, left ventricular enlargement, right ventricular enlargement, acute cor pulmonale resulting from pulmonary embolism, and of doubtful or bizarre forms of bundle branch block.
5. The right arm was both the most informative and the most convenient site for the distal electrode ; and we believe that the evidence is now sufficient to warrant its routine use in preference to the left leg. The latter was only advantageous when it was desired to distinguish left ventricular enlargement from cardiac displacement due to elevation of the diaphragm.
6. Multiple chest leads are of value not only because they may yield

diagnostic evidence of myocardial infarction when a single chest lead is barren, but also because they are a safeguard against faulty interpretation of lead IV, because each of the three leads (lead IV and the two pectoral leads) used in this investigation has some special value peculiar to itself, and because a study of these three leads in relation to one another may give information which is unobtainable by a study of individual leads.

Our thanks are due to Sir Frederick Menzies, chief medical officer of the London County Council, for his permission to publish this material, and to Prof. F. R. Fraser for his constant encouragement and advice.

## REFERENCES

- Bellet, S., and McMillan, T. M. (1938). *Arch. intern. Med.*, **61**, 381.
- Bohning, A., and Katz, L. N. (1938). *ibid.*, **61**, 241.
- Donzelot, E., and Pelaez, M. (1938). *Arch. Mal. Coeur*, **31**, 393.
- Edeiken, J., Wolferth, C. C., and Wood, F. C. (1936). *Amer. Heart J.*, **12**, 666.
- Evans, W., and Turnbull, H. M. (1937). *The Lancet*, **2**, 1127, 1184.
- Faulkner, J. M. (1936). *New Engl. J. Med.*, **213**, 1215.
- Feinstein, M. A., and Lieberson, A. (1937). *Amer. Heart J.*, **14**, 69.
- Freeman, E. T. (1937). *The Lancet*, **1**, 499.
- Goldbloom, A. A. (1934). *Amer. J. med. Sci.*, **187**, 489.
- Groedel, F. M. (1934). *Das Elektrokardiogramm. Eine vergleichene Studie*, Theodor Steinkopff, Dresden und Leipzig.
- Hecht, H. (1936). *Dtsch. Arch. klin. Med.*, **179**, 1.
- Hoffman, A. M., and DeLong, E. (1933). *Arch. intern. Med.*, **51**, 947.
- Holzmann, M. (1937). *Arch. Kriessl Forsch.*, **1**, 1.
- Jervell, A. (1935). *Acta Med. Scand.*, Sup. 68.
- Johnston, F. D., Hill, I. G. W., and Wilson, F. N. (1935). *Amer. Heart J.*, **10**, 889.
- Keller, F. (1937). *Dtsch. Arch. klin. Med.*, **180**, 193.
- Kossmann, C. E., and de la Chapelle, C. E. (1938). *Amer. Heart J.*, **15**, 700.
- Larsen, K. H. (1937). *ibid.*, **14**, 1.
- and Warburg, E. J. (1937). *ibid.*, **14**, 7.
- Levine, H. D., and Levine, S. A. (1936). *Amer. J. med. Sci.*, **191**, 98.
- Levy, R. L., and Bruenn, H. G. (1935). *Amer. Heart J.*, **10**, 881.
- Lewis, T. (1909–10). *Heart*, **1**, 306.
- Lieberson, A., and Liberson, F. (1933). *Ann. intern. Med.*, **6**, 1315.
- Master, A. M., Dack, S., Kalter, H. H., and Jaffe, H. L. (1937). *Amer. Heart J.*, **14**, 297.
- Præcordial Leads in Electrocardiography: A Joint Memorandum by a Committee of the Cardiac Society of Great Britain and Ireland, and the Committee of the American Heart Association* (1938). *Brit. med. J.*, **1**, 187.
- Robinow, M., Katz, L. N. and Bohning, A. (1936). *Amer. Heart J.*, **12**, 88.
- Roth, I. R. (1935). *ibid.*, **10**, 798.
- (1937). *ibid.*, **14**, 155.
- Selzer, A. (1938). *ibid.*, **16**, 336.
- Sorsky, E., and Wood, P. (1937). *ibid.*, **13**, 183.
- Standardization of Præcordial Leads: Supplementary Report by the Committee of the American Heart Association* (1938). *ibid.*, **15**, 235.
- Stewart, H. J., and Watson, R. F. (1938). *ibid.*, **15**, 604.
- Strauss, H., and Katz, L. N. (1935). *ibid.*, **10**, 546.
- Swan, W. G. A. (1937). *Newc. med. J.*, **17**, 44.
- Vander Veer, J. B., and Norris, R. F. (1937). *Amer. Heart J.*, **14**, 31.
- Van Neiuwenhuizen, C. L. C., and Hartog, H. A. P. (1937 a). *Arch. intern. Med.*, **59**, 448.
- (1937 b). *Amer. Heart J.*, **13**, 308.
- Willcox, A., and Lovibond, J. L. (1937). *The Lancet*, **1**, 501.
- Wilson, F. N. in Levy, R. L. (1936). *Diseases of the Coronary Arteries and Cardiac Pain*, New York, p. 281.
- Barker, P. S., Macleod, A. G. and Klostermeyer, L. L. (1932 a). *Proc. Soc. exp. Biol., New York*, **29**, 1006.
- Hill, I. G. W., and Johnston, F. D. (1934 a). *Amer. Heart J.*, **9**, 596.
- (1935 a). *ibid.*, **10**, 903.
- Johnston, F. D., and Barker, P. S. (1934 b). *ibid.*, **9**, 472.
- Johnston, F. D., and Hill, I. G. W. (1935 b). *ibid.*, **10**, 1025.

- Wilson, F. N., Johnston, F. D., Hill, I. G. W., Macleod, A. G. and Barker, P. S. (1934 c), *ibid.*, **9**, 459.
- Johnston, F. D., Macleod, A. G. and Barker, P. S. (1934 d), *ibid.*, **9**, 447.
- Macleod, A. G. and Barker, P. S. (1932 b), *ibid.*, **7**, 305.
- Macleod, A. G., Barker, P. S., Johnston, F. D. and Klostermeyer, L. L. (1933). *Heart*, **16**, 155.
- Wolferth, C. C., and Wood, F. C. (1932 a). *Amer. J. med. Sci.*, **183**, 30.
- (1932 b). *Med. Clin. N. Amer.*, **16**, 161.
- (1935). *Arch. intern. Med.*, **56**, 77.
- Wood, F. C., Bellet, S., McMillan, T. M. and Wolferth, C. C. (1933), *ibid.*, **52**, 752.
- and Wolferth, C. C. (1932). *J. clin. Invest.*, **11**, 815.
- (1933). *Arch. intern. Med.*, **51**, 771.
- (1934). *Amer. Heart J.*, **9**, 706.
- Wood, Paul (1937). *The Lancet*, **2**, 796.