

# CONGENITAL COMPLETE HEART BLOCK

BY

MAURICE CAMPBELL

*From Guy's Hospital and the National Hospital for Diseases of the Heart*

Received October 21, 1942

Few of the reported cases of congenital complete heart block have been over twenty years of age. It seems, therefore, worth reporting seven cases who are in good health at various ages between 22 and 42 years. This ætiological factor should, therefore, be thought of in middle-aged and even in elderly patients with complete heart block of unknown ætiology.

Campbell and Suzman (1934), reporting eight cases, suggested that "when patients have been followed for a longer time they may be found in good health at a more advanced age." Of the eight cases reported in 1934, one had died and one was then only 3 so would still be a child; the remaining six, who were then between 12 and 33 years of age, and another man of 29, who was seen soon after, have been followed up; all have been traced and found to be leading ordinary lives without trouble from their hearts. This paper is not concerned with a clinical description of their condition which has been given already. It is an attempt to assess their capacity for leading a normal active life during the nine years that have elapsed since they were reported. The first six are given the same case numbers as in the previous paper; the seventh (Case 9) has not been reported previously.

Case 2. The diagnosis was made when she was 1 year old. She was under observation at the Heart Hospital from the age of 12 to 19 years. She was then a fit normal-looking girl, free from symptoms, and working as a shorthand typist. Her heart was a little enlarged and she was thought to have a patent interventricular septum.

Four years later she was examined at a routine visit and the condition of her heart was unchanged. A year later she had pleurisy; she did not feel ill for long and had little cough, but after some weeks' observation was diagnosed as early tuberculosis of the lung. She was in bed for two months and off work for six months, and six months later (with medical approval) married. This was shortly before the war. Since then, except that she has been "bombed out" of her home, she has led an uneventful life and kept in good health.

She is now 28 and does her normal household duties and feels less tired than when she was doing regular office work. She states that she cannot do heavy work without feeling unduly tired, but this has always been the case; recently to the surprise of herself and her friends she has been able to do all the heavier work connected with re-starting her London home.

Case 3. The diagnosis was made when he was 2, and confirmed at his school medical examination at 6 years old. He was under observation at the Heart Hospital at the age of 12 years. He was leading a normal life except that he had not been allowed to play games at school. The heart was just enlarged, and he was thought to have a slight interventricular septal defect.

After school he worked as an electrician and kept in good health. Though he did not play football, he did a good deal of camping and swimming.

He is now 22, and has been 2 years in the R.A.F. He actually passed for flying duties, but has continued his ground duties as an electrician. He has not been to hospital and has had nothing except very minor ailments.

Examined recently while on leave, he looked fit. His heart rate was unchanged at 48, and his B.P. 130/85. The systolic murmur was not very obvious and I was less sure of the diagnosis of patent interventricular septum. The apex beat was forcible and just out to the left. Radioscopy showed a large left ventricle with a very forcible beat and some prominence of the pulmonary conus. In proportion, his heart had certainly not become larger—the maximum transverse diameter in 1932 being 10.9 cm. in a chest of 20.4 cm.; and in 1942, 11.6 cm. in a chest of over 23 cm., which is some evidence, I think, that his work has not been too strenuous. He said he was a little breathless when there was specially heavy work, but was otherwise able to do everything in the same way as the others.

Case 4. Here, too, the diagnosis was made at the age of 2 years, and he was the only patient in the series with a clear history of Stokes-Adams attacks, frequently from the age of 2 to 4 and occasionally up to 8. He then got on well and was under observation at Guy's Hospital from the age of

12 to 16 years. His heart was slightly enlarged, the rate was generally about 42, and there were signs of a patent interventricular septum.

His story since his case was last reported is as follows. He started work at 16 as a baker's van boy, and though the work was light, the Stokes-Adams attacks recurred after a year. He took as much rest as he could without reporting sick, and changed his work to a hairdresser's apprentice. Here he kept quite fit for a year and gradually resumed cricket, football, and swimming. He then, at 18, started work in a garage and though it was heavy work felt very fit and got on well. At 21 (1938) he went into an aircraft factory and also indulged in cycling, dancing, and gymnastics, and had almost forgotten that there was anything the matter with his heart till long hours and hard work after the war had started made him feel it again. In spite of this he carried on and joined the Home Guard and acted as a fire watcher in his factory until January, 1941, when he again had a recurrence of his Stokes-Adams attacks. He took three weeks' rest in bed, again asking no medical advice, and changed his work, becoming a machine shop foreman where he managed well and had no further attacks (September, 1942).

He is now 25 and has done extremely well, working hard in many jobs and playing cricket and football, and since the war taking his full share in the Home Guard, firewatching, etc. He has without doubt done much more than he should, and I have advised him to take his heavier duties as easily as possible. I have given this story fully, because so often it is lack of courage rather than bodily disability that is responsible for the refusal to work hard and to face difficulties.

Case 5. Here, too, the diagnosis was first made at the age of 2 years. She attended the Heart Hospital for six months when she was 27 years old and, until that time, had easily been able to cycle 40 miles a day. Her heart was a little enlarged, the rate was from 46 to 50, and there were signs of a patent interventricular septum. Six years later, when she was 33, she was doing ordinary housework on a farm and was also walking two miles a day to her work without any real discomfort.

She is now 42 and writes that she has kept well and continued the same work, and that she has needed no medical attention of any sort for the last 15 years (August, 1942). So far as I am aware, this and the patient of Peel (1943) are the oldest cases of congenital complete heart block reported.

Case 7. The diagnosis was first made when she was 5 years old. She attended the Heart Hospital from the age of 20 to 22 years. She looked a very healthy girl and was leading a normal quiet life working as a hairdresser. She had never been allowed to play games and was somewhat short of breath on any special exertion. She came to hospital because of tiredness and of feeling faint and giddy, but there was nothing to suggest that she had Stokes-Adams attacks, and ordinary attacks of faintness were actually observed. The heart was full size and she was thought to have a defect of the interventricular septum.

She is now 31 and writes: "I have not been engaged in any regular occupation for several years with the exception of light household duties. But since the war I have been doing sedentary work with an optical firm and I have managed this all right, though at times it makes me tired. Apart from an occasional visit to my own doctor I have had no treatment for nine years."

Case 8. The diagnosis was first made when he was 13 years. He was under observation at Guy's

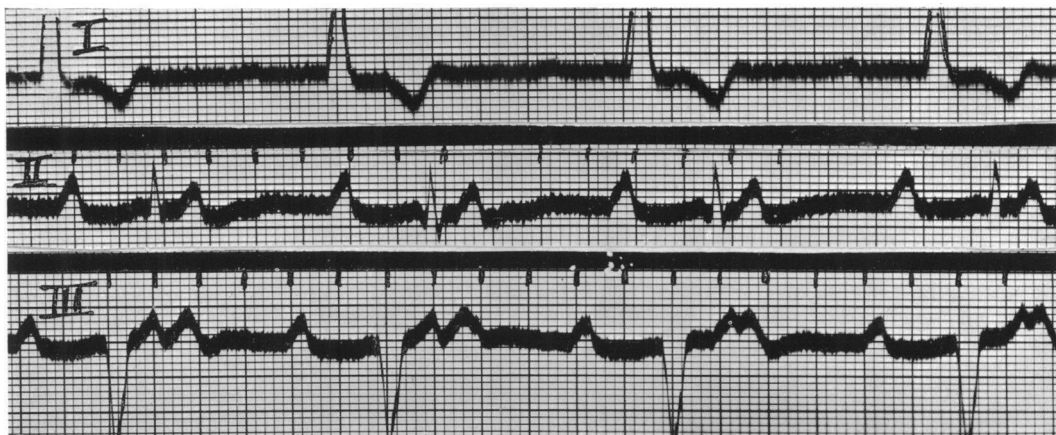

FIG. 1.—Case 8. The degree of heart block is probably complete, but it has the appearance of 2 : 1 block—a condition that is rare, if not unknown, in congenital cases—because the auricle is beating almost exactly twice as fast as the ventricle. The inversion of T in lead I has developed in the last ten years.

Hospital from then to 17 years, and felt well and was working in a bottling factory. His heart was slightly enlarged and he was thought to have a slight defect of the interventricular septum.

He was difficult to trace since the area in which he had lived was a waste of rubble as a result of enemy action. But by a curious coincidence he was attending Guy's Hospital at the time of this survey with a Colles' fracture sustained at work at Salisbury; he thought so little of his heart that he had not mentioned it at all.

He is now 26 and, though he was rejected from the army, has worked as hard as his mates, laying concrete floors for 54 hours a week, has played football in his club team, and has won several boxing matches. He has been regularly at work without medical attention for 9 years.

I have not been able to examine him, but have obtained a cardiogram which is shown (Fig. 1), because the signs of left ventricular preponderance with inversion of T in lead I, this last having developed since 1932 (see Fig. 13, *loc. cit.*), might suggest that it was associated with coronary atheroma or high blood pressure and not congenital; and also because it is suggestive of 2 : 1 heart block—a condition which I have not seen with congenital disease.

Case 9. *Not previously reported.* A dental surgeon, aged 29, came to see me in 1935 because his slow heart rate had led to difficulties about life insurance. His only recent illness had been a rather severe attack of migraine six months before, with vomiting, faintness, and hemianopia; he had reduced his cigarette smoking and there had been no recurrence.

His heart rate was generally between 36 and 42 and the electrocardiogram confirmed complete

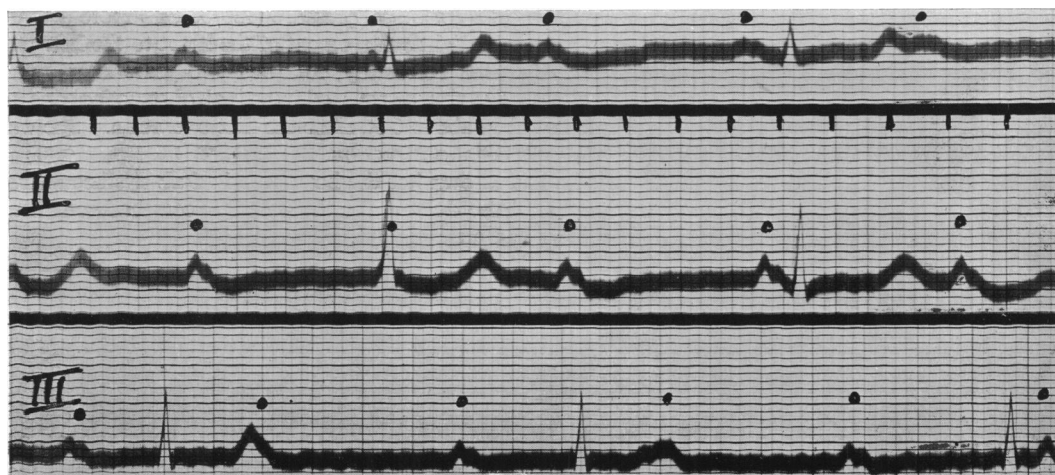


Fig. 2.—Case 9. Congenital complete heart block in a man of 29 with few symptoms. Auricular rate 80; ventricular rate 36; this could easily be increased to 50 after exercise.

heart block without any other abnormality. The heart was full-sized or a little enlarged to the left (max. trans. diam. 11.5 cm. in a chest of 21.5 cm.) with a rounded left ventricle. There was a systolic murmur, loudest half-way between the apex and the mid-line, which was thought to indicate a patent interventricular septum, though it was softer than in most such cases. The blood pressure was 125/80 and no other abnormality was found. The heart rate quickened a little with exercise, rising from 18 in the half-minute before to 27 and 23 in the first two half-minutes after a simple stepping exercise (18 steps a minute for 3 minutes).

The diagnosis of complete heart block had not been made at an early age so as to make it certain that this was congenital, but there was no history of rheumatism or diphtheria or of other serious illness, and he had seen Dr. R. O. Moon in early childhood because there was some question about his heart being enlarged. His mother remembered the heart was then said to be slow and that the doctors always seemed very interested. Dr. Moon wrote that he had never found anything to suggest rheumatic or other inflammatory disease and that after keeping him under observation for some time he had allowed him to ignore it, and that he thought the diagnosis now made was probably correct, though he had no notes available to confirm the actual rate of the pulse.

I advised that he should lead a normal life and that he should be accepted for life assurance with a small extra. It is interesting that as a student at Guy's he remembered being admitted to hospital with jaundice and being demonstrated as a case of bradycardia due to this, showing how readily congenital heart block may be overlooked.

He is now 36 years of age, feels quite fit and leads a normal life, practising as a dentist, cycling (since the war), and gardening. His pulse rate is generally between 35 and 40.

One other new case, though not of interest from the present point of view, may be mentioned because of the post-mortem finding of a patent foramen ovale without any patency of the inter-ventricular septum.

Case 10. A girl, aged 8 months, was admitted under Dr. E. C. Warner for severe malnutrition. She was short of breath, even feeding, and the heart was enlarged, with the rate between 48 and 60. A diagnosis of congenital complete heart block was made and she was sent to see me. The diagnosis was confirmed by a cardiogram (auricle, 114; ventricle, 44), which was normal otherwise. There was thought to be a patent septum on the evidence of a systolic murmur.

She died a few weeks later and Dr. Warner wrote that the heart was much enlarged with collapse of the left upper lobe of the lung. There was a large patent foramen ovale, but no visible abnormality in the interventricular septum or elsewhere in the heart, which unfortunately was not kept.

Probably, some of the elderly patients with complete heart block of unknown ætiology are in fact congenital cases that have not been recognized, partly because the pulse is generally not nearly as slow as with acquired heart block. The following case might perhaps be of this nature though the evidence is very incomplete.

She was first seen by me when she was 65, with symptoms of intestinal obstruction. She had led a semi-invalid life for 20 years. She had no cardiac symptoms, but the heart rate was 40 due to complete heart block. There were no murmurs, no rise of blood pressure (130/80), no more arterial thickening than might be expected at her age, and only slight enlargement of the heart to the left.

Twenty years before she had an unfortunate partial colectomy, followed two years later by an operation for partial obstruction and subsequently by two attacks of intestinal obstruction due to volvulus. Her weight was 4 st. 9 lb. and had not been above 6 st. since the first operation. She was relieved of this attack but died a year later with intestinal obstruction.

Her doctor wrote that during the 7 years he had known her the heart rate had always been slow, and that he thought it had always been slow as all the doctors for the past 20 years had remarked on it. He also reported that one of her brothers had a slow pulse.

This history only takes her heart block back till she was 45, but as it was symptomless and found by chance it may well have been there before, for if it had been due to coronary disease something more would probably have been found after 20 years. The rate of 40 is slower than in many congenital cases, but the idiopathic ventricular rate may perhaps become slower as the patient gets older.

#### SUMMARY AND CONCLUSIONS

The present condition of seven cases of congenital complete heart block, now aged 42, 36, 31, 28, 26, 25, and 22 is reported shortly. Full details about six of them were published nine years ago. All these six and one other (first seen shortly after the paper was published) have been traced—a very satisfactory result after this interval of nine years, especially in war time.

All are alive and well, and their degree of activity could be taken as a fair cross section of the general public. Of the four men, two are working men, who though rejected from the army have led strenuous lives, both in their work and in their play—almost certainly doing more than they ought to as their hearts are not normal. One has been two years in the R.A.F. and has been passed for flying duties, and the fourth is a professional man who leads a normal life with gardening and cycling in his spare time.

Of the three women the eldest does ordinary housework on a farm, but the other two lead rather more sheltered lives, possibly because their doctors have discouraged them too much. One was at easy work till she developed tuberculosis a year before her marriage, and the other after doing light duties at home for six years has taken up sedentary work since the war. Except for the one case of tuberculosis, no unexpected developments have arisen in any case, and the one who had Stokes-Adams attacks in infancy has led the most strenuous life with only two short periods of recurrences.

Congenital complete heart block is not rare. It is overlooked because the rate is relatively fast, about 40–56, and also because the possibility is not remembered.

If there are no special complications carrying special risks of their own, the prognosis is good, and it will probably prove that the condition is compatible with survival to old age.

#### REFERENCES

- Campbell, M., and Suzman, S. (1934). *Amer. Heart J.*, 9, 304.  
 Peel, A. A. F. (1943). *Brit. Heart J.*, 5, 11.