

MS ARD 2015-207709: Supplementary material

“Value of ultrasonography as a marker of early response to abatacept in patients with rheumatoid arthritis and an inadequate response to methotrexate: results from the APPRAISE study”

Maria-Antonietta D’Agostino et al. on behalf of the OMERACT-EULAR-Ultrasound Task Force

Methods

1. Scoring of joint effusion (JE) using greyscale ultrasound

The composite OMERACT-EULAR power Doppler and greyscale ultrasound (PDUS) score is a combination score obtained from synovial hypertrophy and power Doppler signal in the included joints; joint effusion (JE) does not participate to this combined score. This because effusion alone does not reflect completely the synovial inflammation, since it can also be observed in mechanical and degenerative joint diseases; thus would be less responsive to treatment. JE was therefore measured independently, using the following grading system:

Grade 0: No effusion

Grade 1: Minimal amount of joint effusion

Grade 2: Moderate amount of joint effusion (little distension of the joint capsule)

Grade 3: Extensive amount of joint effusion (with high distension of the joint capsule)

2. Atlas

See file below:

Ultrasound Atlas for BMS Clinical Protocol IM101179

**Dr Richard Wakefield
Dr Maria-Antonietta D'Agostino**

Overall Aims of ATLAS

- **Technique of image acquisition for individual joints**
 - **Model for interpreting and scoring synovitis using a composite score**
 - B-mode (or Gray scale)
 - Power Doppler
- PDUS**

Definition of singles PDUS components

(based on preliminary OMERACT definition)

Synovial Hyperplasia:

Abnormal hypoechoic* intraarticular tissue (e.g. inflamed tissue) or higher echoic (e.g. fibrotic tissue) that is not or poorly displaceable and which may exhibit Doppler signal

Doppler signal:

Abnormal vascularization detected within the hypoechoic synovial hyperplasia

Synovial Effusion:

Abnormal anechoic* or hypoechoic* intraarticular material that is easily displaceable, but does not exhibit Doppler signal

**relative to subdermal fat*

PDUS definition of synovitis in RA

(based on preliminary OMERACT definition)

Synovitis is defined as :

Hypoechoic* synovial hyperplasia in the joint space, which may exhibit Doppler signal.

** compared with subdermal fat*

Grading system

- **For both Power Doppler and Gray scale we will use a semi-quantitative scoring system 0-3**

Gray scale: General Considerations

- Remember to optimise the gray scale images
 - Use minimal number of focal zones
 - Ensure focus points are on region of interest
- Observe full extent of joint space (capsule) proximally and distally
- Ensure pathology seen in both longitudinal and transverse views, but record images only in longitudinal view

Power Doppler: General Considerations

- **Observe full extent of joint space (capsule) proximally and distally**
- **Take care not to press the probe too hard**
- **Ensure colour box captures whole joint and that box reaches skin surface**
- **For Doppler settings, increase gain to point that you just beginning to get background noise; settings should be same for subsequent scans**

Scoring methodology

There will be 3 methods employed for scoring synovitis in each joint

- **Gray scale**

- **Power Doppler**

- **PDUS total score** – which is a composite score of both gray scale and power Doppler scores

How to assess gray scale grading – general examples (not exhaustive!!)

- **Grade 0** – no effusion or hypertrophy
- **Grade 1** – minimal: below or approximately at the level of bony joint line
- **Grade 2** – moderate: above level of bony joint level but without complete distension of joint capsule (forming concavity of upper joint surface)
- **Grade 3** – severe: above level of bony joint line with distension of joint capsule (forming convexity of upper surface)

Joint effusion (gray scale scoring)

- **grade 0** = no effusion
- **grade 1** = minimal amount of joint effusion
- **grade 2** = moderate amount of joint effusion
- **grade 3** = extensive amount of joint effusion

Inflammatory or active synovial hyperplasia (gray scale scoring)

- **grade 0** = no hypoechoic synovial hyperplasia
- **grade 1** = minimal hypoechoic synovial hyperplasia
- **grade 2** = moderate hypoechoic synovial hyperplasia
- **grade 3** = severe hypoechoic synovial hyperplasia

Power Doppler scoring

- **grade 0** = no flow in the synovium (gray scale area)
- **grade 1** = up to 3 single spots signals or up to 2 confluent spots or 1 confluent spot + up to 2 single spots
- **grade 2** = vessel signals in less than half of the area of the synovium (< 50%)
- **grade 3** = vessel signals in more than half of the area of the synovium (> 50%)

PDUS composite scoring of synovitis

- **Grade 0 (normal joint):**

No greyscale-detected synovial hyperplasia and no PD signal

- **Grade 1 (minimal synovitis):**

Grade 1 synovial hyperplasia and \leq Grade 1 PD signal

- **Grade 2 (moderate synovitis):**

Grade 2 synovial hyperplasia and \leq Grade 2 PD signal;

OR Grade 1 synovial hyperplasia and Grade 2 PD signal

- **Grade 3 (severe synovitis):**

Grade 3 synovial hyperplasia and \leq Grade 3 PD signal;

OR Grade 1 or 2 synovial hyperplasia and Grade 3 PD signal

Machines used in ATLAS

- These images have been taken with 4 machines – Philips HDI 5000, GE E9, Esaote Technos MPX, Esaote MyLab70

Joint to be evaluated

• 44 joint count

- Shoulders (2)
- Elbows (2)
- Wrists (2)
- Metacarpophalangeal joints - MCPJ (10)
- Proximal interphalangeal joints - PIPJ (10)
- Knees (2)
- Ankles (2)
- Metatarsophalangeal joints - MTPJ (10)
- Talonavicular joint - TNJ (2)
- Calcaneocuboidal joint - CCJ (2)

Remember!

Primary objective: MCPJ from 2nd to 5th bilaterally

Secondary objective: all other joints

General considerations for grading and recording images

- **The whole of the dorsal aspect of each joint is examined in a sweeping fashion in both longitudinal and transverse planes**
- **Knee and wrist are examined also in a lateral view**
- **Elbow is examined by using anterior and posterior view**
- **Shoulder is examined by using posterior and axillary view**
- **Images of pathology are recorded**
- **Only the highest score for each joint is recorded (independently of the used scan)**

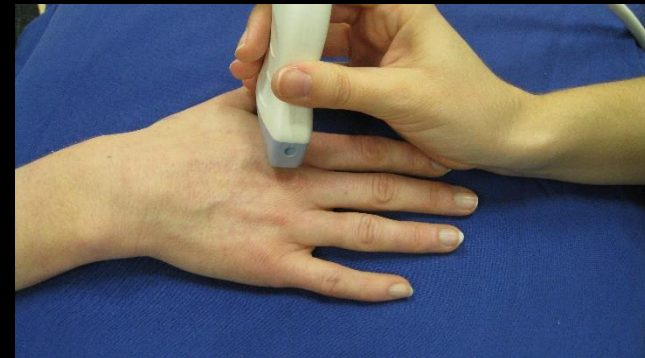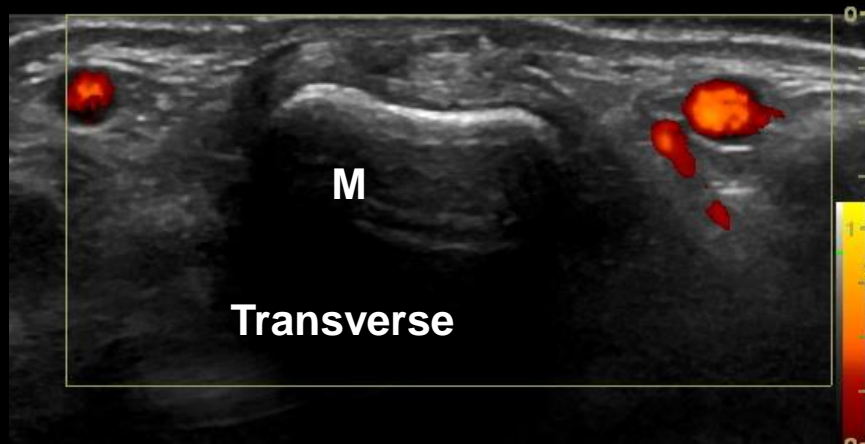
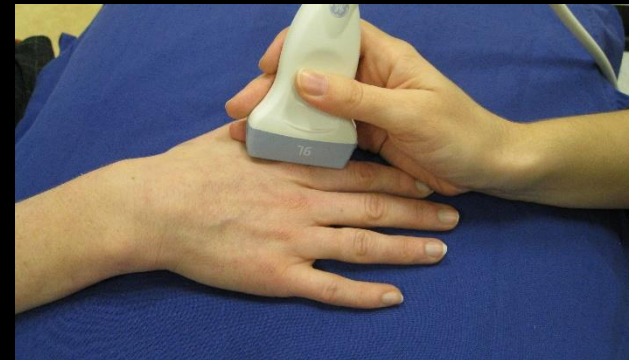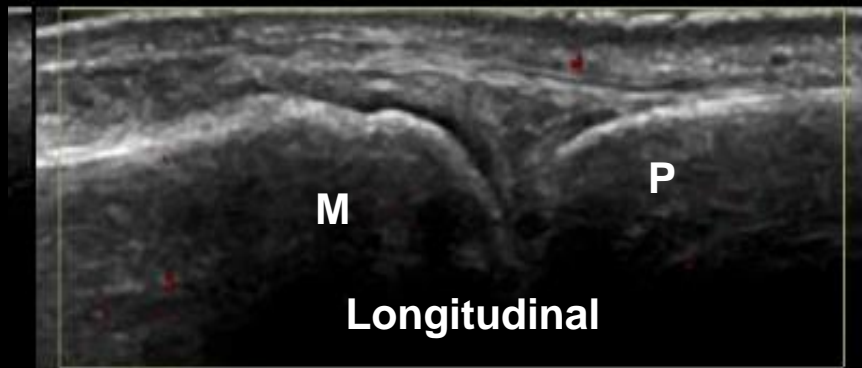Metacarpo-phalangeal joints (primary objective!!!)

- **The whole of the dorsal aspect of each joint is examined in a sweeping fashion in both longitudinal and transverse planes**
- **Images of pathology are recorded**
- **Only the highest score is recorded**

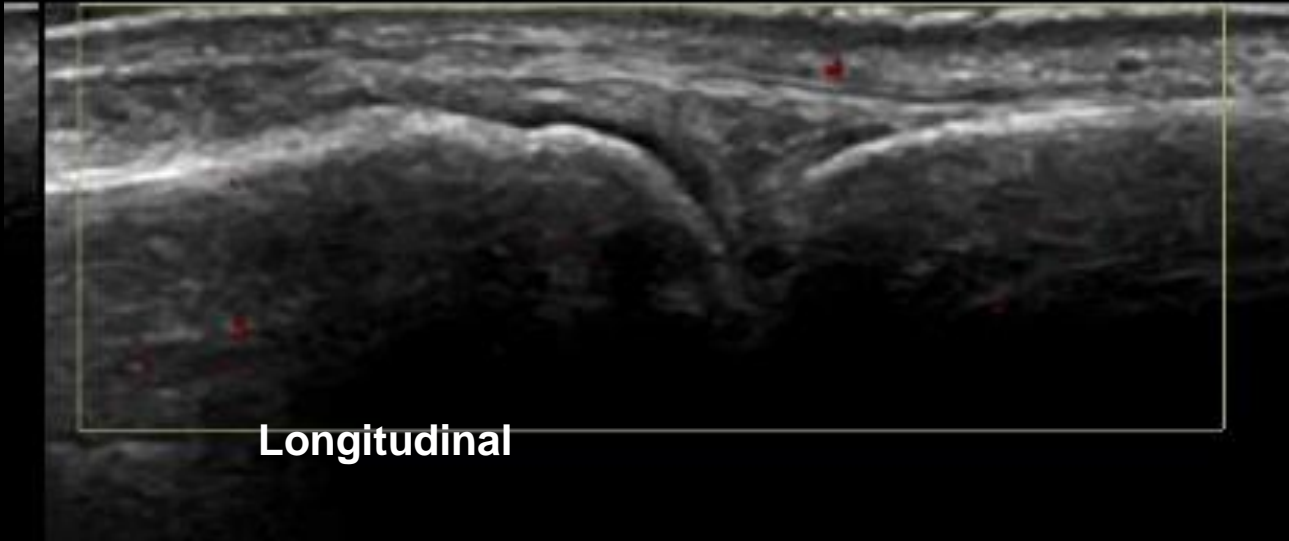
MCP – The Normal Joint – Dorsal view

Clearly defined cartilage over the metacarpal head (M)

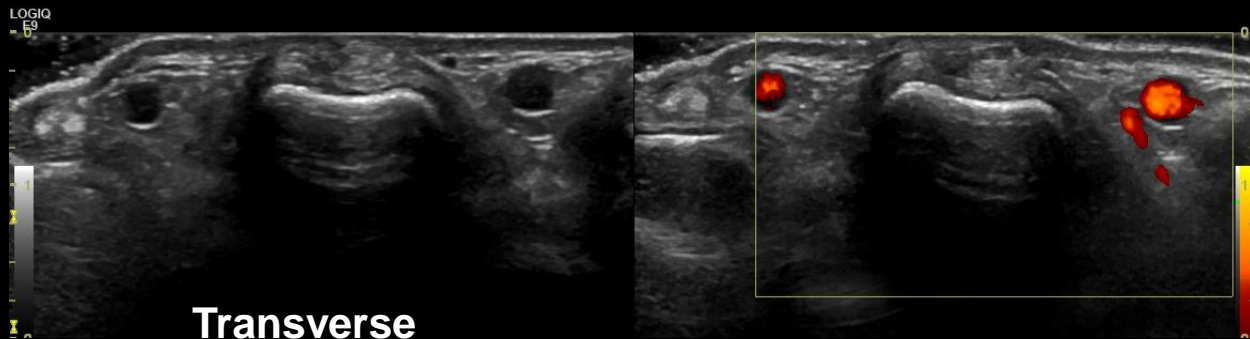
- Iso-echoic tissue (compared with sub-dermal tissue) within the joint space
- No Doppler signal within the joint space



MCP – Dorsal – Effusion – Grade 0

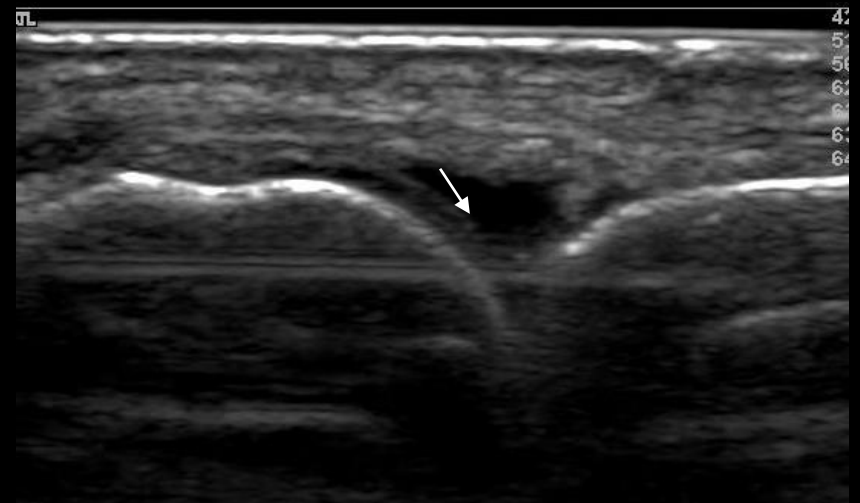
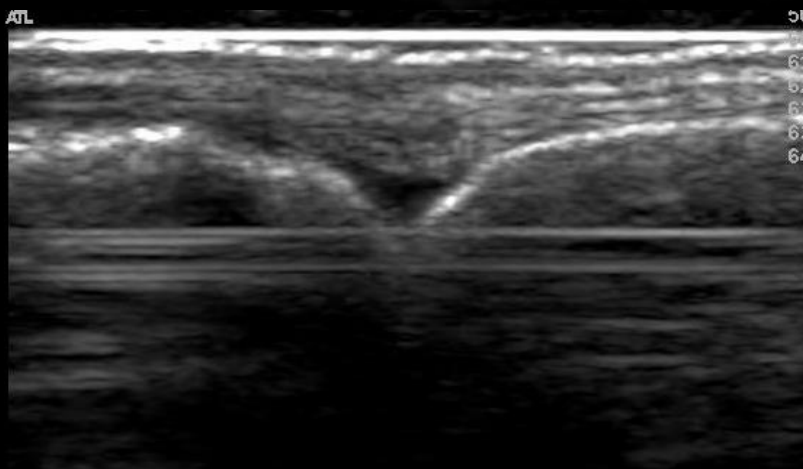
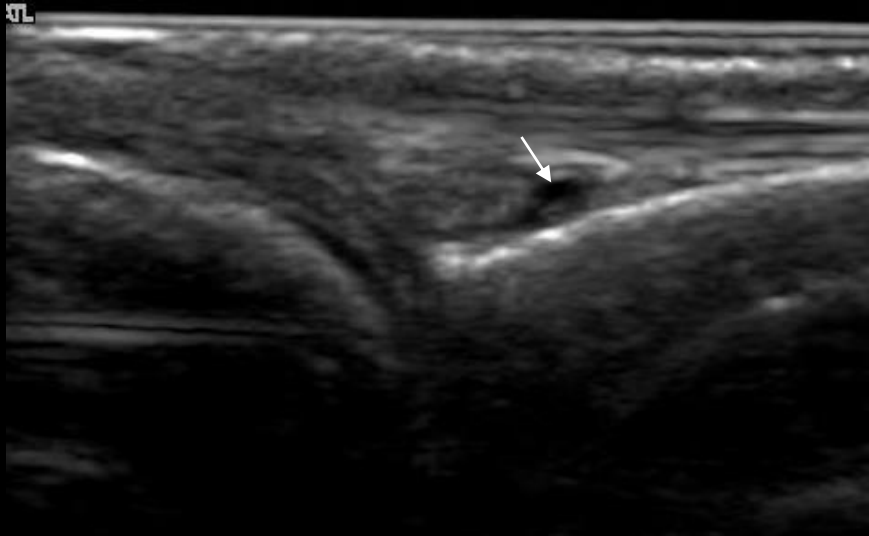


Longitudinal

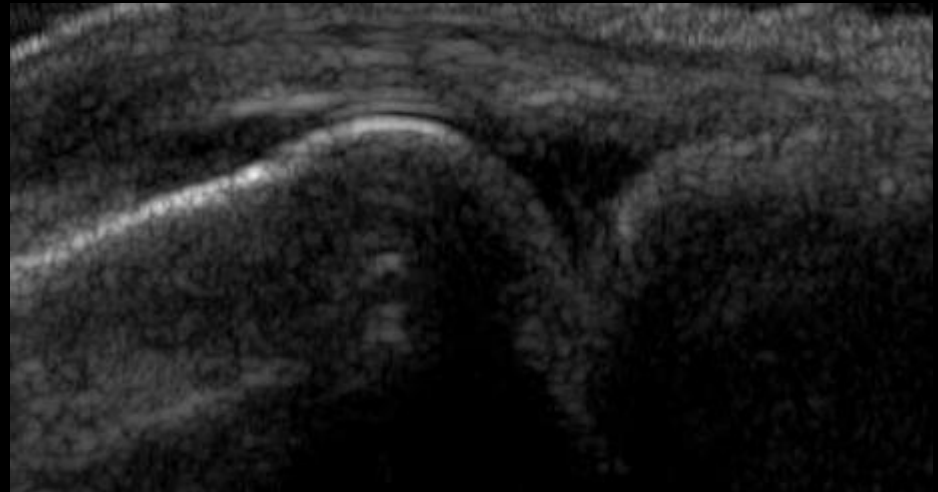
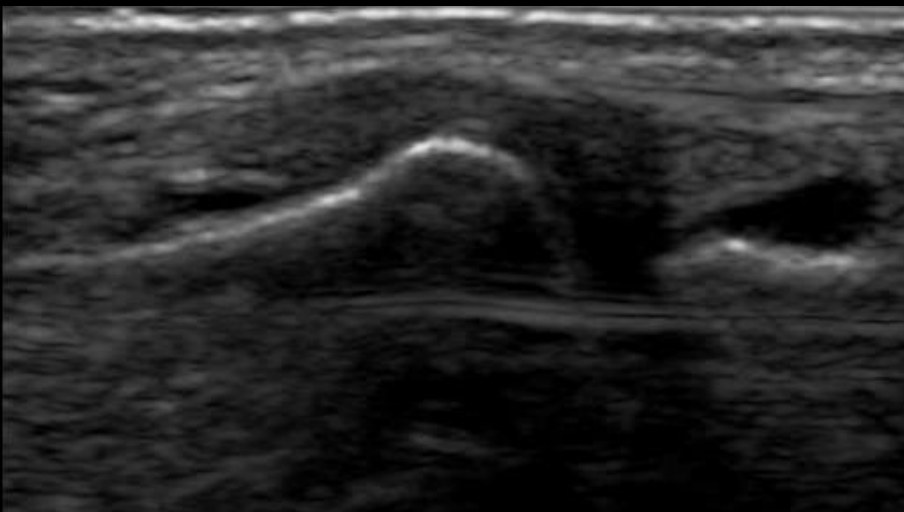
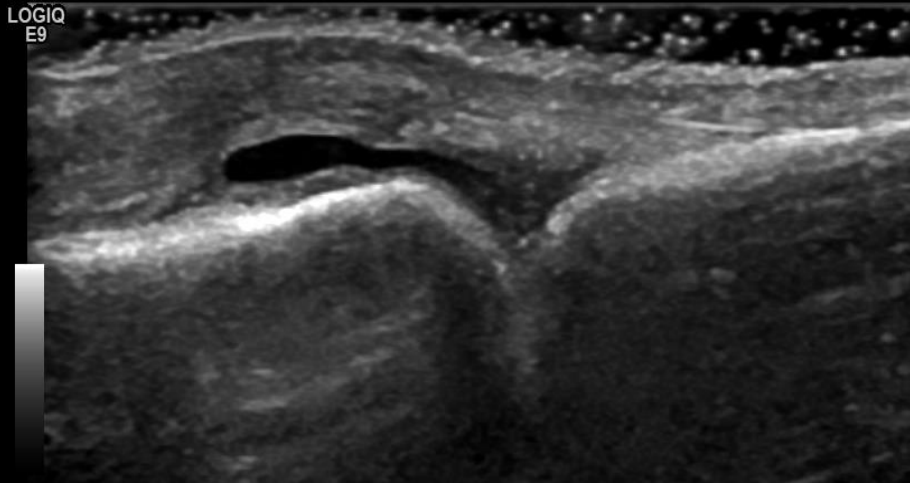


Transverse

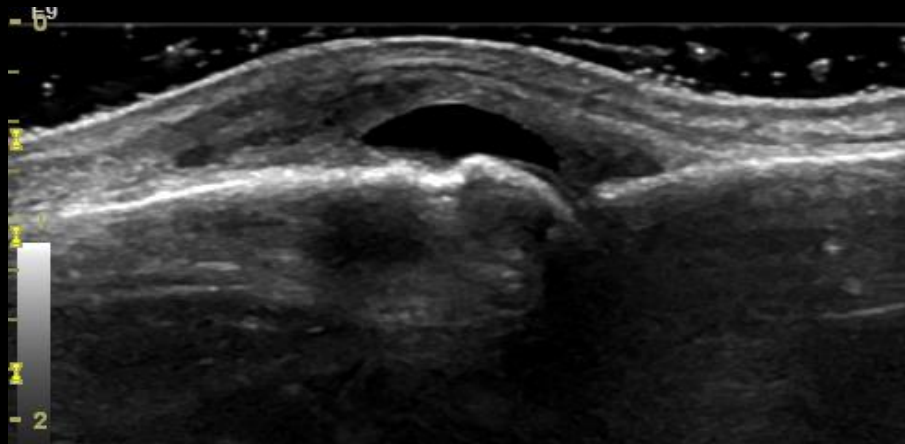
MCP – Dorsal – Effusion – Grade 1



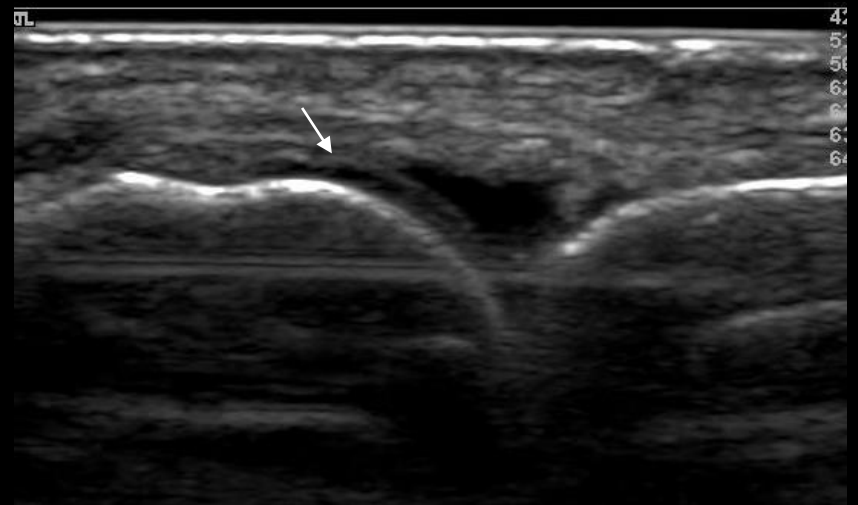
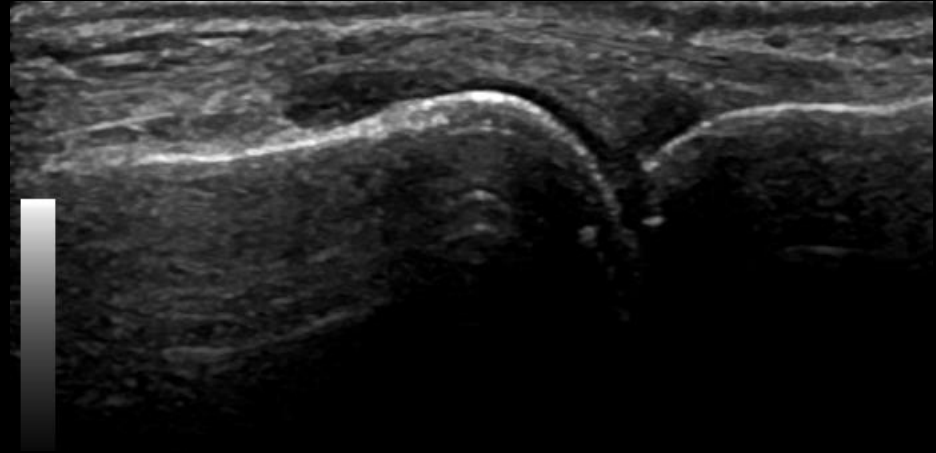
MCP – Dorsal – Effusion – Grade 2



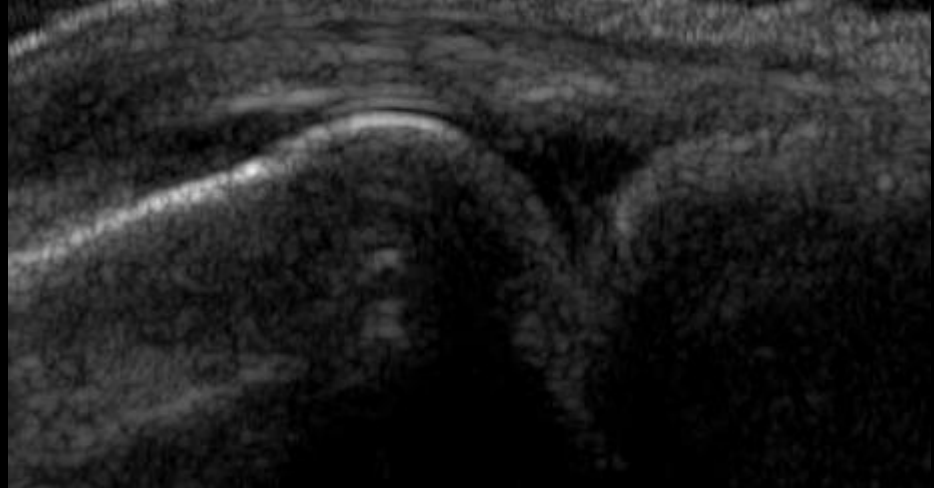
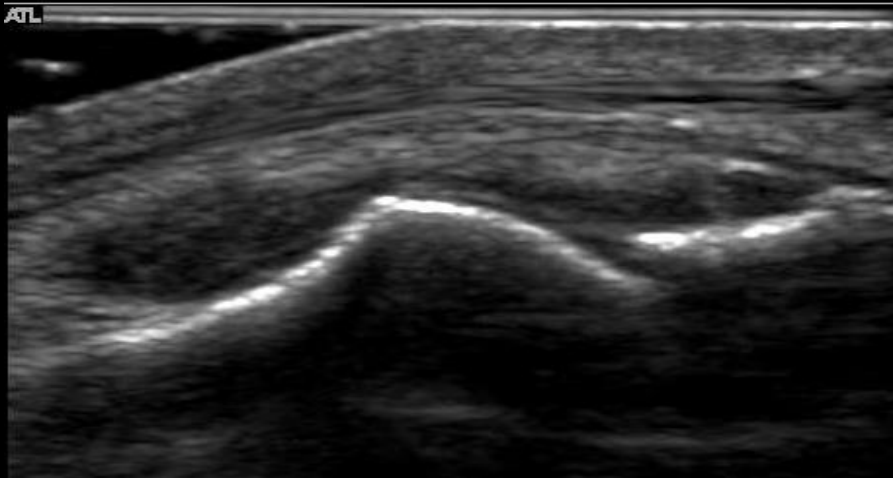
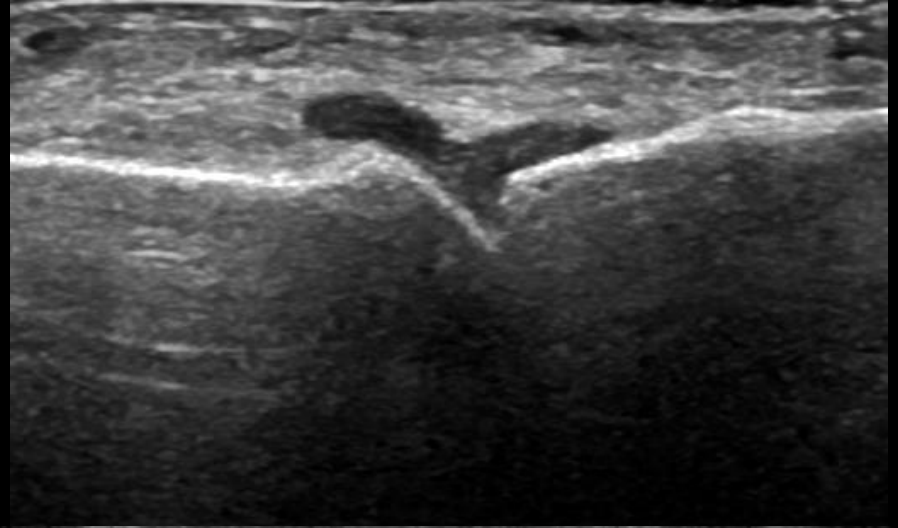
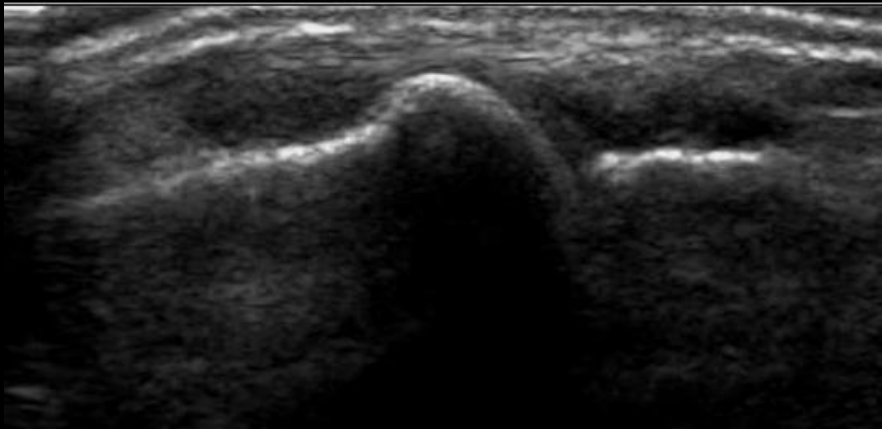
MCP – Dorsal – Effusion – Grade 3



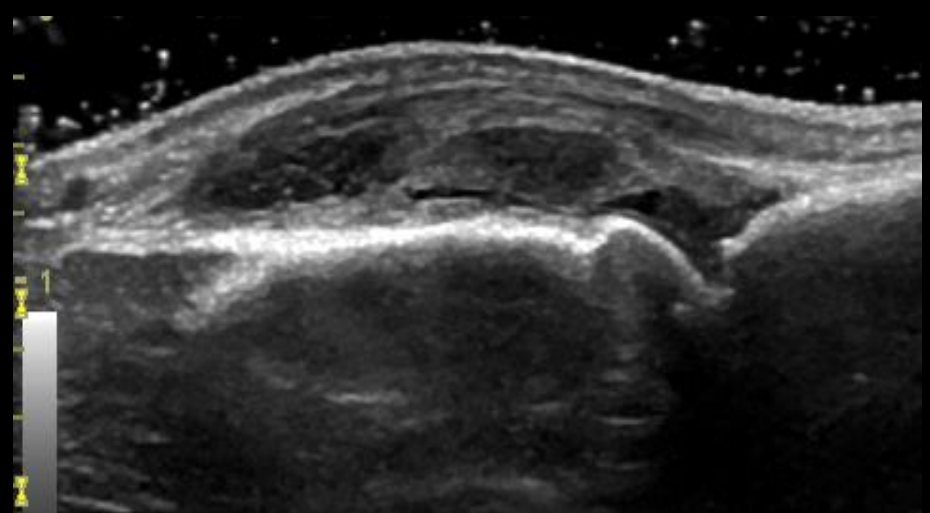
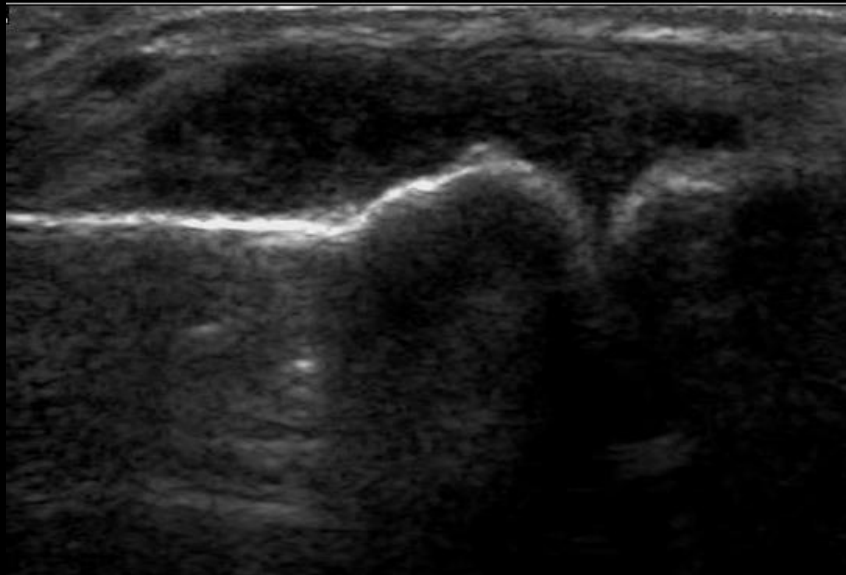
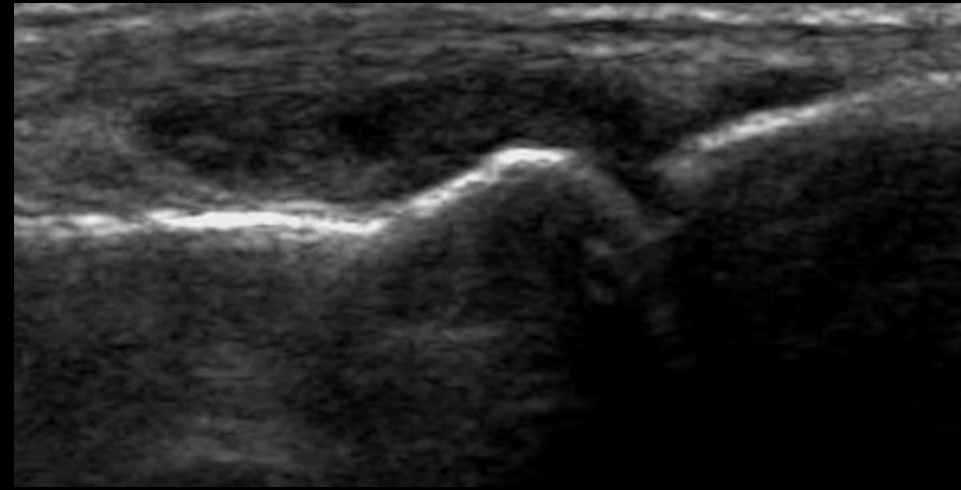
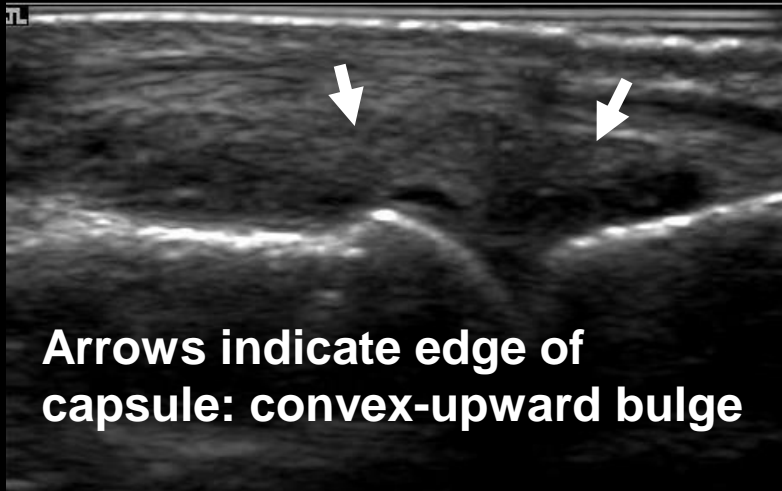
MCP – Dorsal – Synovial hypertrophy – Grade 1



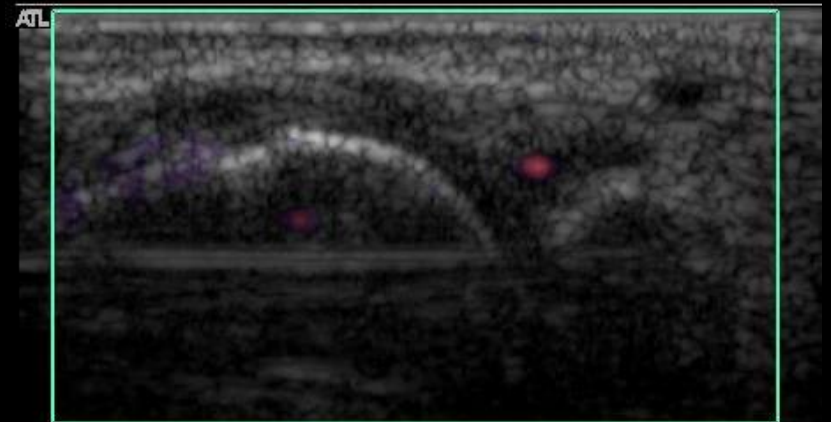
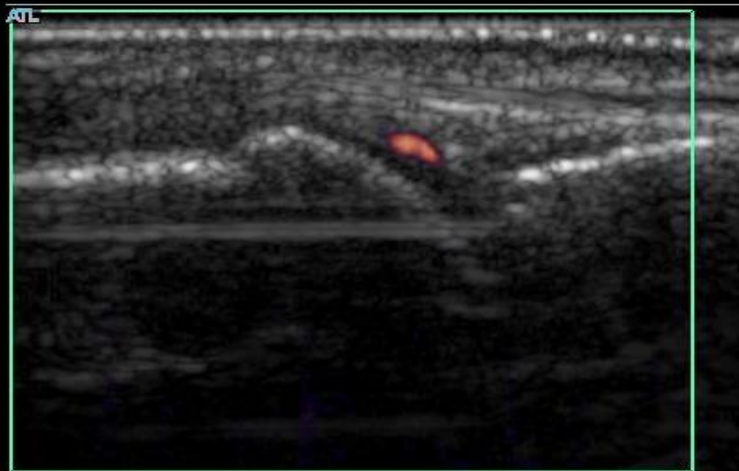
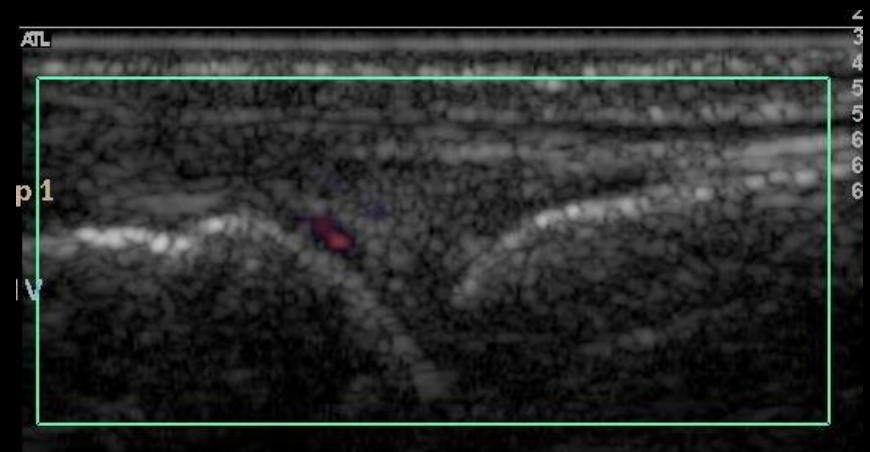
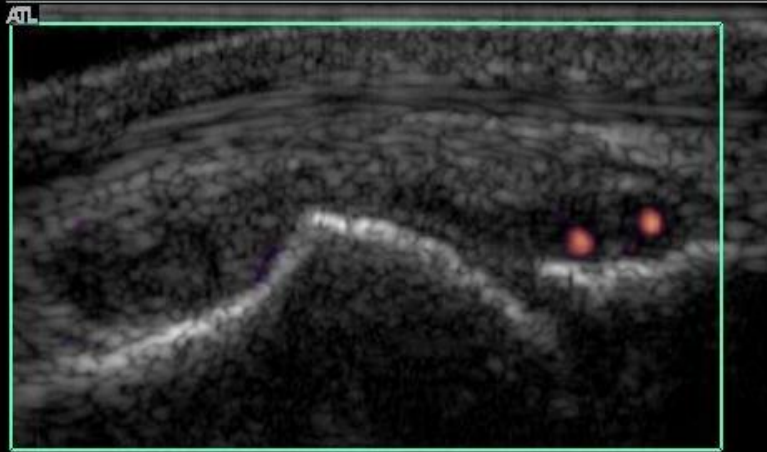
MCP – Dorsal – Synovial hypertrophy – Grade 2



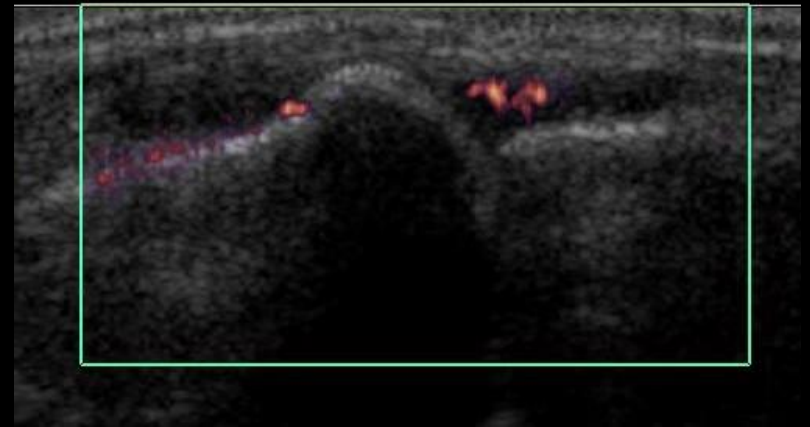
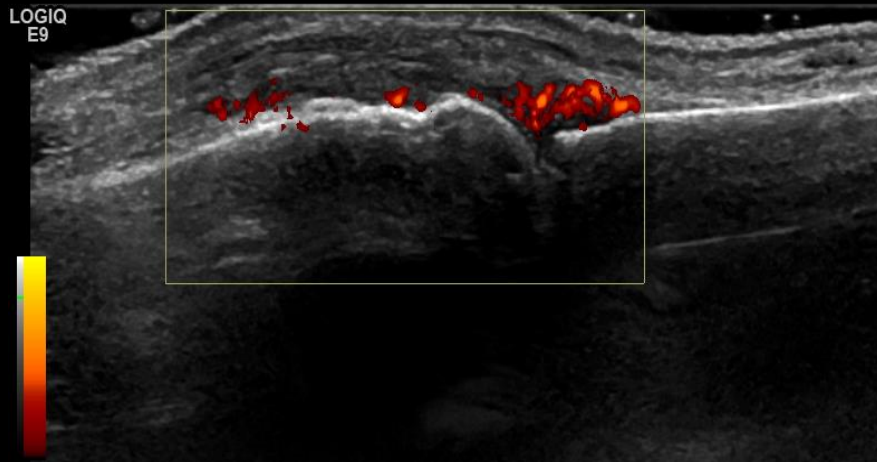
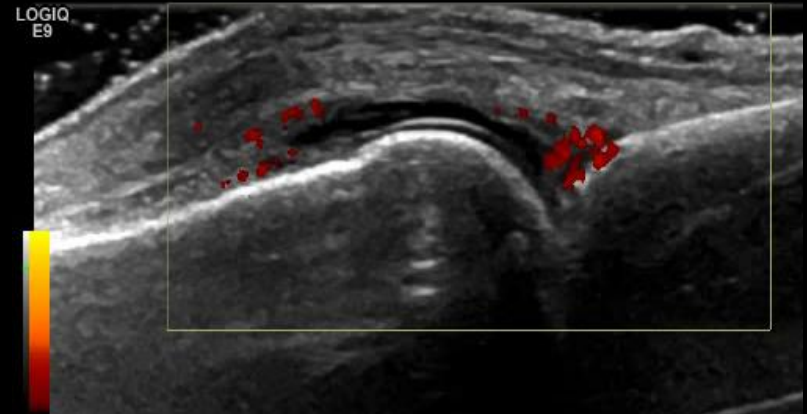
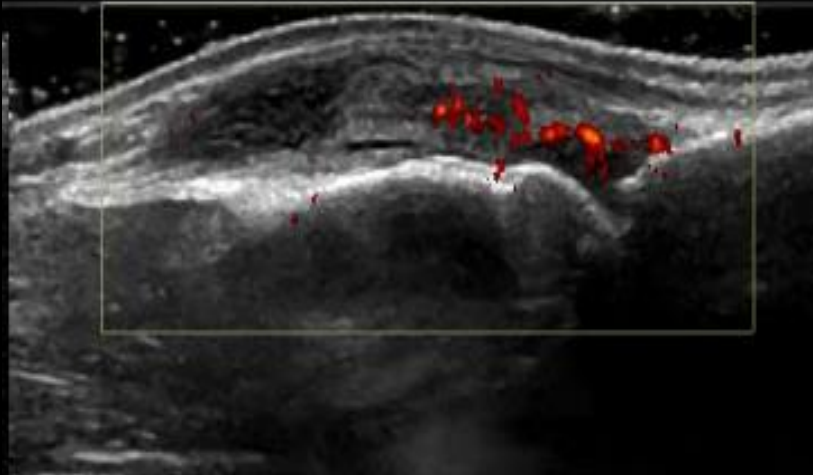
MCP – Dorsal – Synovial hypertrophy – Grade 3



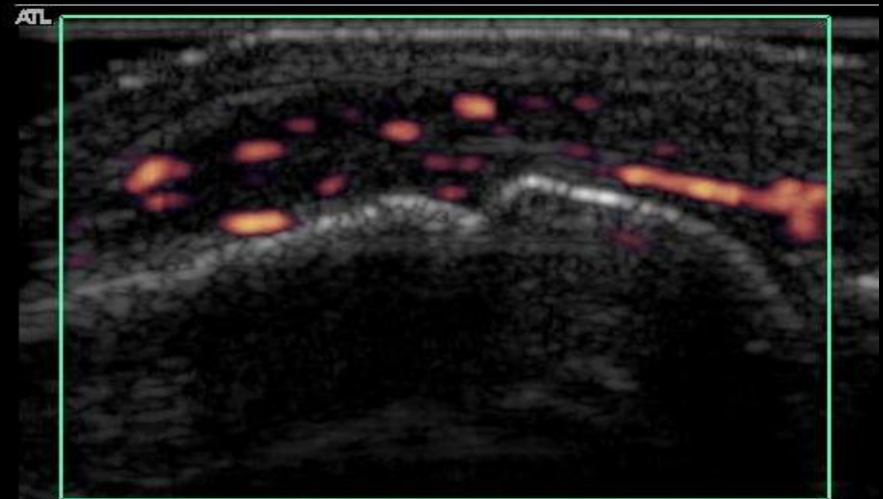
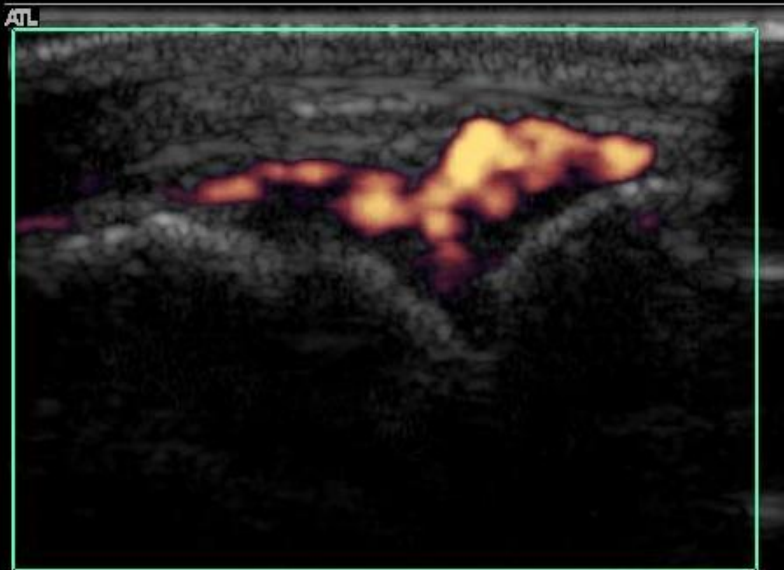
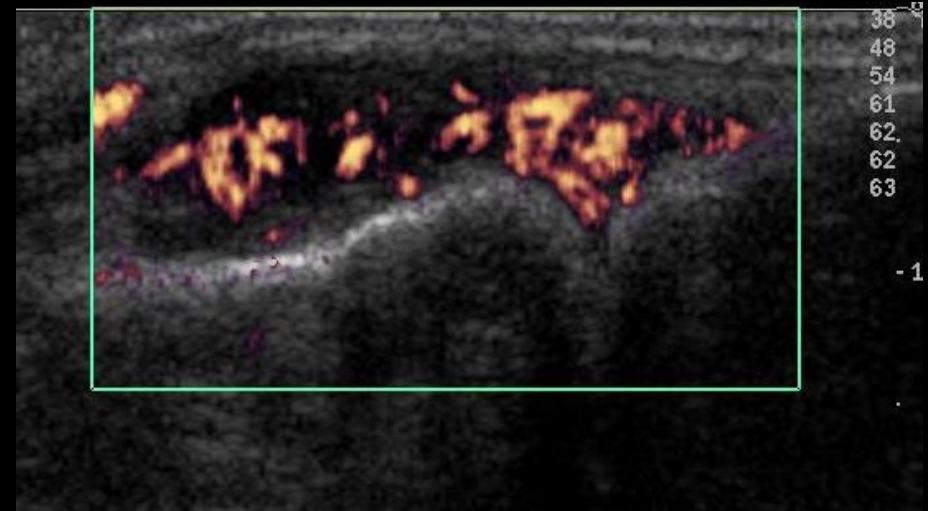
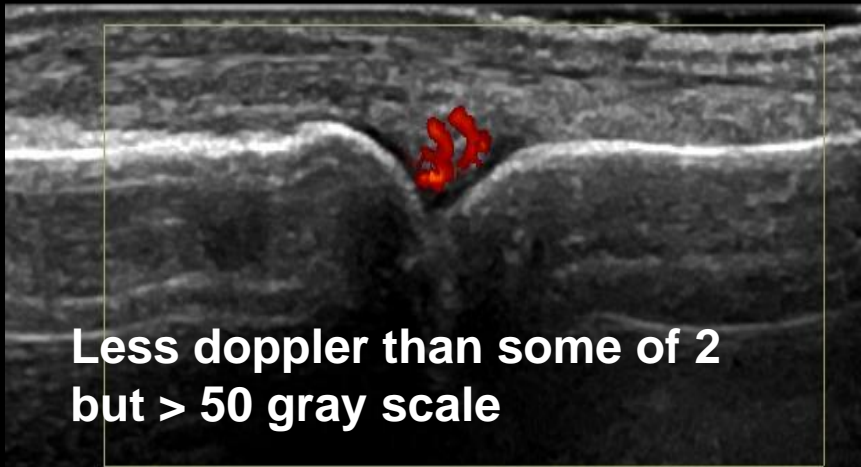
MCP – Dorsal – Doppler – Grade 1



MCP – Dorsal – Doppler – Grade 2

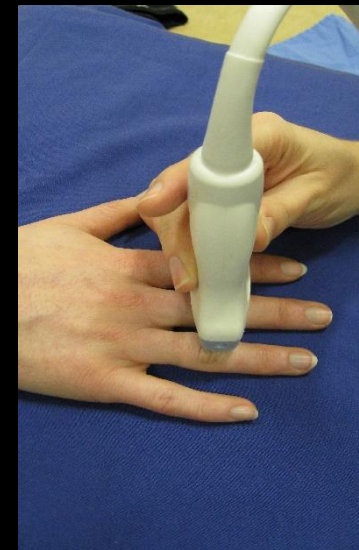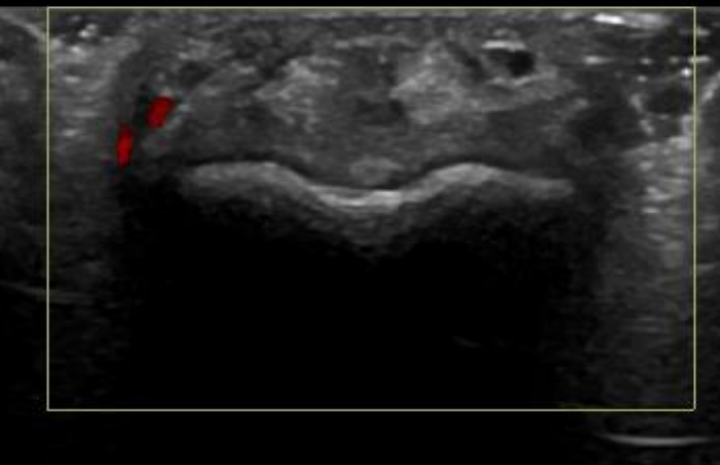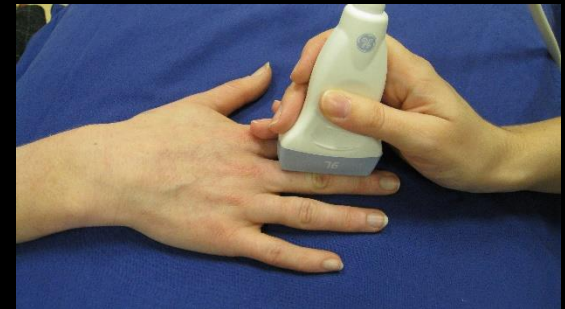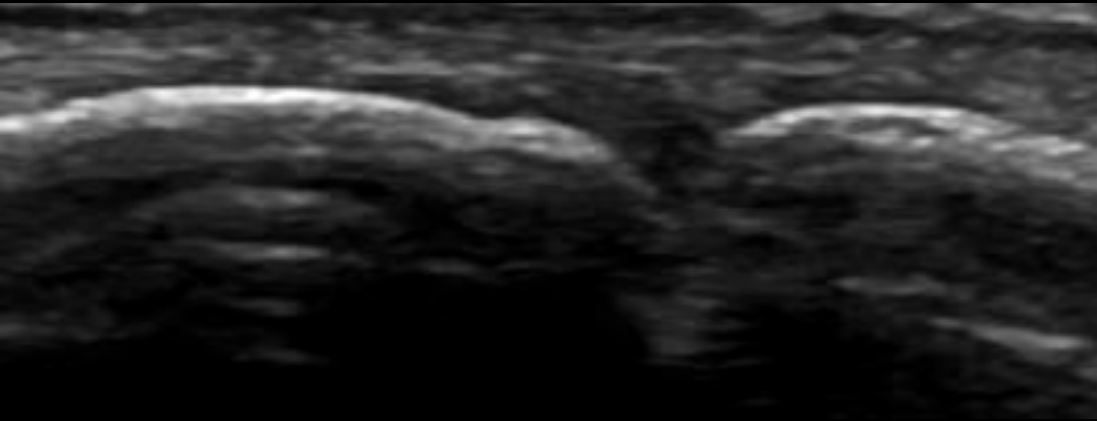


MCP – Dorsal – Doppler – Grade 3

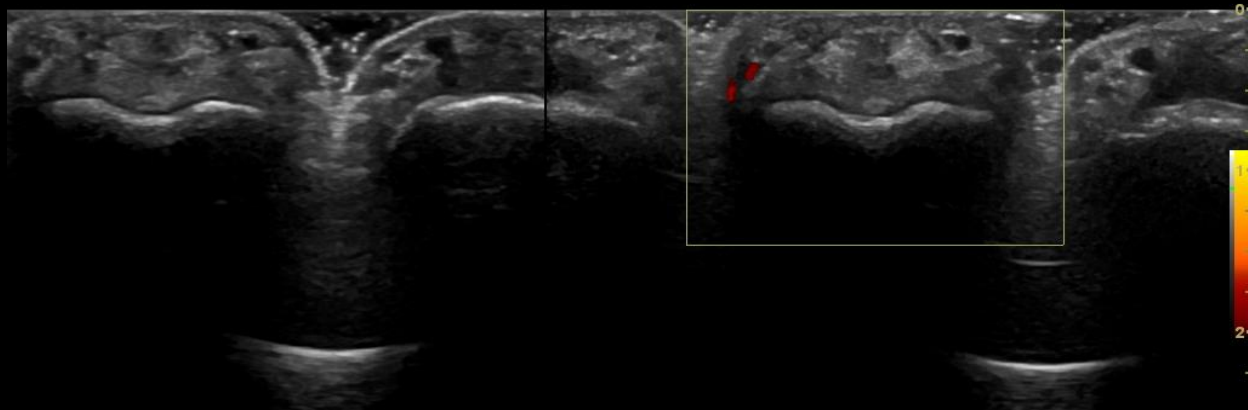
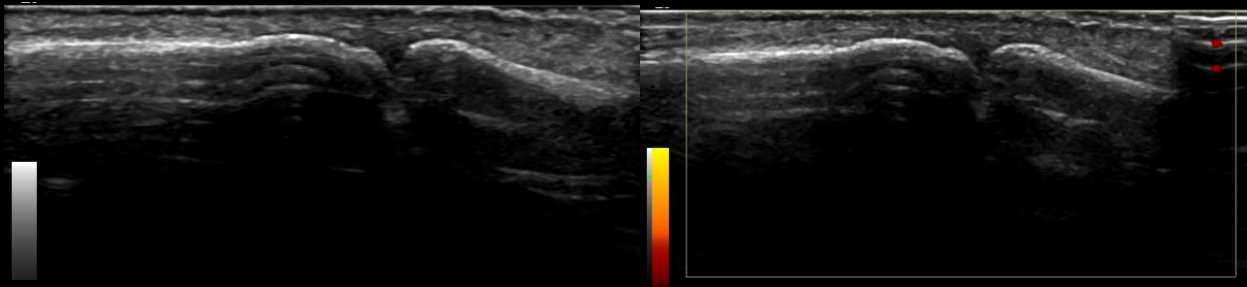


Proximal inter-phalangeal Joints – The Normal Joint – Dorsal view

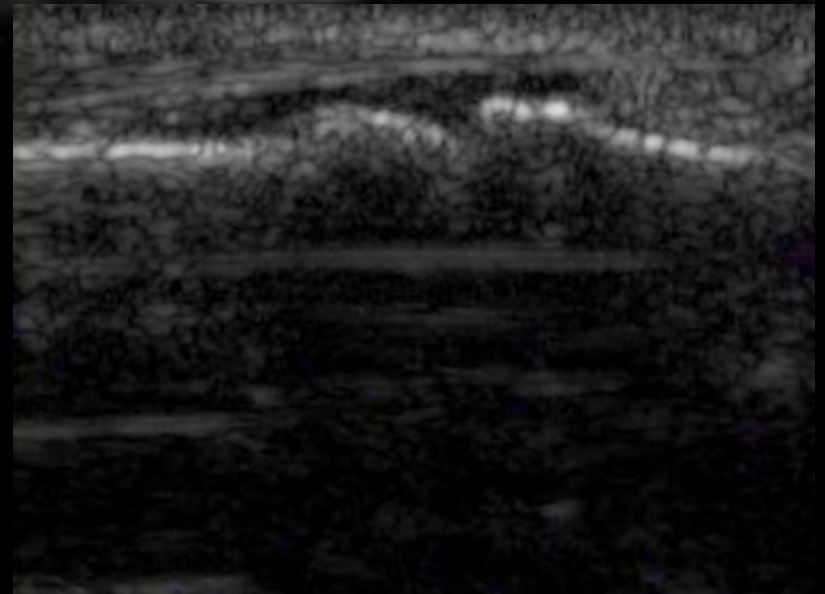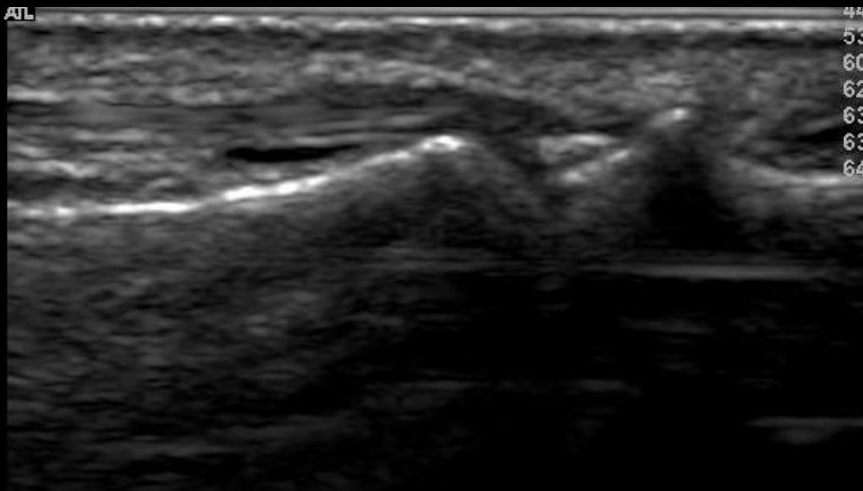
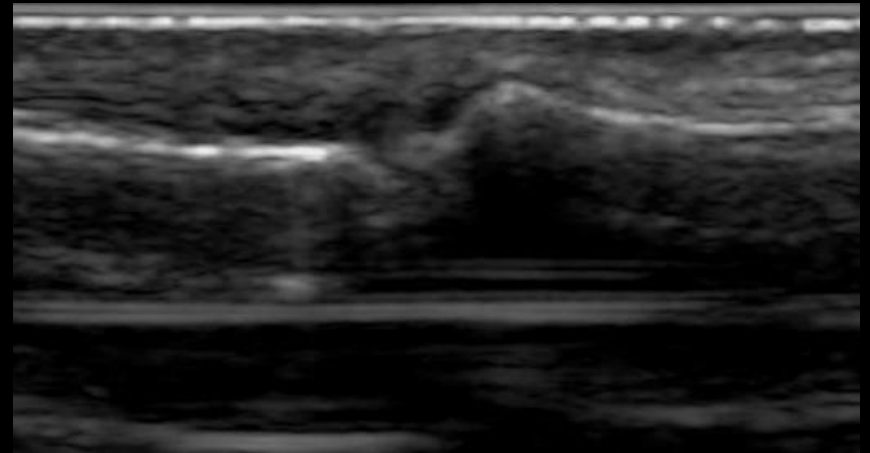
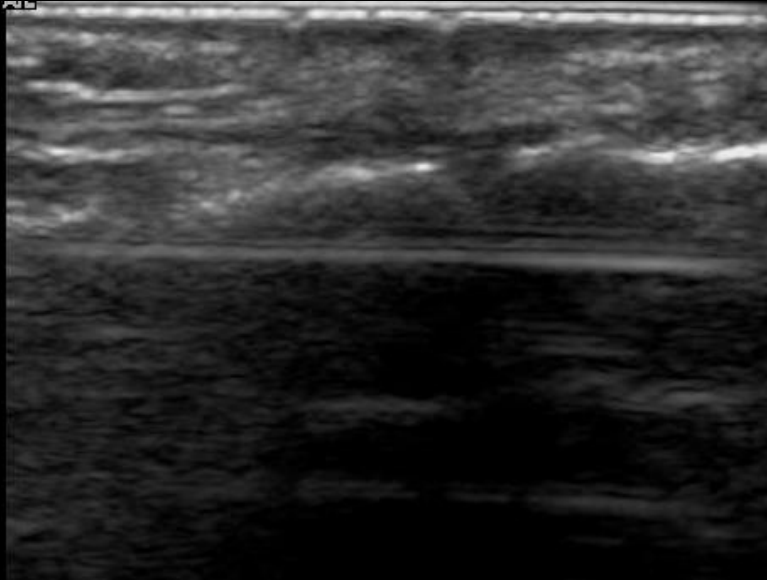
- No hypo- or anechoic area (synovial hypertrophy or effusion) overlying the joint
- No Doppler signal within the joint space



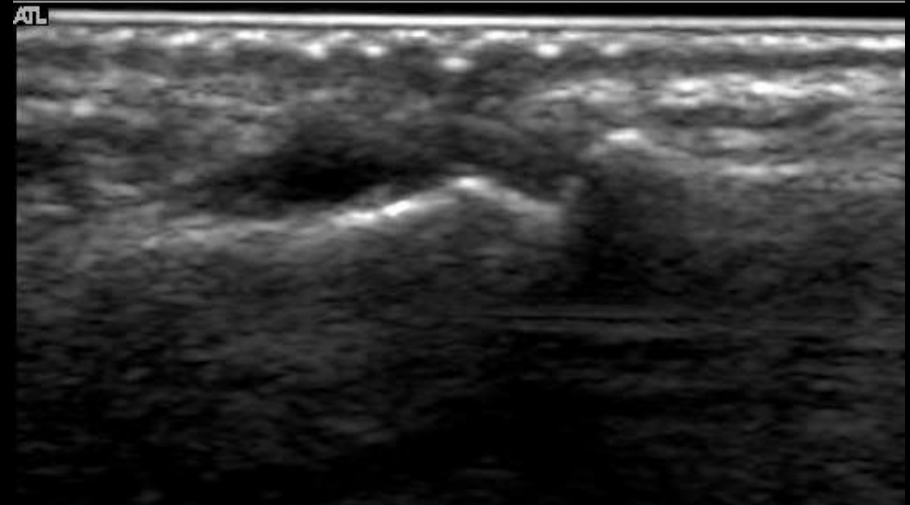
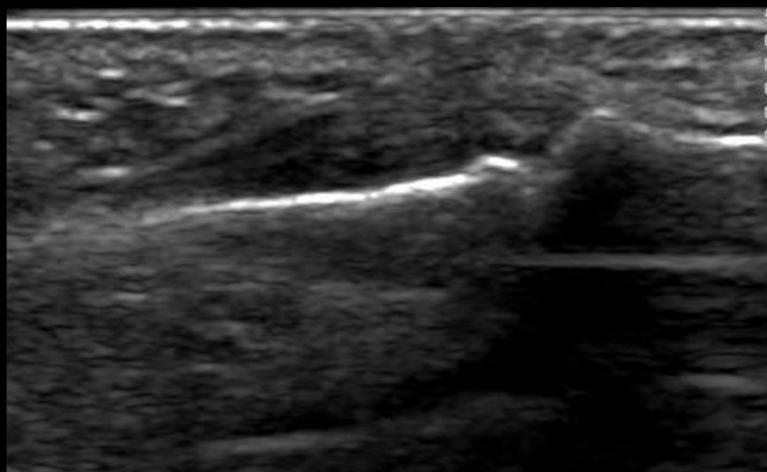
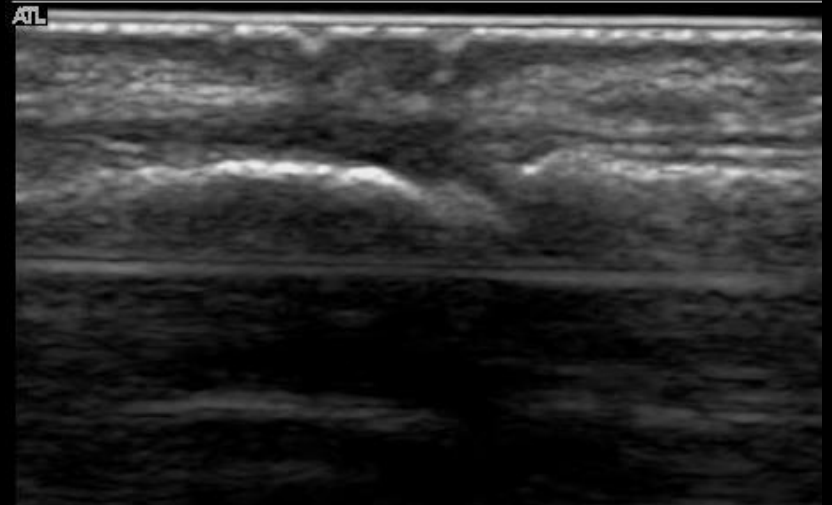
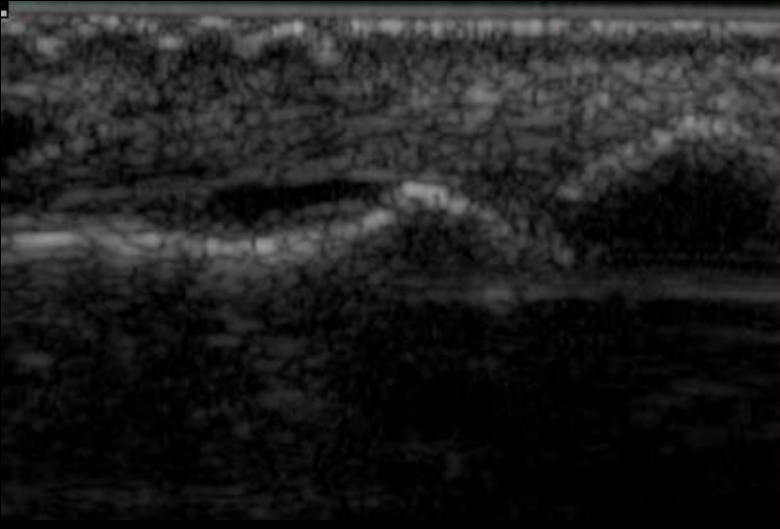
PIP – Dorsal – Effusion and synovial hypertrophy – Grade 0



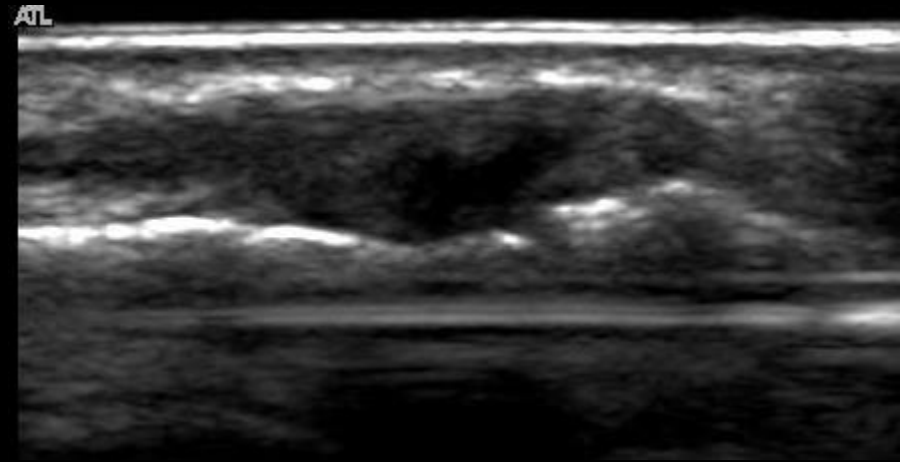
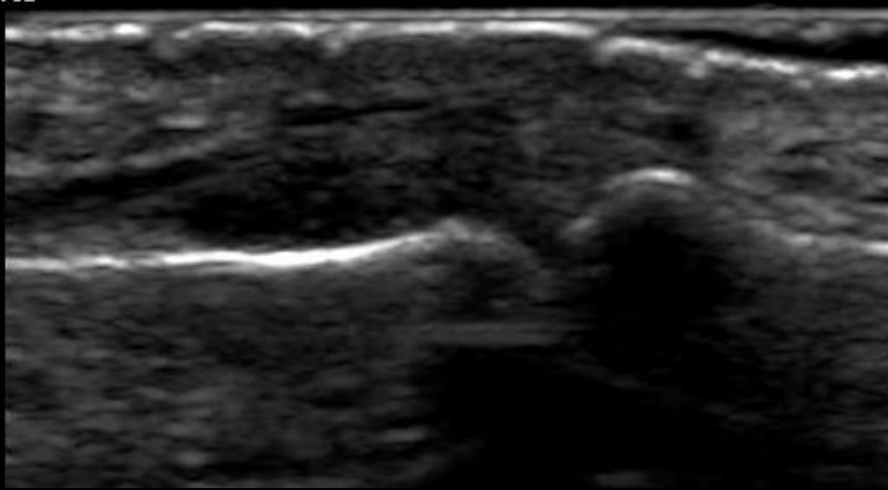
PIP – Dorsal – Synovial hypertrophy – Grade 1



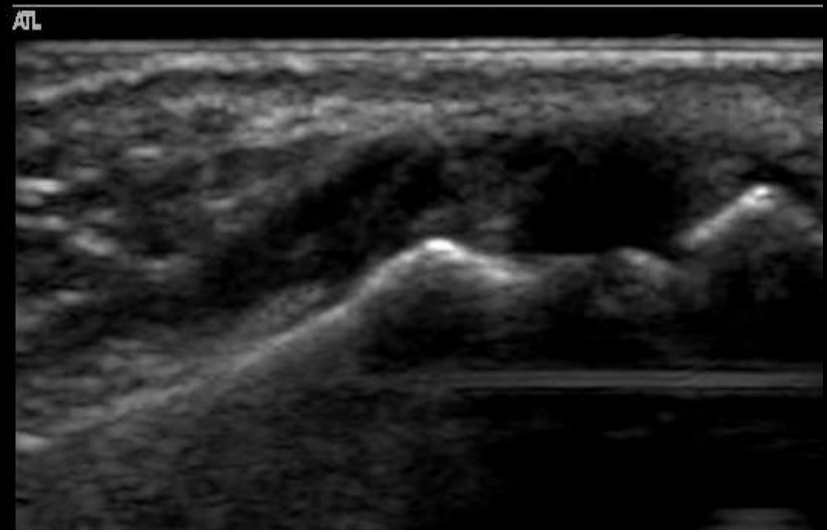
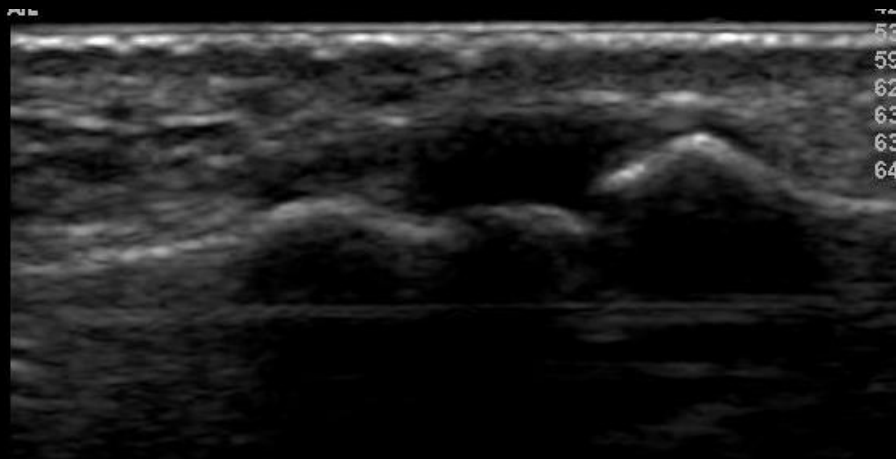
PIP – Dorsal – Synovial Hypertrophy – Grade 2



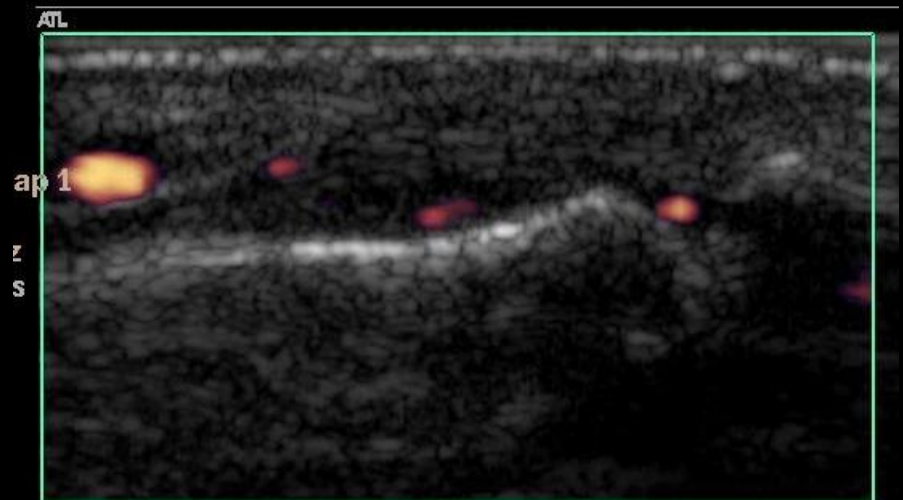
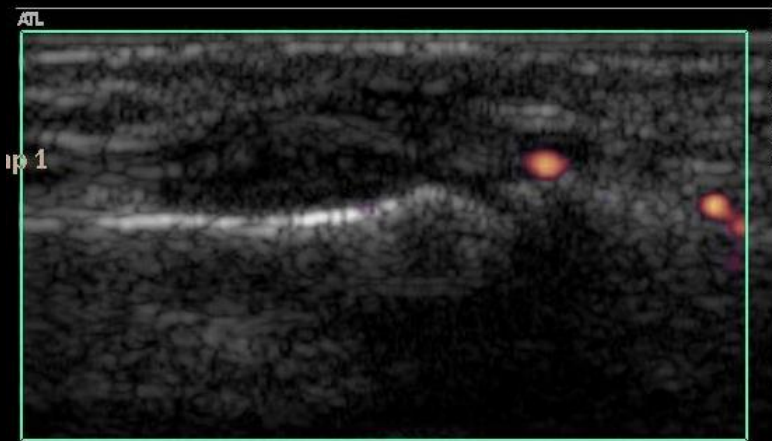
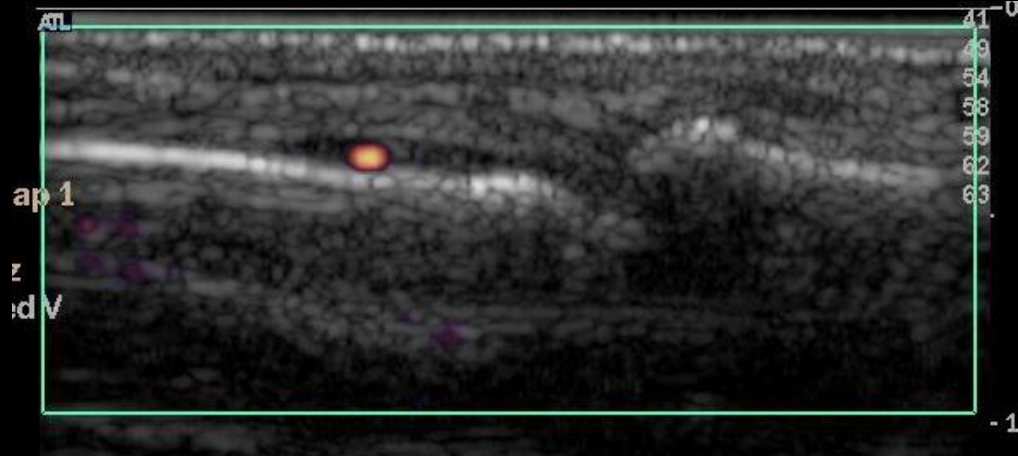
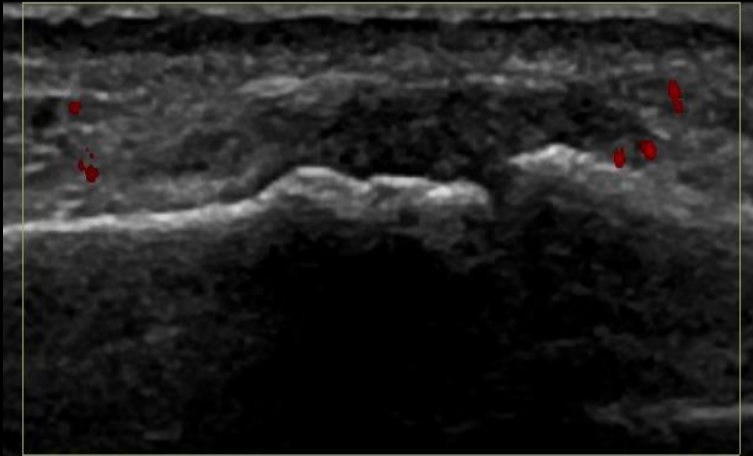
PIP – Dorsal – Synovial Hypertrophy – Grade 3



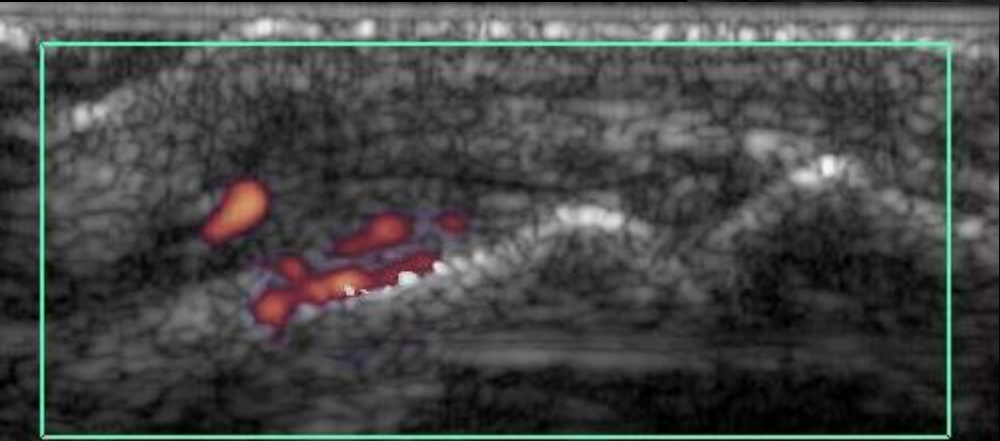
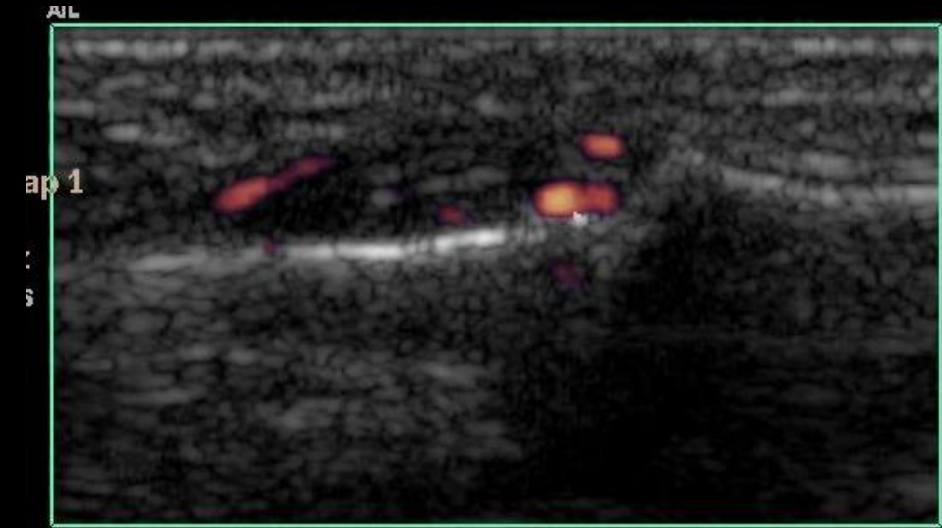
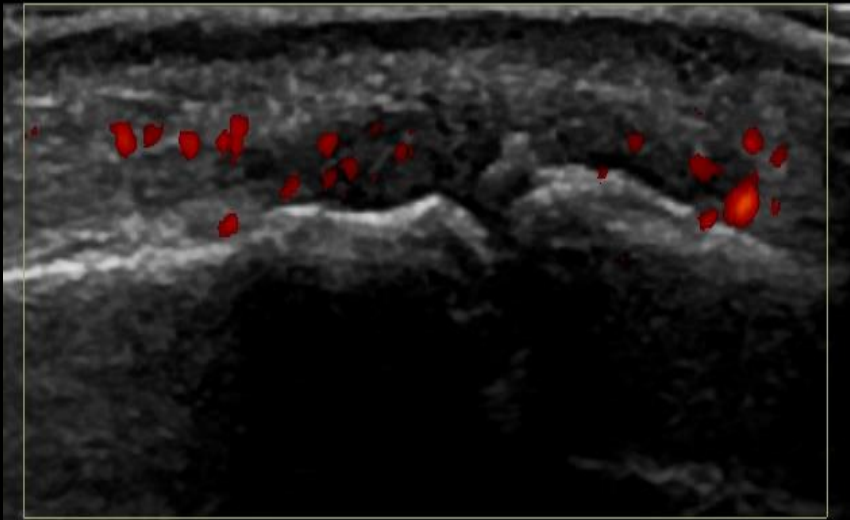
PIP – Dorsal – Effusion – Grade 3



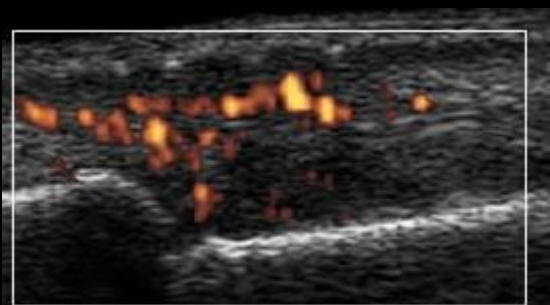
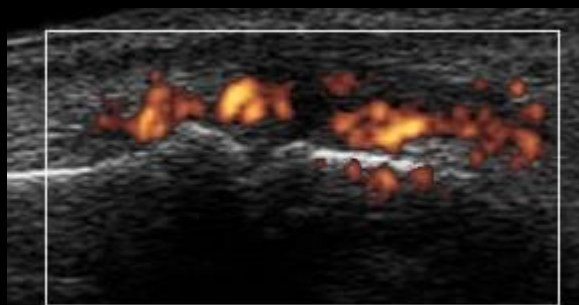
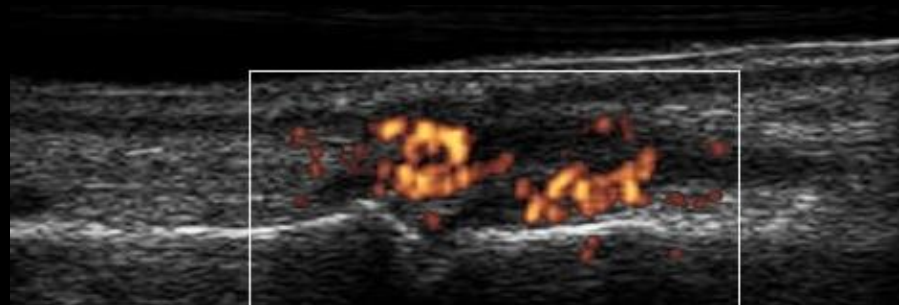
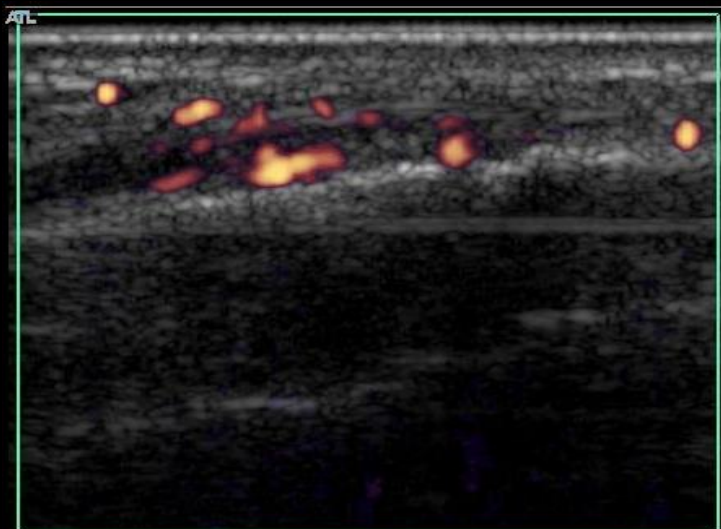
PIP – Dorsal – PD – Grade 1



PIP – Dorsal – PD – Grade 2



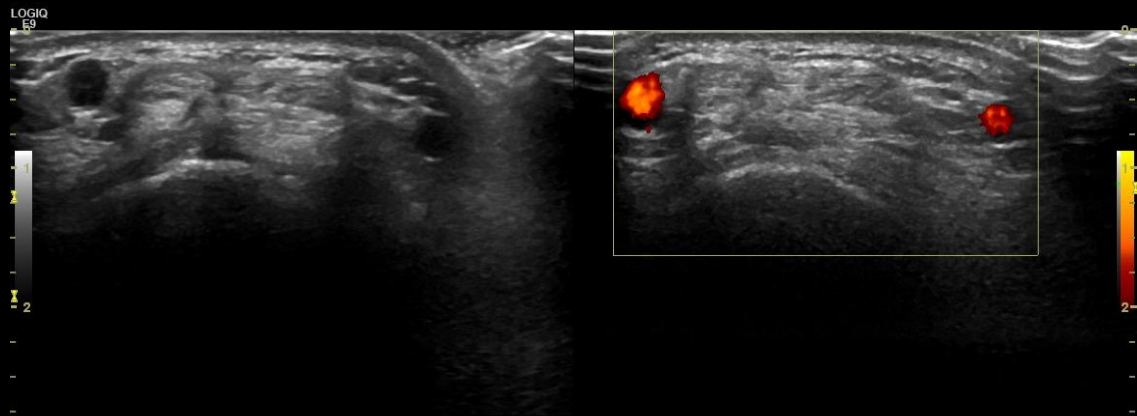
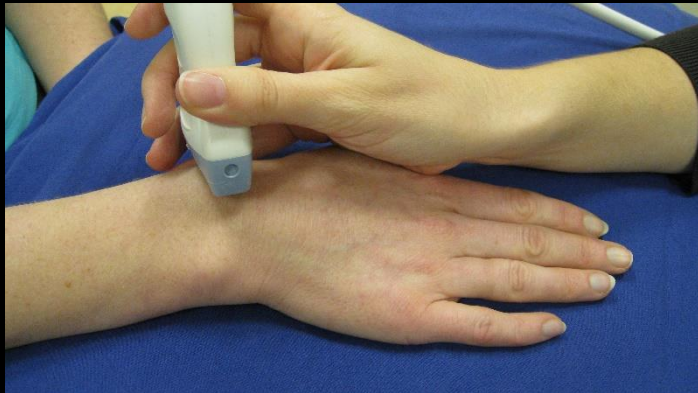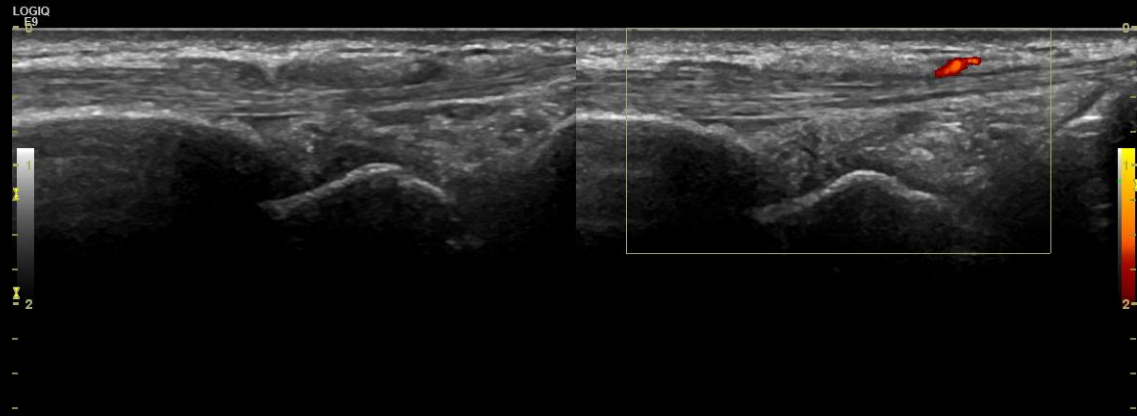
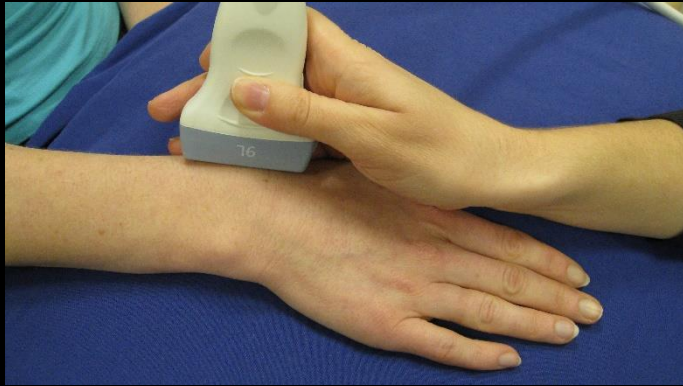
PIP – Dorsal – PD – Grade 3



Wrist

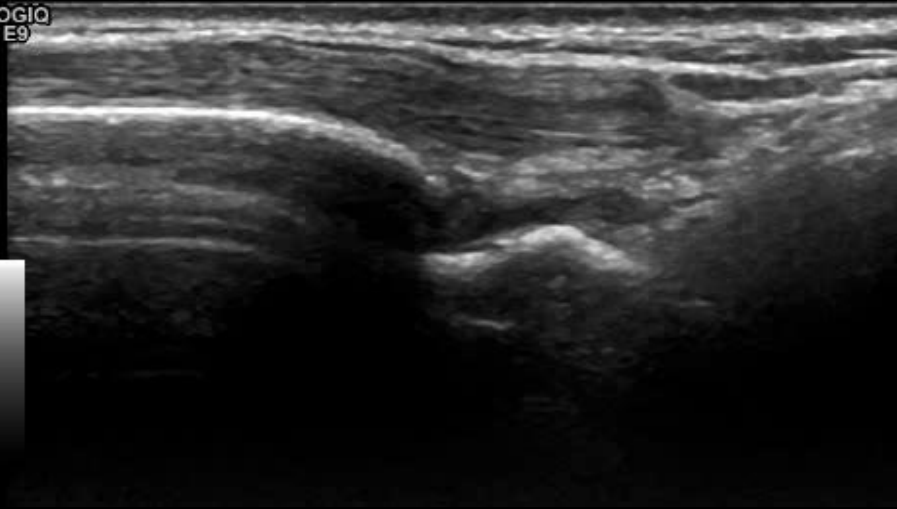
- **Radio-scaphoid joint**
- **Inter-carpal joint**
- **Ulnar-carpal joint**
 - **Lateral**
 - **Dorsal**

Radio-carpal Joint - Normal

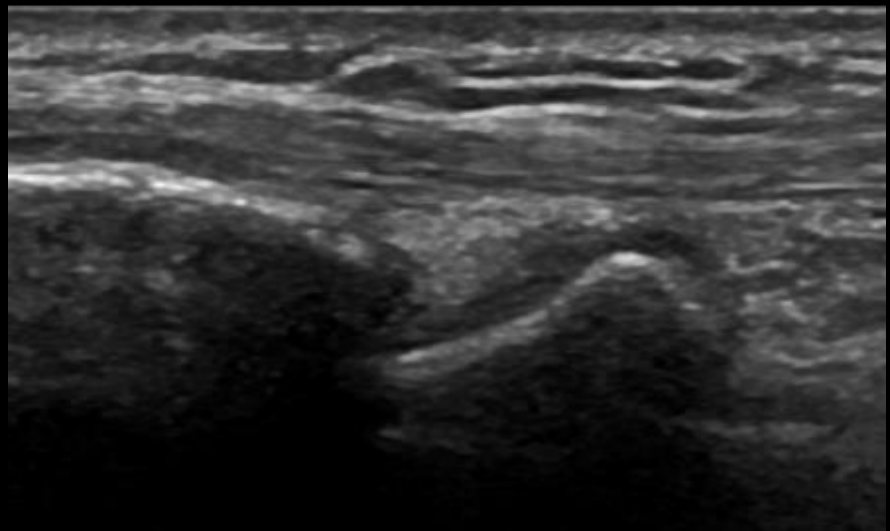
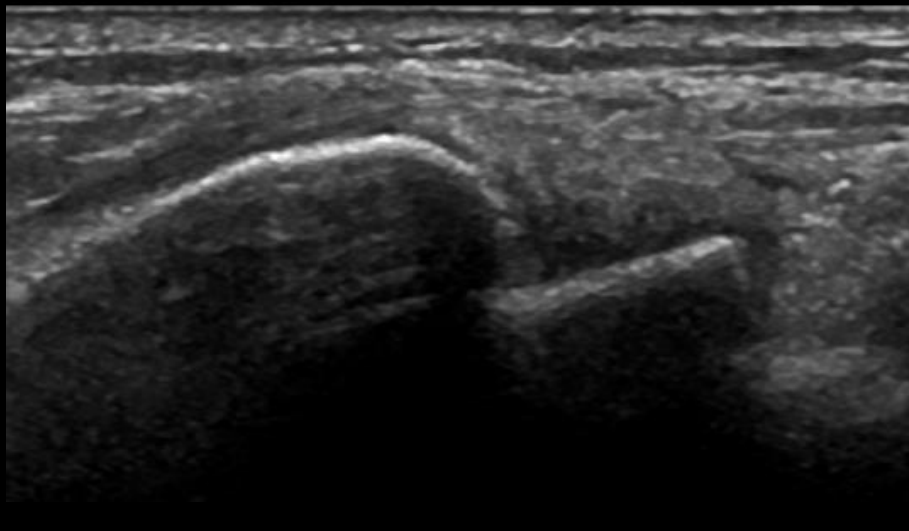
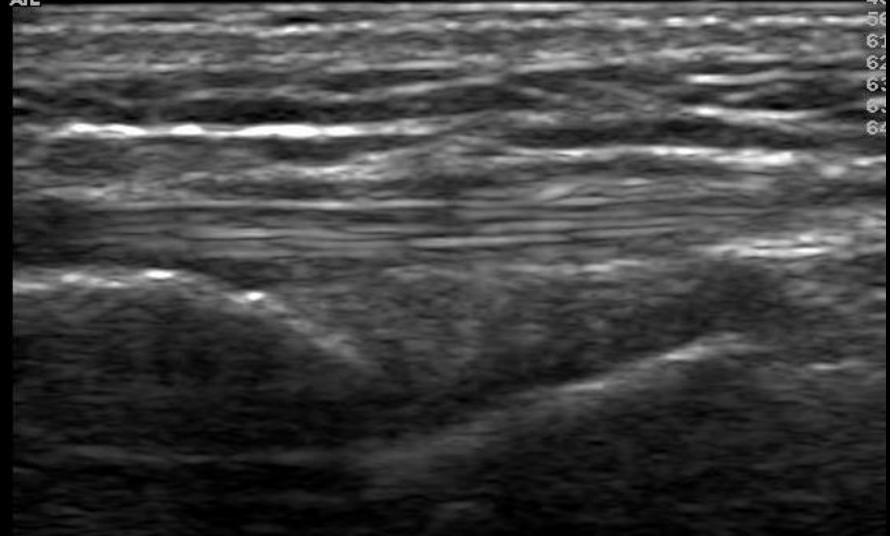


Radio-carpal joint – Dorsal – Synovial Hypertrophy – Grade 1

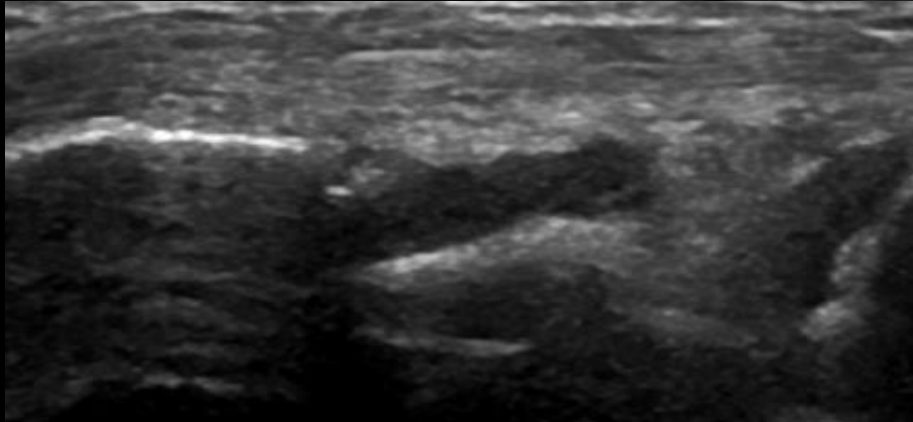
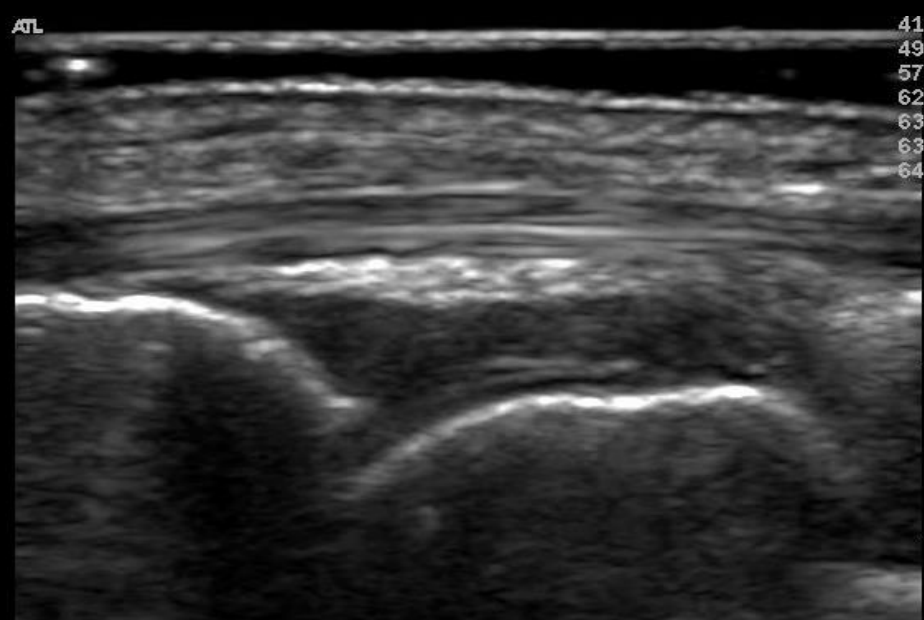
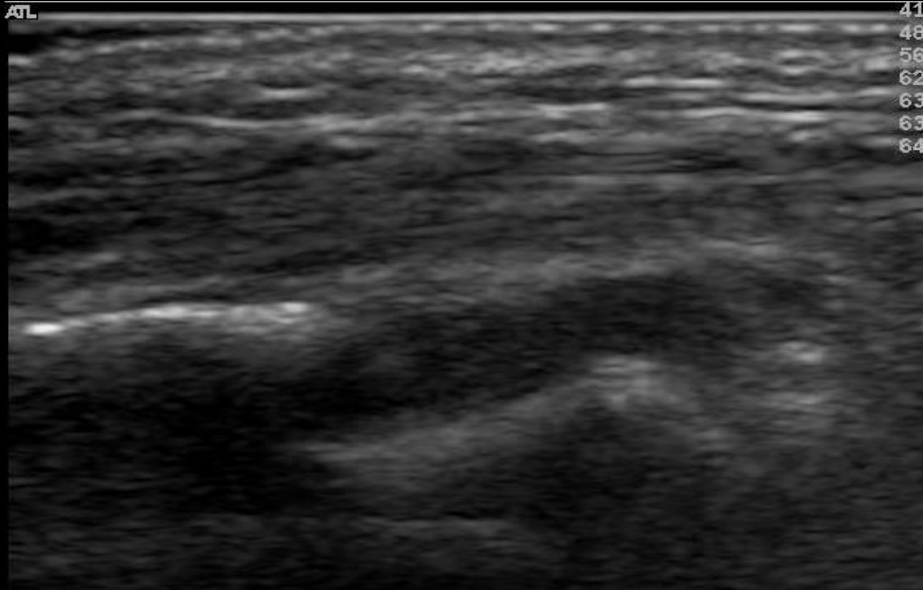
LOGIQ
E9



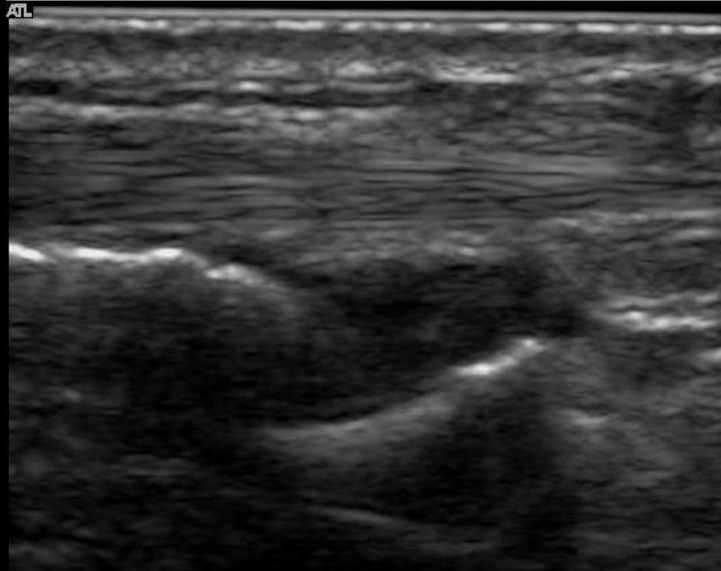
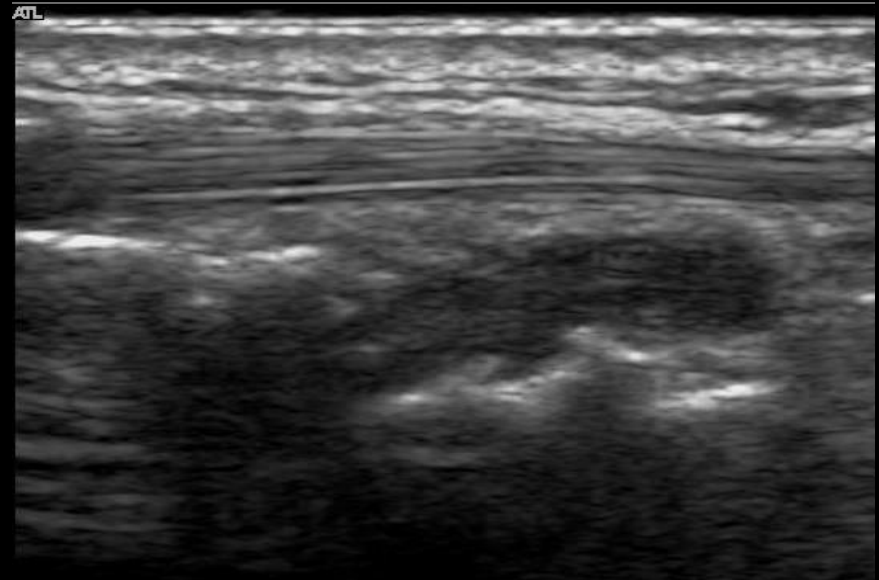
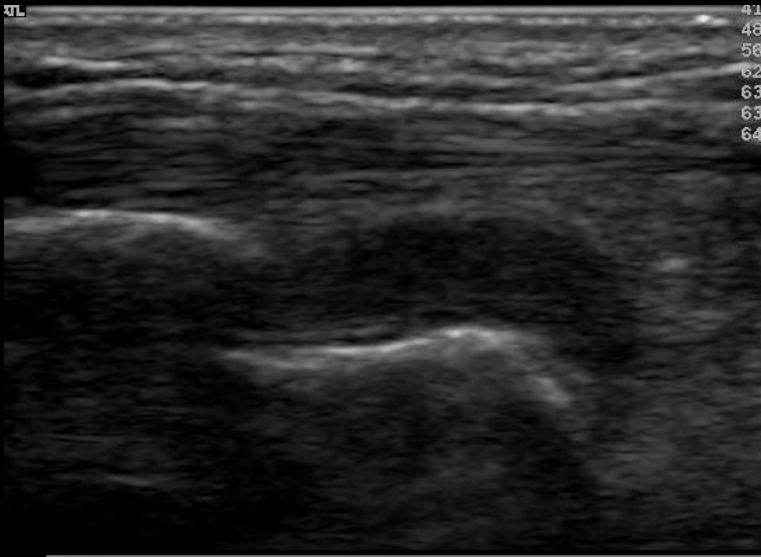
ATL



Radio-carpal joint – Dorsal Synovial Hypertrophy - Grade 2



Radio-carpal joint – Dorsal Synovial Hypertrophy - Grade 3

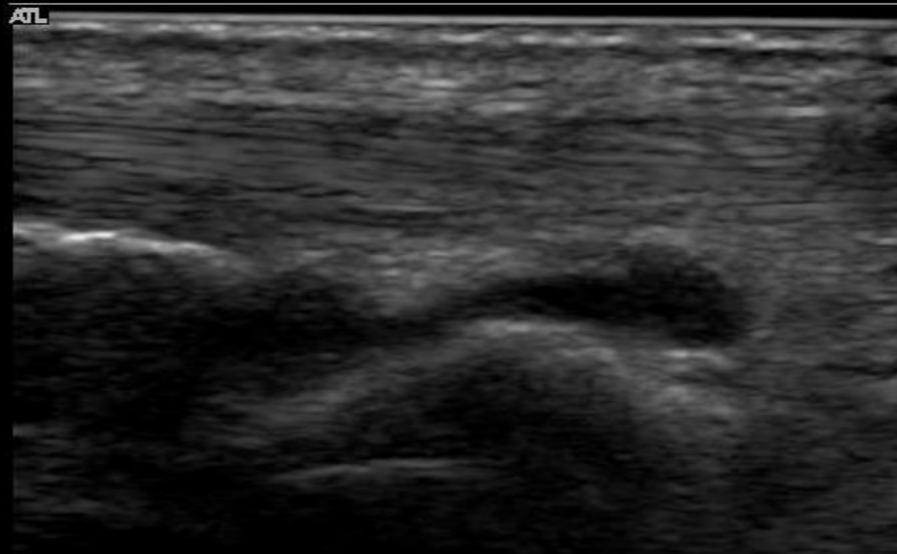


LOGIQ
E9

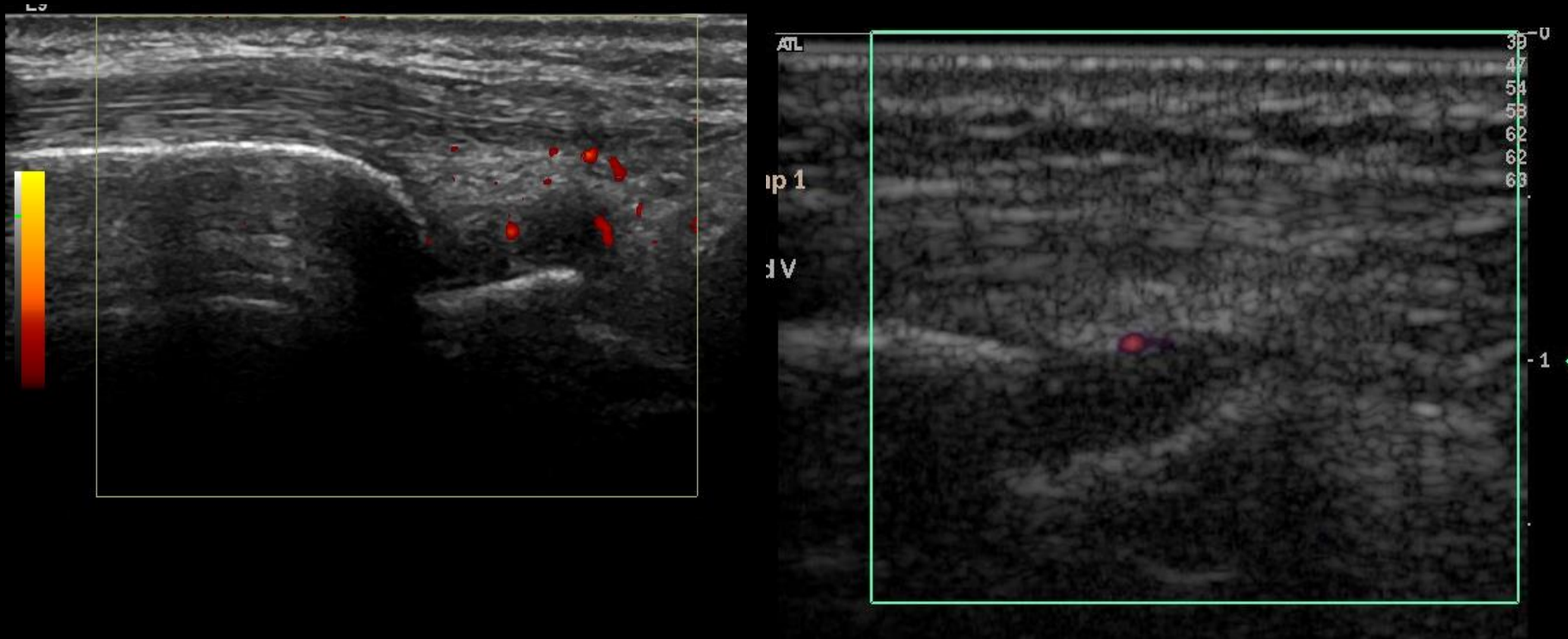


This B-mode ultrasound image shows a longitudinal view of the radio-carpal joint. The joint space is filled with a large, echogenic, and irregular mass of synovial hypertrophy, significantly narrowing the joint space. The underlying bony structures are partially obscured by the thickened synovium.

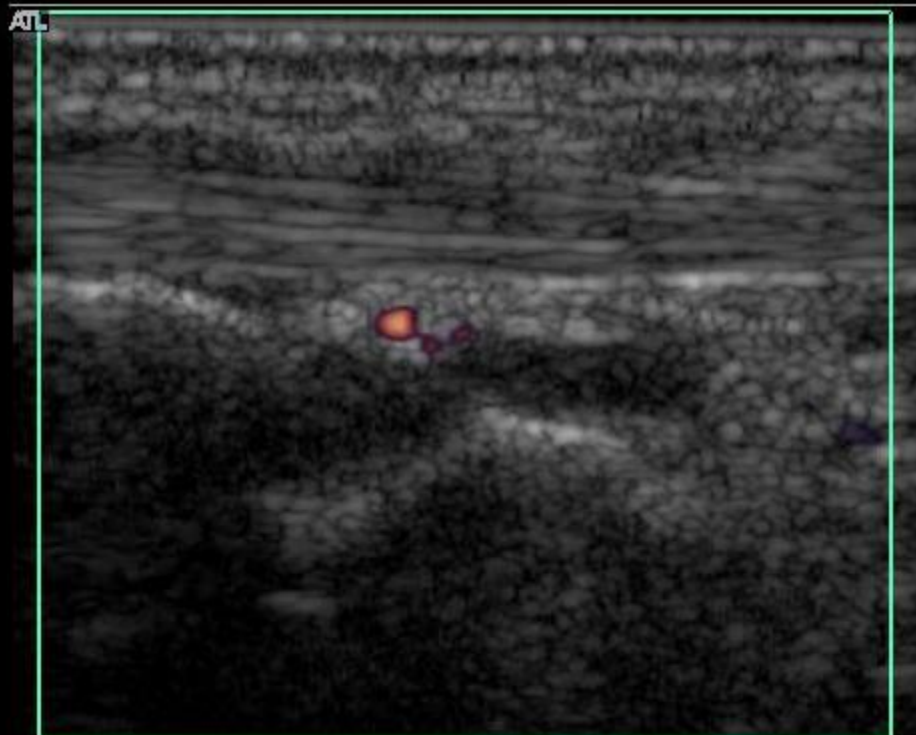
Radio-carpal joint – Dorsal – Effusion – Grade 1



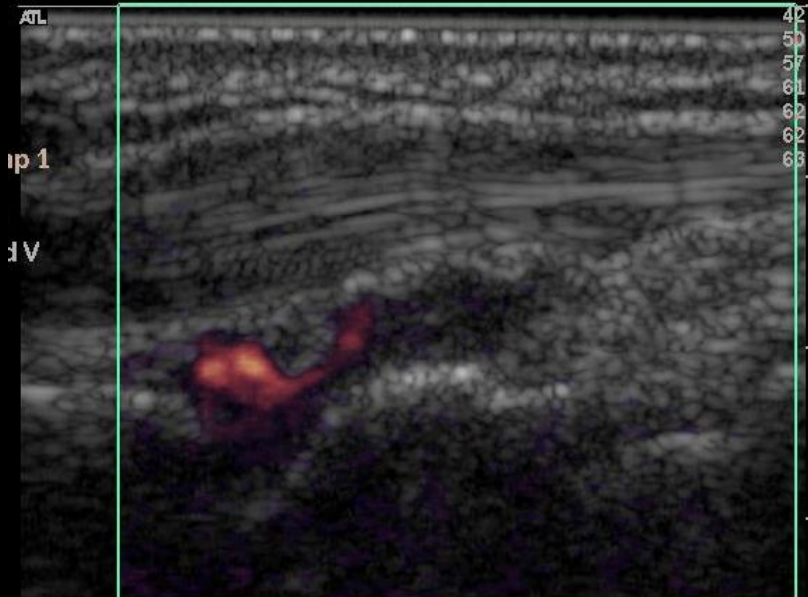
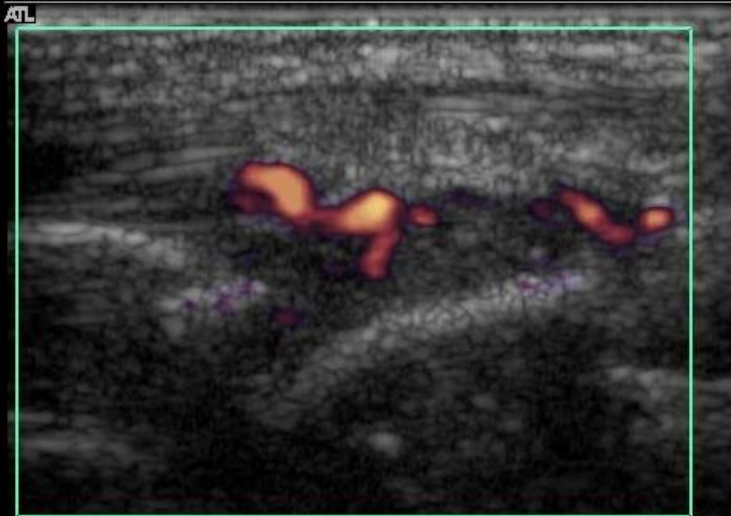
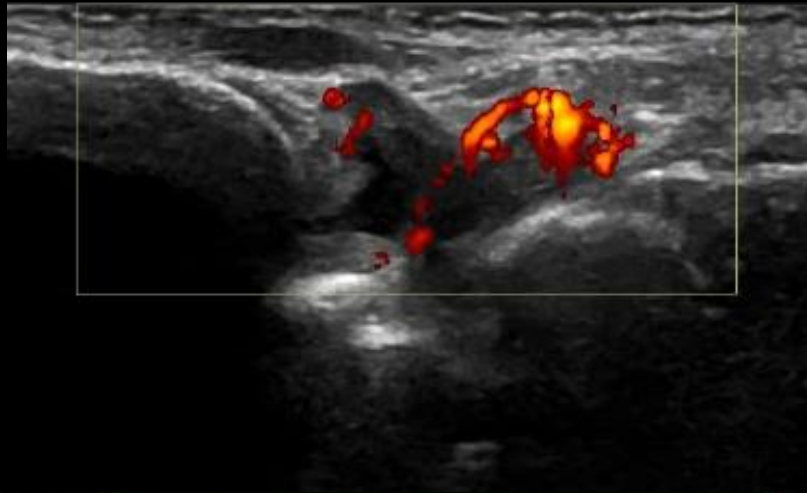
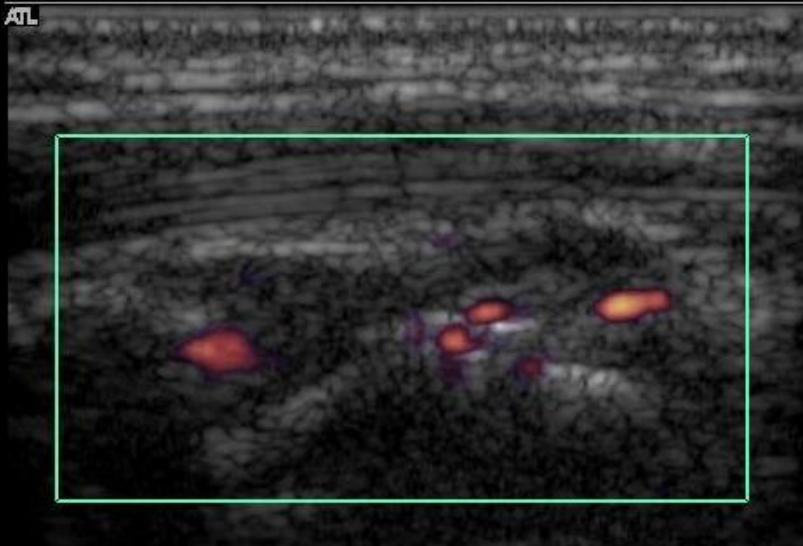
Radio-carpal joint – Dorsal – PD – Grade 1



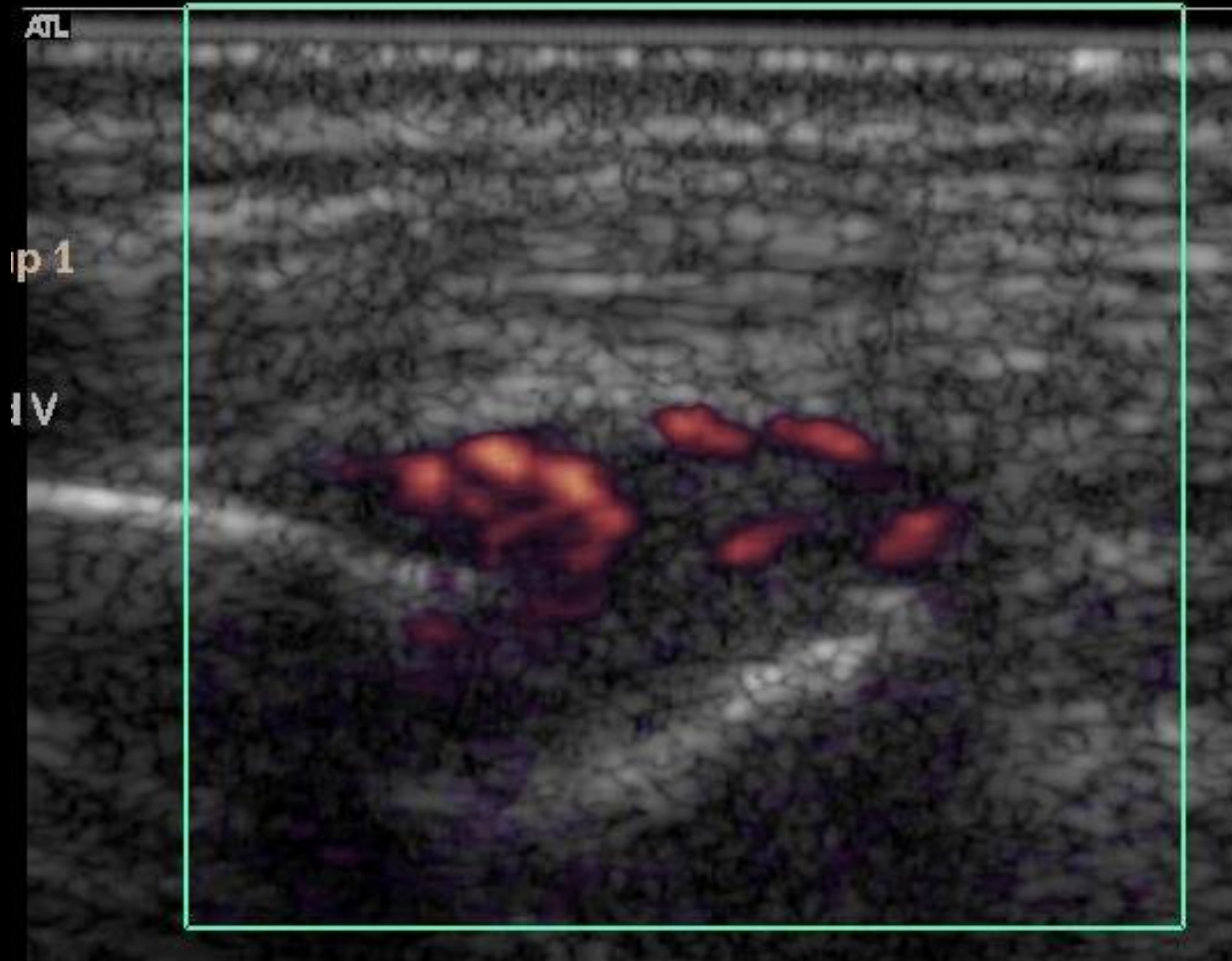
Caveat



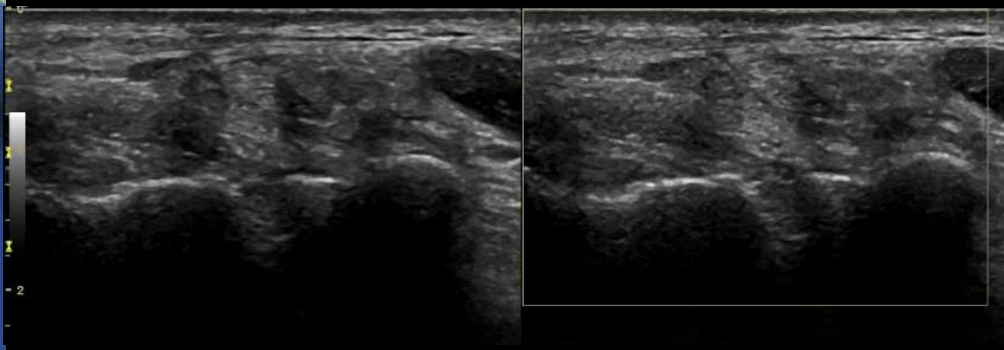
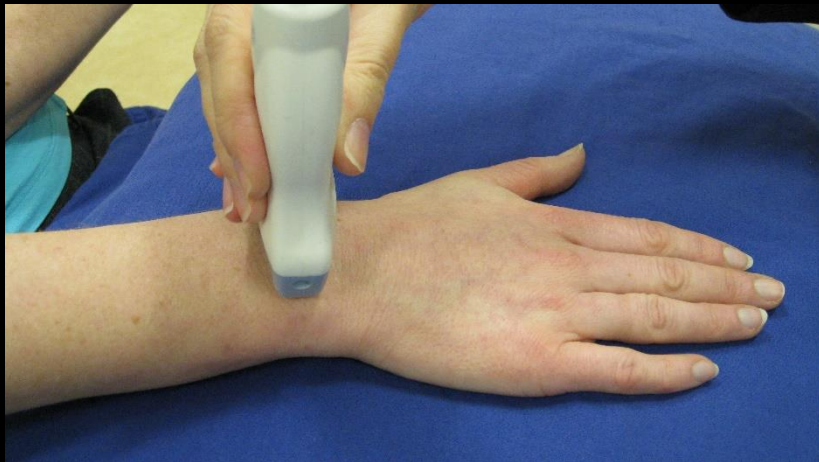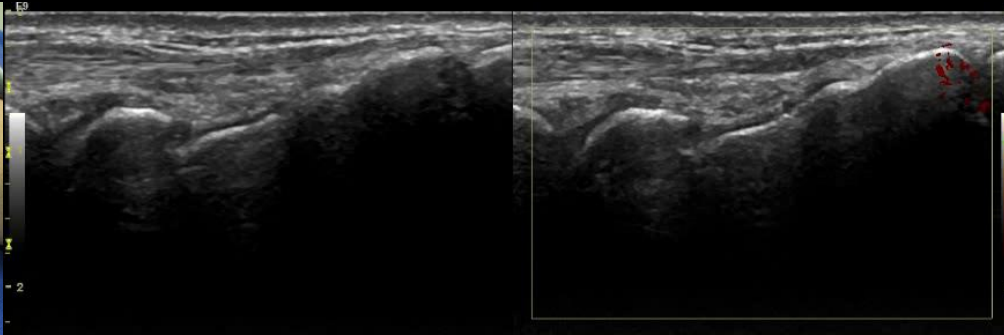
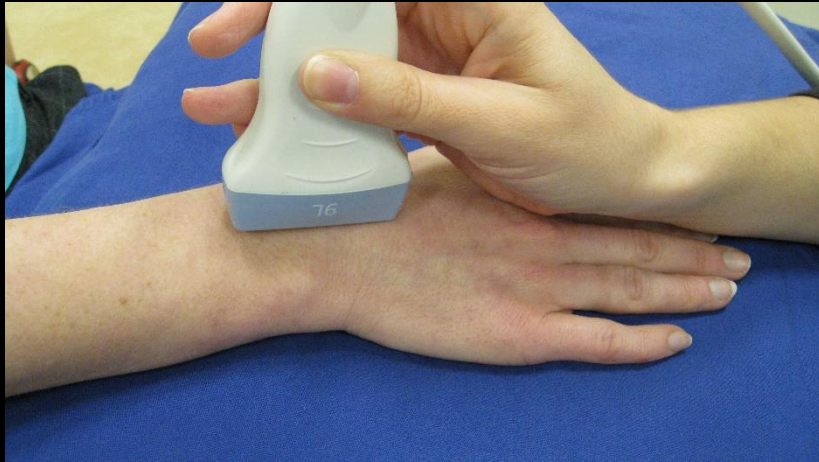Radio-carpal joint – Dorsal – PD – Grade 2



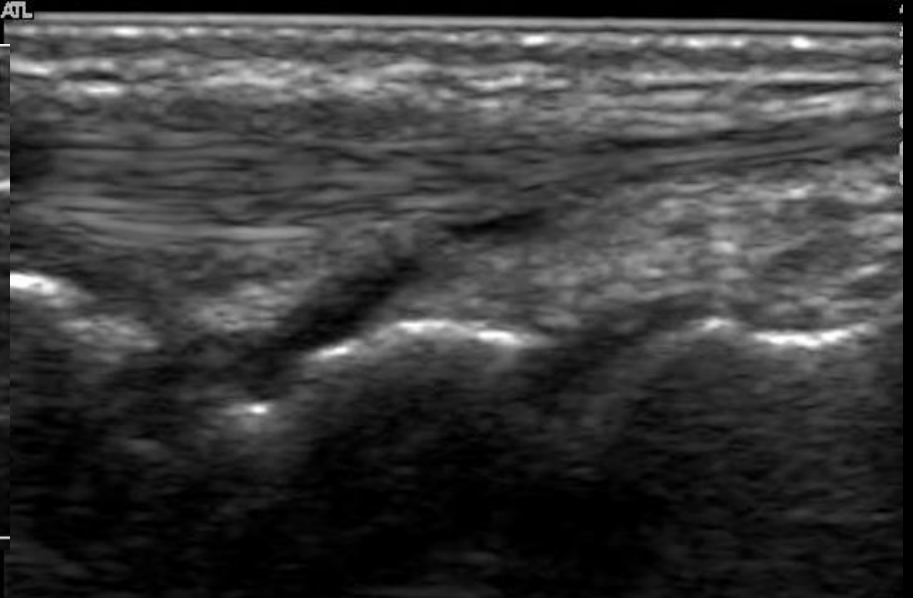
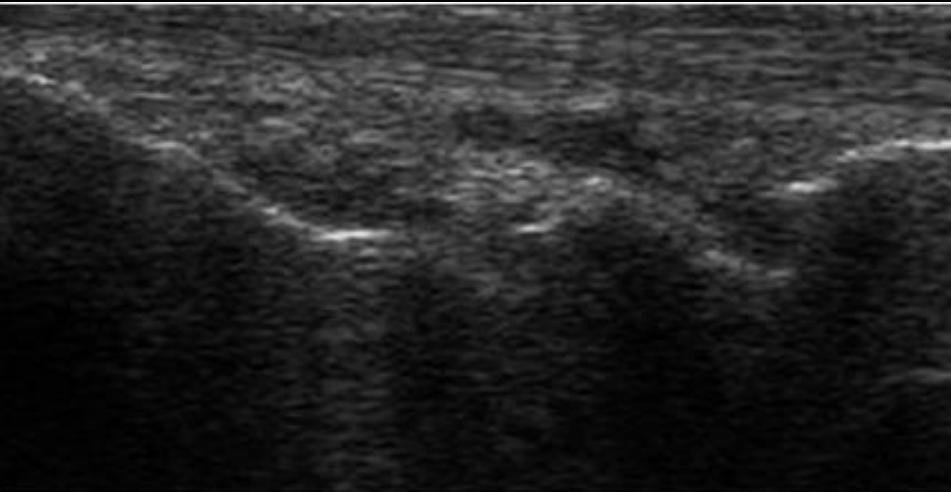
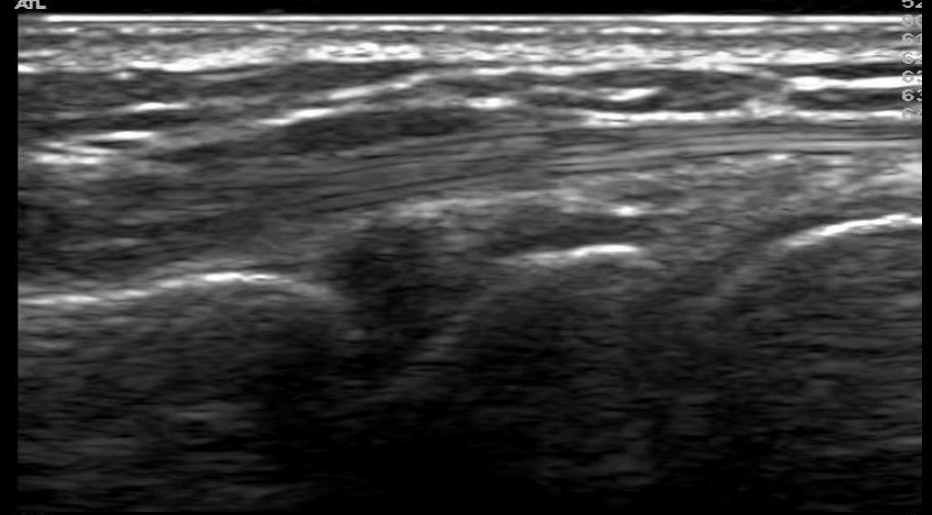
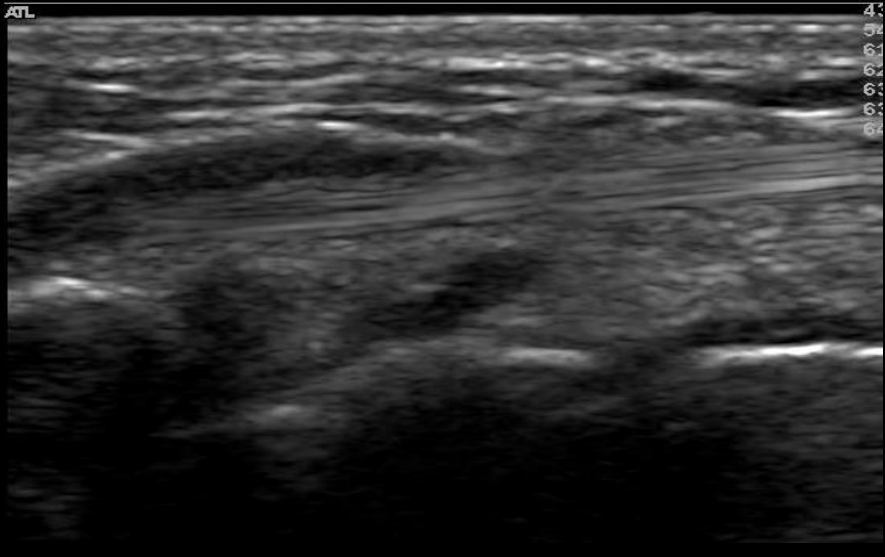
Radio-carpal joint – Dorsal – PD – Grade 3



Inter-carpal Joint - Normal

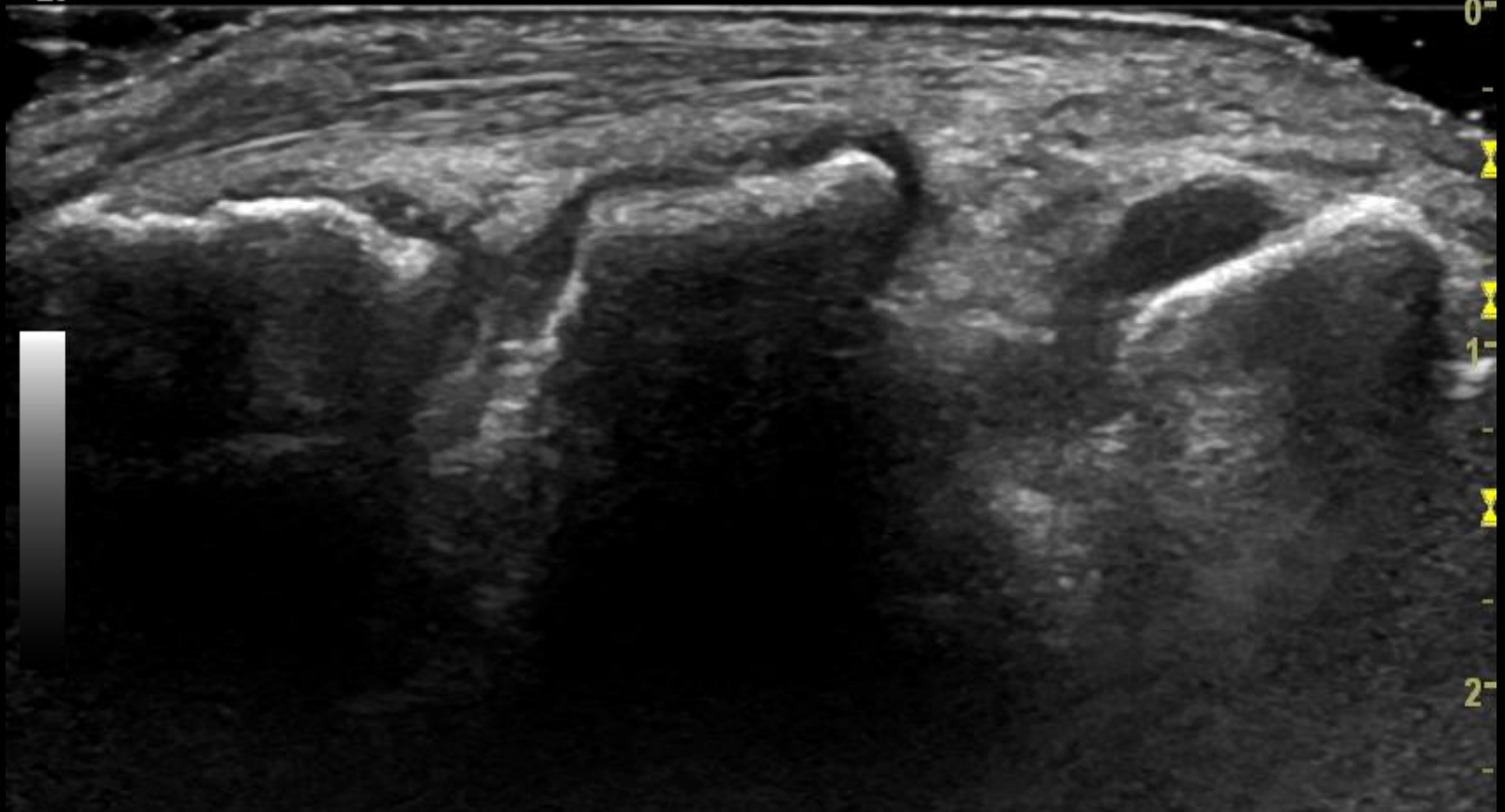


Inter-carpal – Dorsal – Synovial Hypertrophy – Grade 1

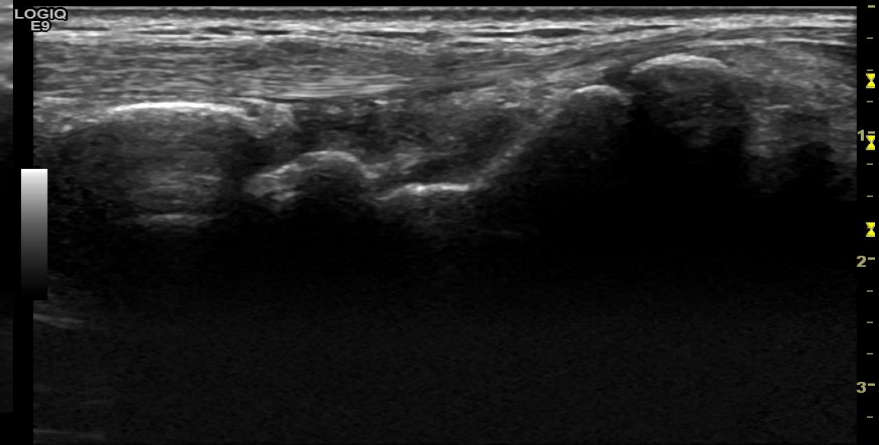
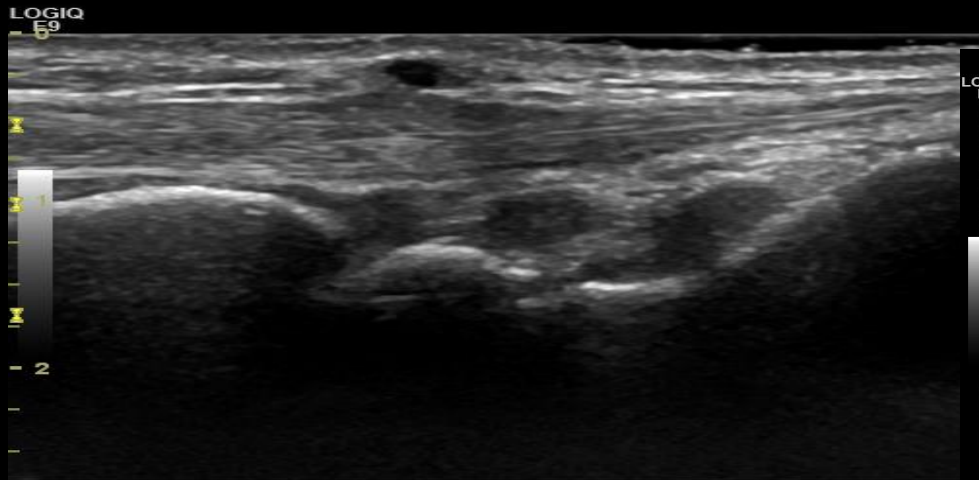
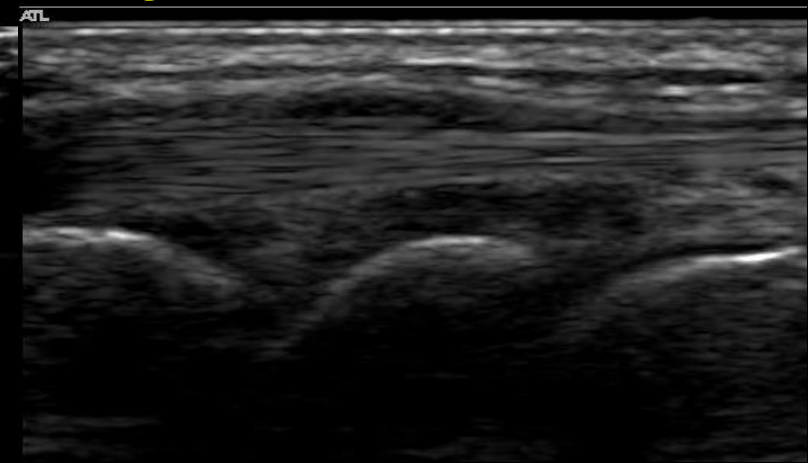
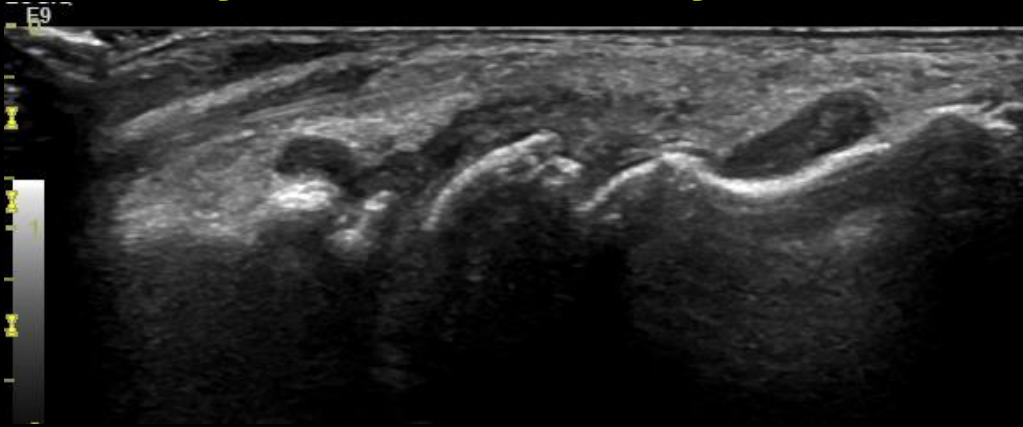


Caveat

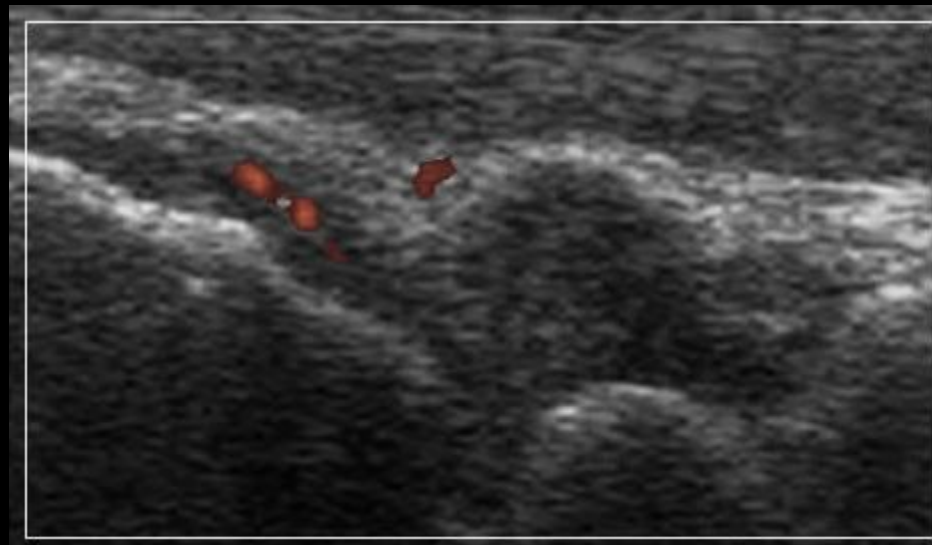
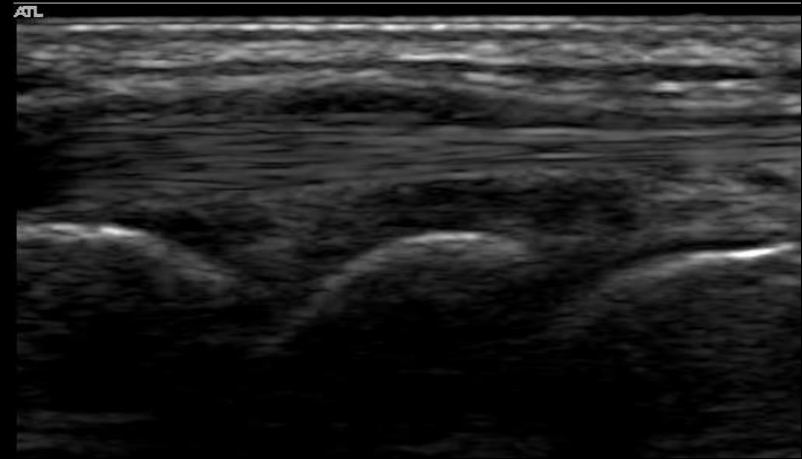
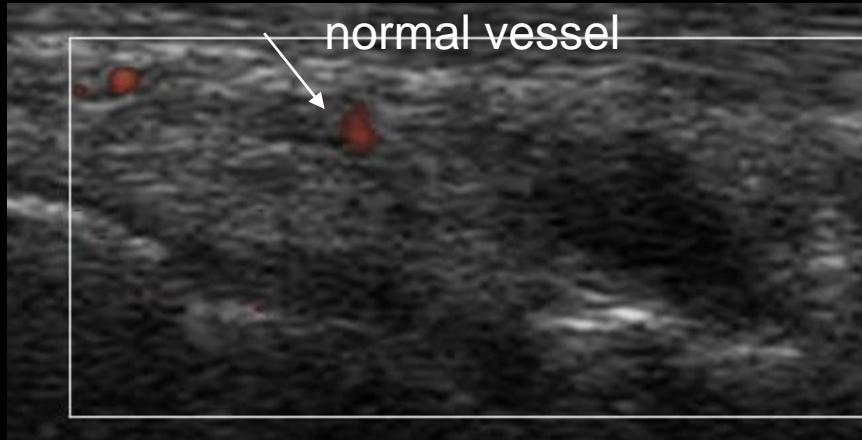
LOGIQ
E9



Inter-carpal – Dorsal – Synovial Hypertrophy – Grade 2

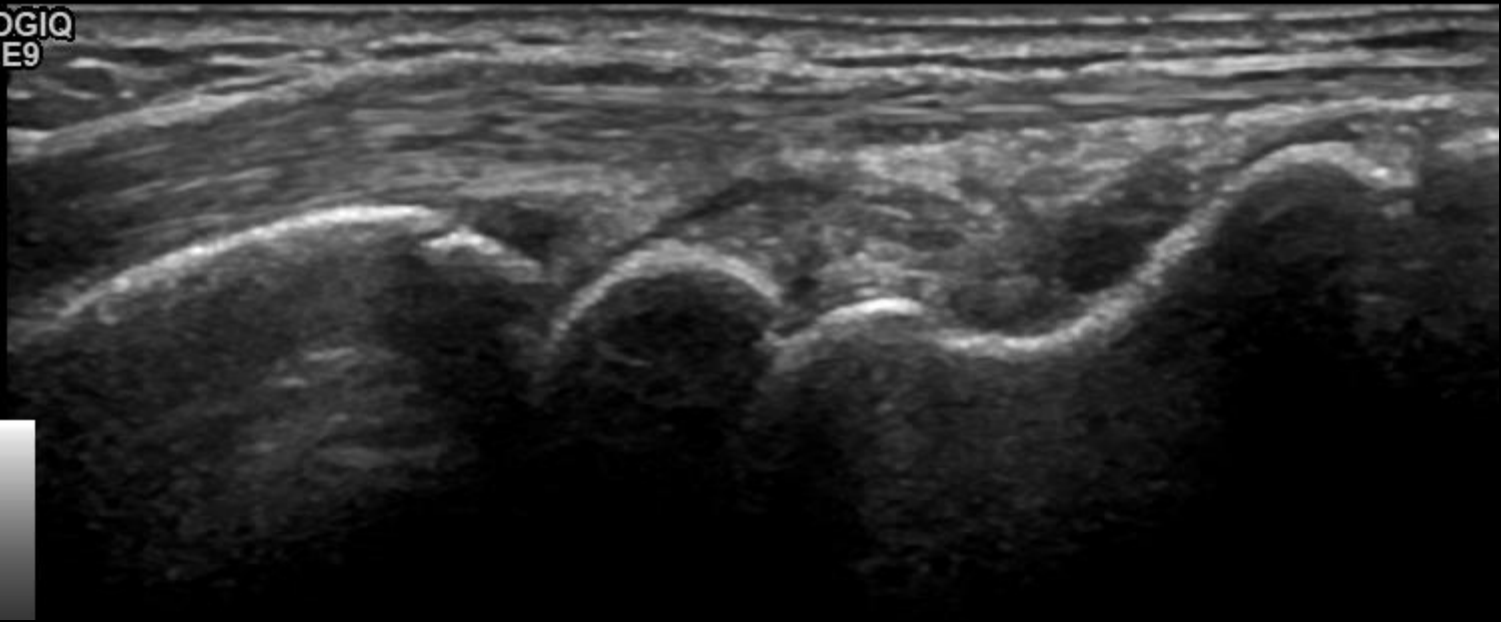


Inter-carpal – Dorsal – Effusion – Grade 2

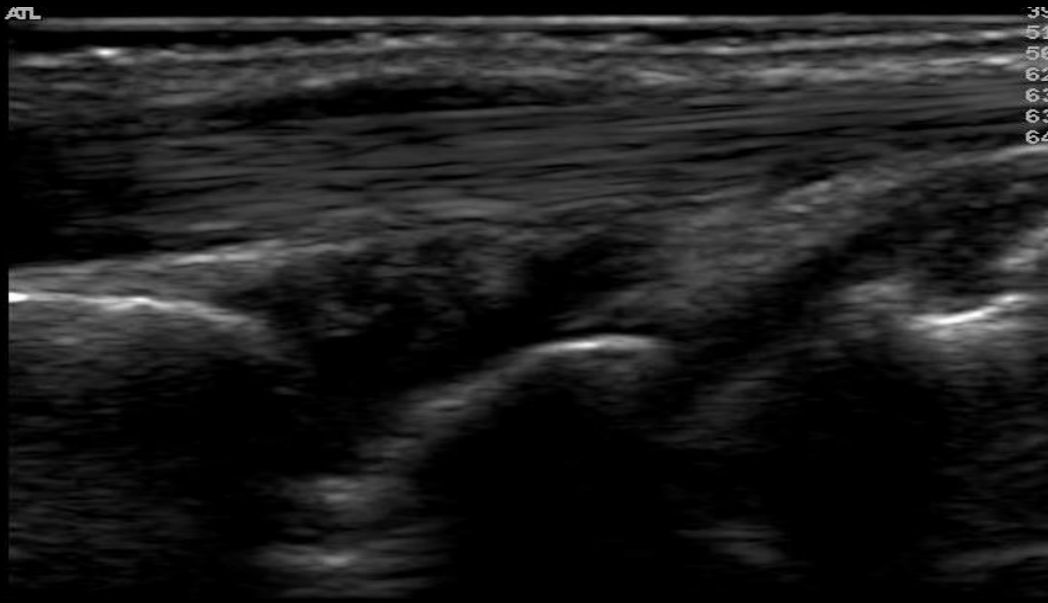


Caveat

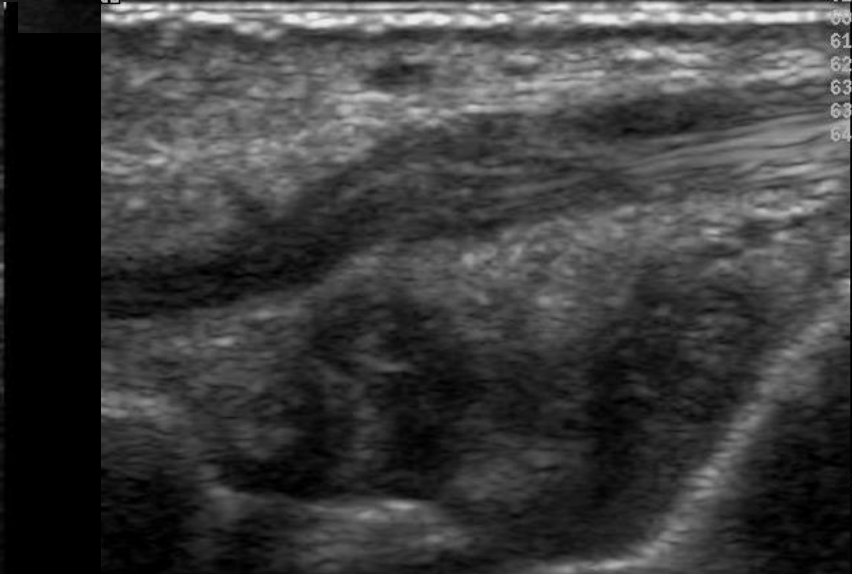
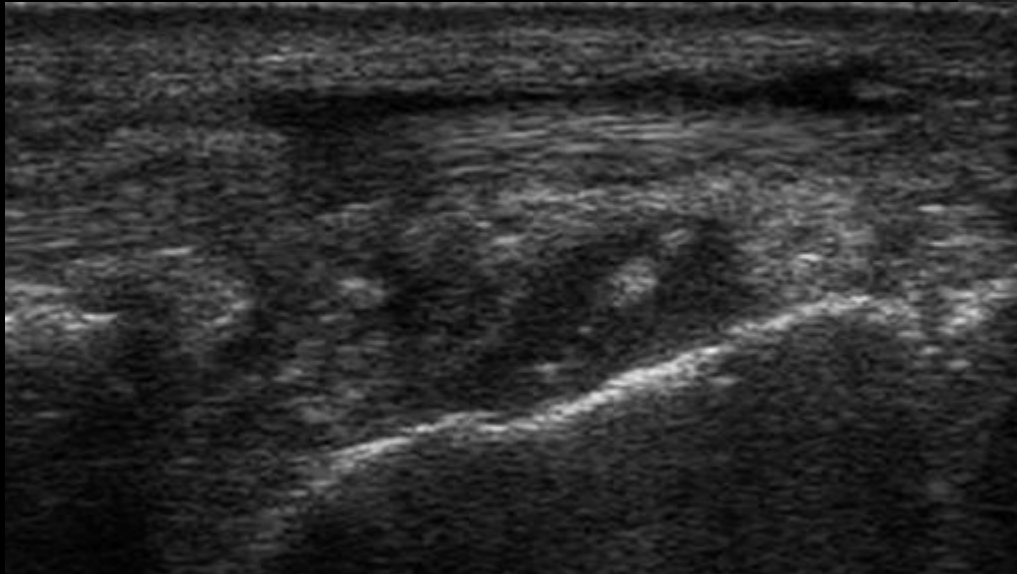
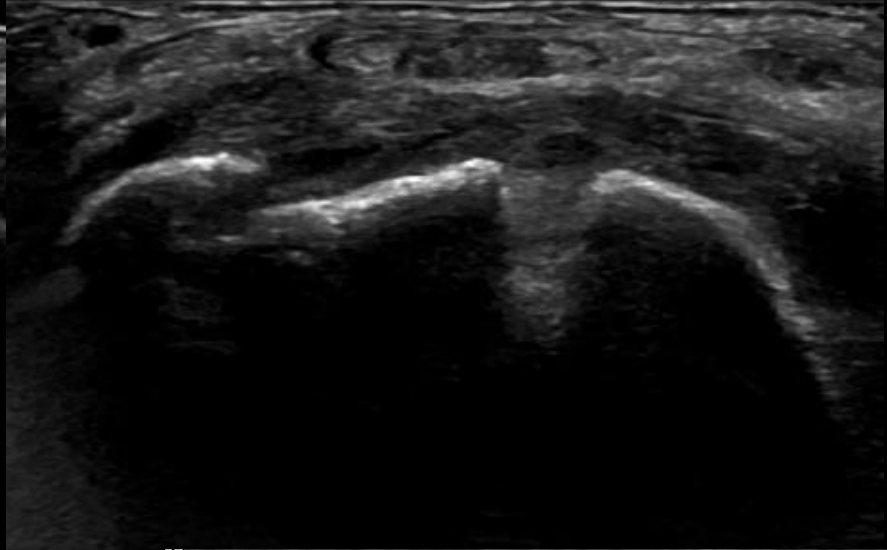
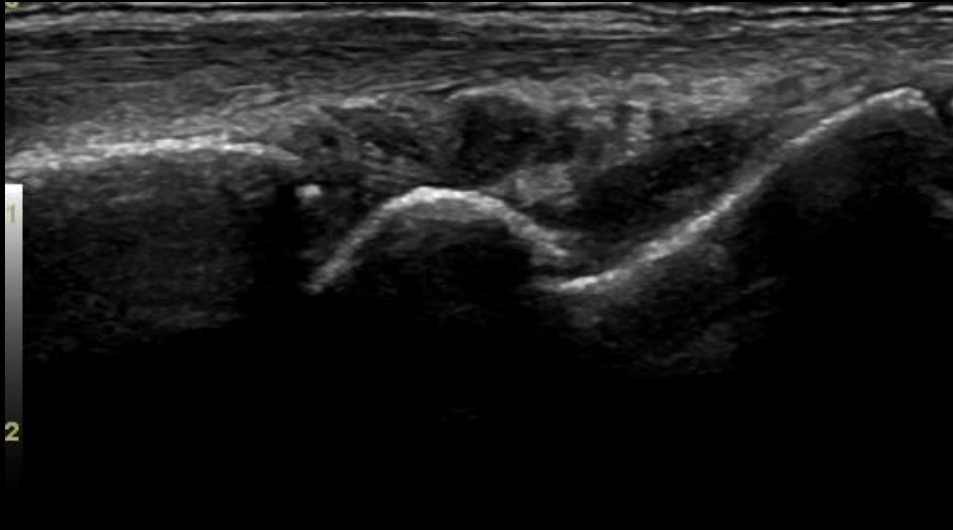
LOGIQ
E9



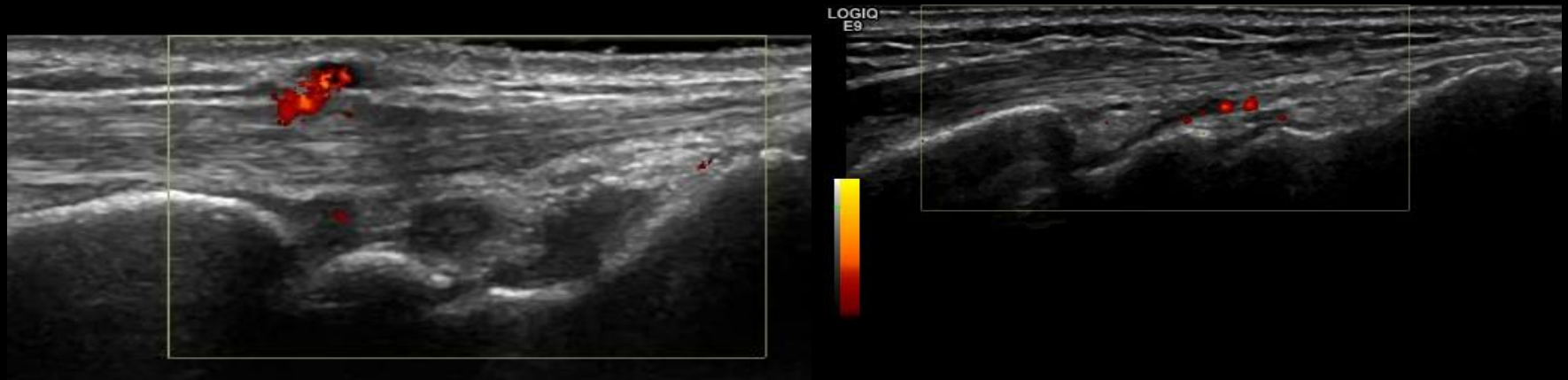Inter-carpal – Dorsal – Effusion – Grade 2



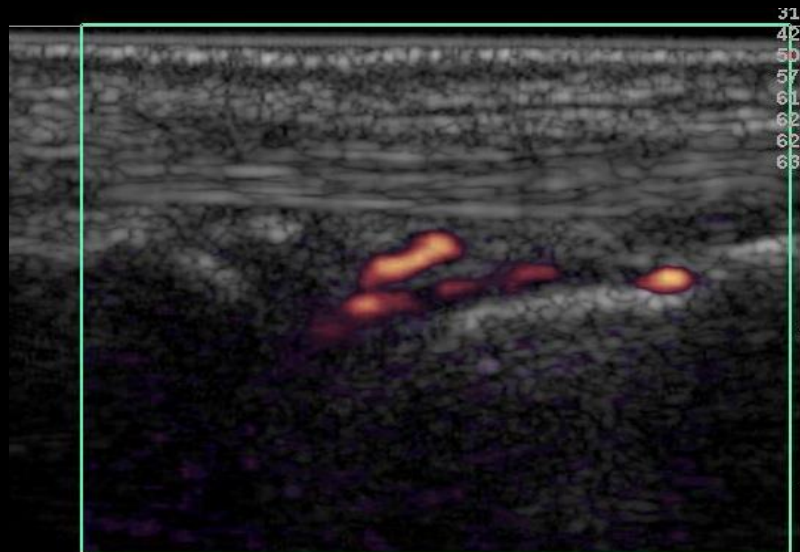
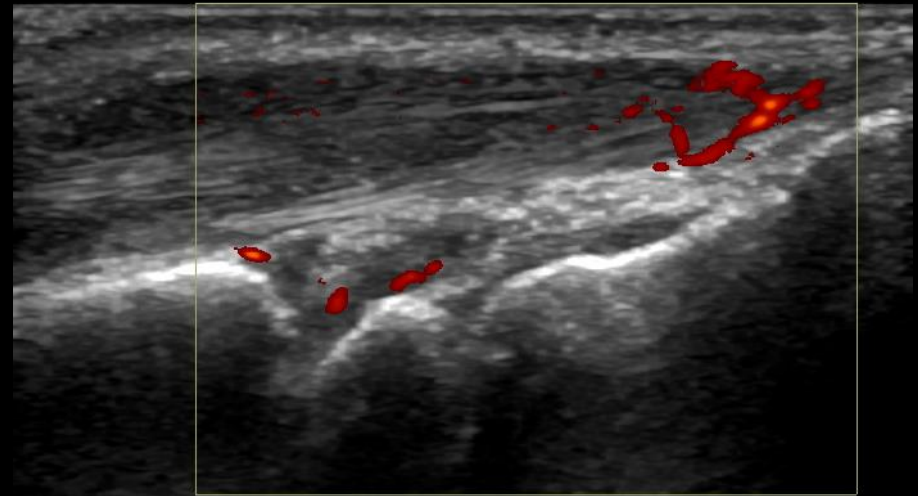
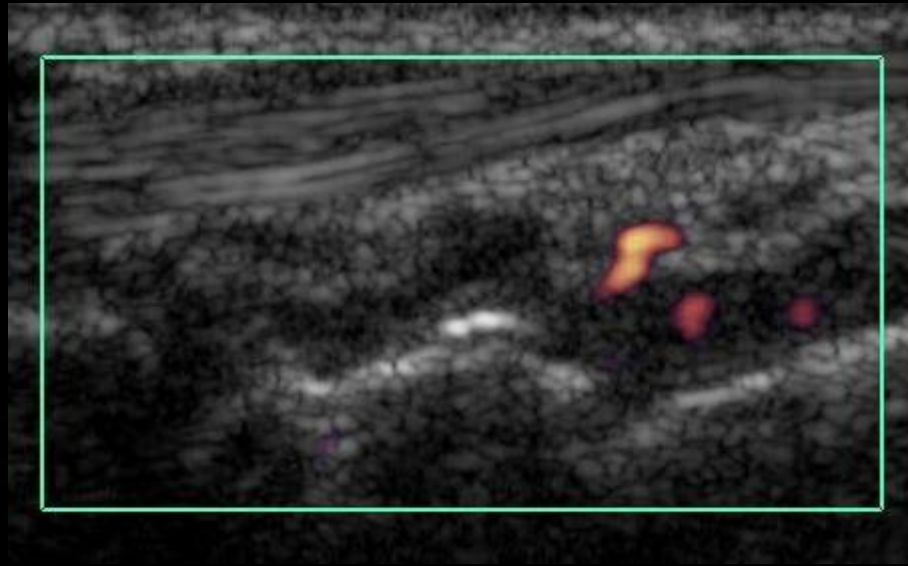
Inter-carpal – Dorsal – Synovial Hypertrophy – Grade 3



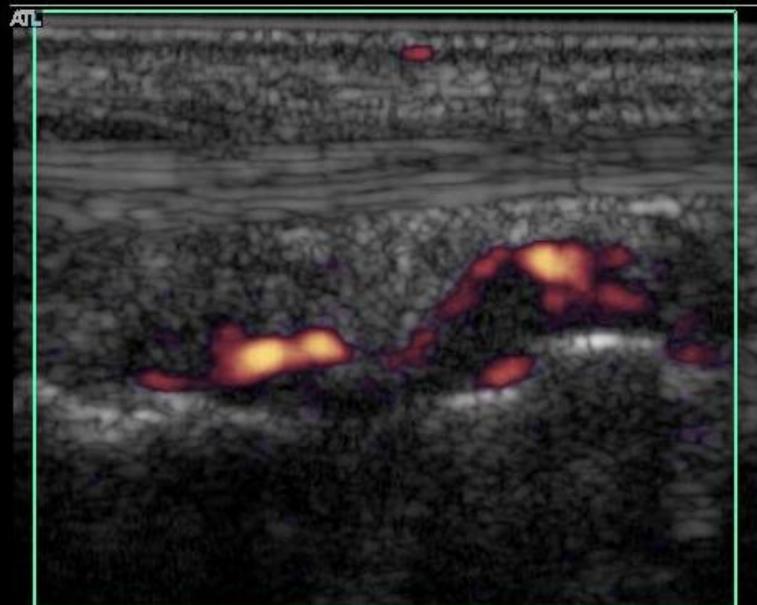
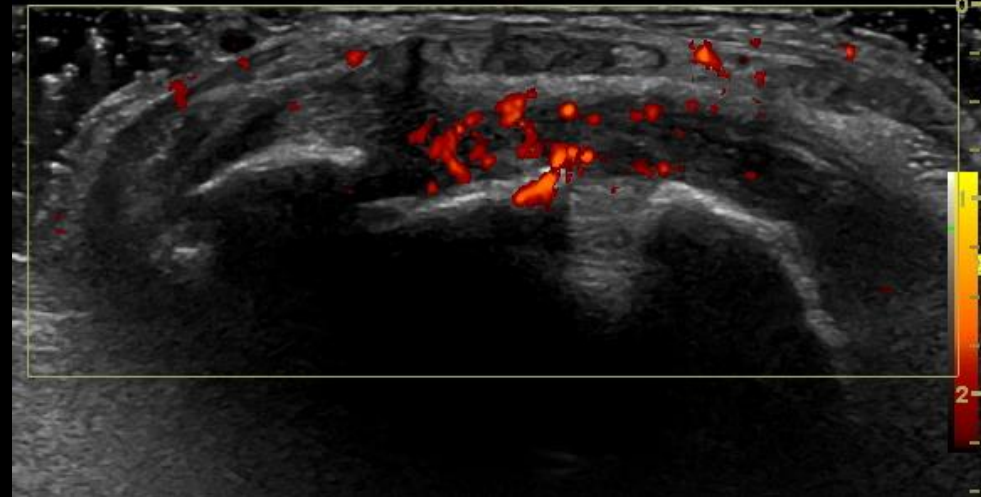
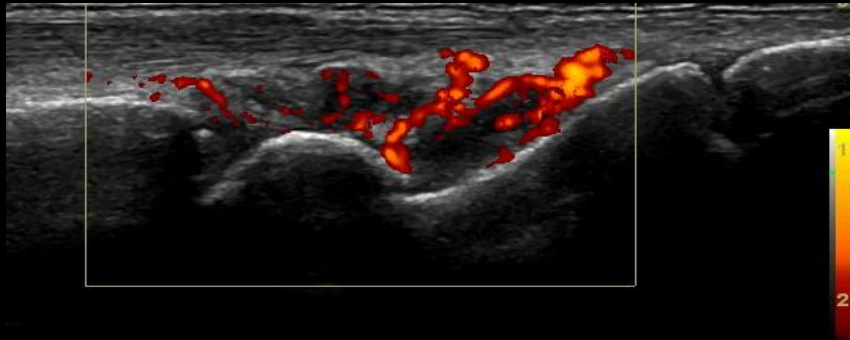
Inter-carpal – dorsal- PD 1



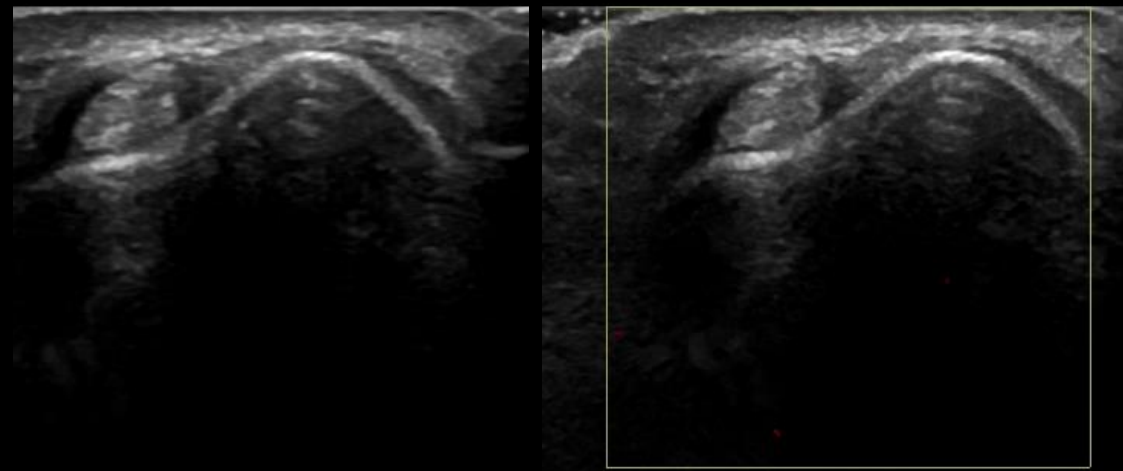
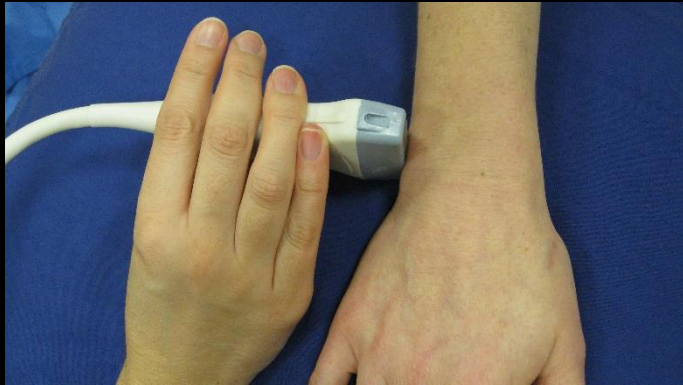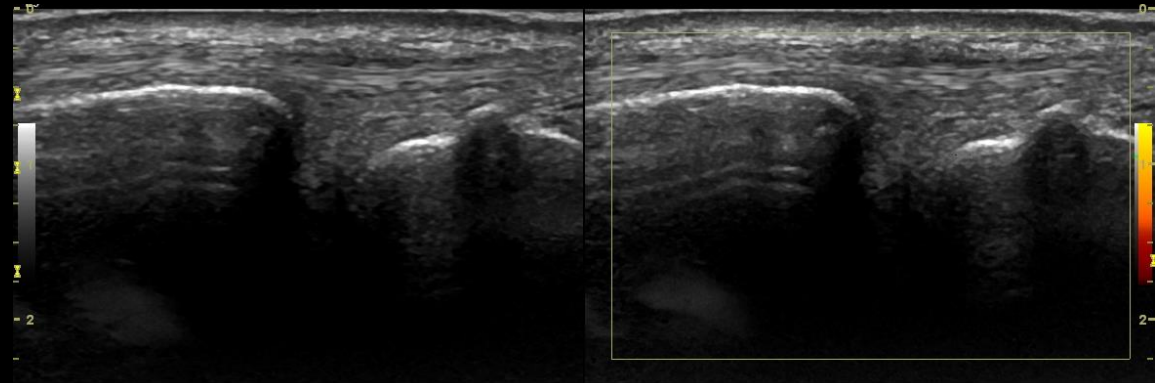
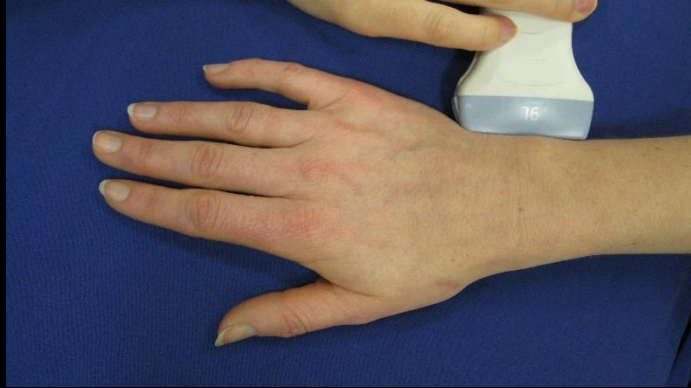Inter-carpal – dorsal- PD 2



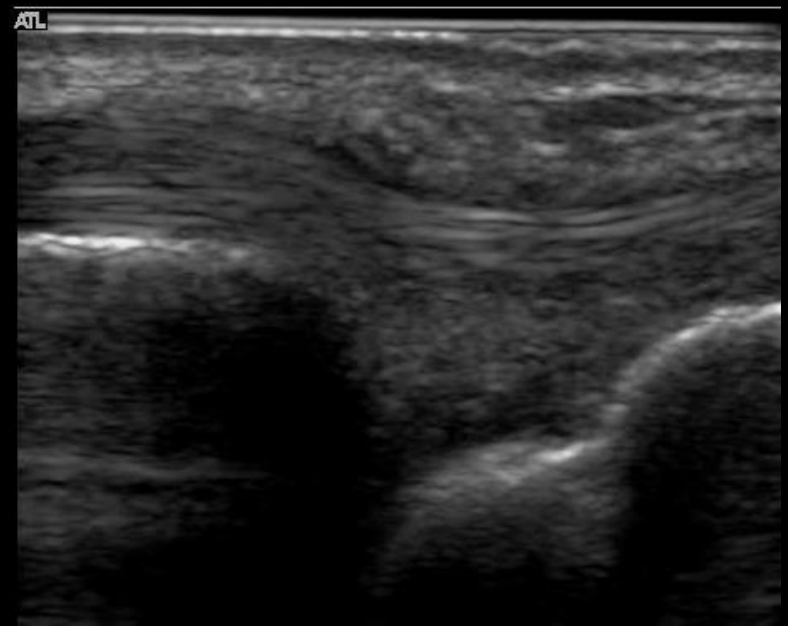
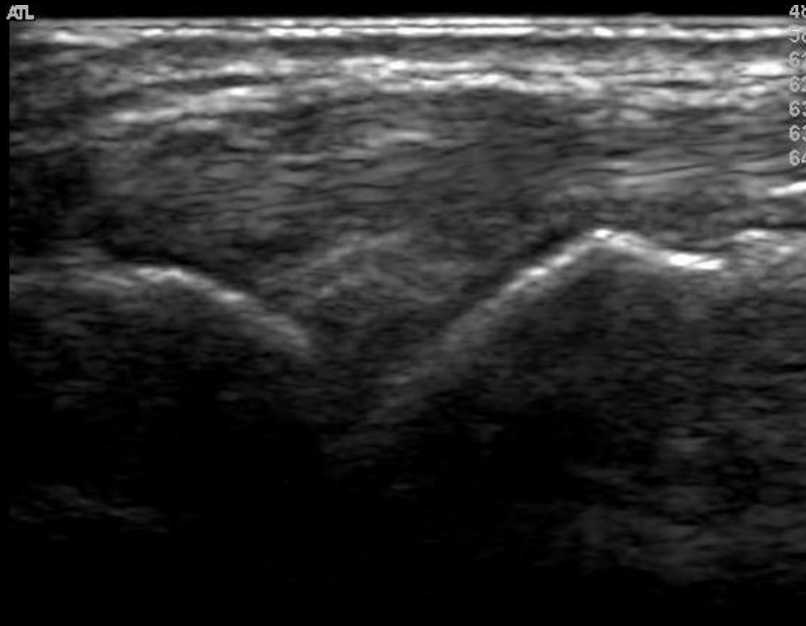
Inter-carpal – Dorsal- PD 3



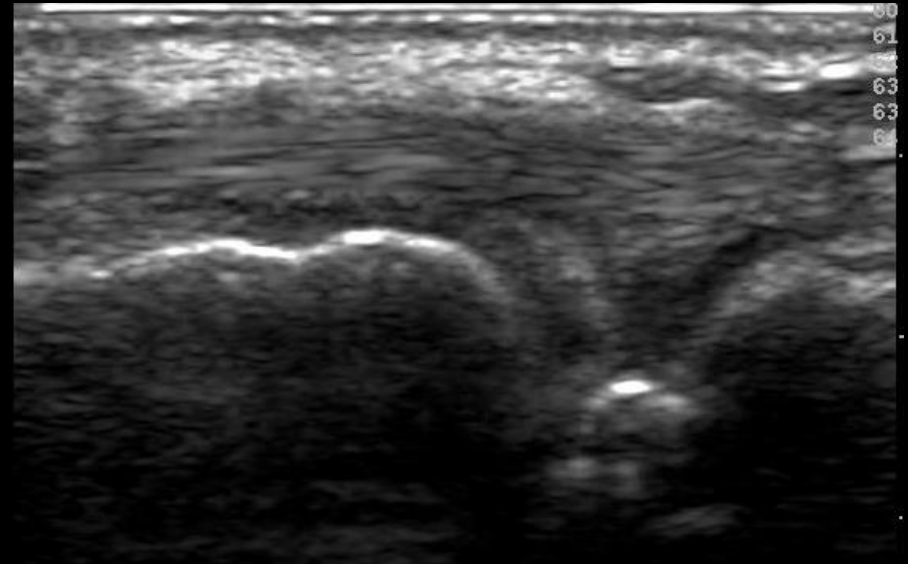
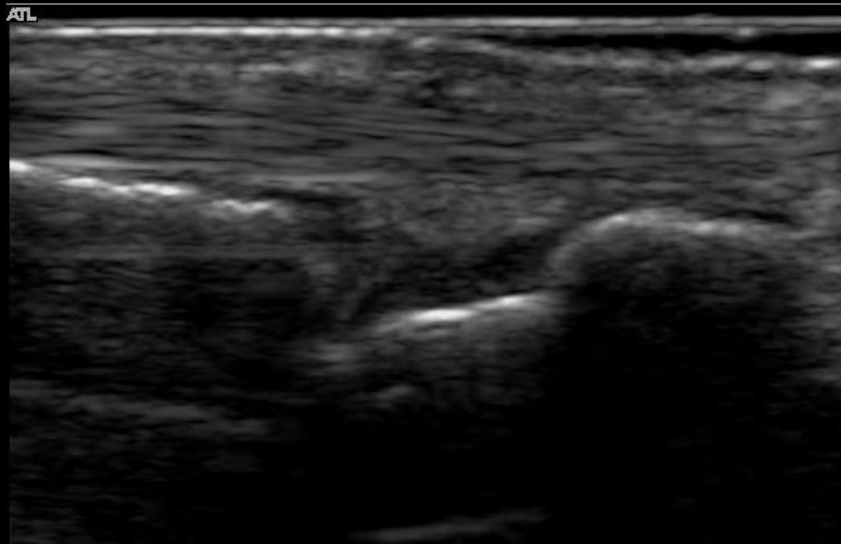
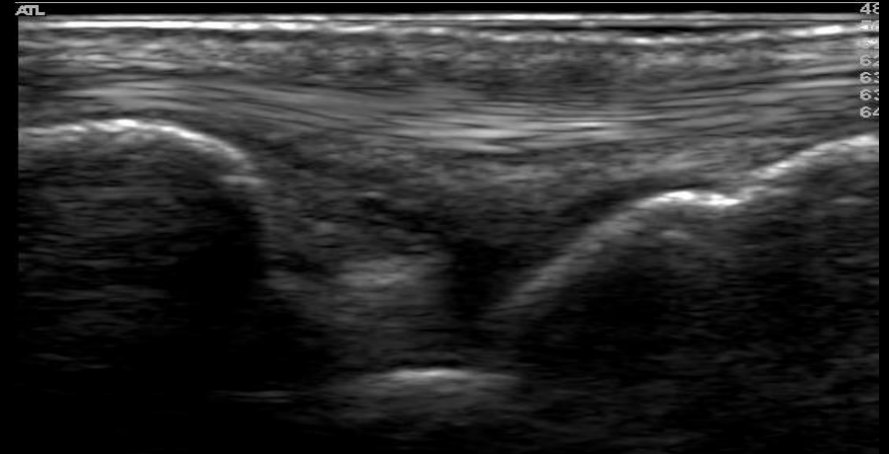
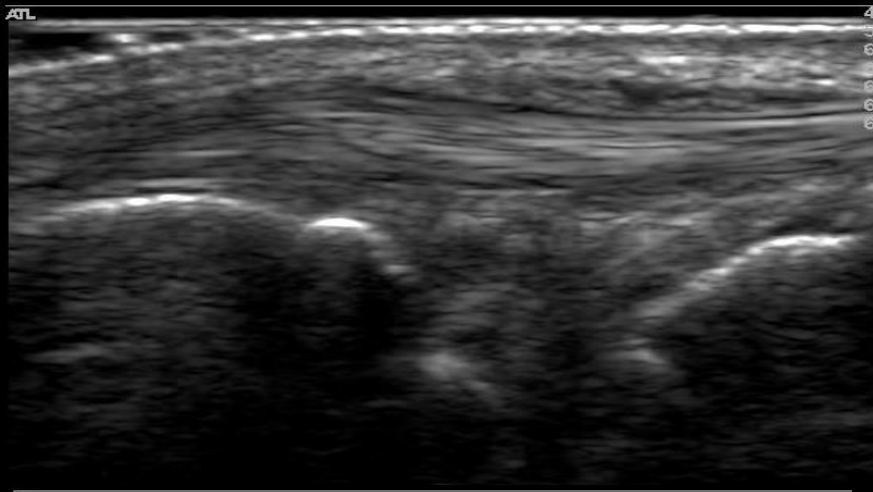
Ulnar-carpal joint - Lateral



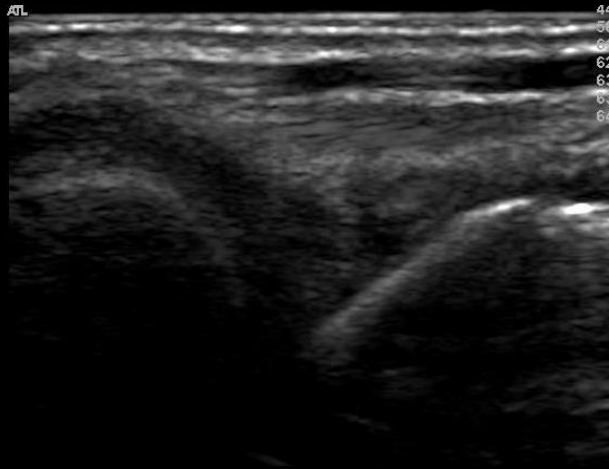
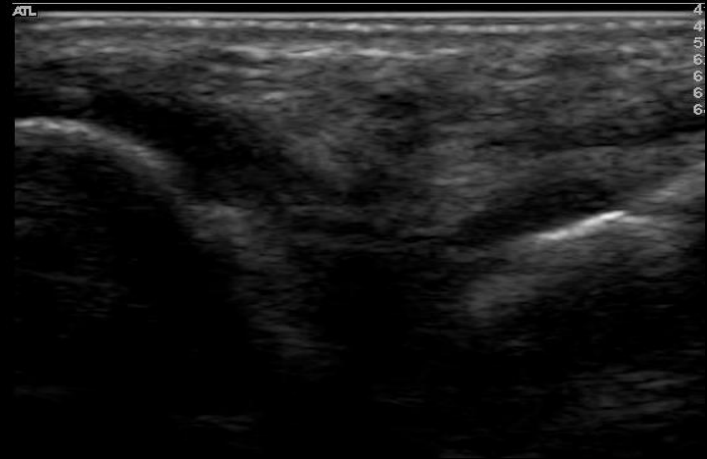
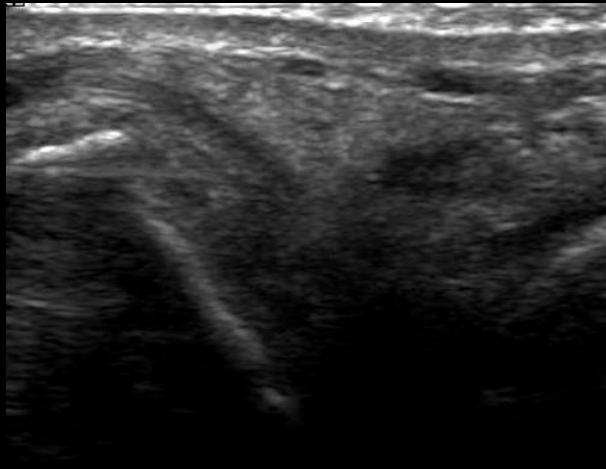
Ulnar-carpal joint - Lateral- GS- Grade 1



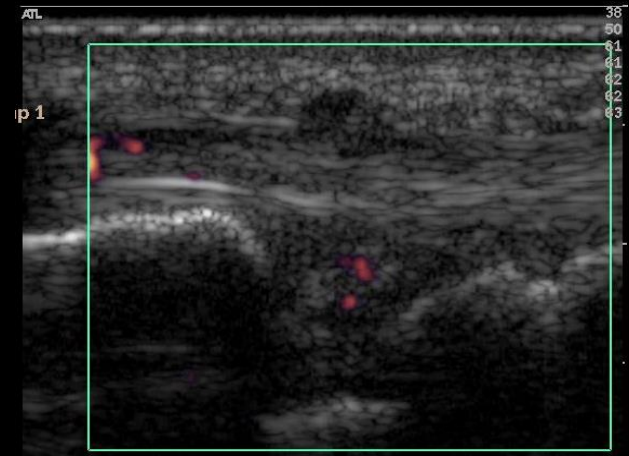
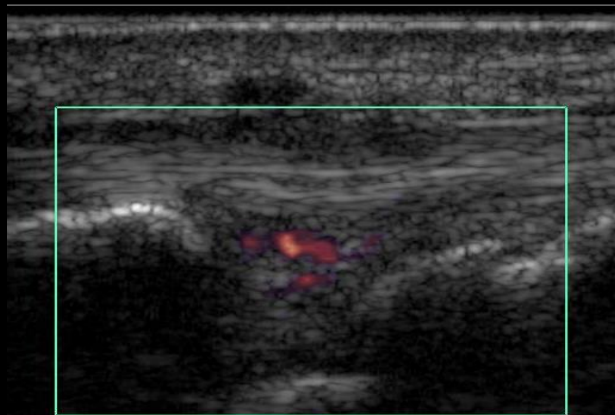
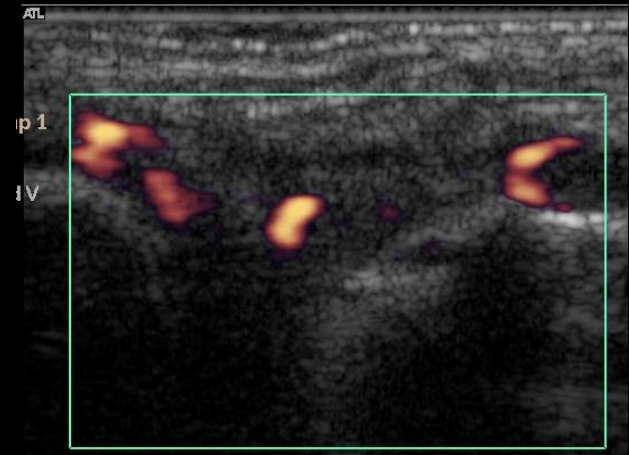
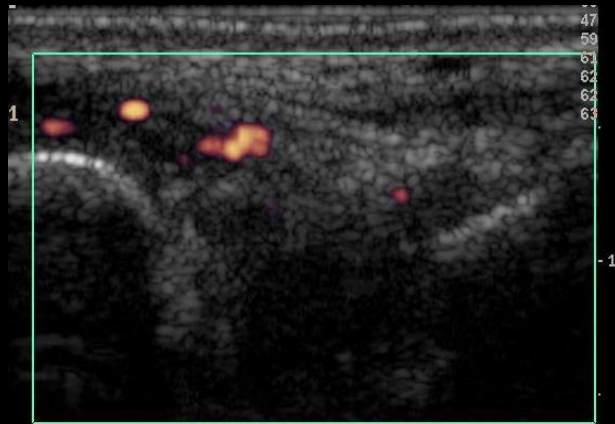
Ulnar-carpal joint - Lateral- GS- Grade 2



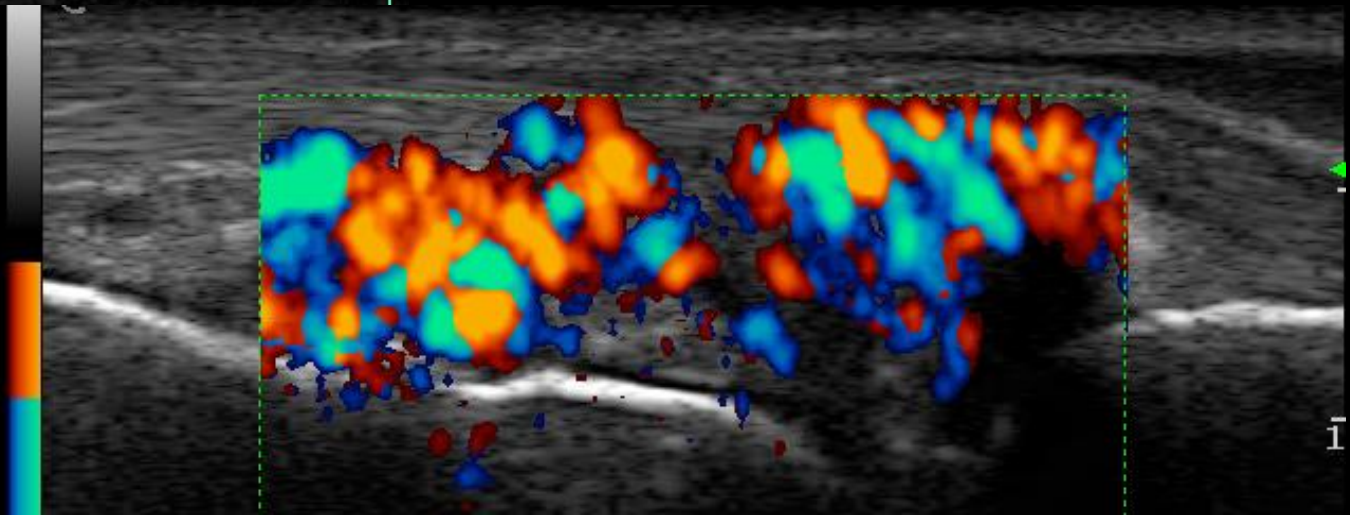
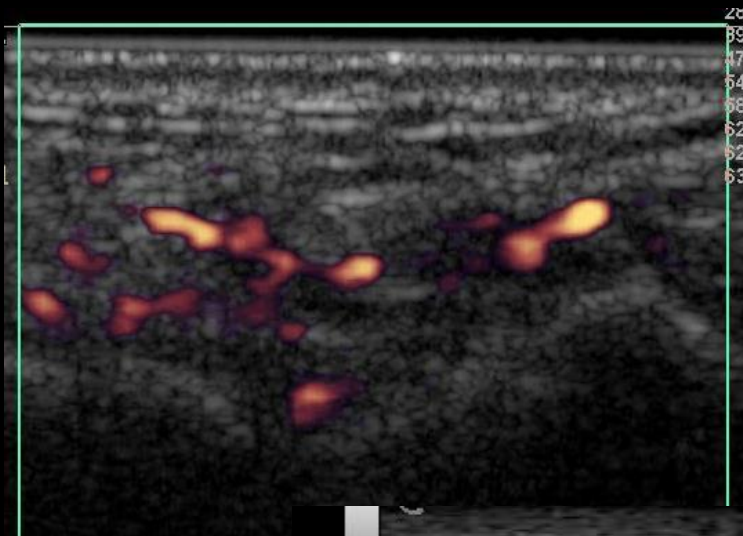
Ulnar-carpal joint - Lateral- GS- Grade 3



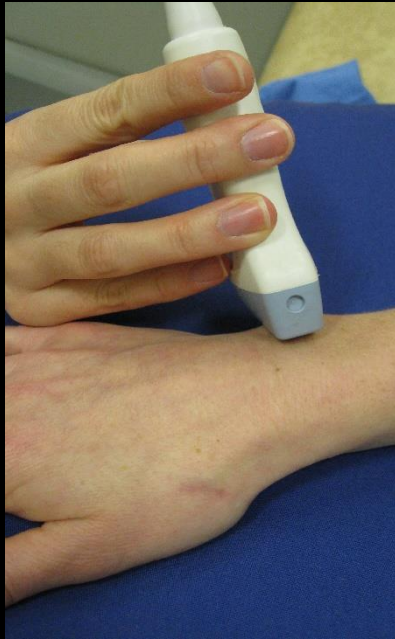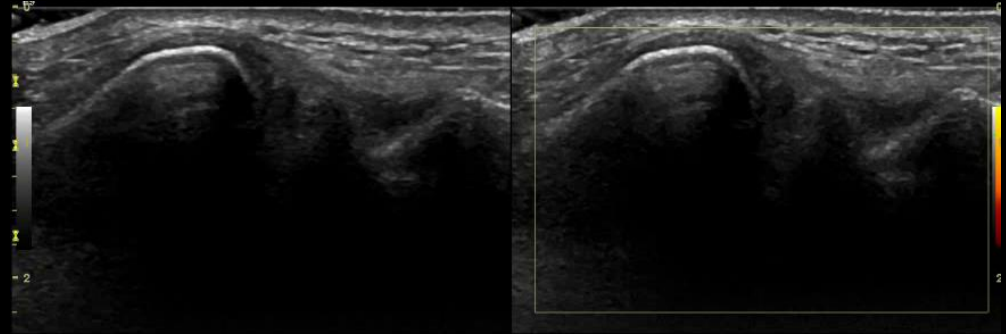
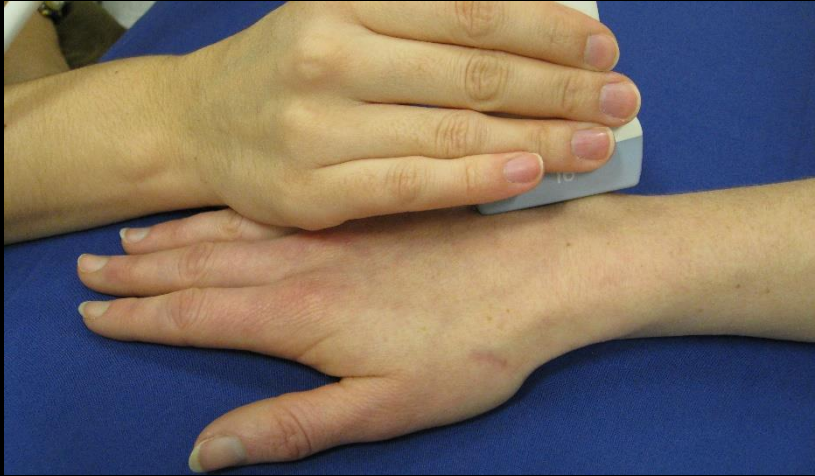Ulnar-carpal joint – Lateral- PD- Grade 2



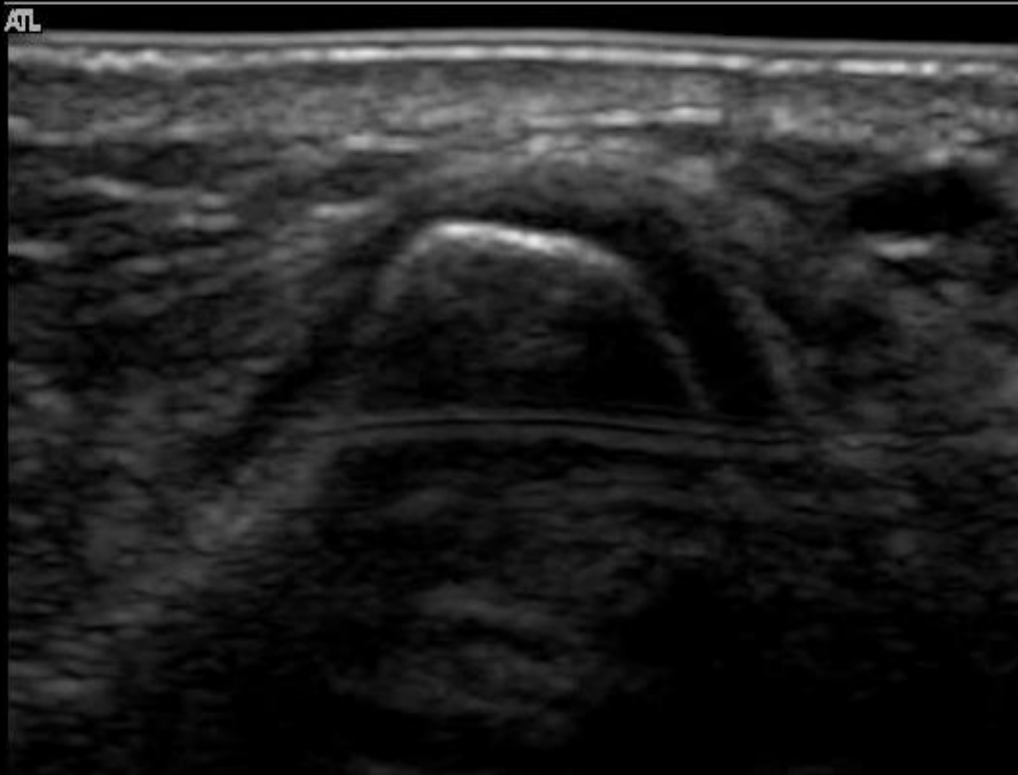
Ulnar-carpal joint – Lateral- PD- Grade 3



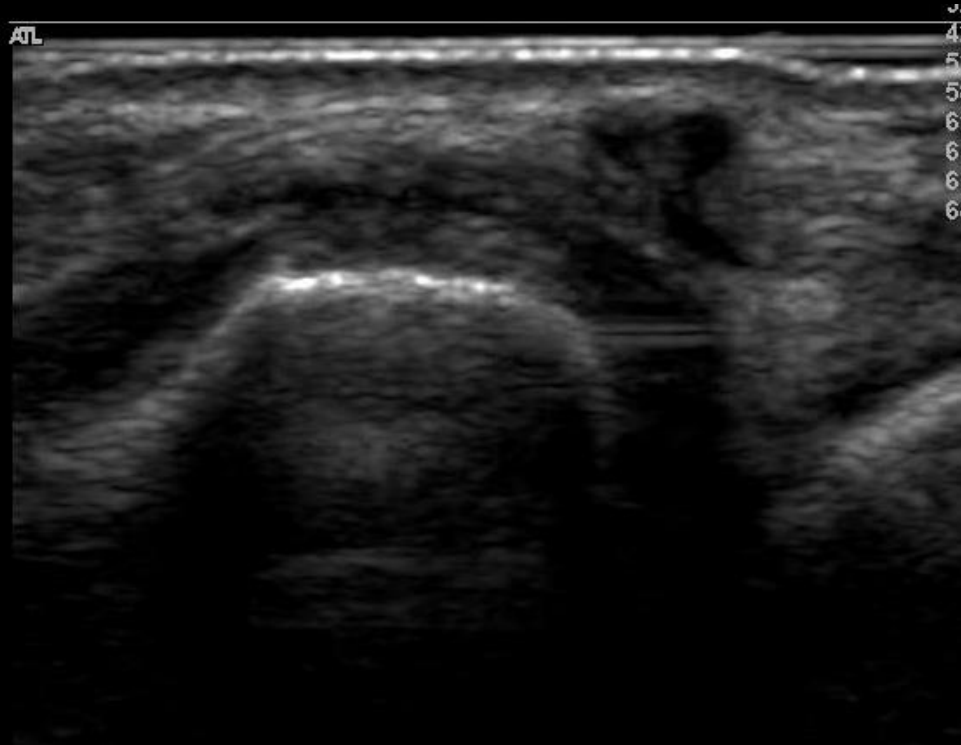
Ulnar-carpal joint - Dorsal



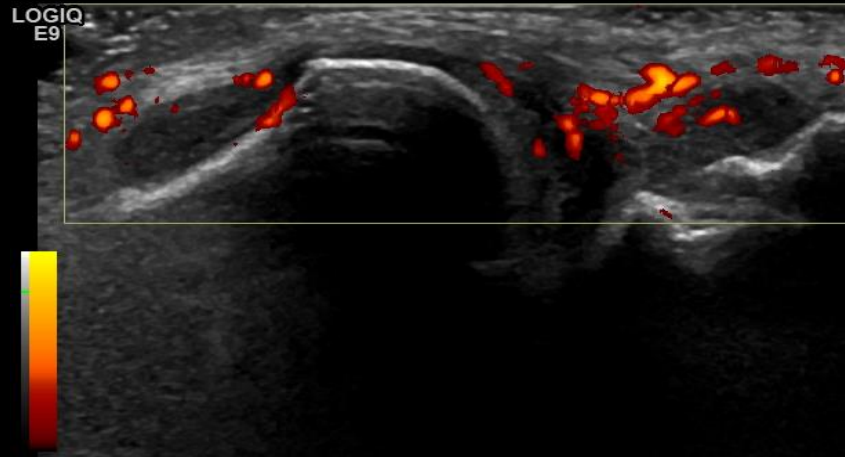
Ulnar-carpal joint – Dorsal- GS- Grade 1



Ulnar-carpal joint – Dorsal- GS- Grade 3



Ulnar-carpal joint – Dorsal- PD- Grade 2

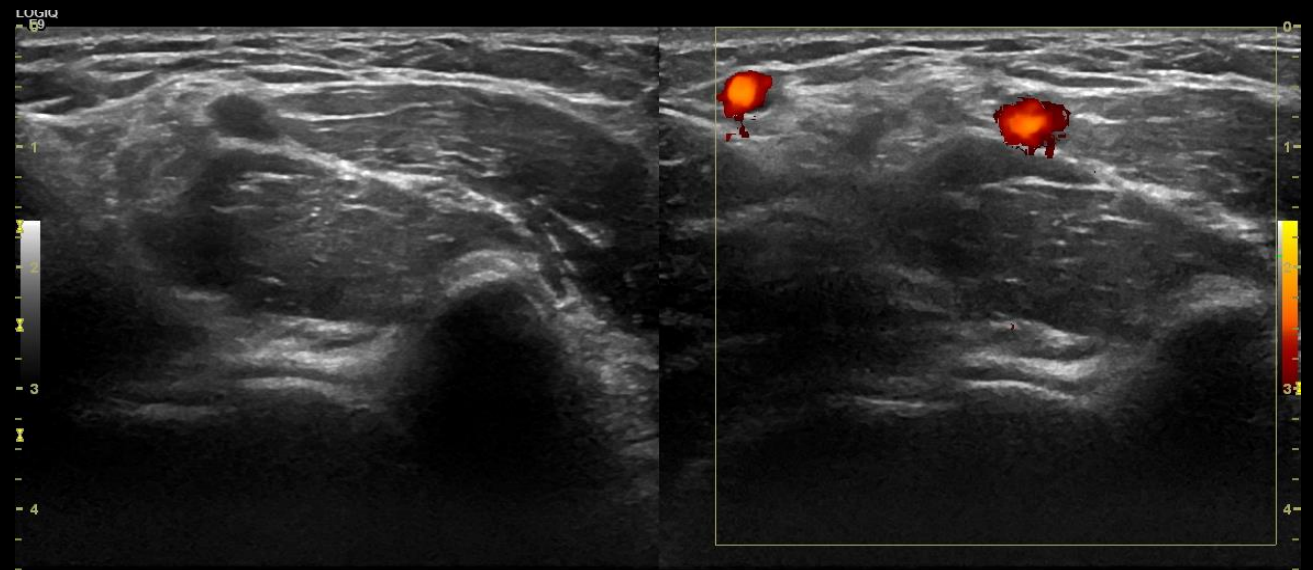
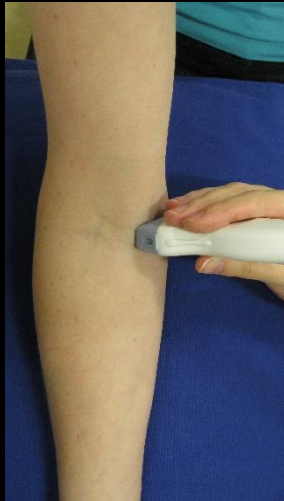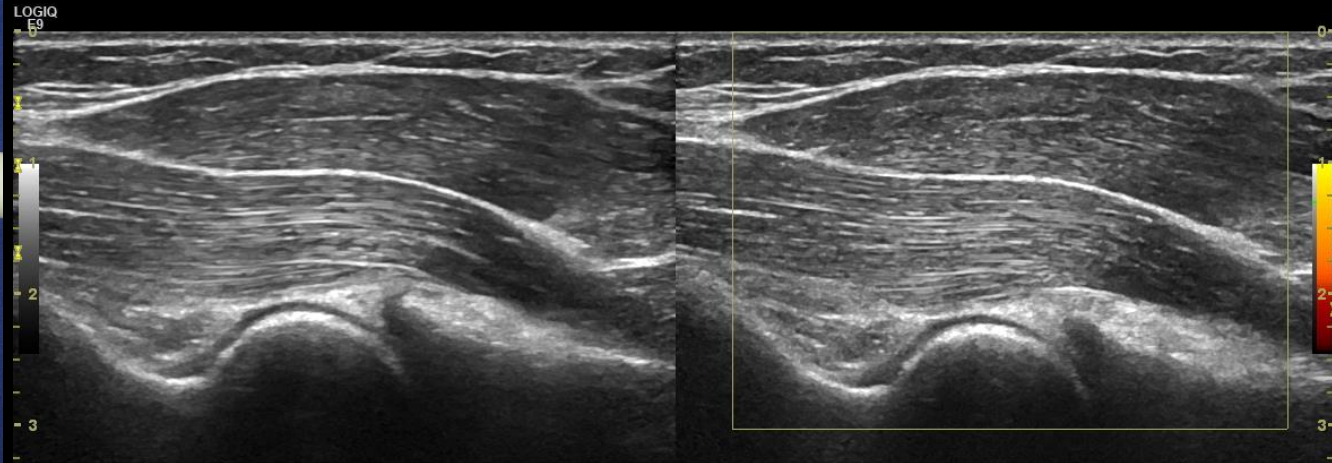
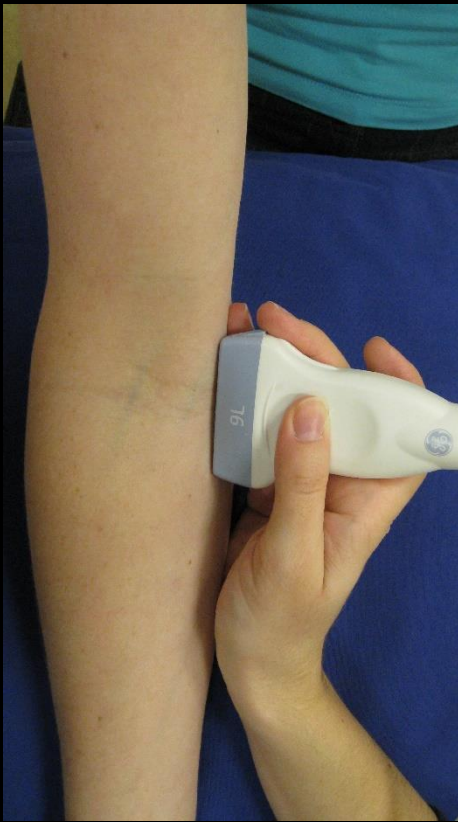


Elbow

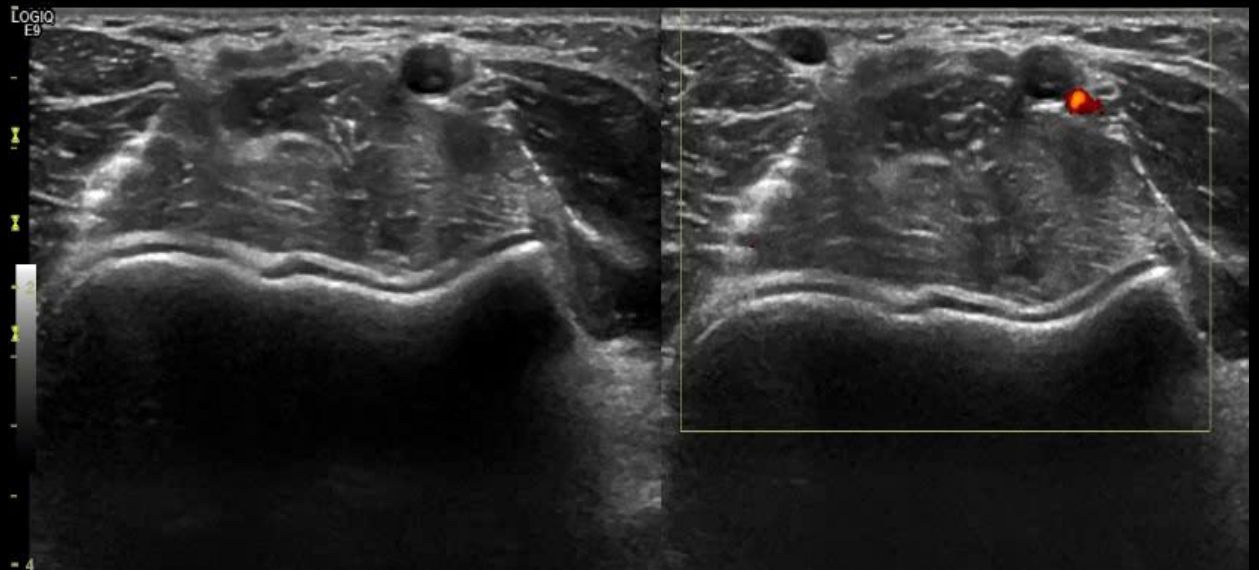
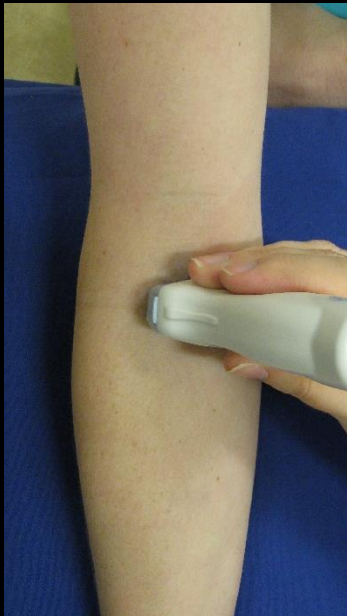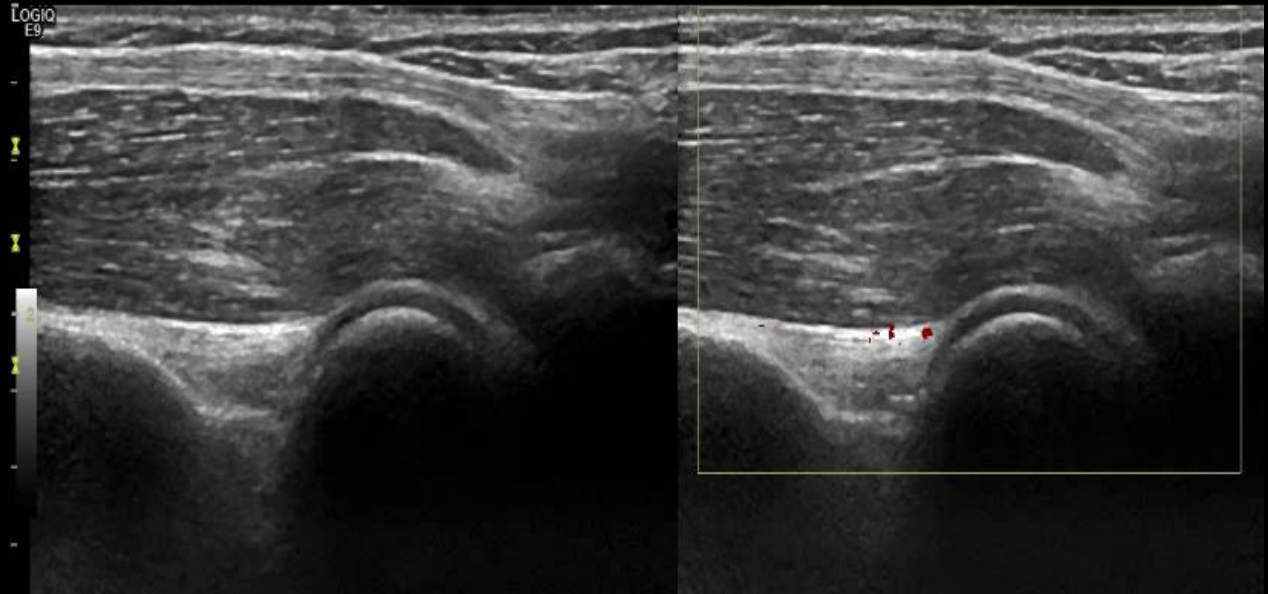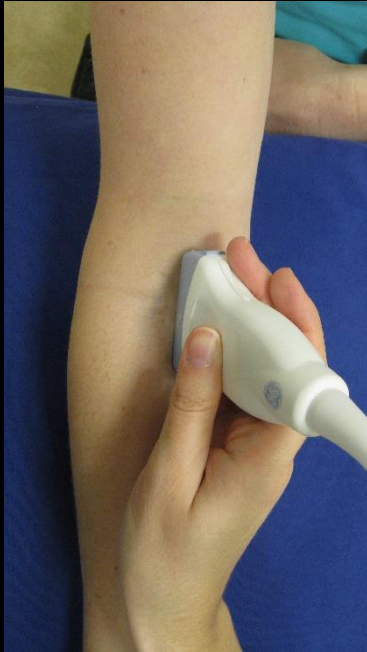The elbow is scanned from 4 views

- **Humero-ulnar joint**
- **Midline**
- **Humero-radial joint**
- **Posterior – olecranon fossa**

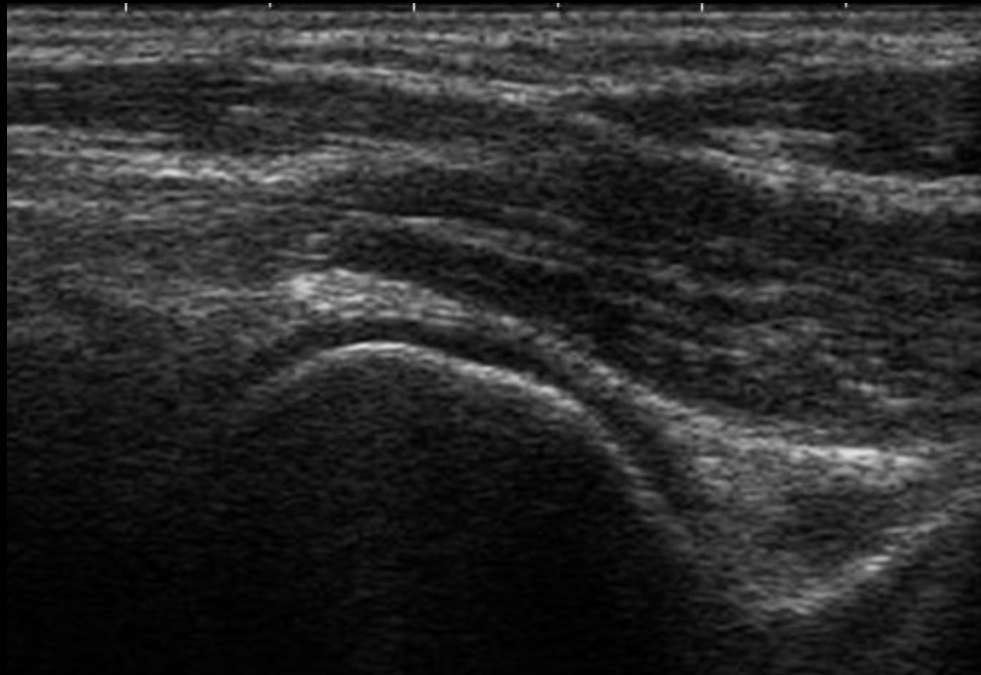
Humero-ulnar joint - Normal



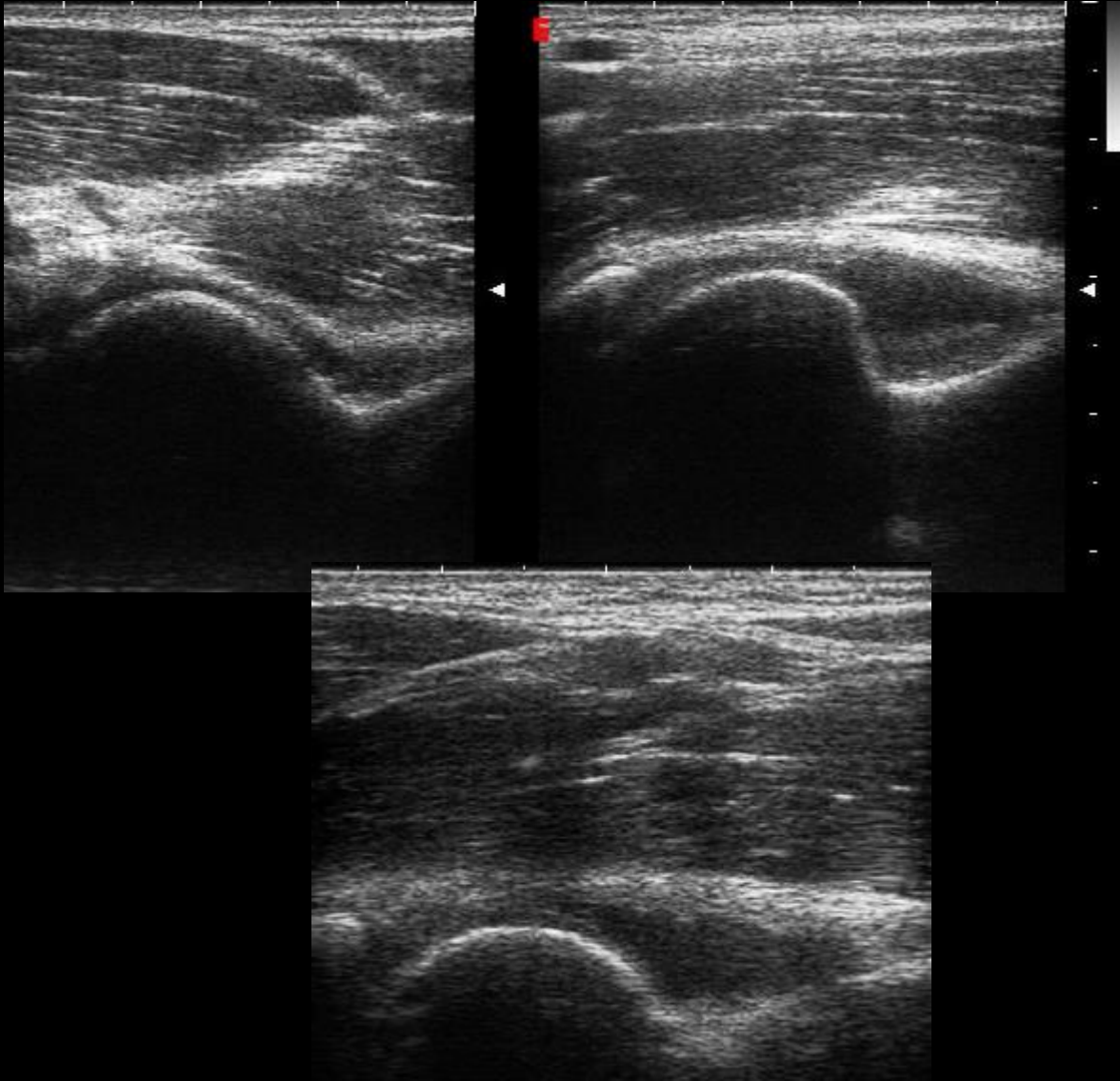
Mid-elbow – Normal



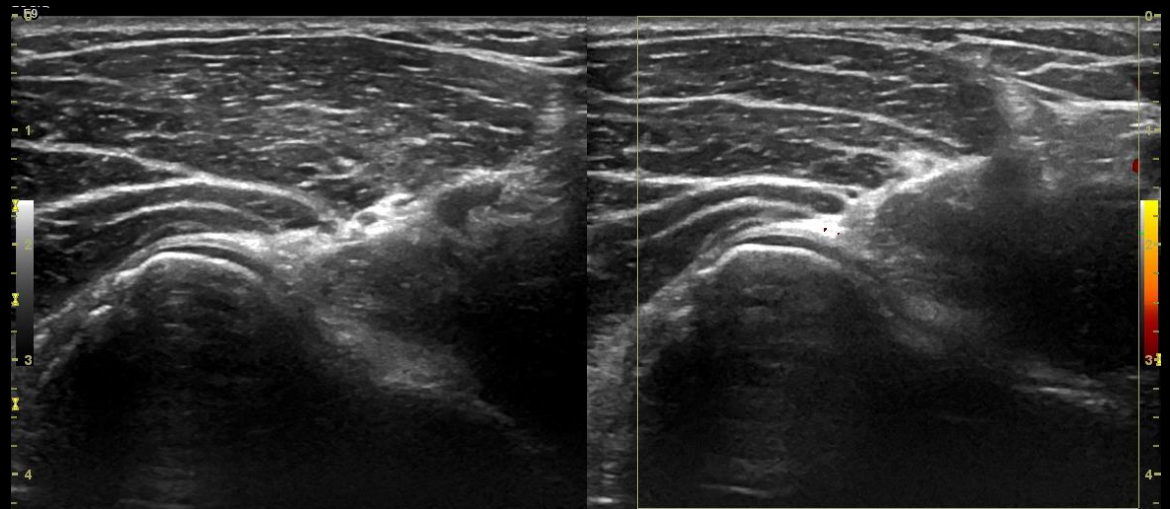
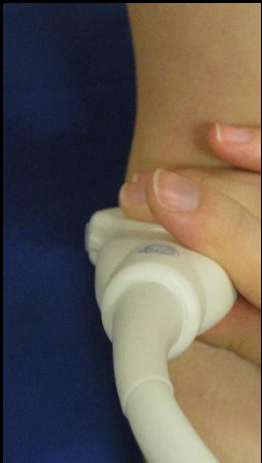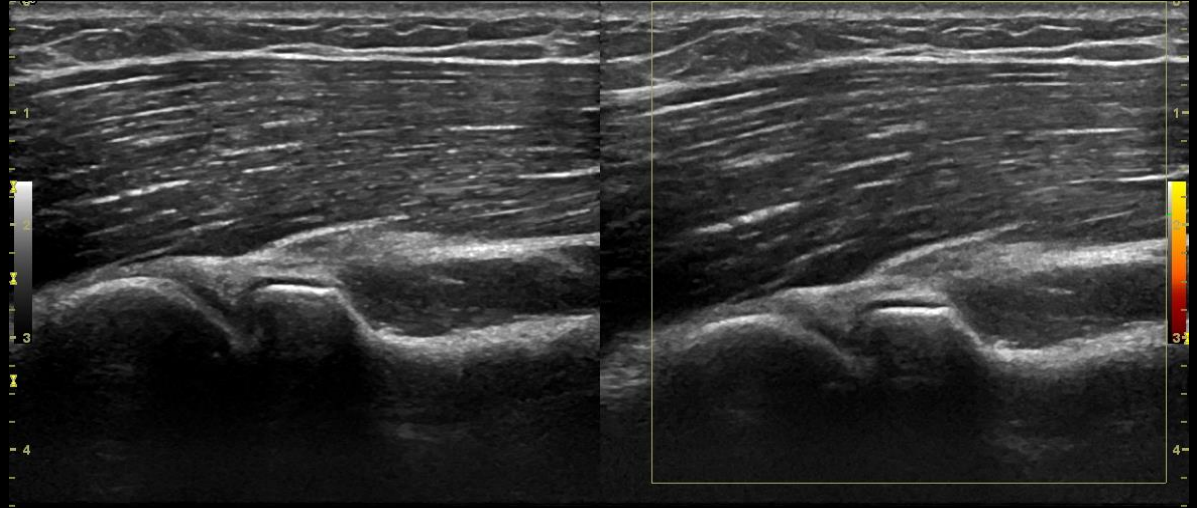
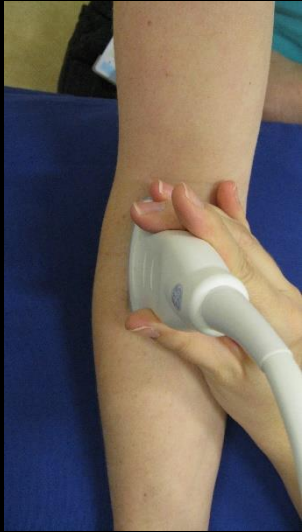Mid-elbow-GS-Grade 1



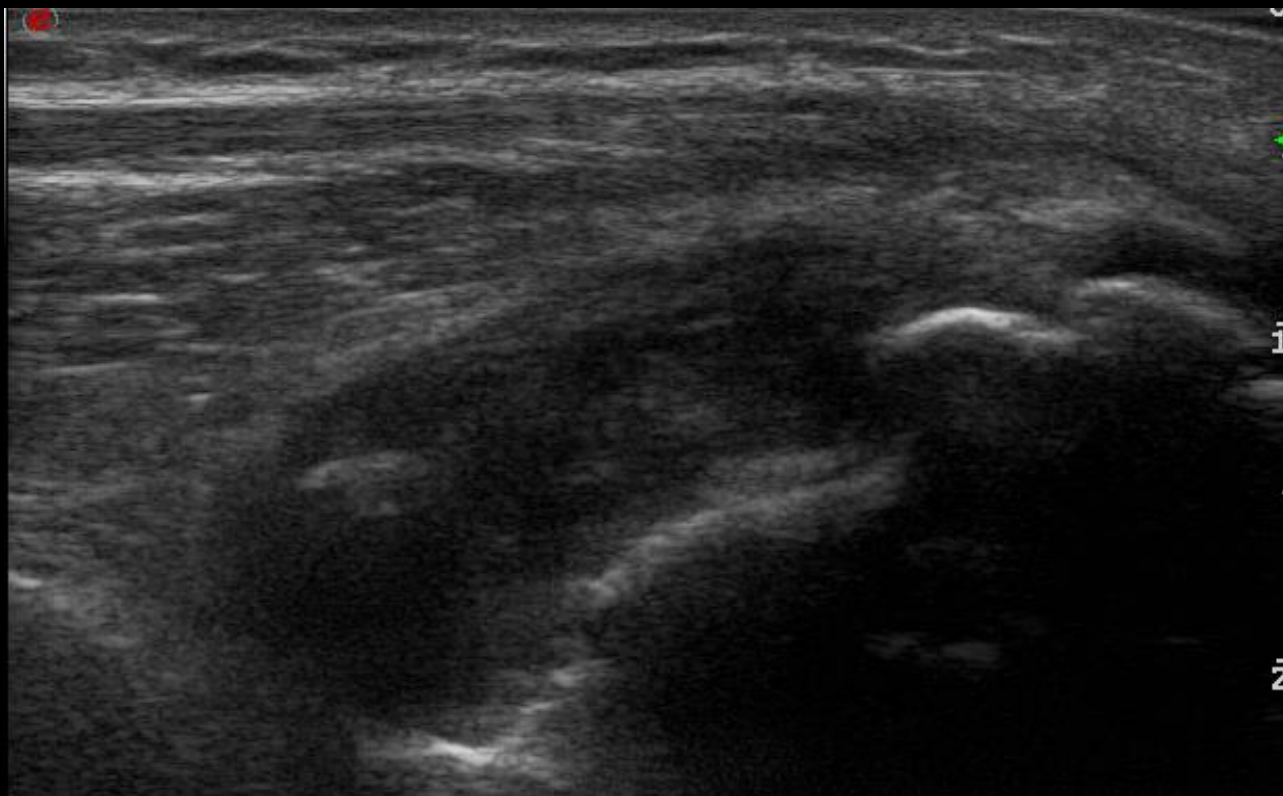
Mid-elbow-GS-Grade 2



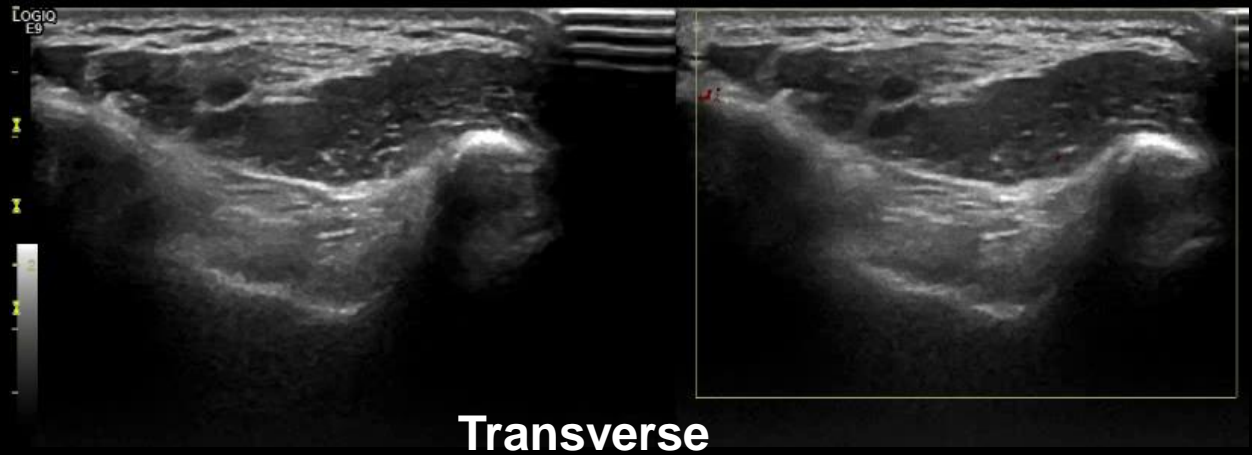
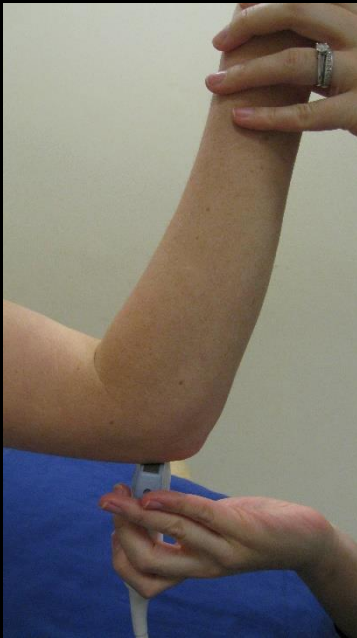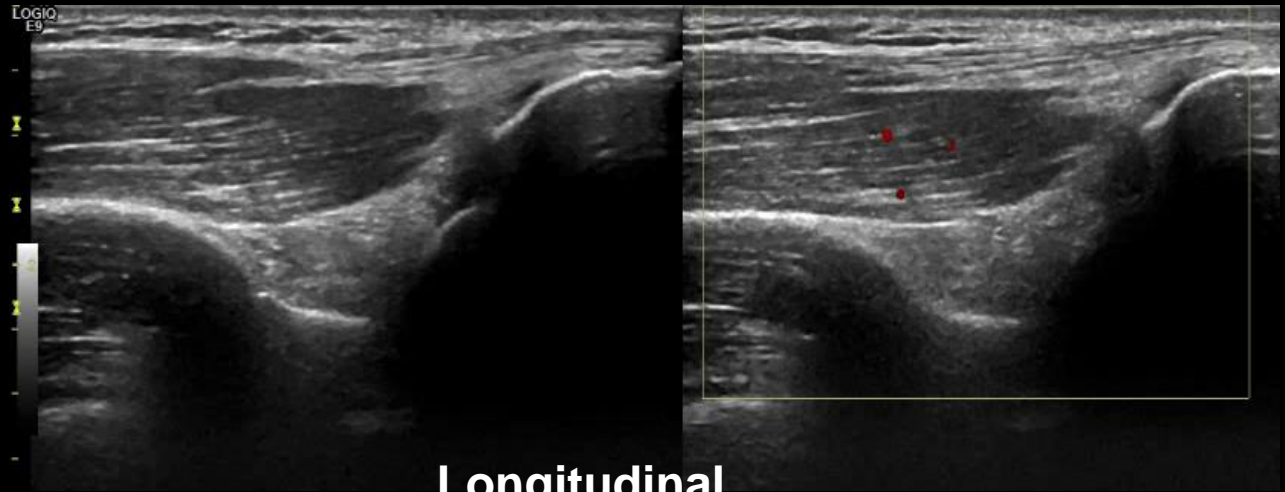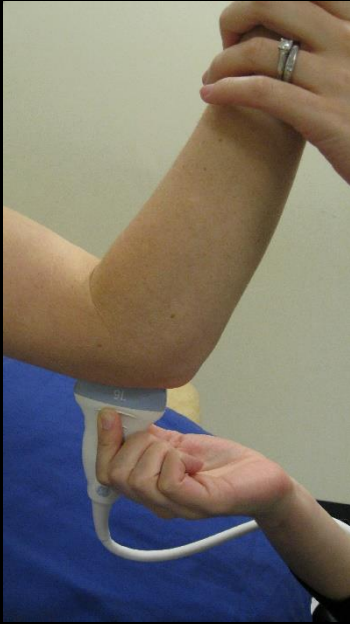Humero-radial joint - Normal



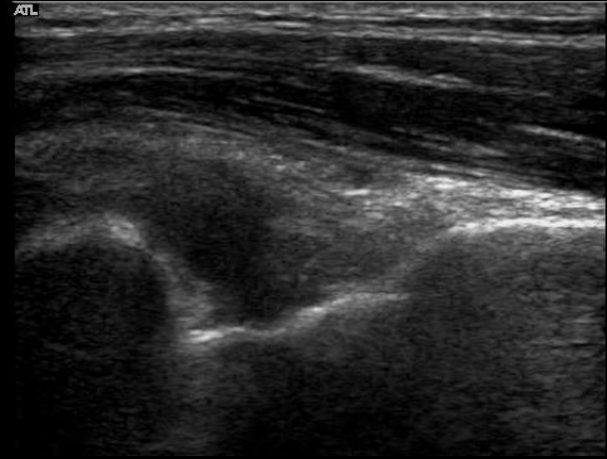
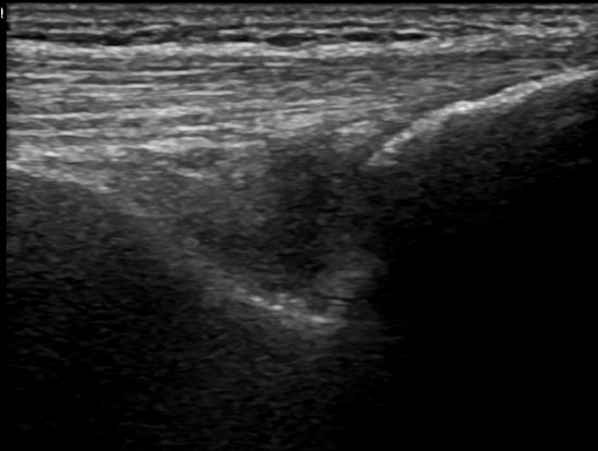
Humero-radial joint – GS- Grade 3



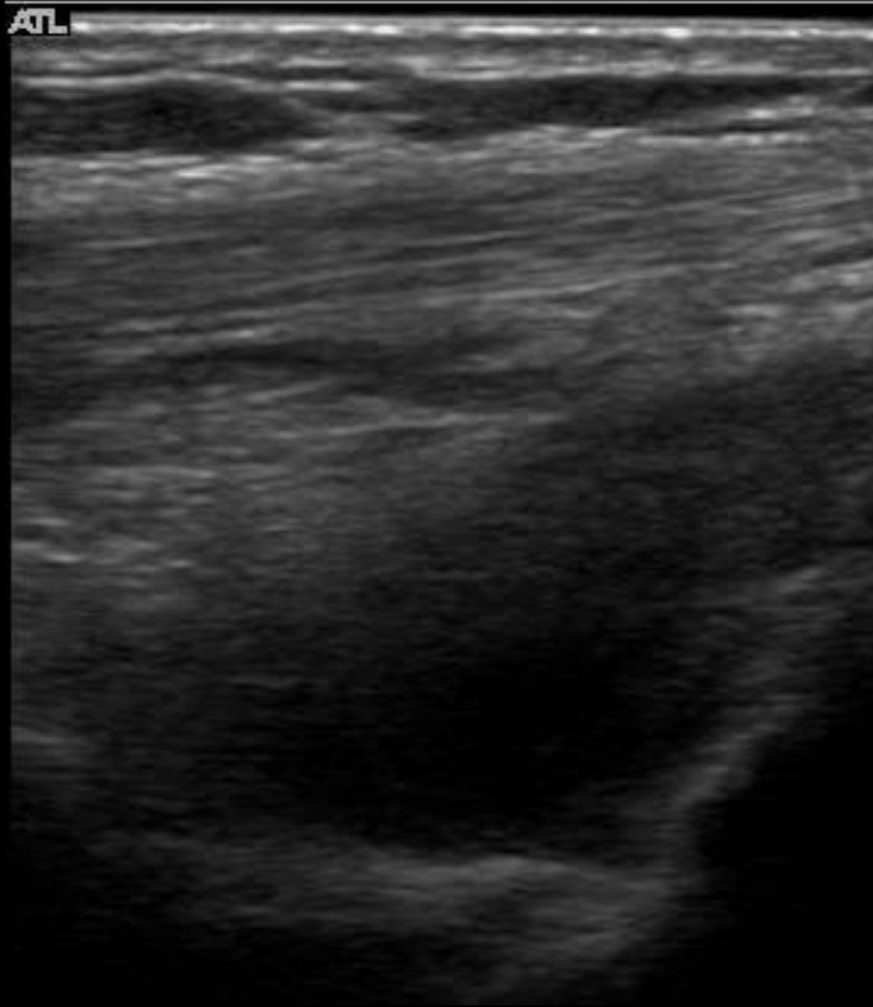
Posterior: Olecranon fossa - Normal



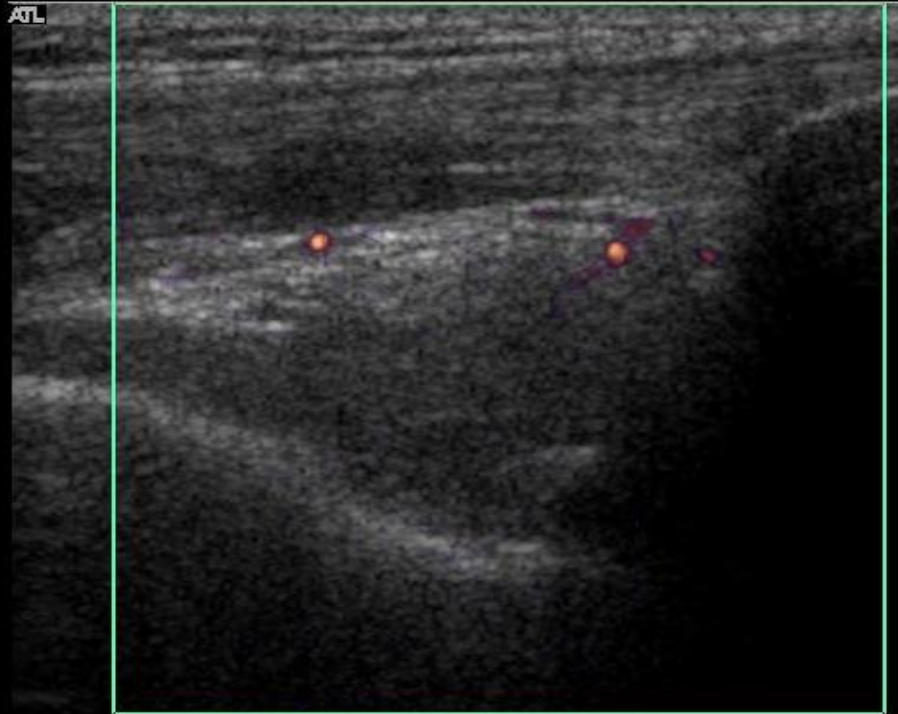
Olecranon fossa- GS- Grade 2



Olecranon fossa- GS- Grade 3

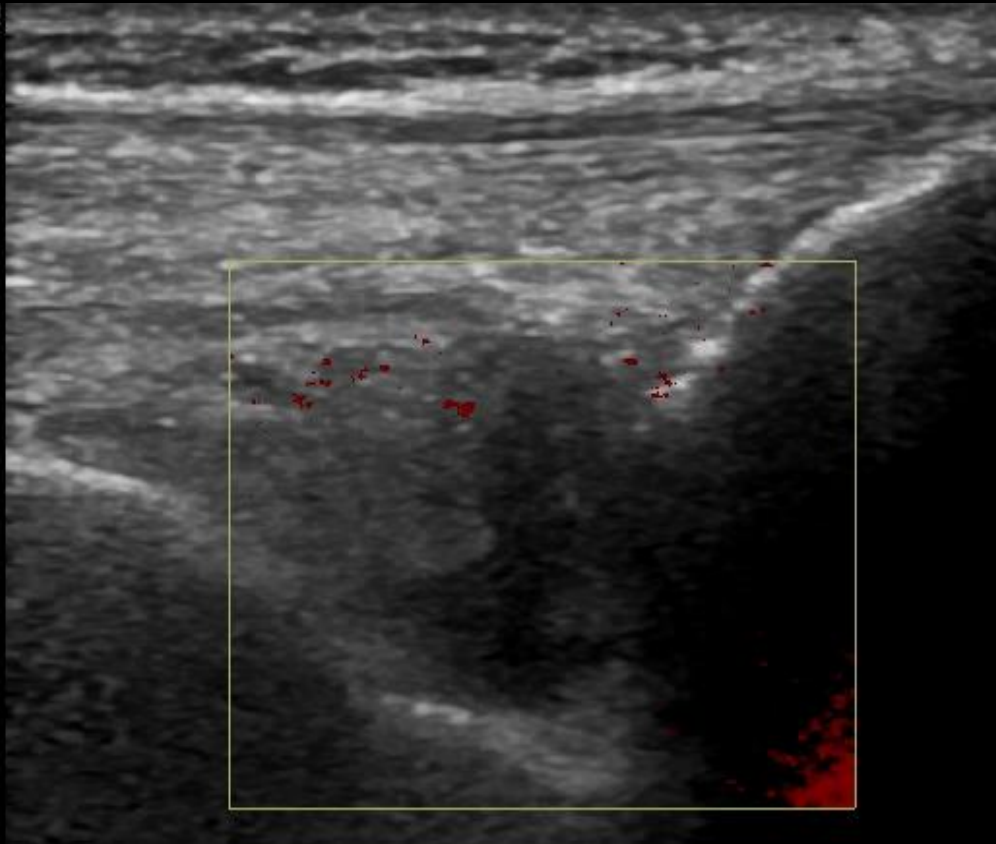


Olecranon fossa- PD- Grade 1

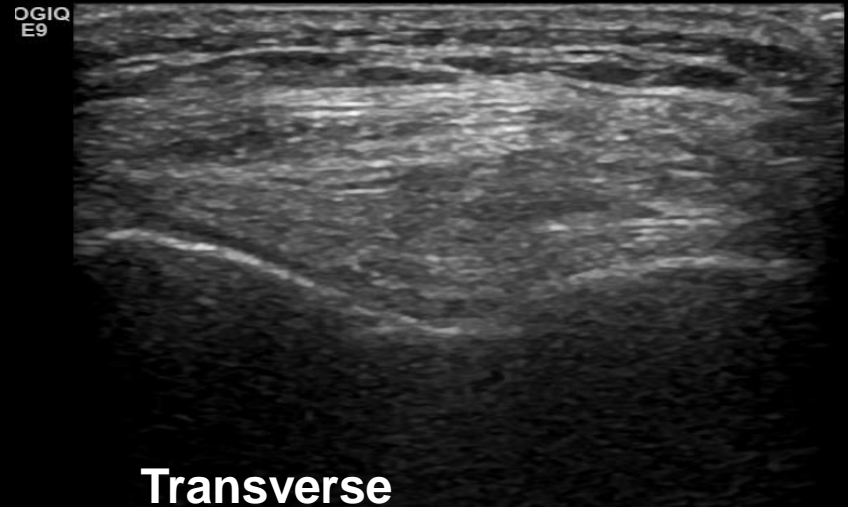
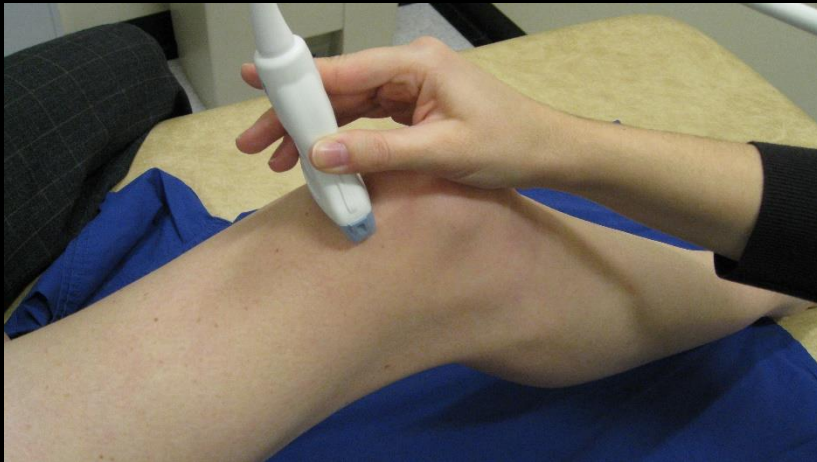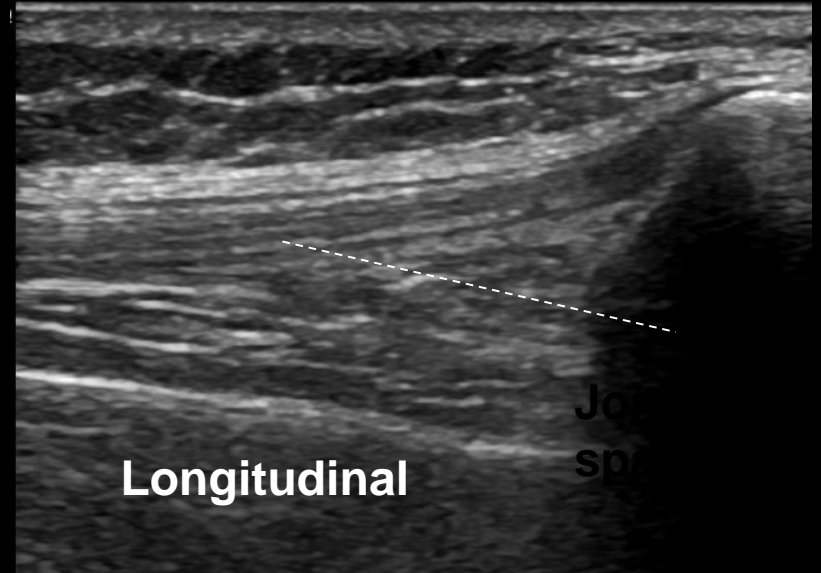

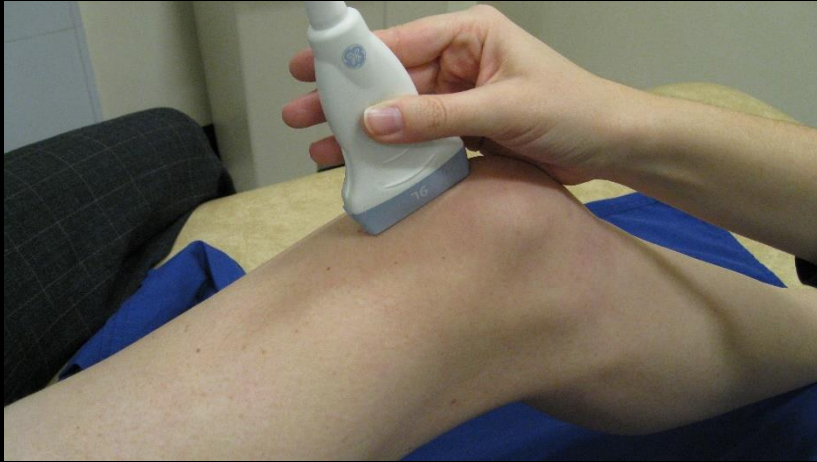
44
41
50
59
62
62
63
64

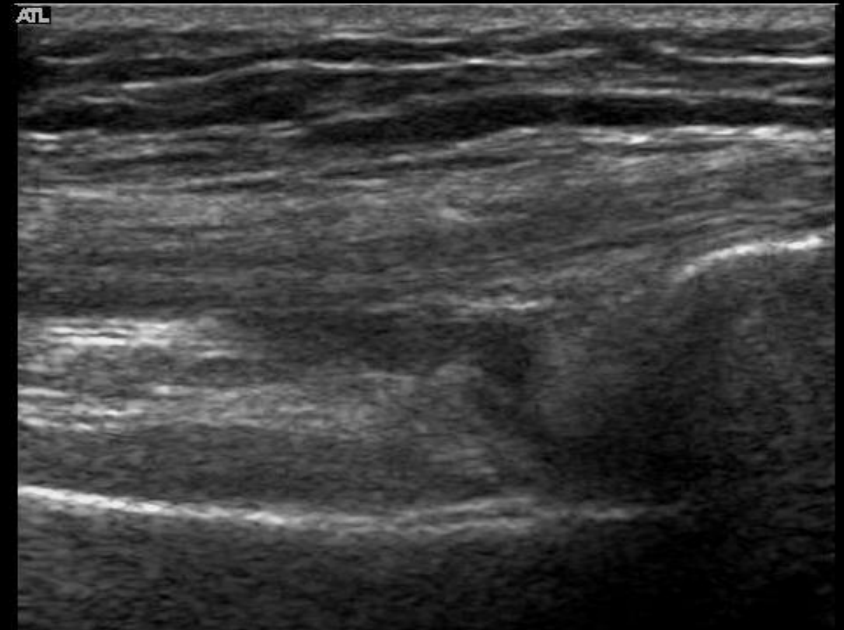
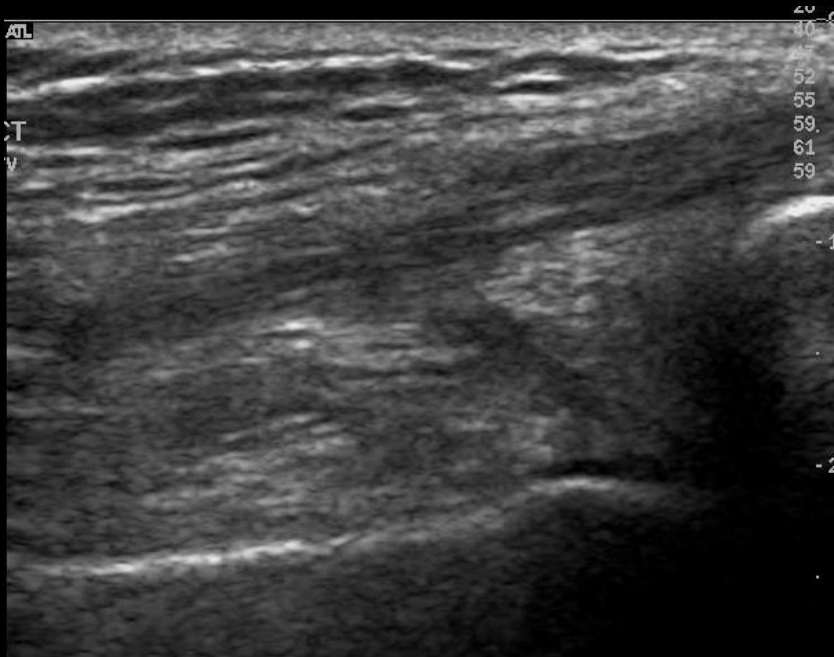
Olecranon fossa- PD- Grade 2



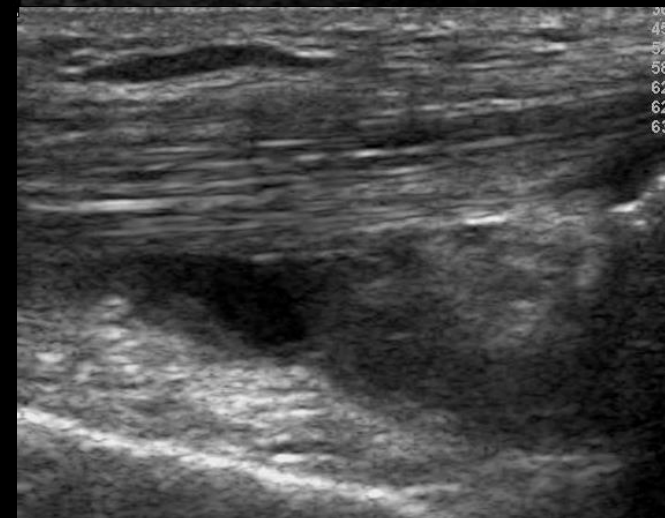
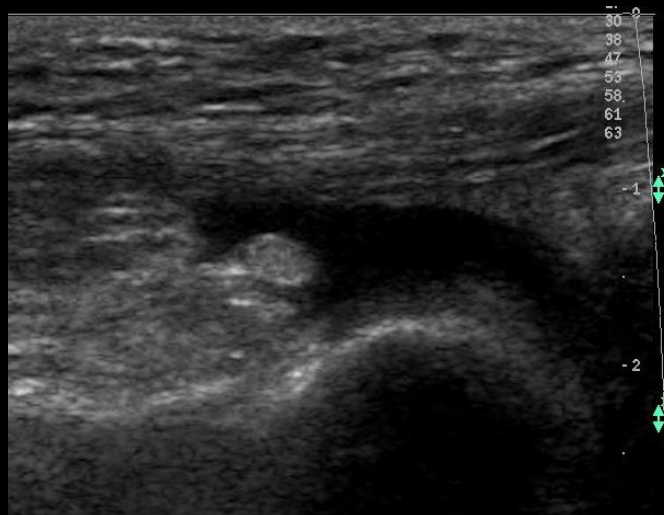
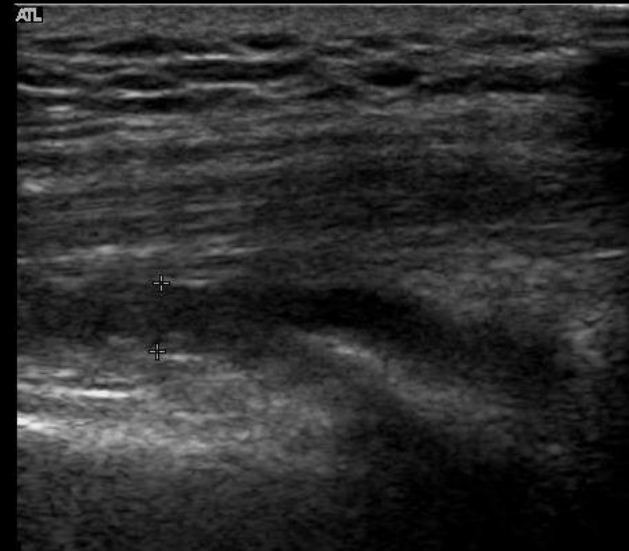
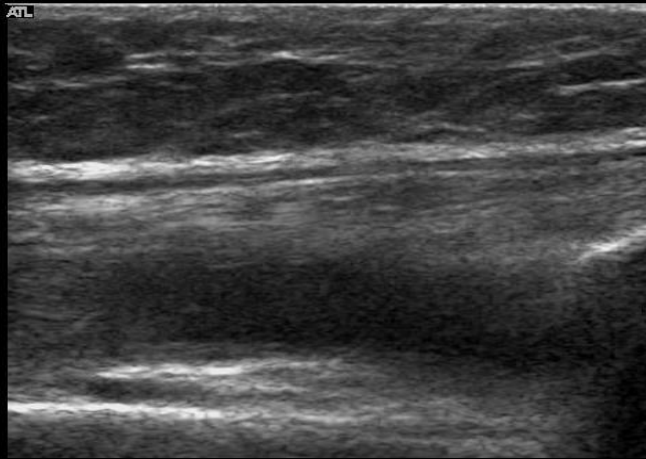
Supra-patella pouch – 30 degrees - Normal



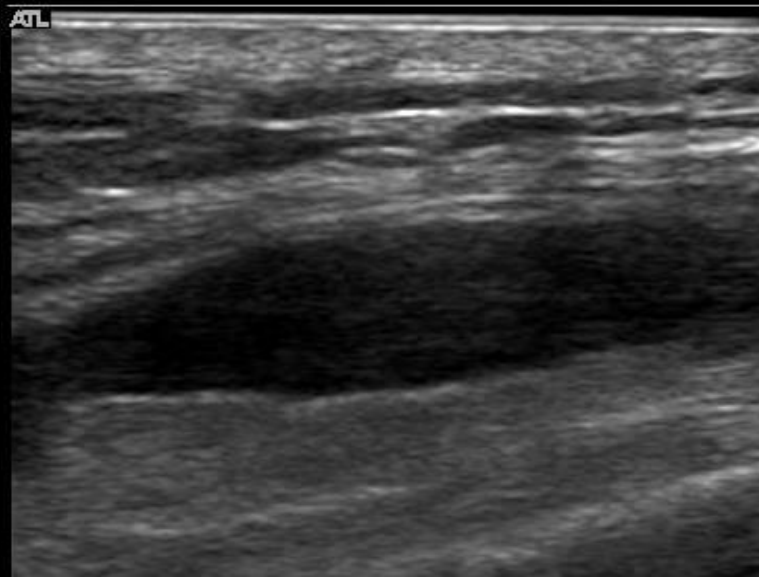
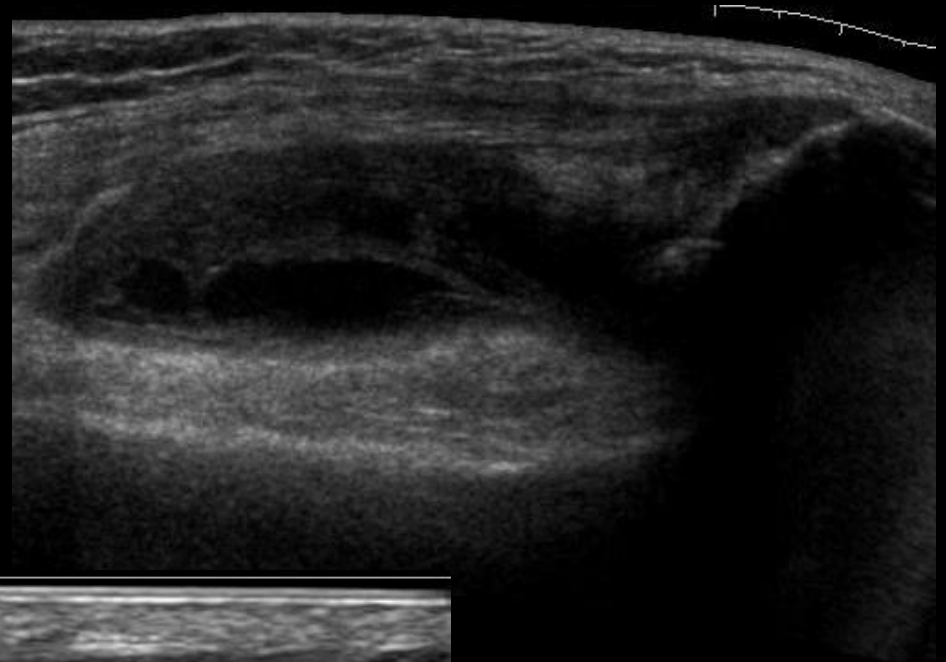
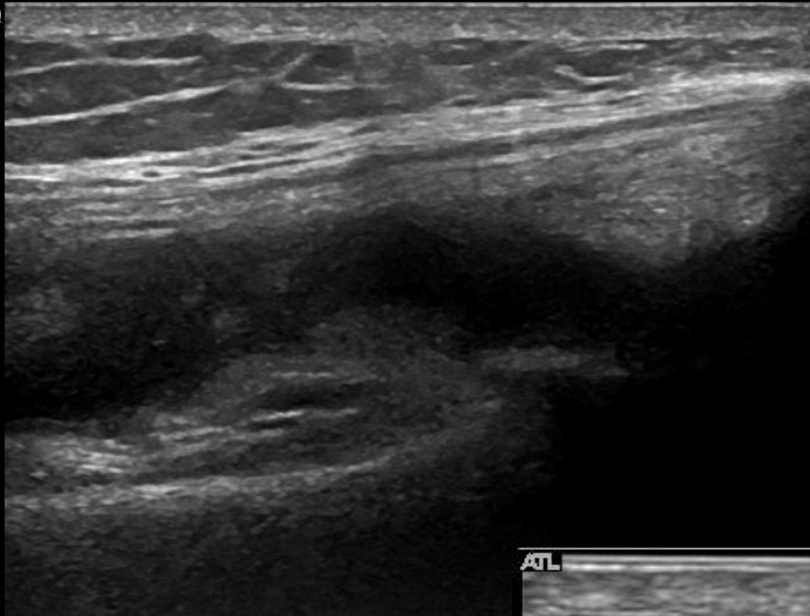
Supra-patella pouch – GS -Grade 1



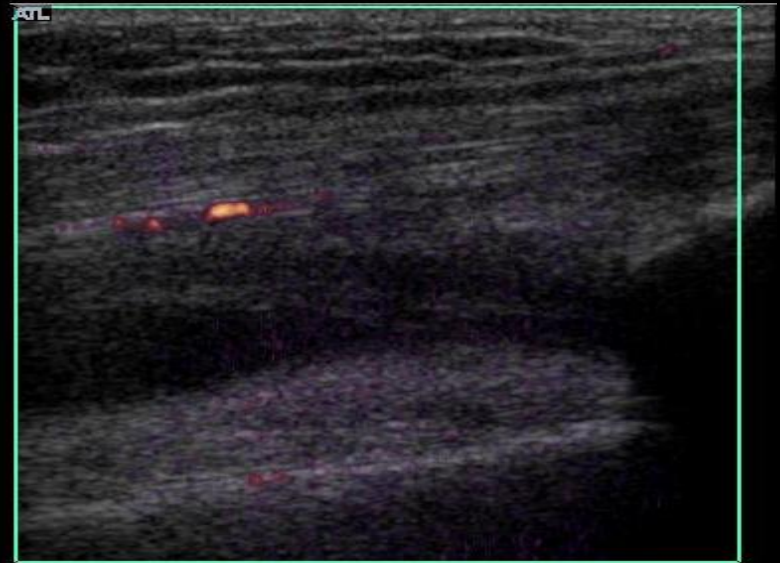
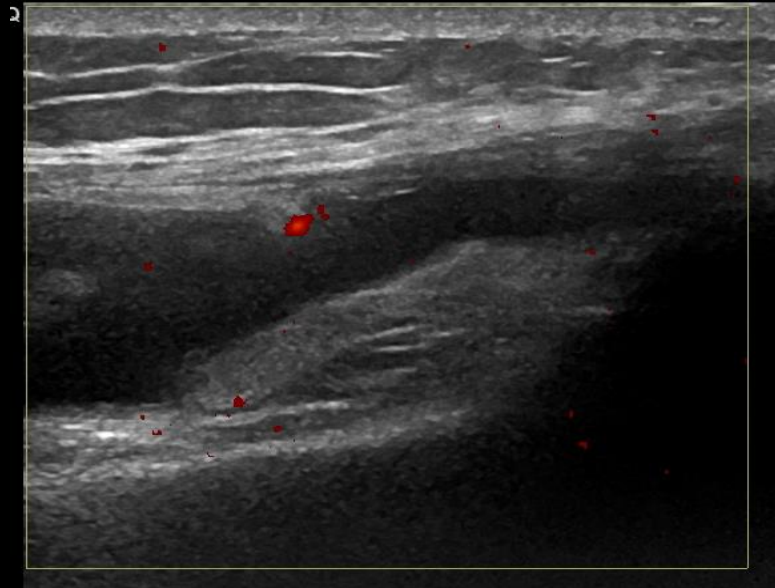
Supra-patella pouch – GS - Grade 2



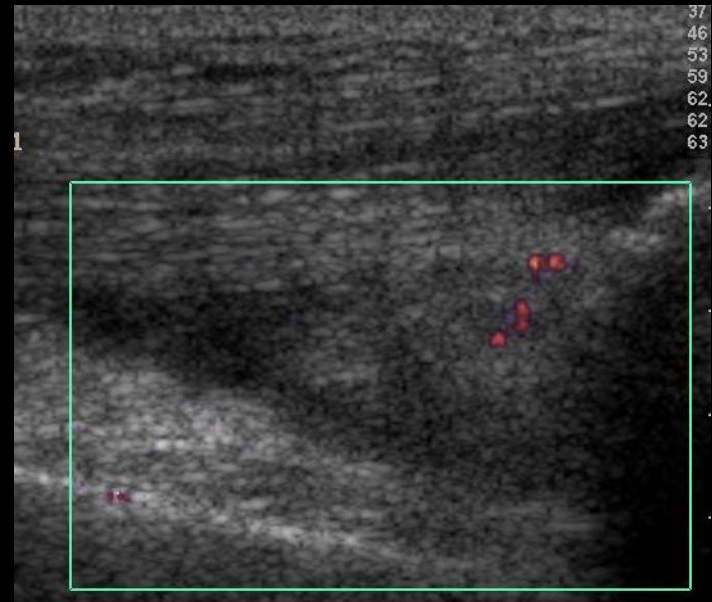
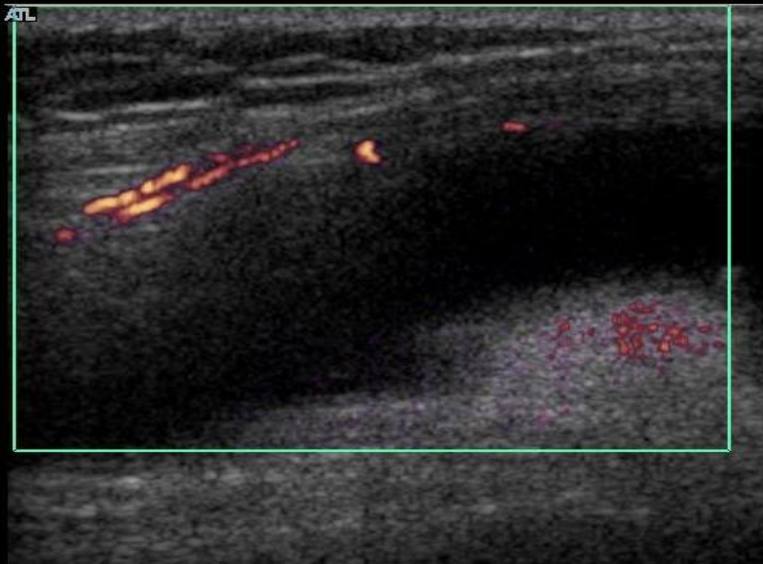
Supra-patella pouch – GS - Grade 3



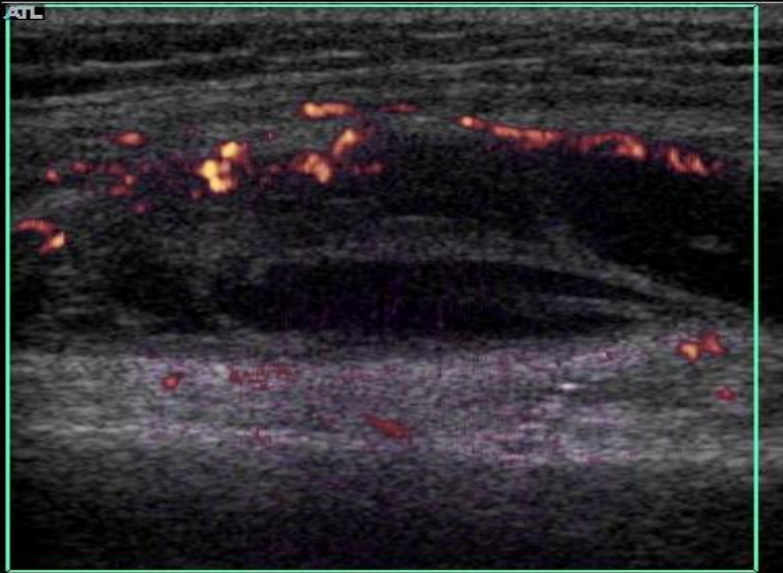
Supra-patella pouch – PD - Grade 1



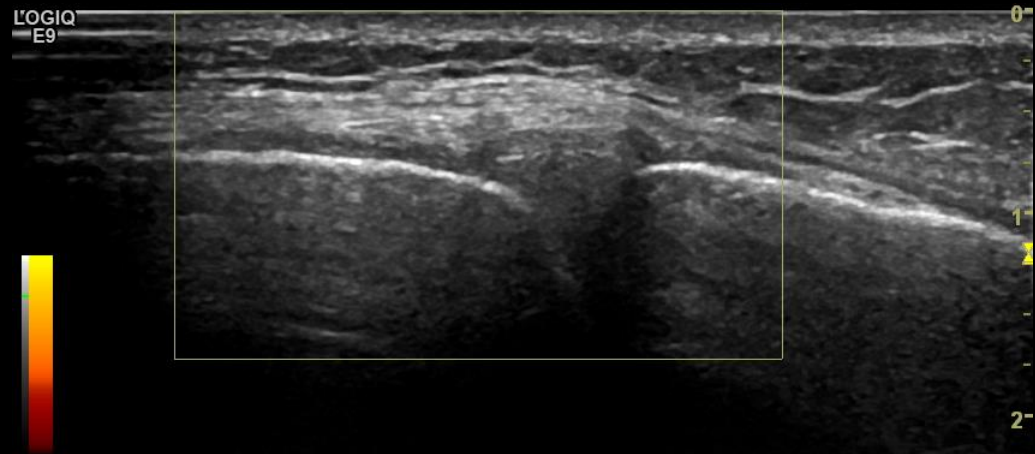
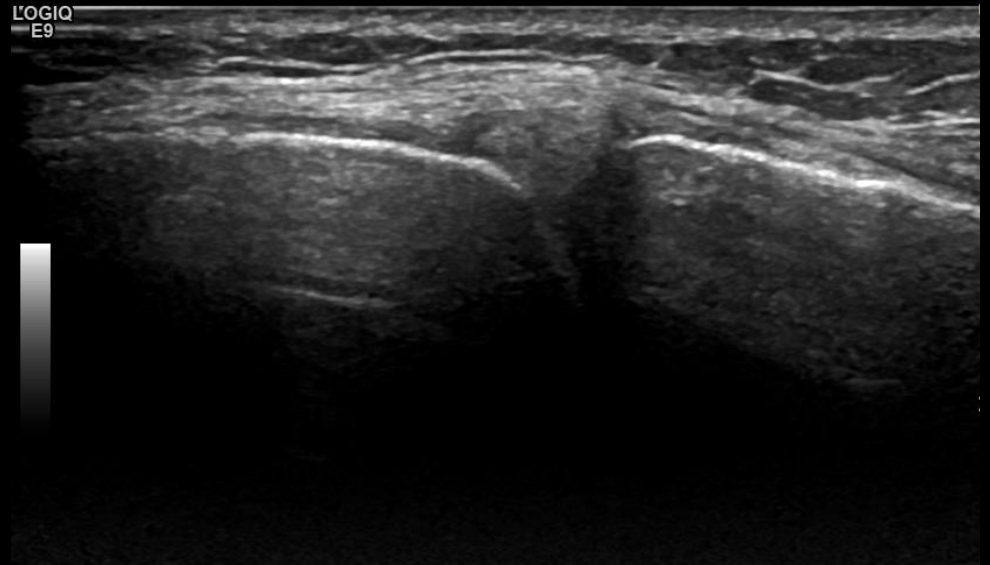
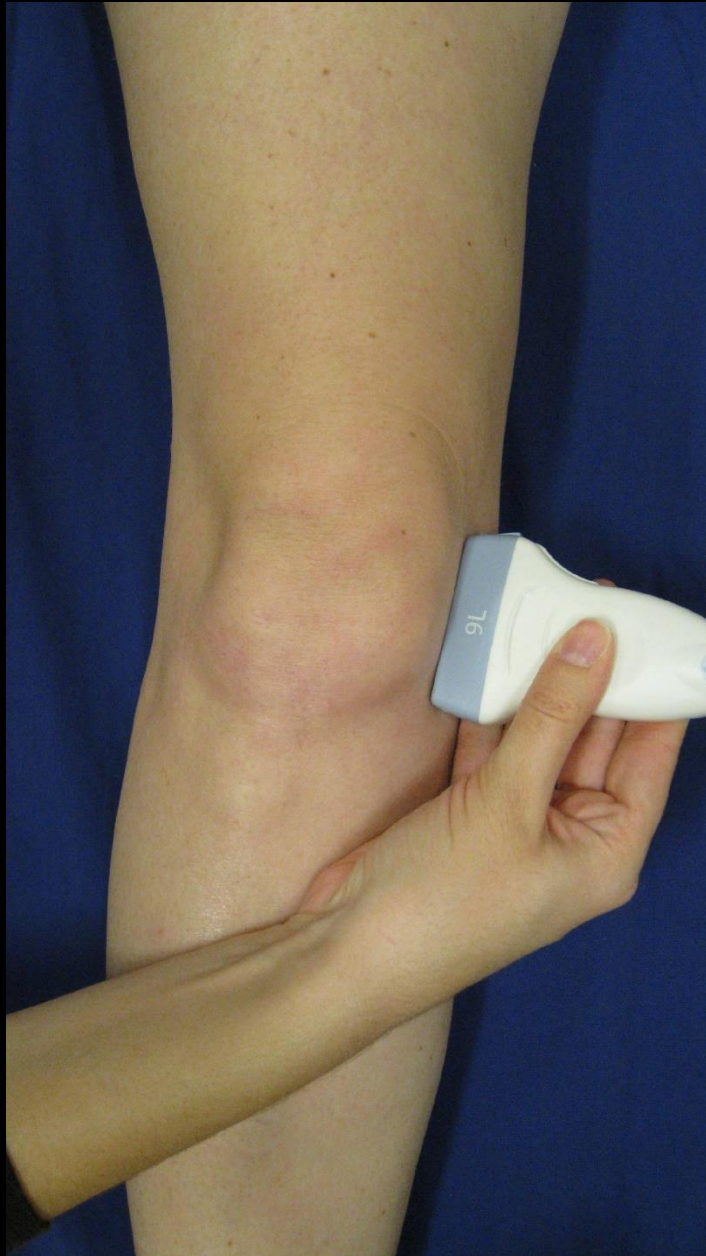Supra-patella pouch – PD - Grade 2



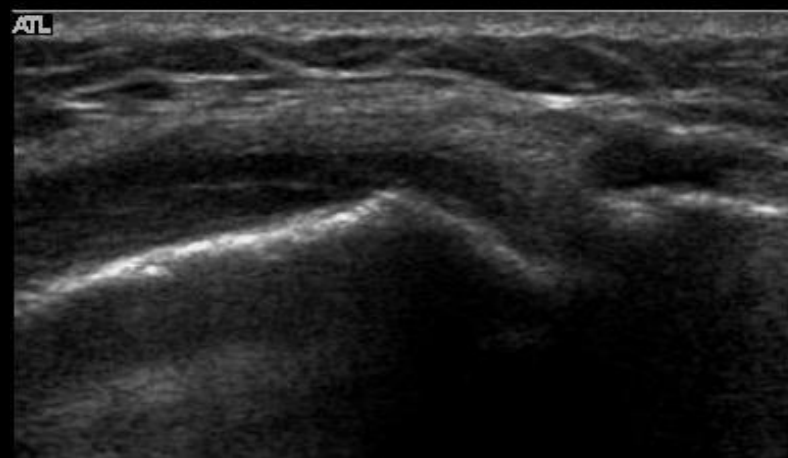
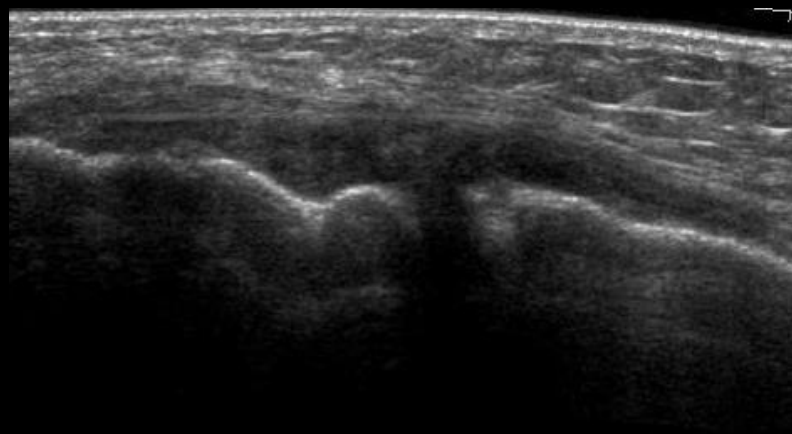
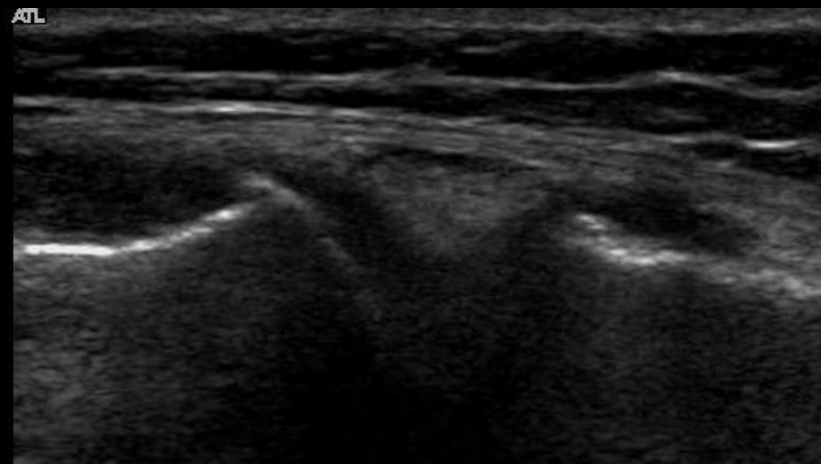
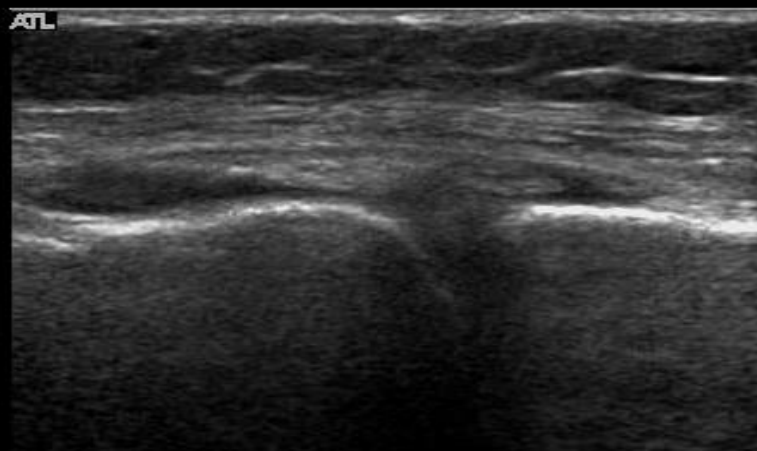
Supra-patella pouch – PD - Grade 3



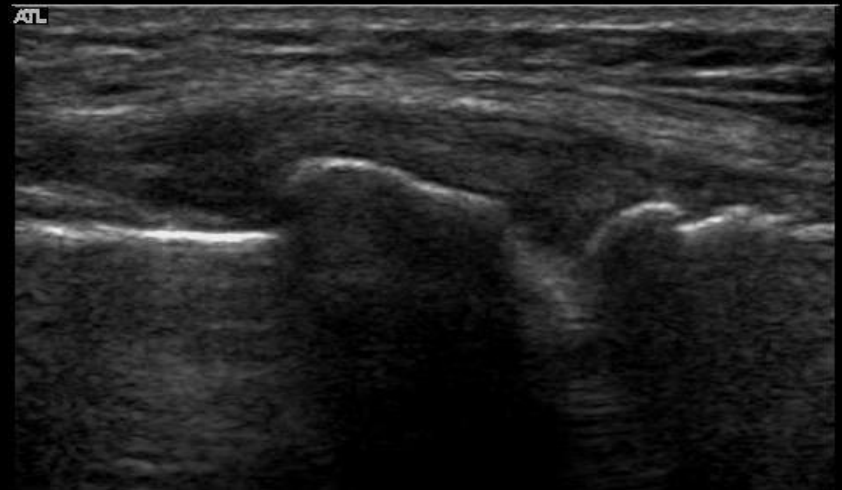
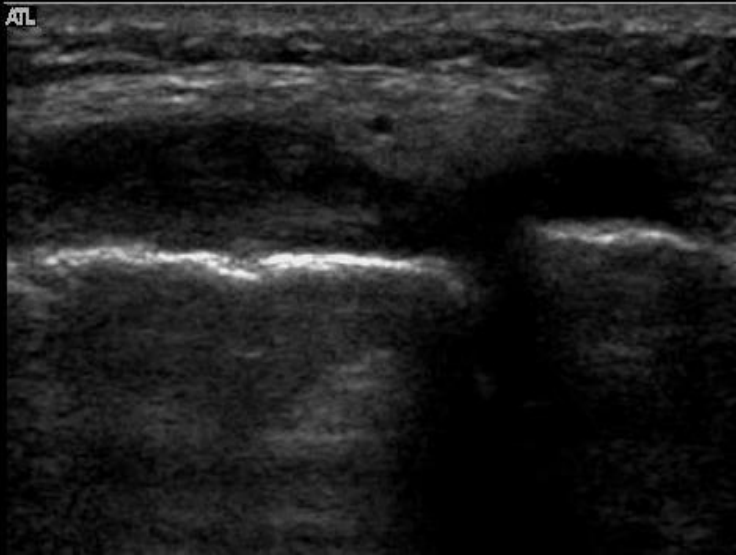
Medial joint space



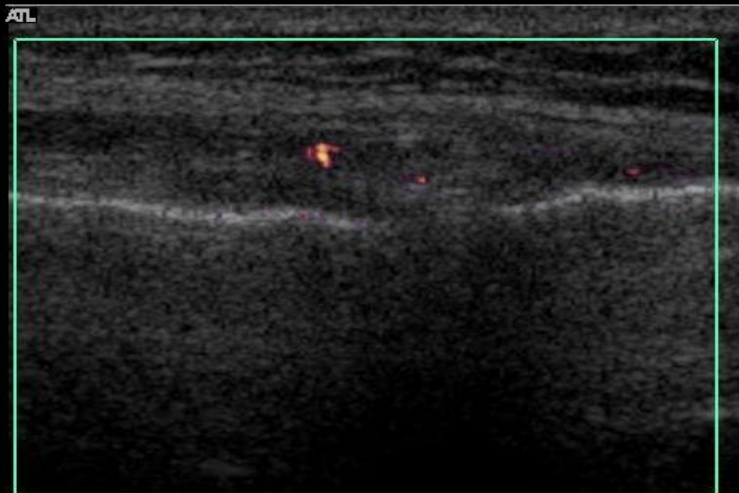
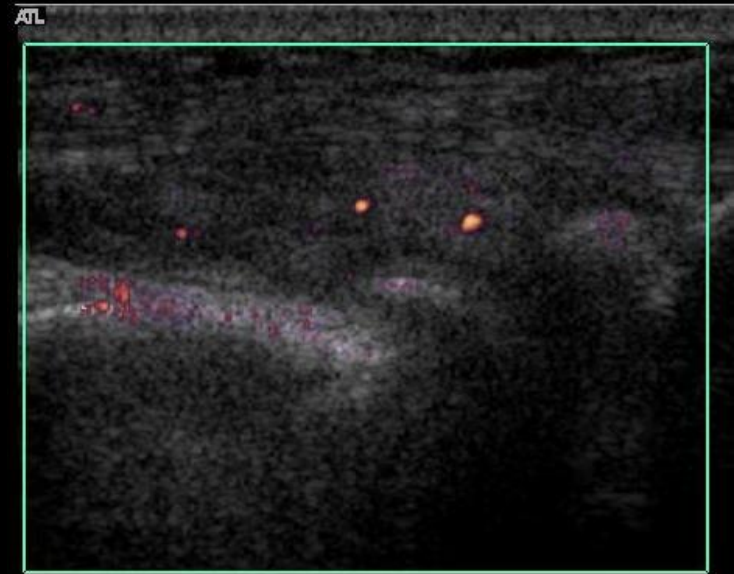
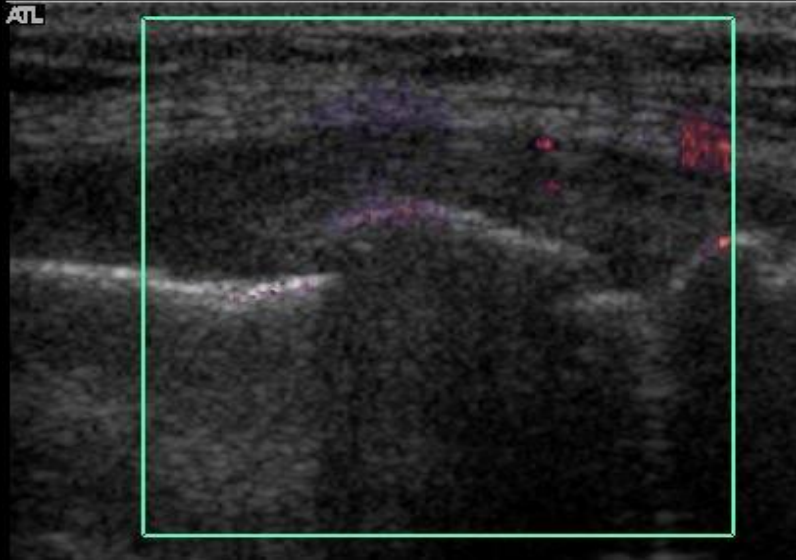
Medial joint space: GS: Grade 2



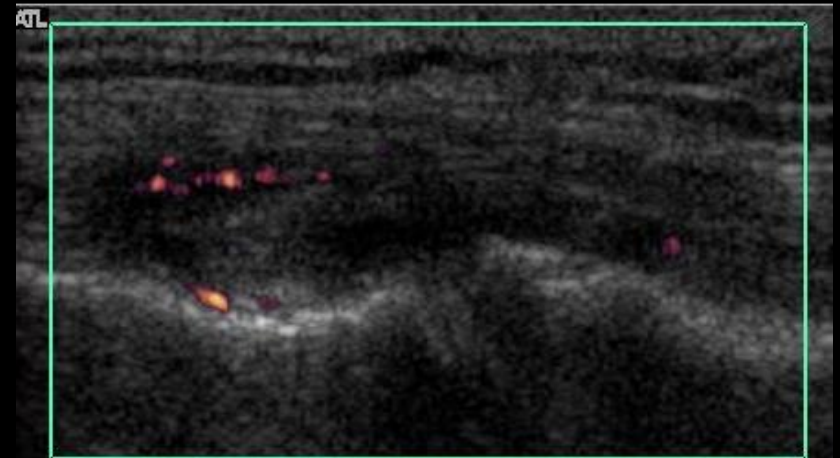
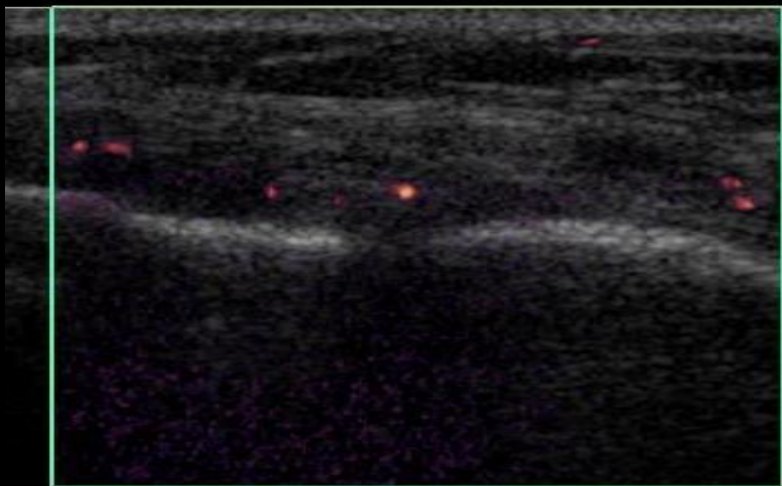
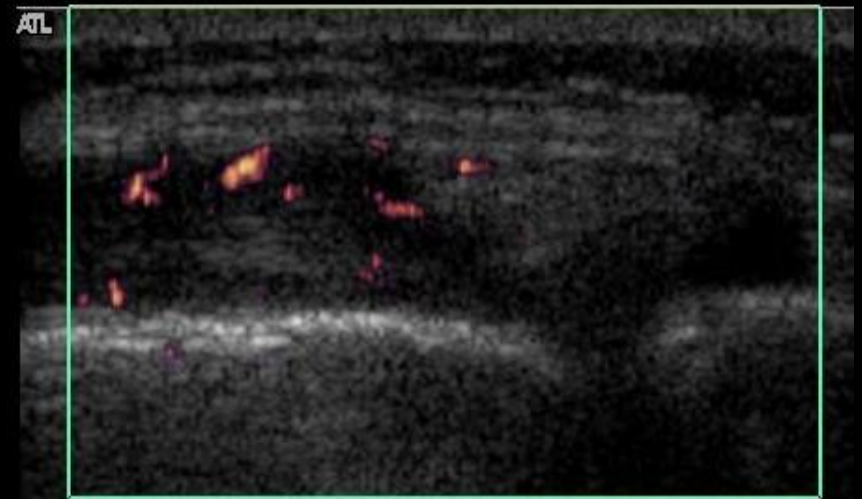
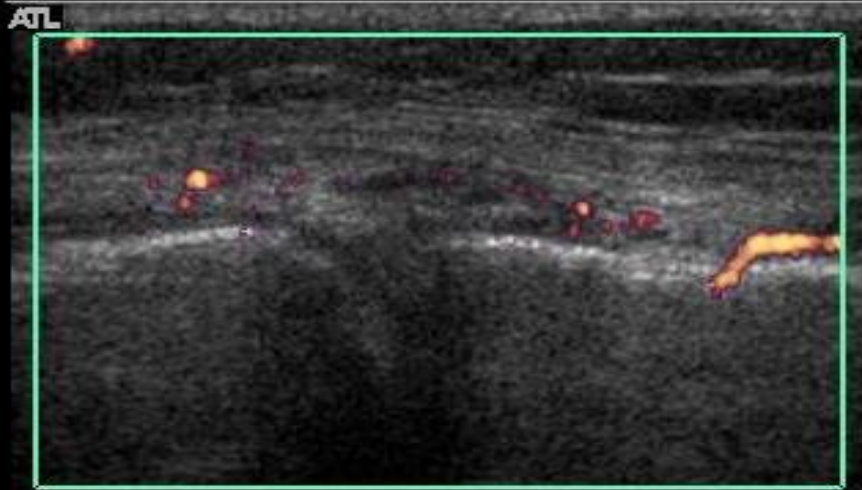
Medial joint space: GS: Grade 3



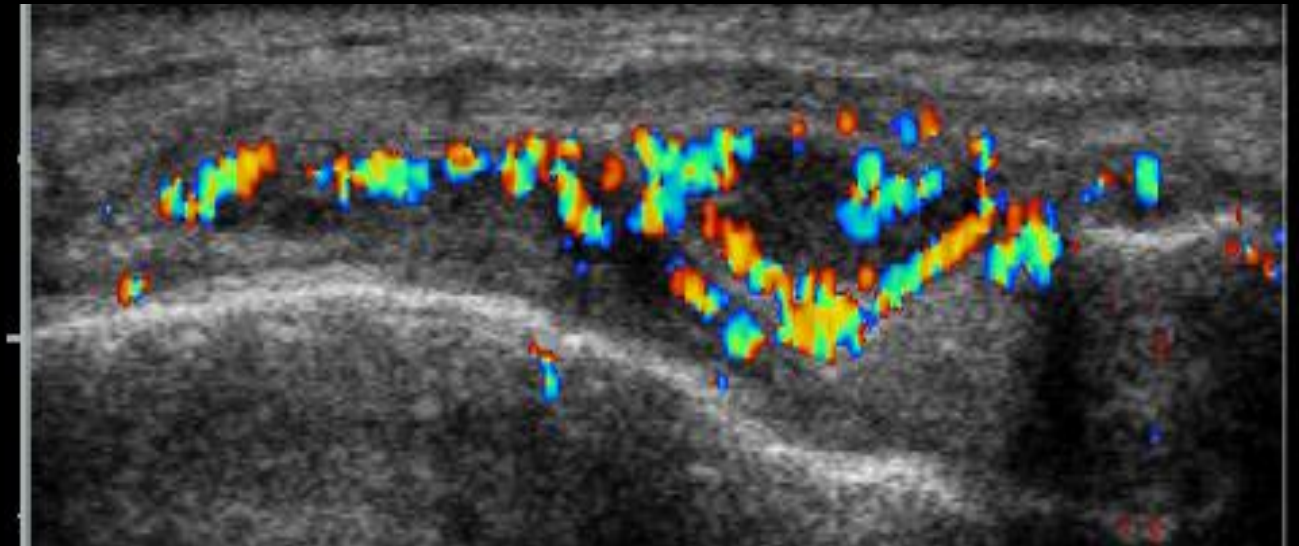
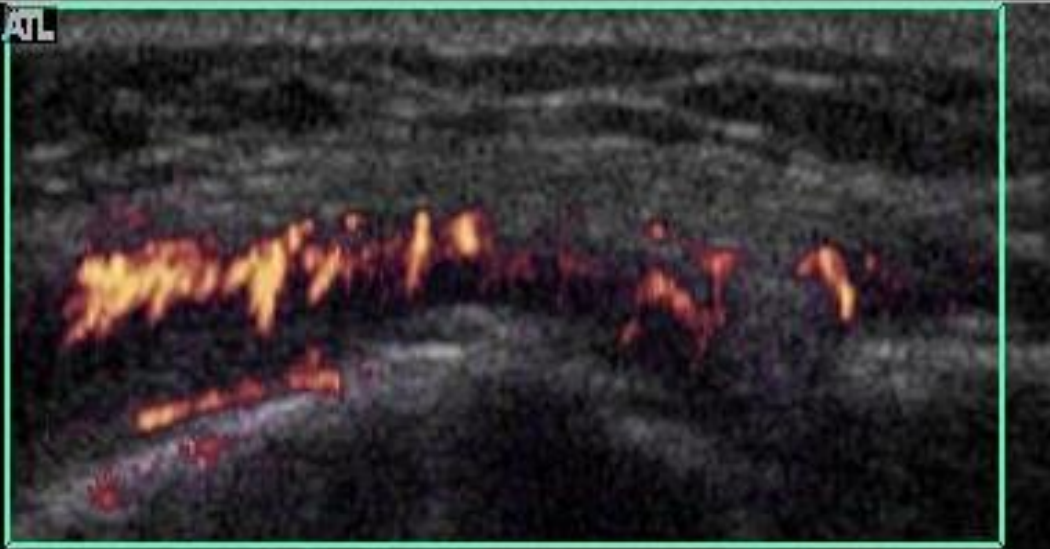
Medial joint space: PD: Grade 1



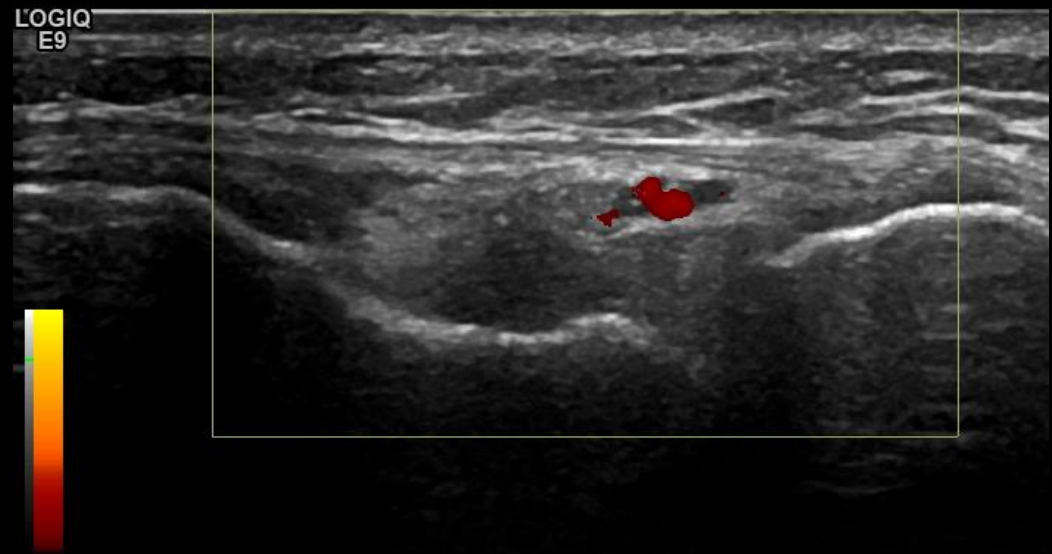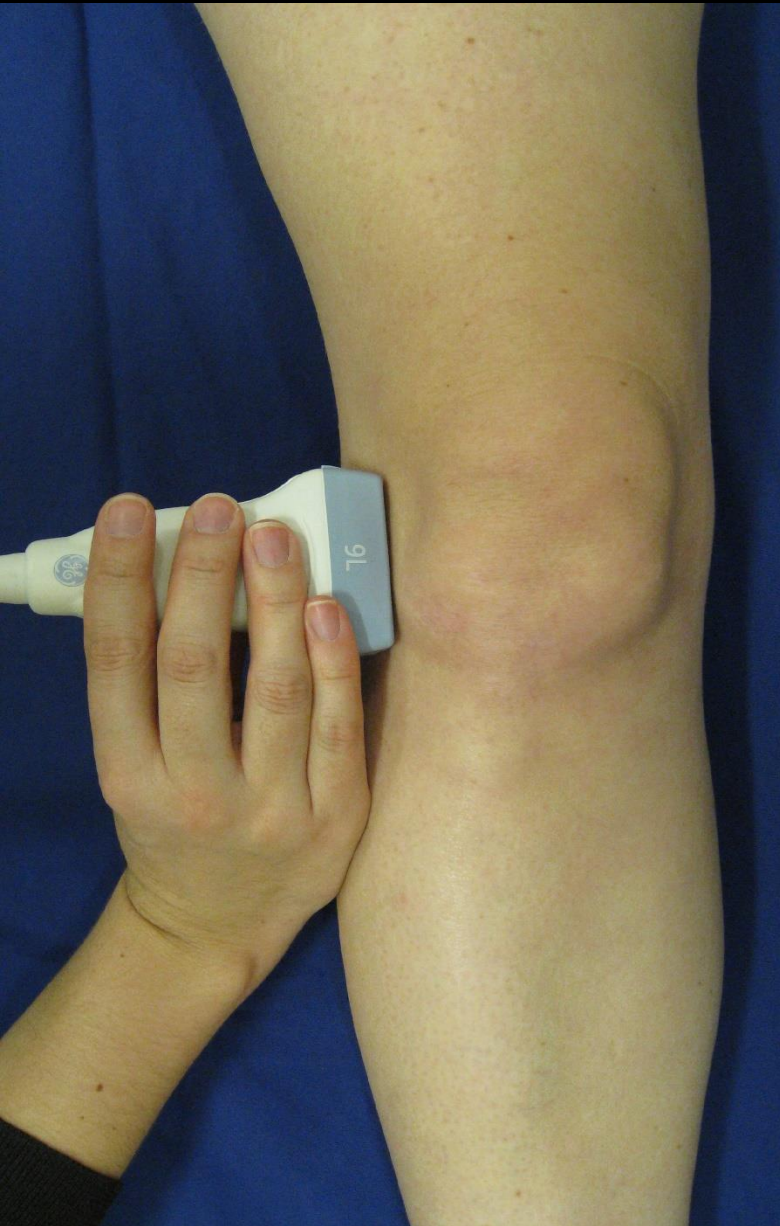Medial joint space: PD: Grade 2



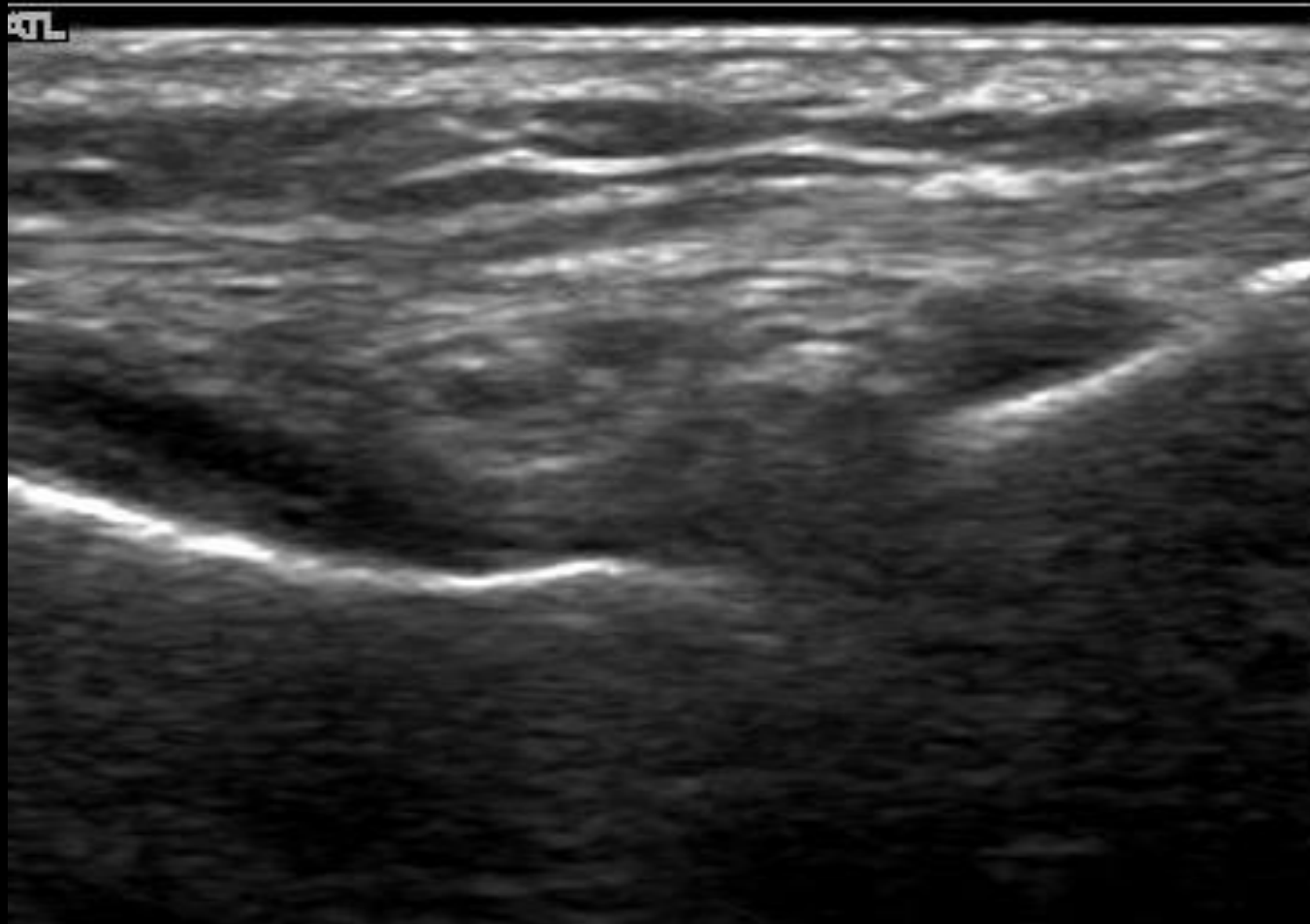
Medial joint space: PD: Grade 3



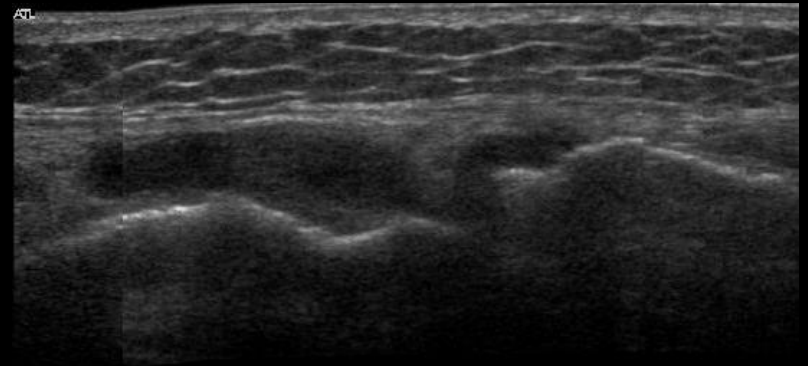
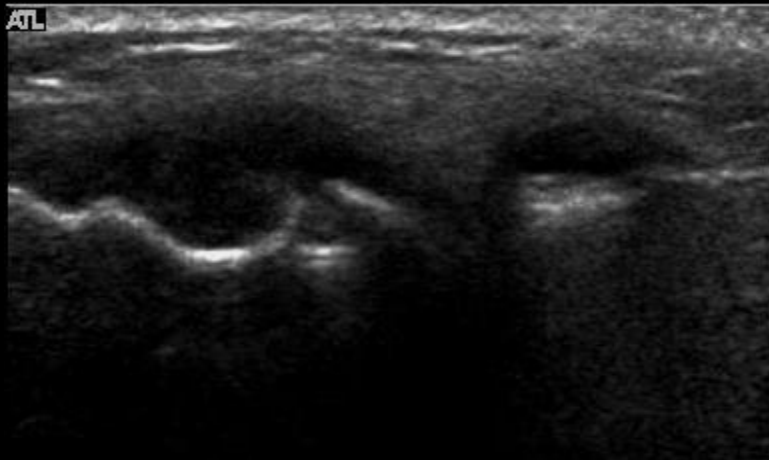
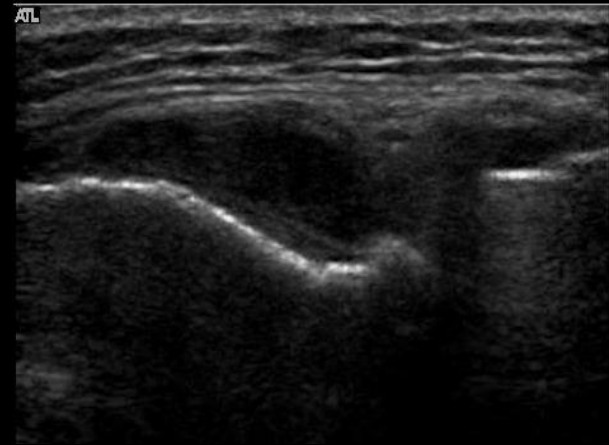
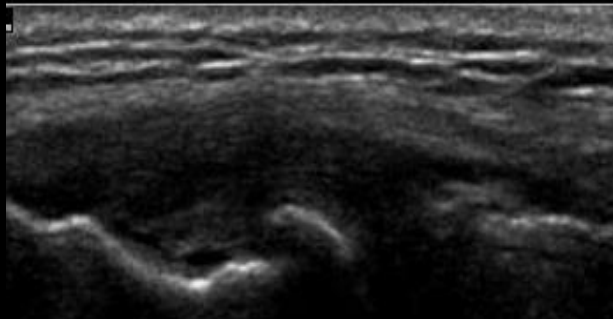
Lateral joint space



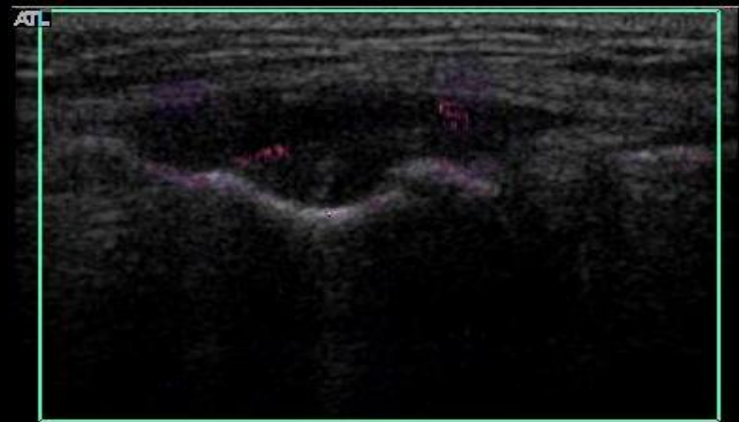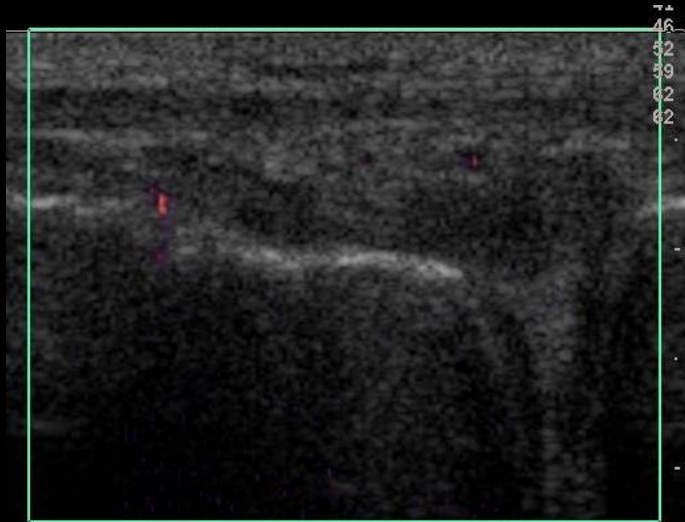
Lateral Joint Space – GS- Grade 2



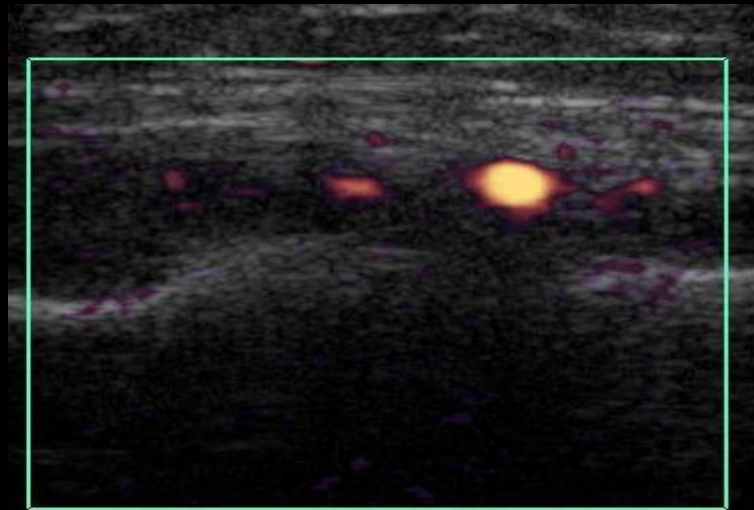
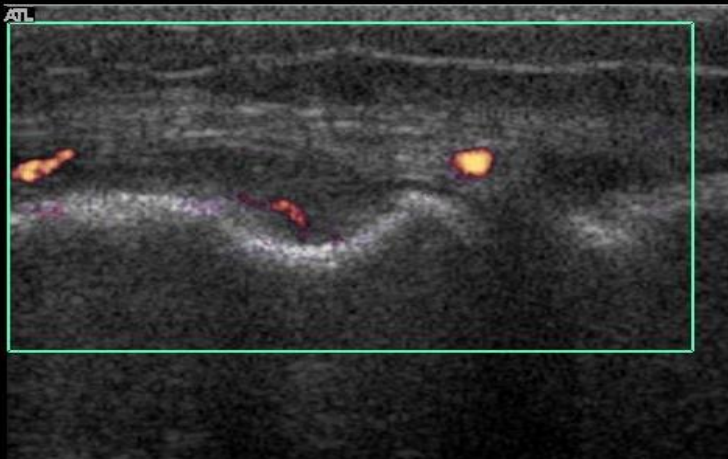
Lateral Joint Space – GS- Grade 3



Lateral Joint Space – PD- Grade 1

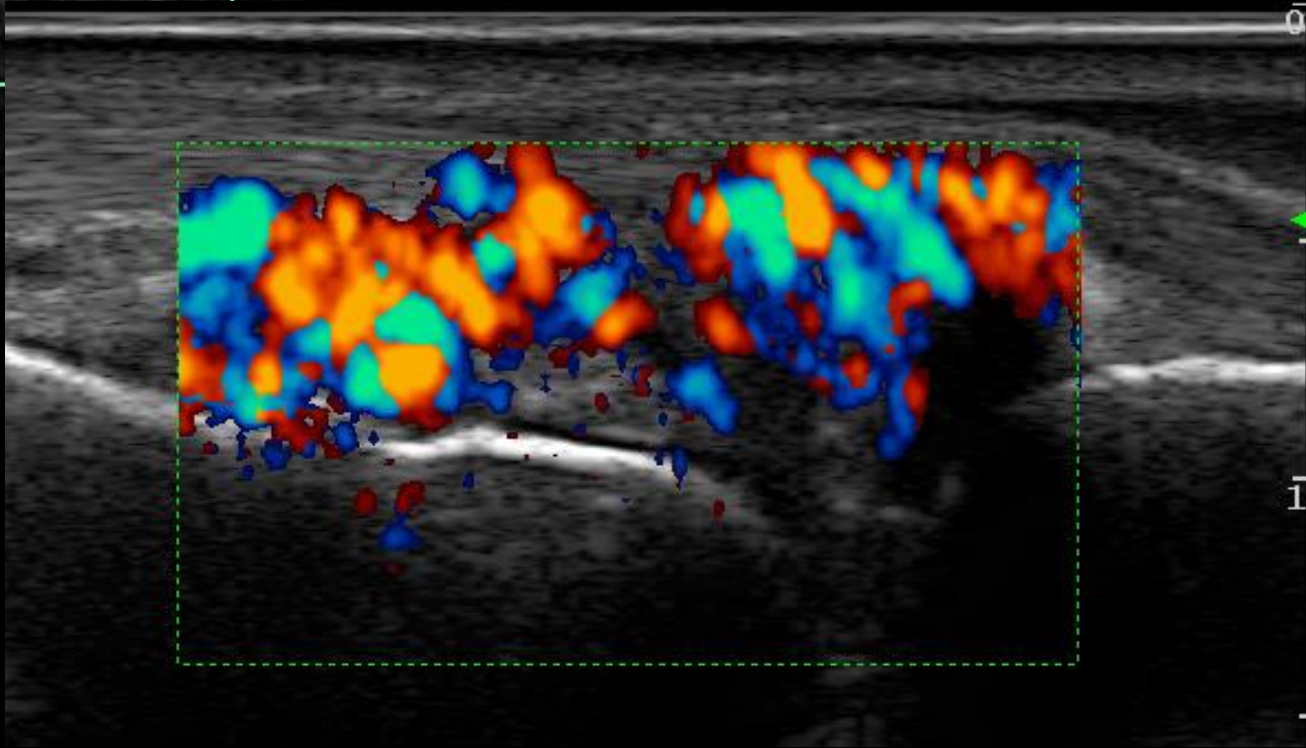
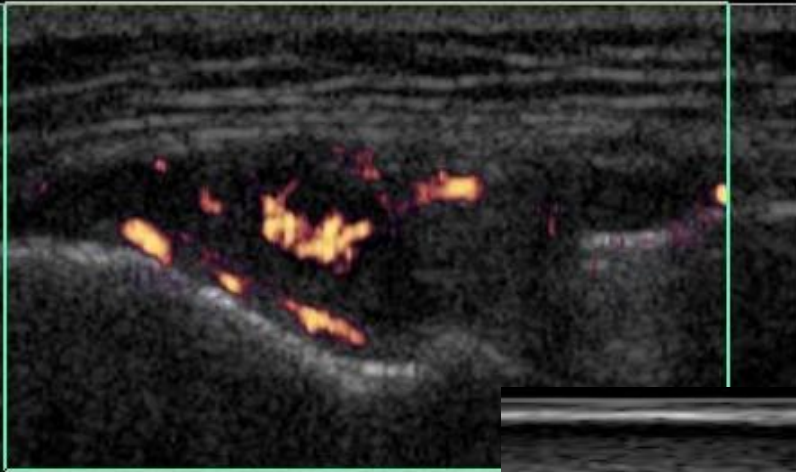


Lateral Joint Space - PD- Grade 2

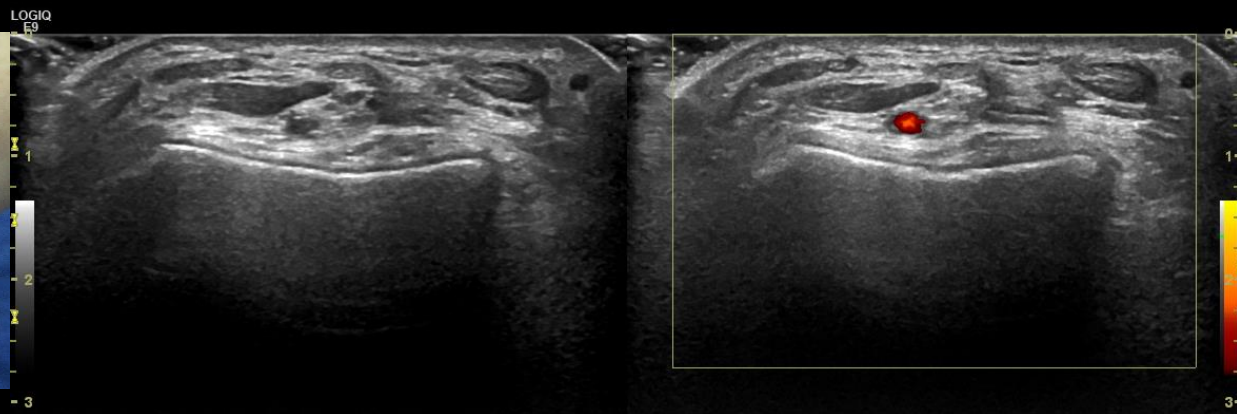
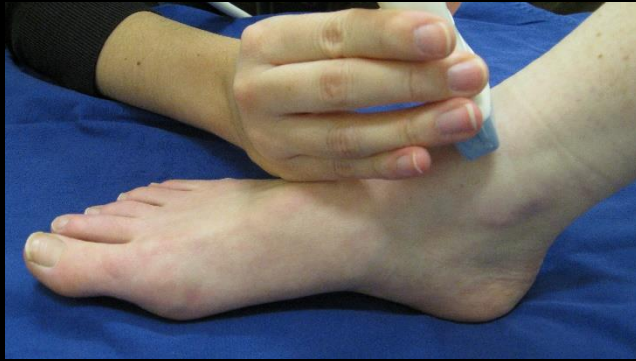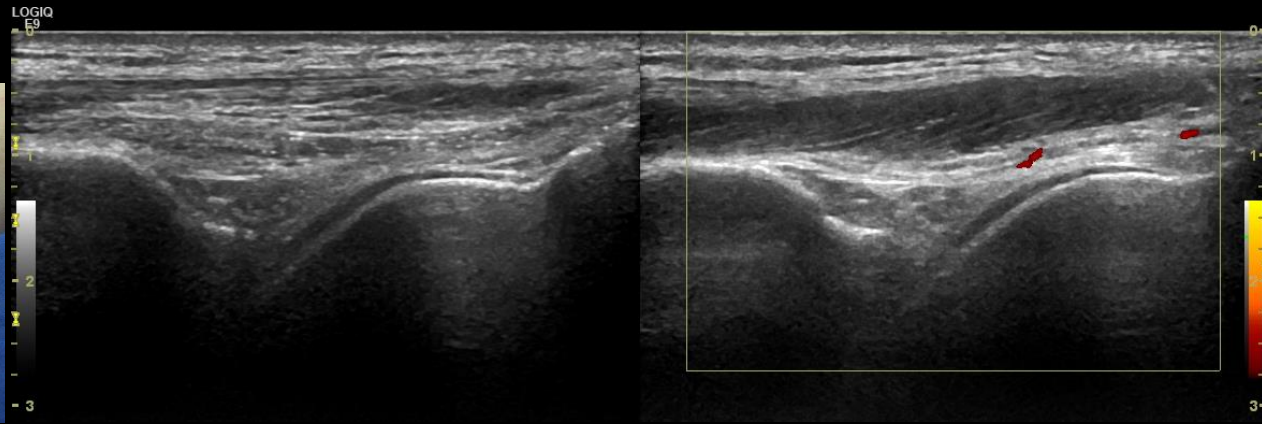

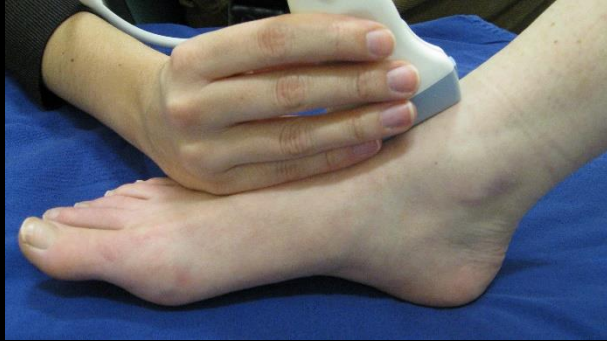
Lateral Joint Space – PD- Grade 3

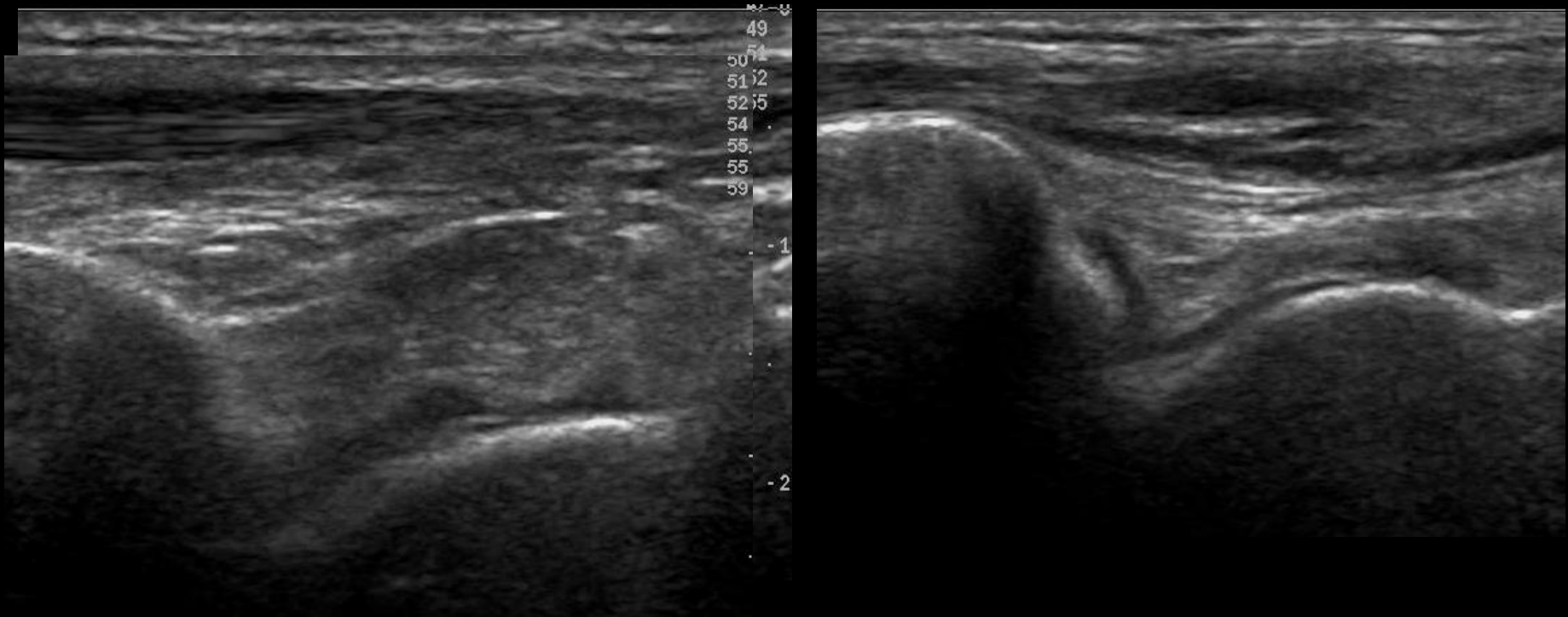
ATL



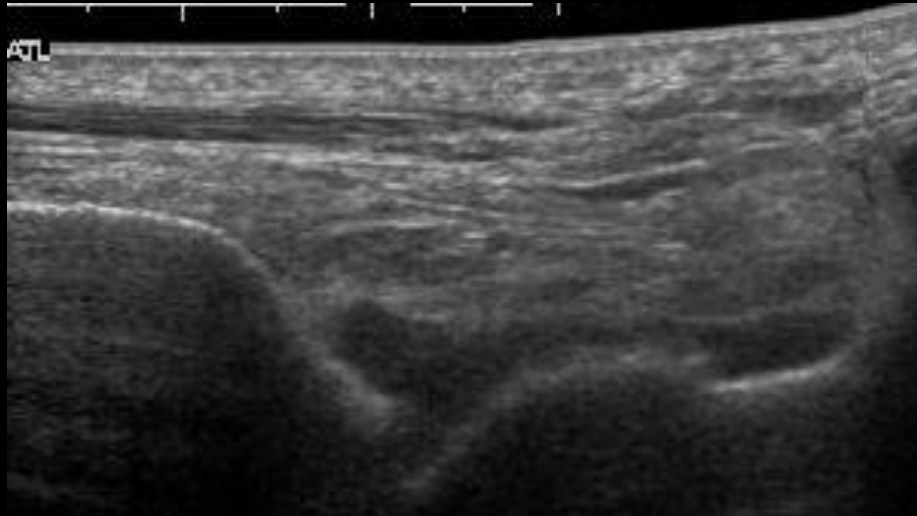
Anterior tibio-talar joint



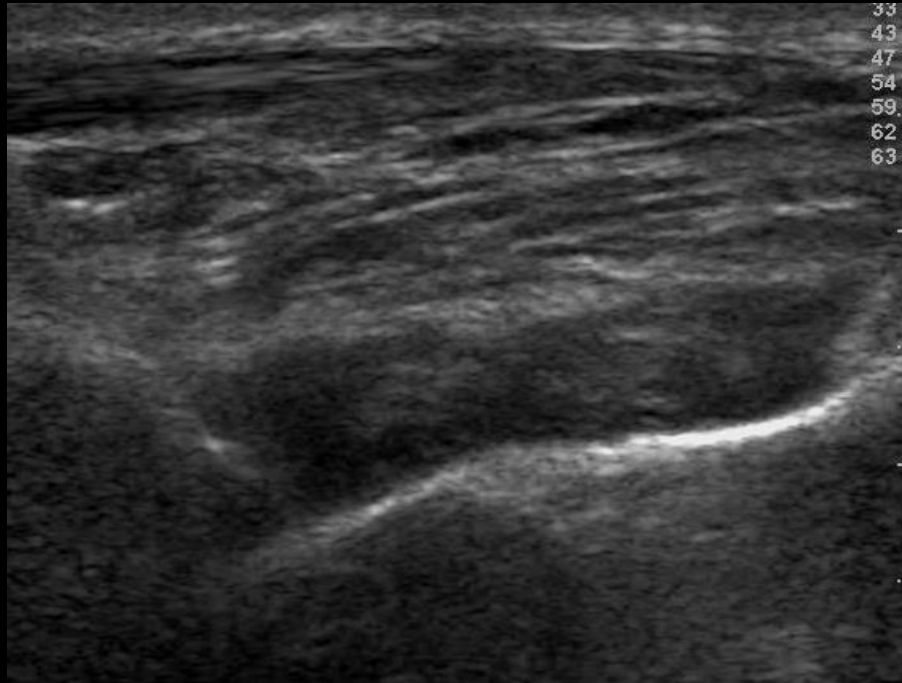
Anterior tibio-talar joint – GS- Grade 1



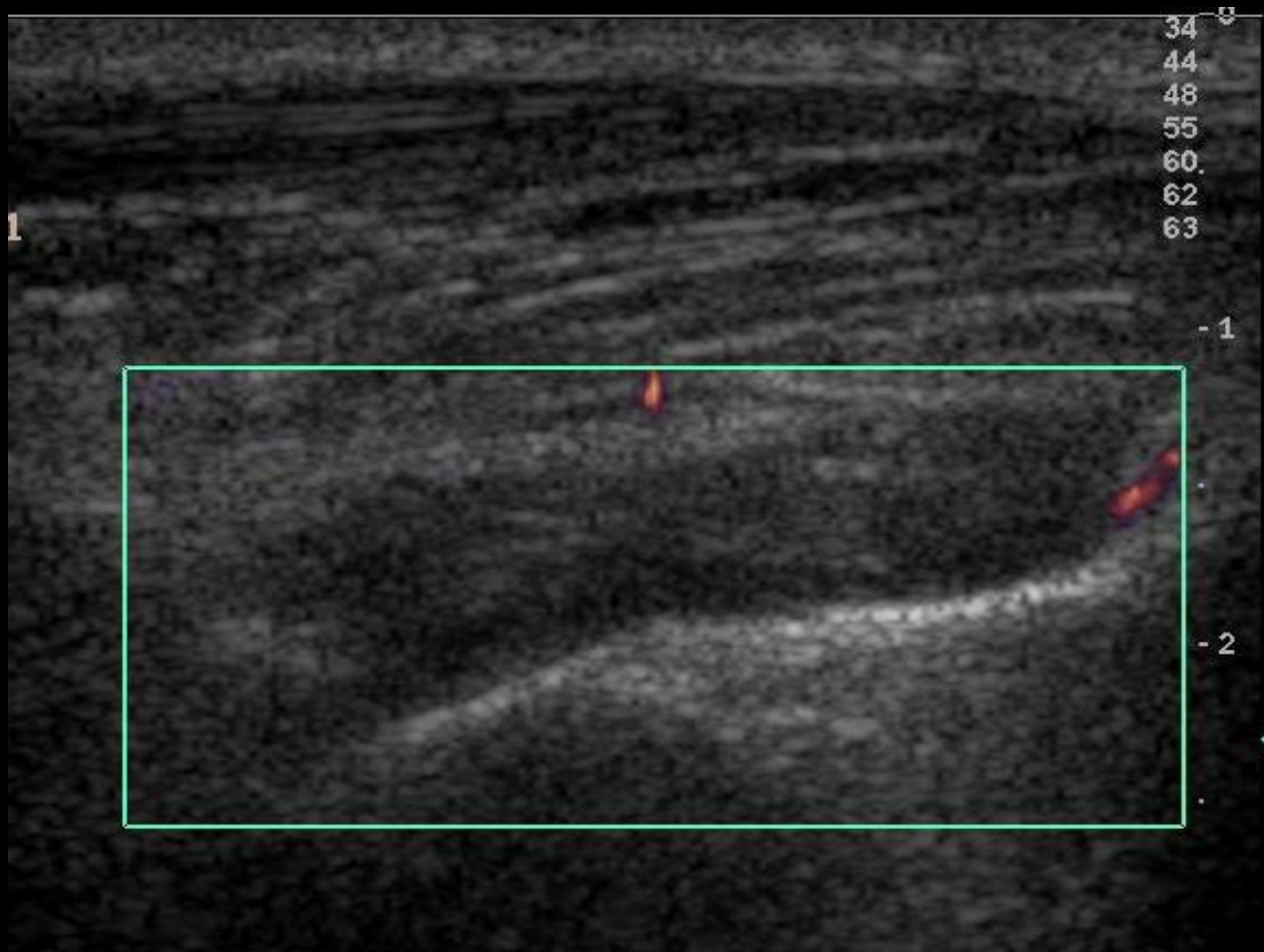
Anterior tibio-talar joint – GS- Grade 2



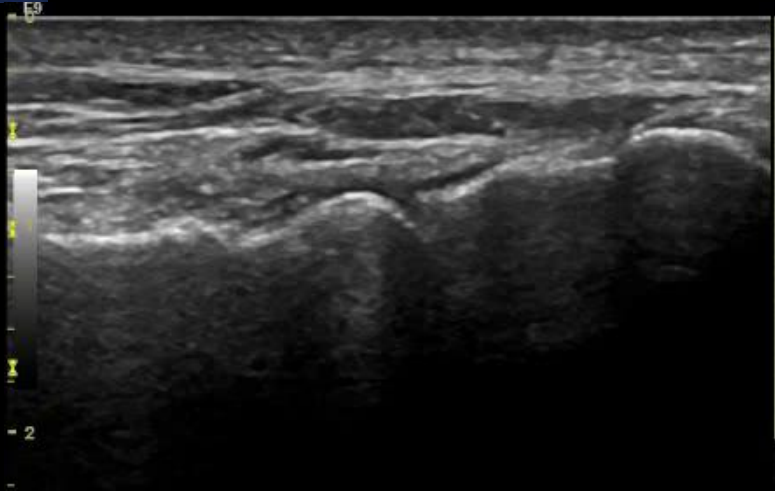
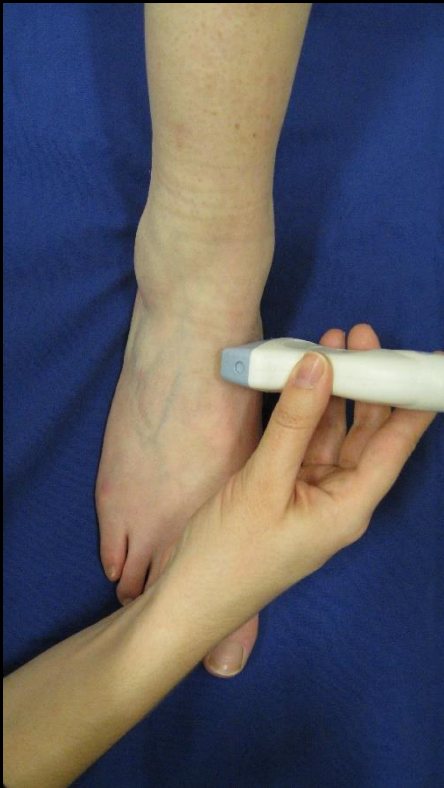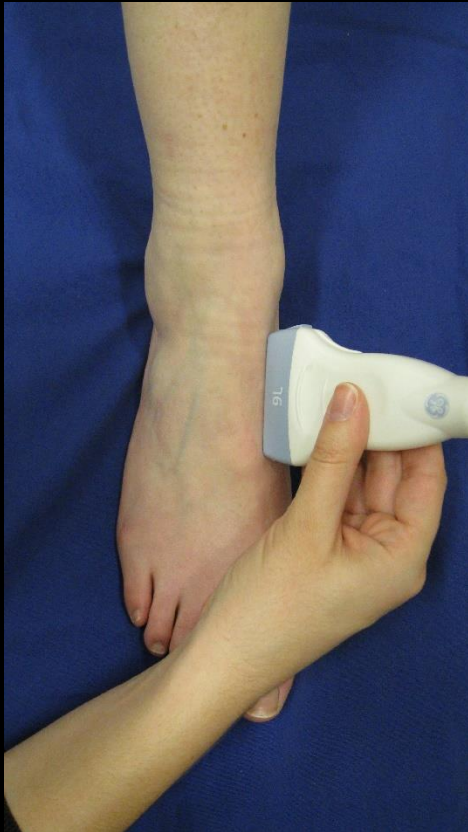Anterior tibio-talar joint - GS - Grade 3



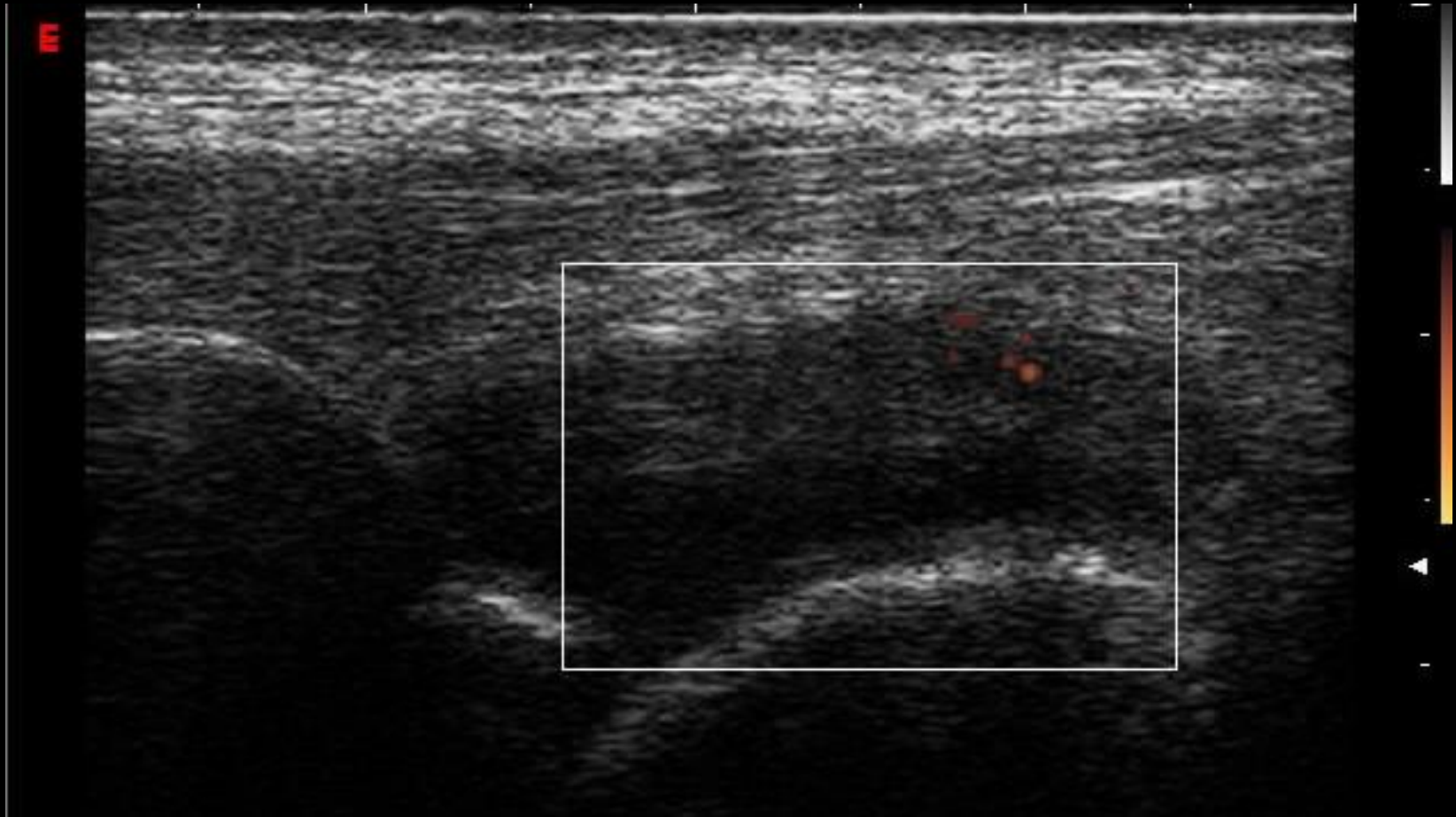
Anterior tibio-talar joint – PD - Grade 1



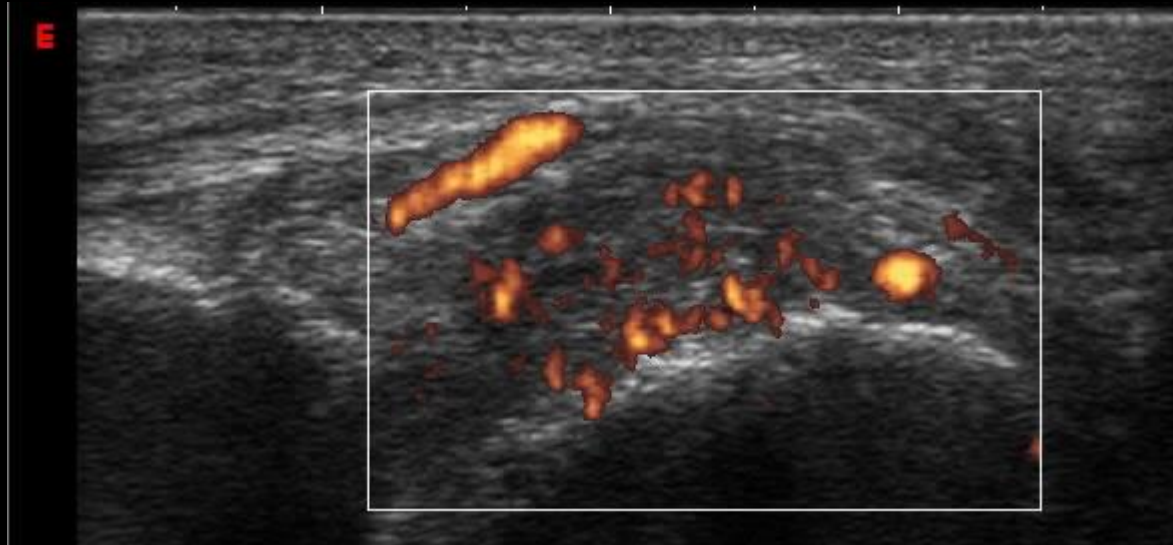
Talo-navicular joint - Normal



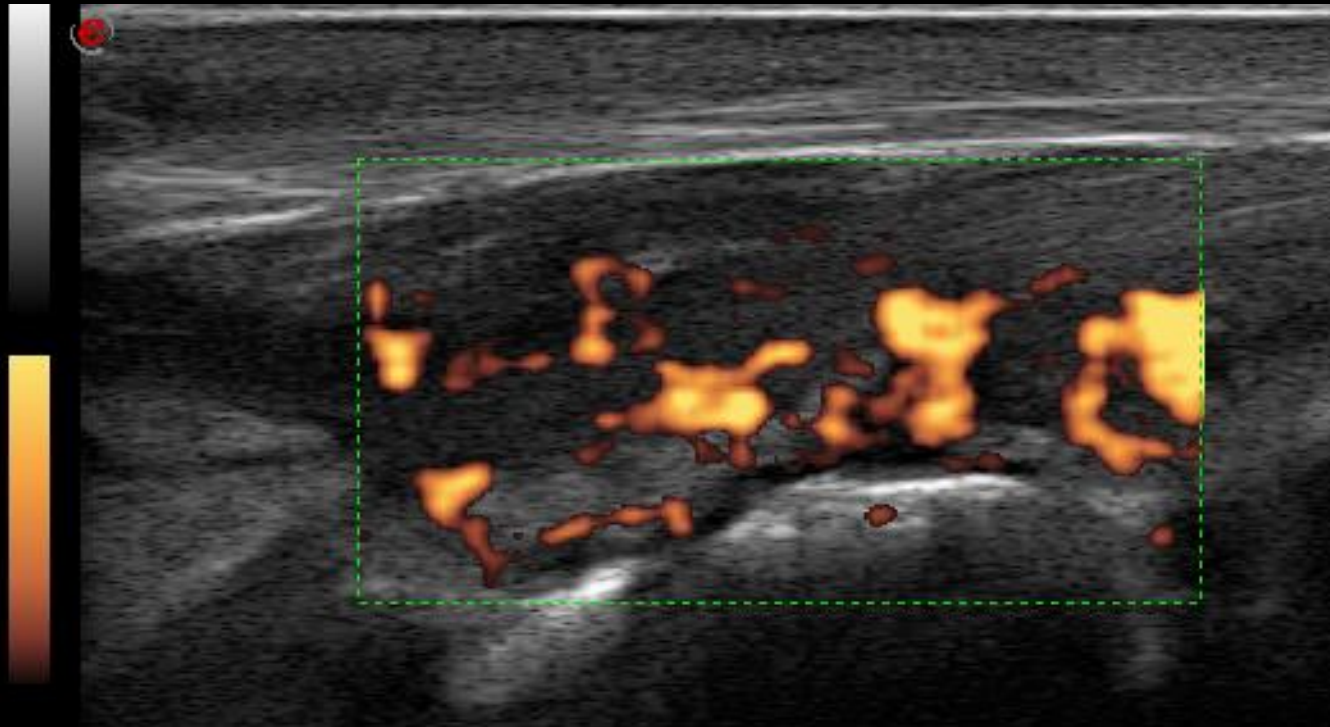
Talo-navicular joint – PD- Grade 1



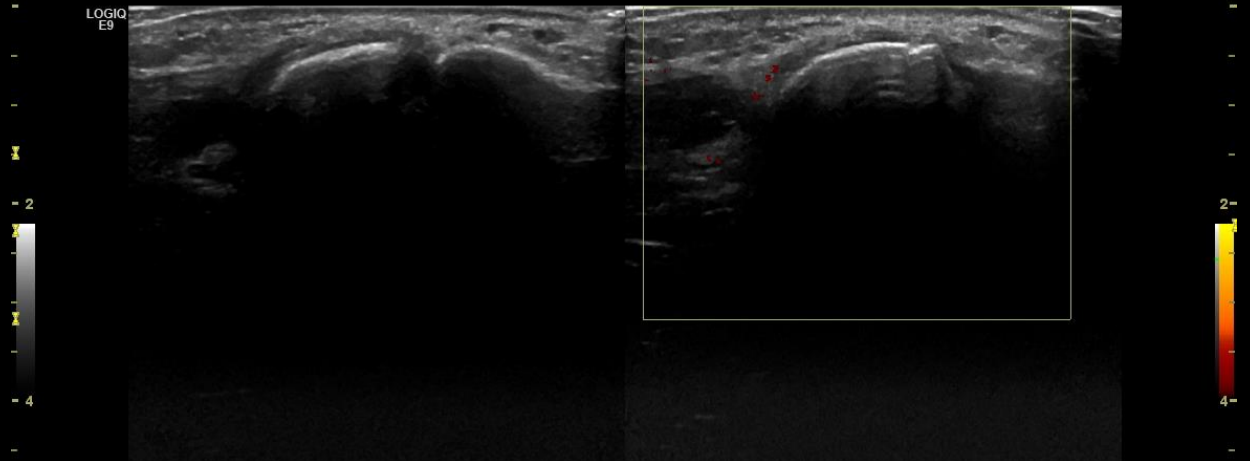
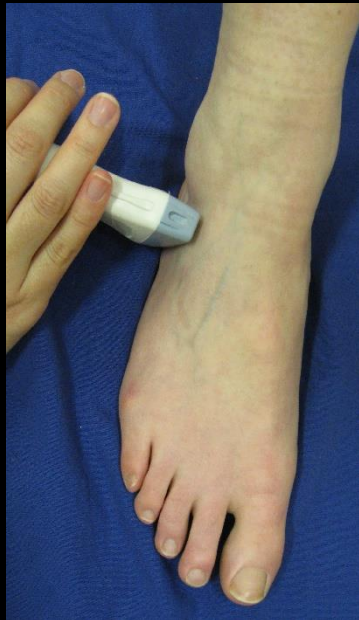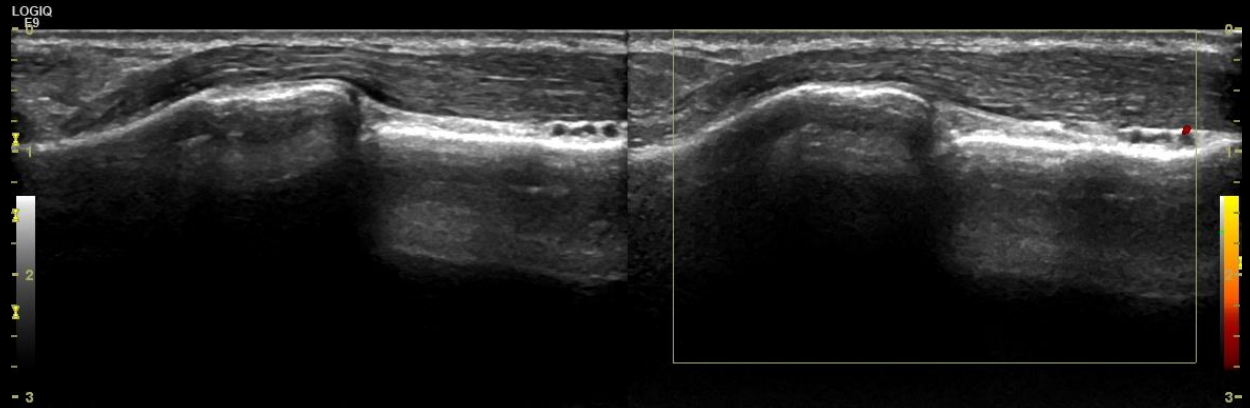
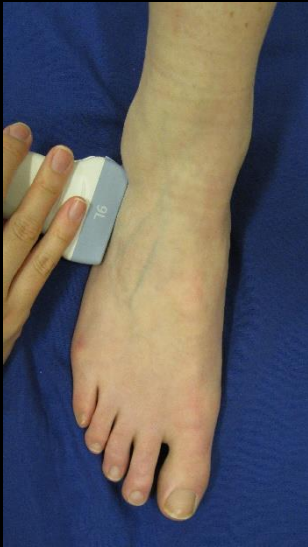Talo-navicular joint – PD- Grade 2



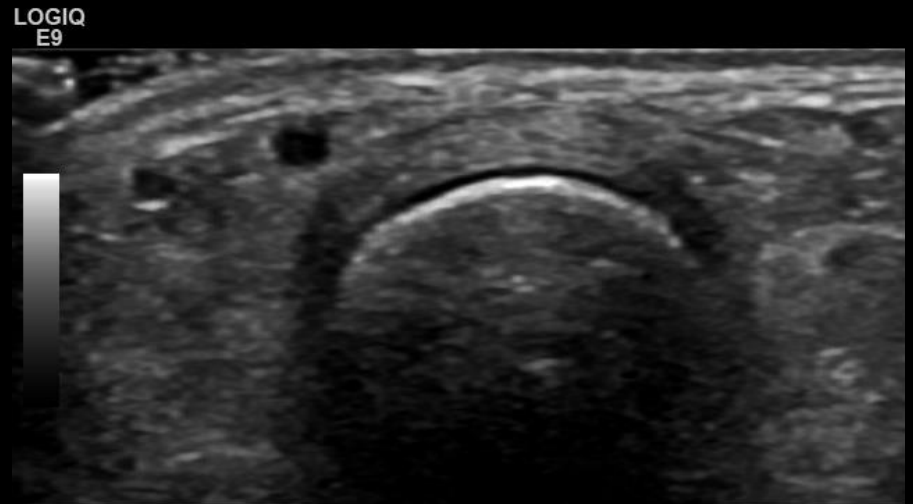
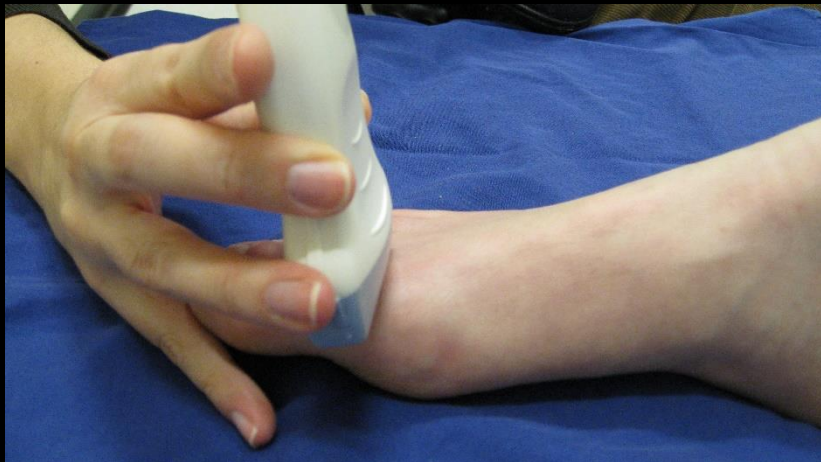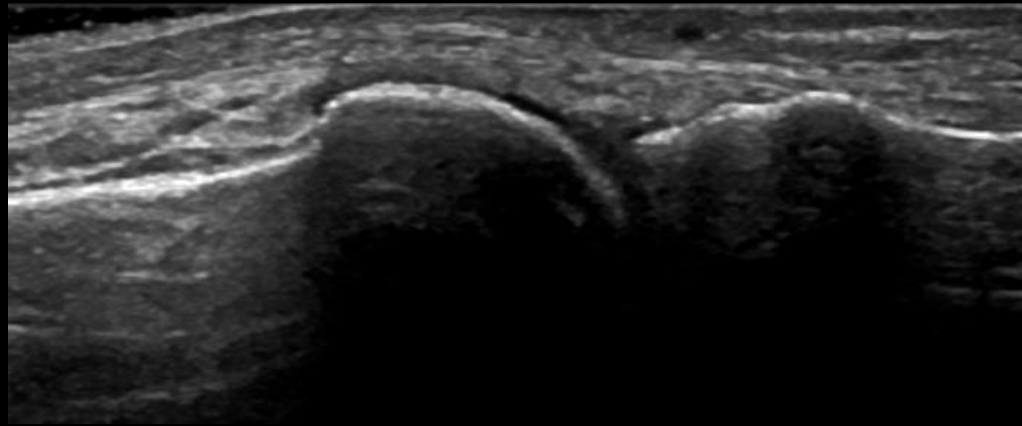
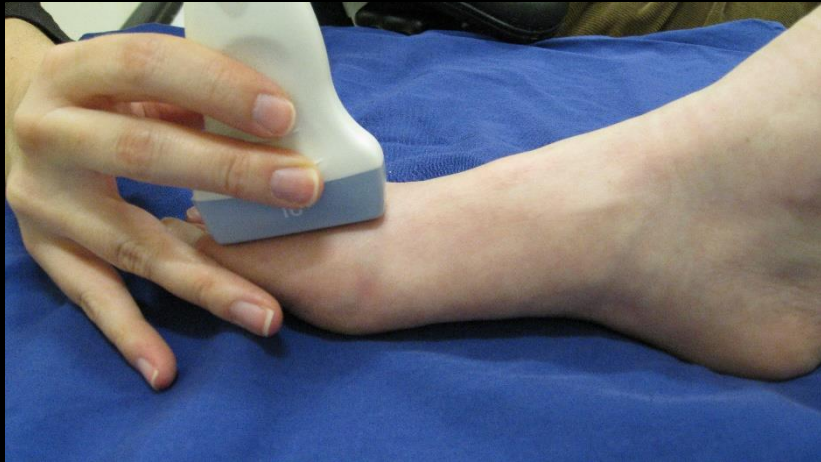Talo-navicular joint – PD- Grade 3



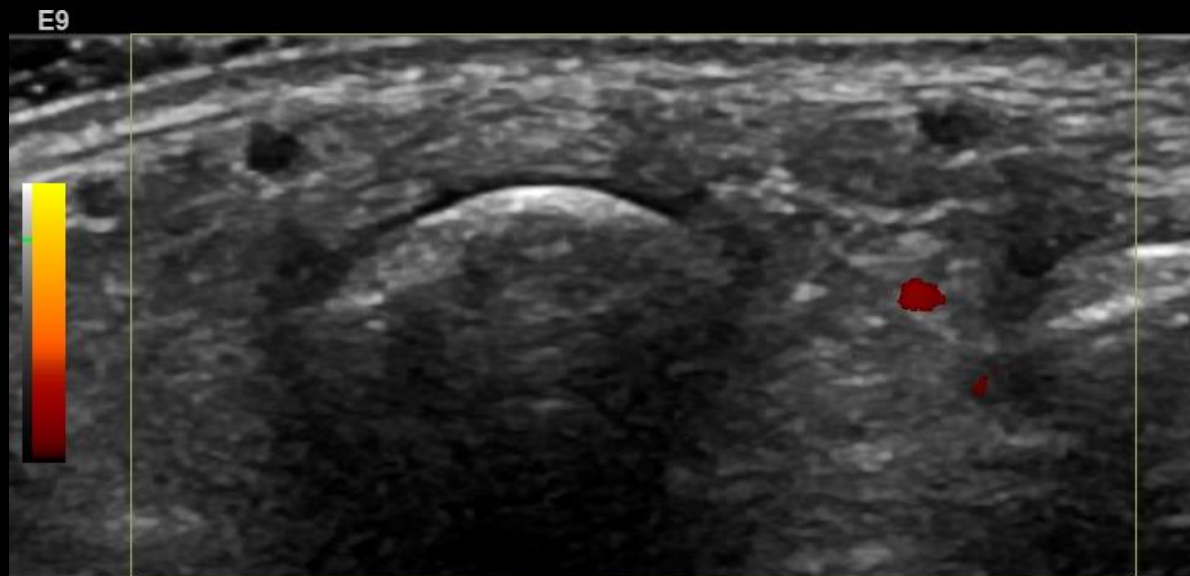
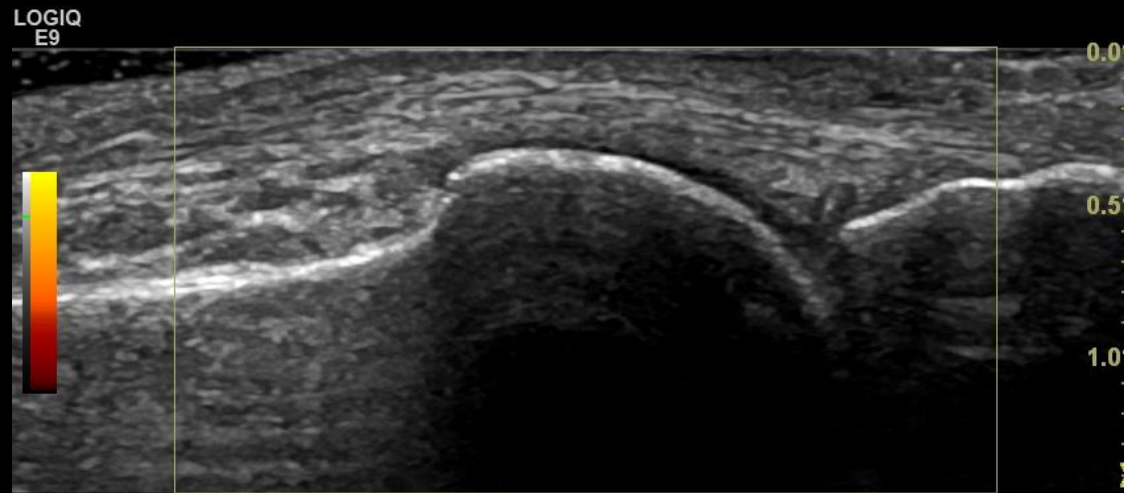
Calcaneo-cuboidal bone - normal



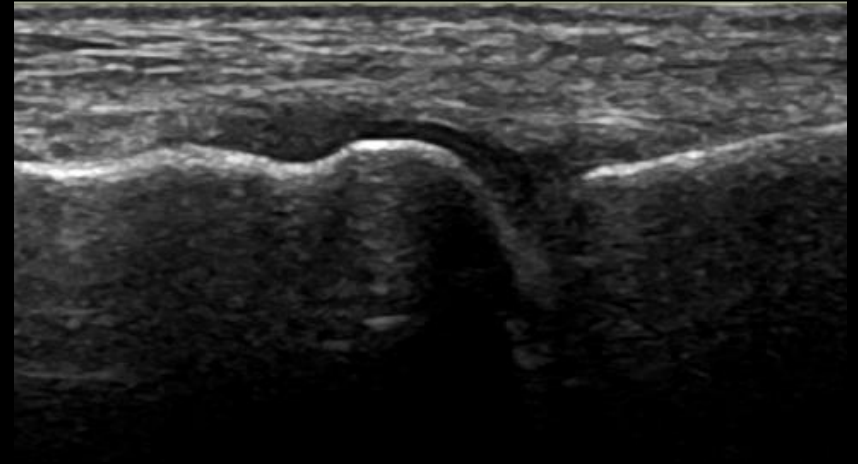
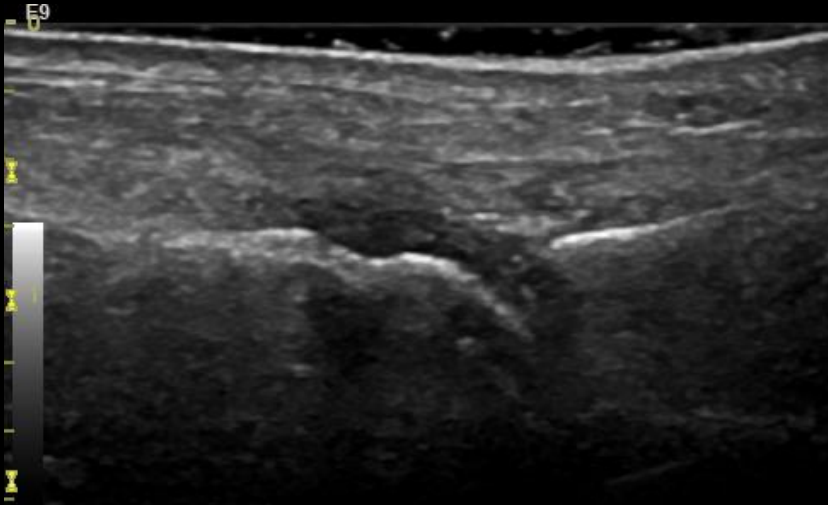
MTPJ –Dorsal – GS - Normal



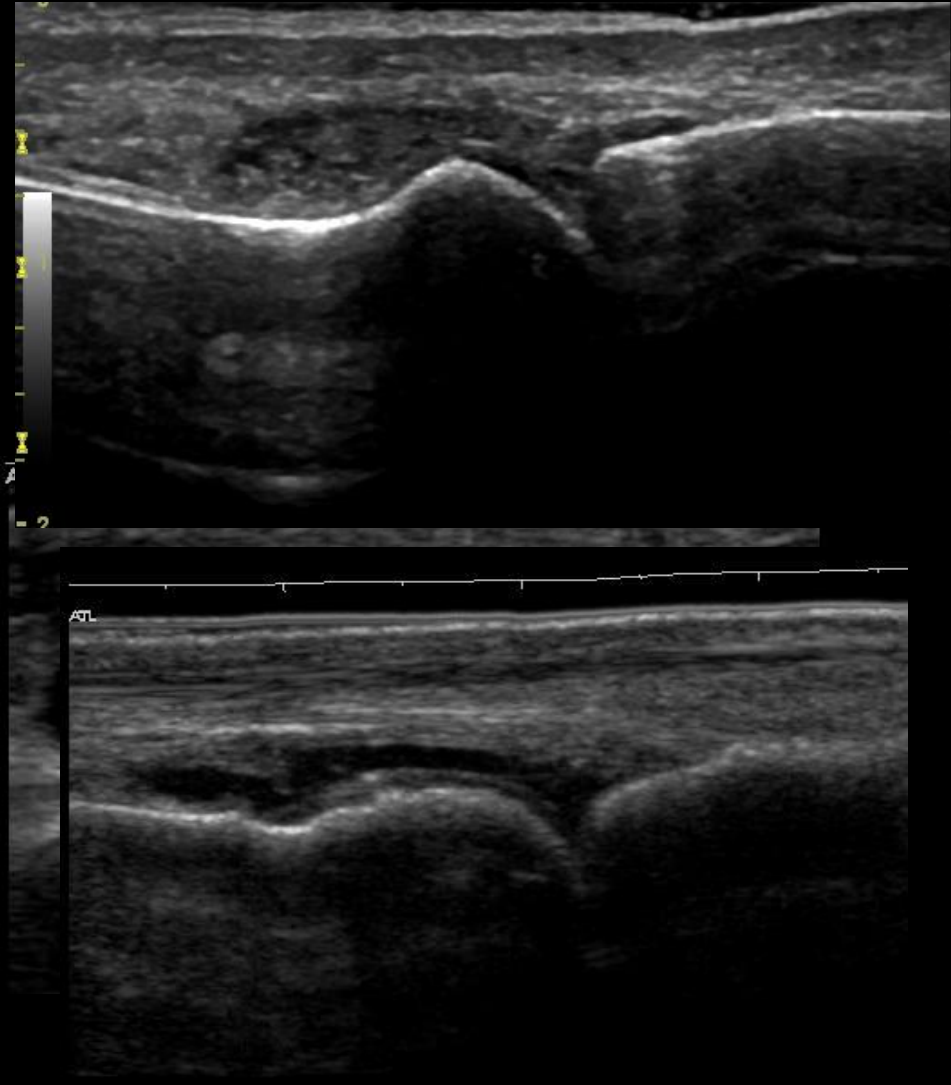
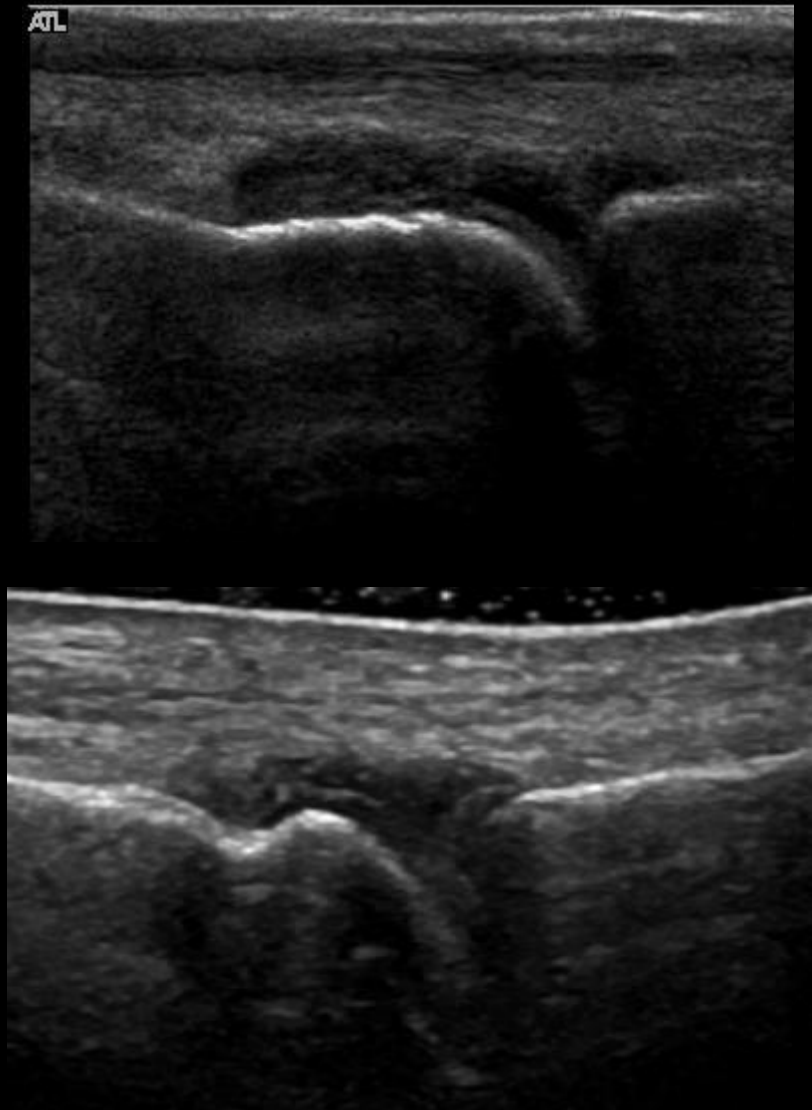
MTPJ - Dorsal - PD - Normal



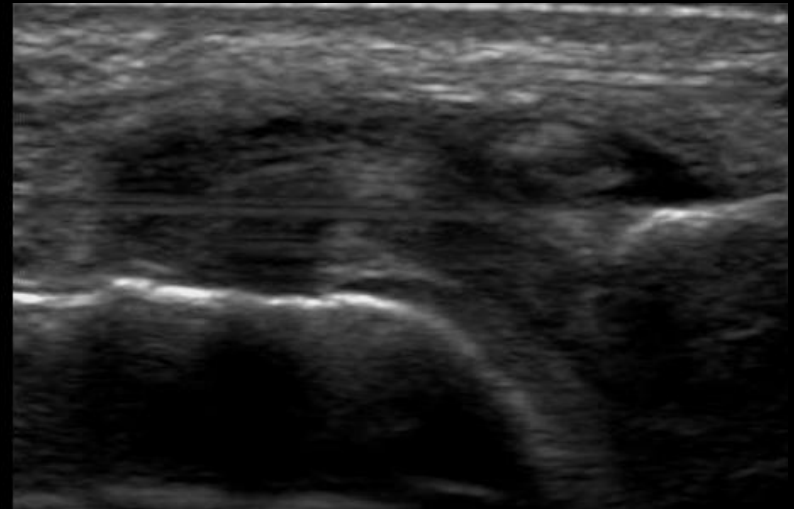
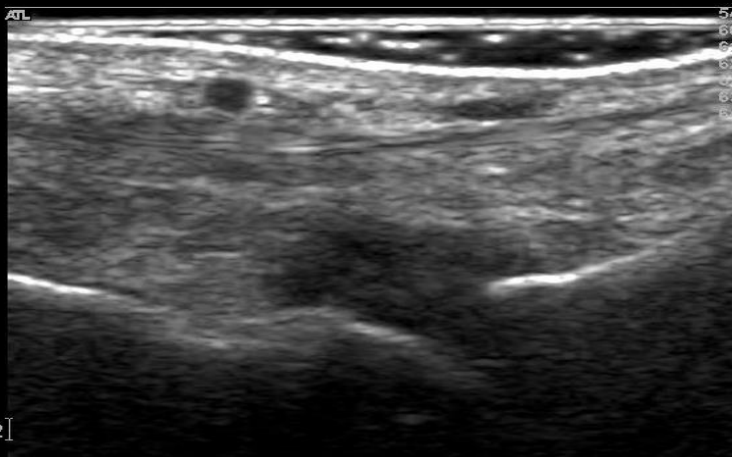
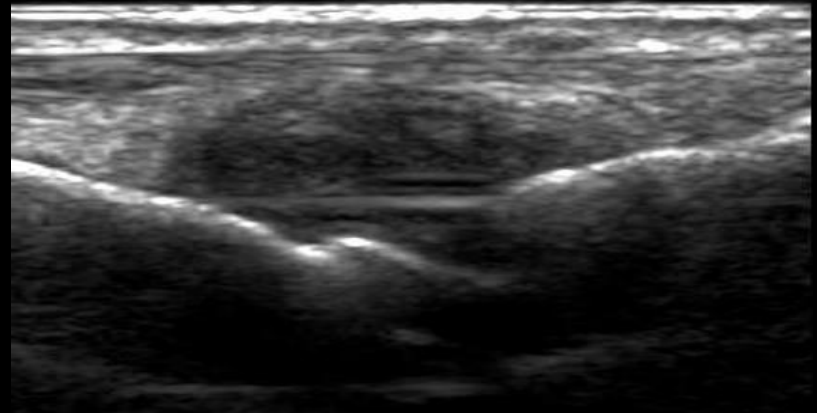
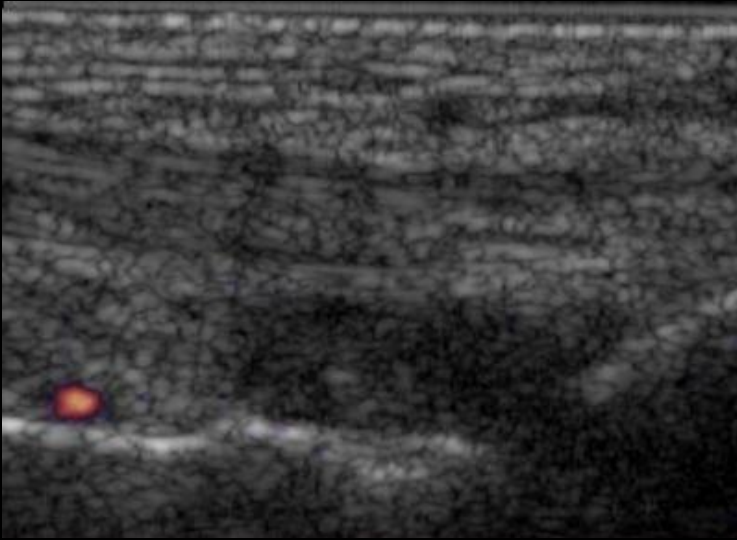
MTPJ - Dorsal - GS – Grade 1



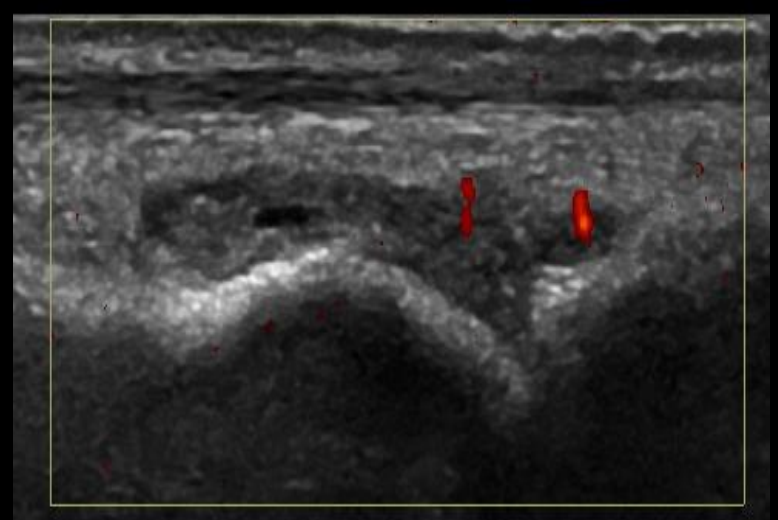
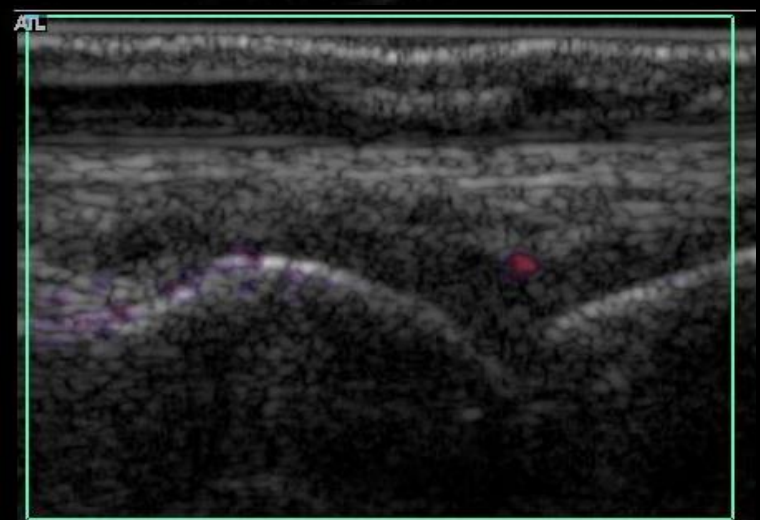
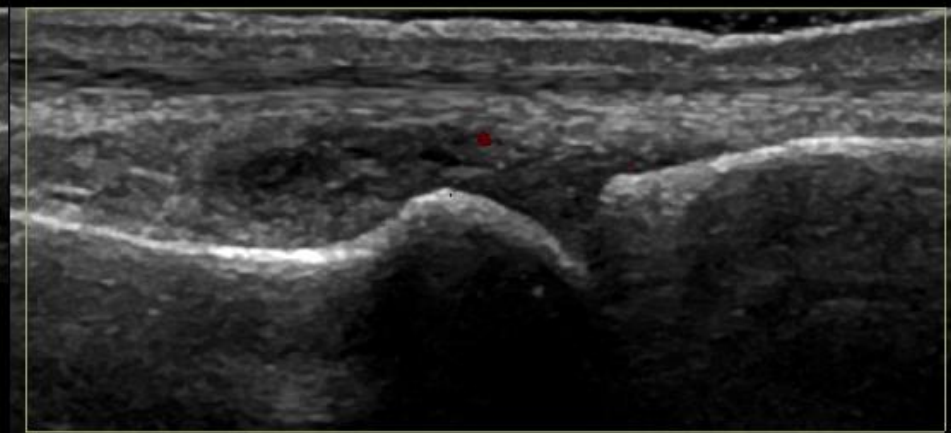
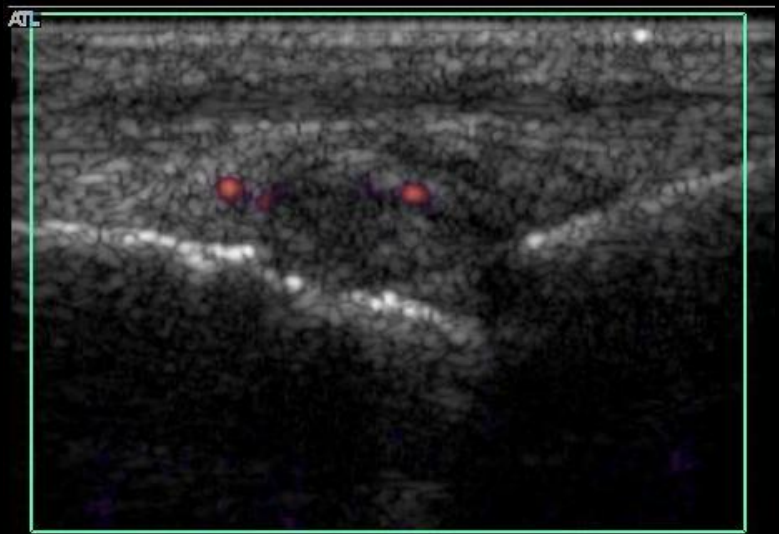
MTPJ - Dorsal – GS – Grade 2



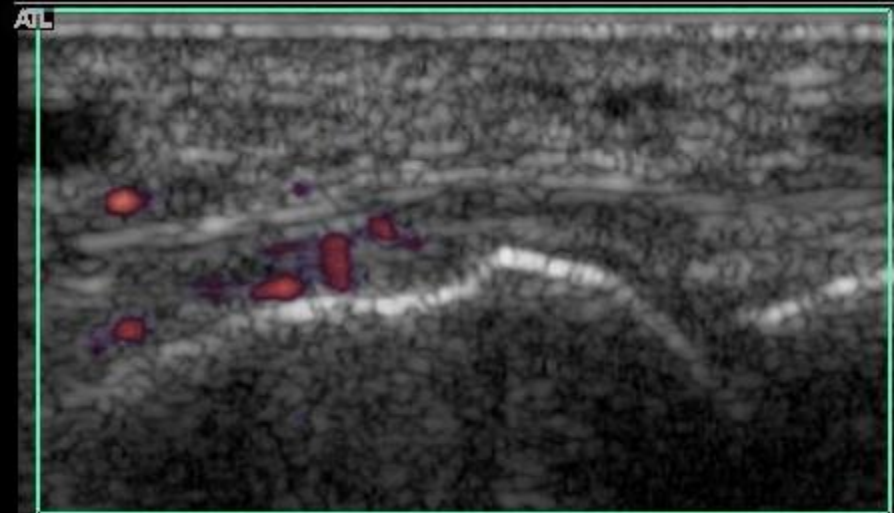
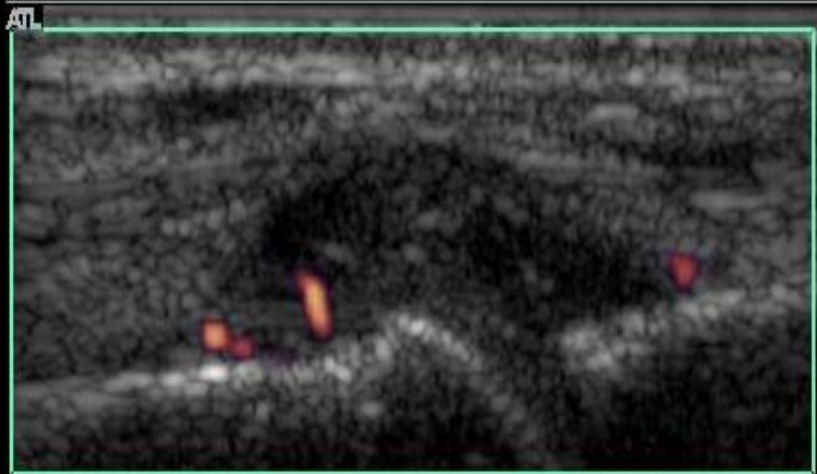
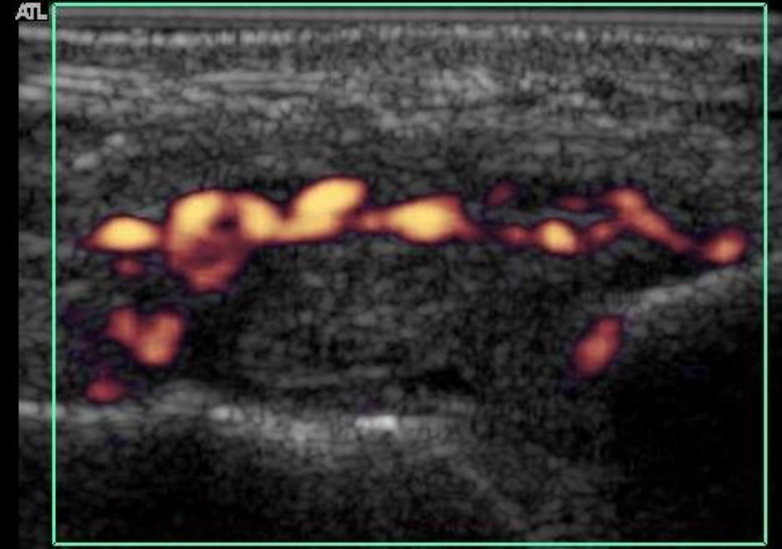
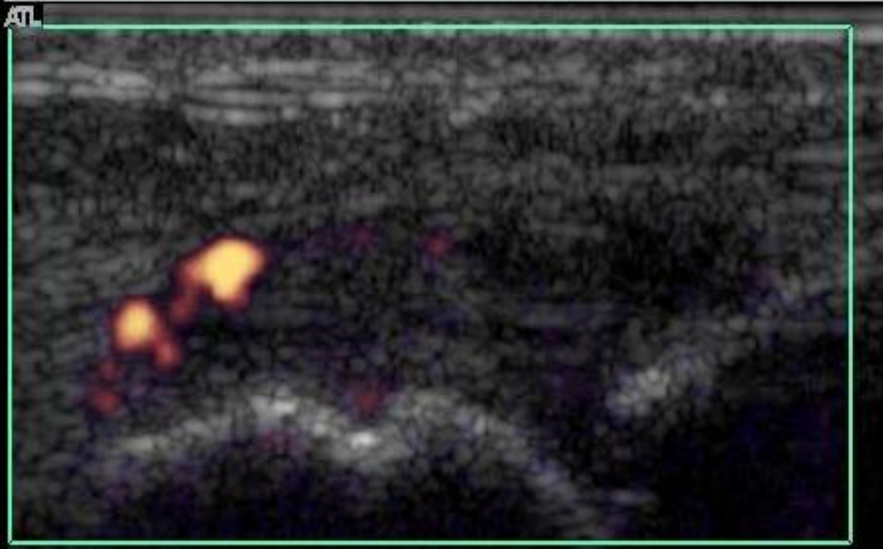
MTPJ - Dorsal – GS- Grade 3



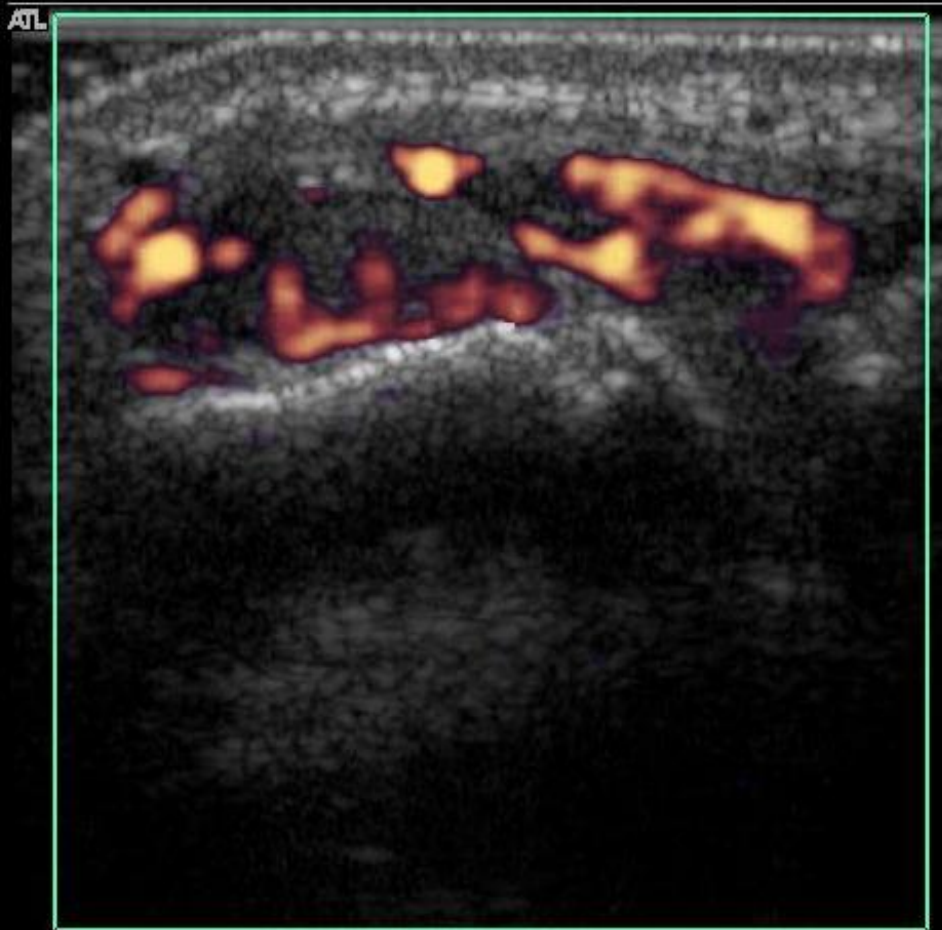
MTPJ - Dorsal – PD - Grade 1



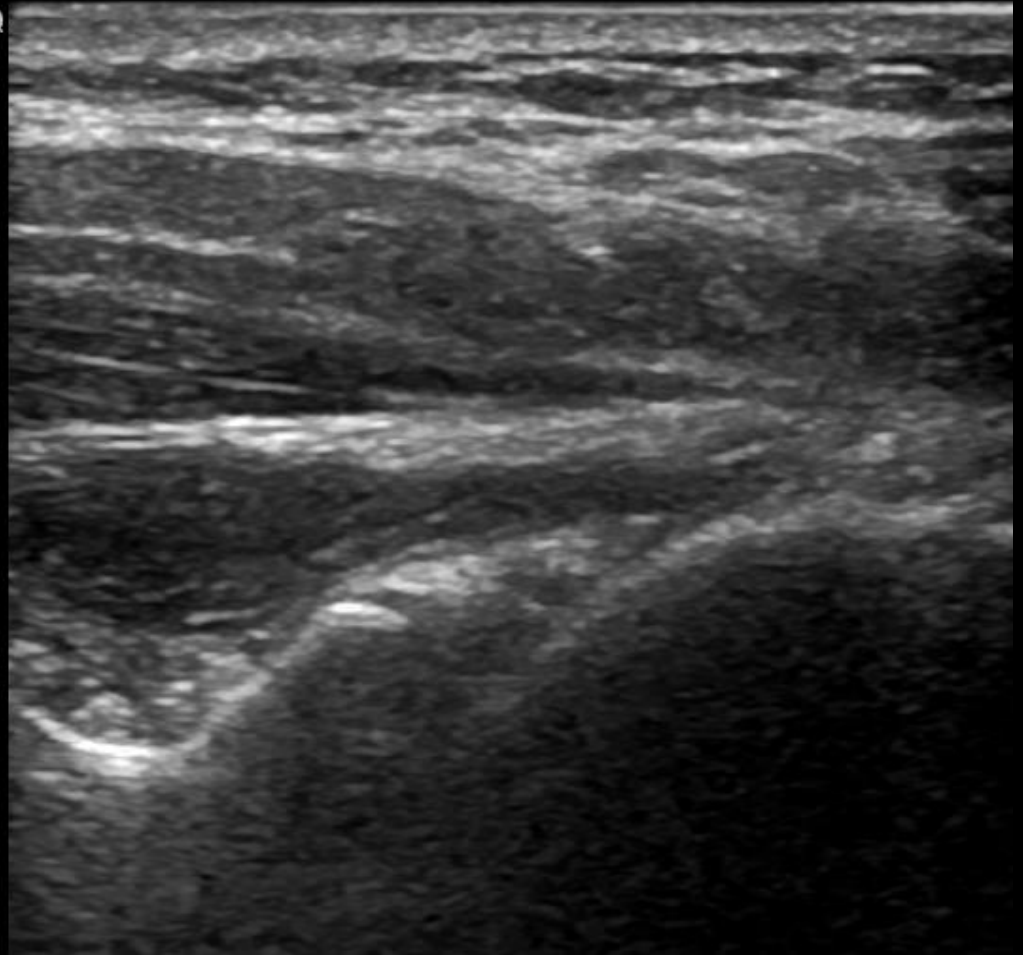
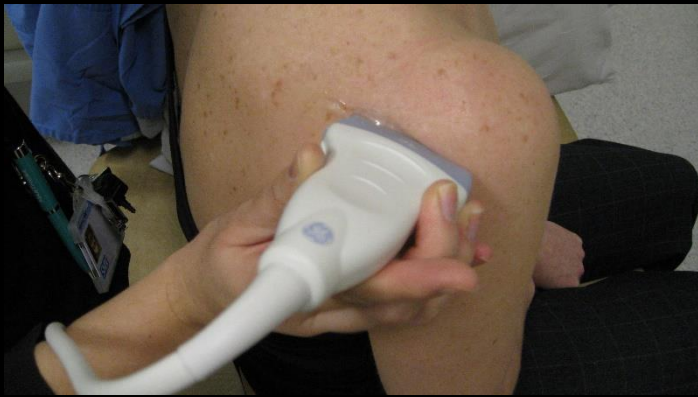MTPJ - Dorsal - PD- Grade 2



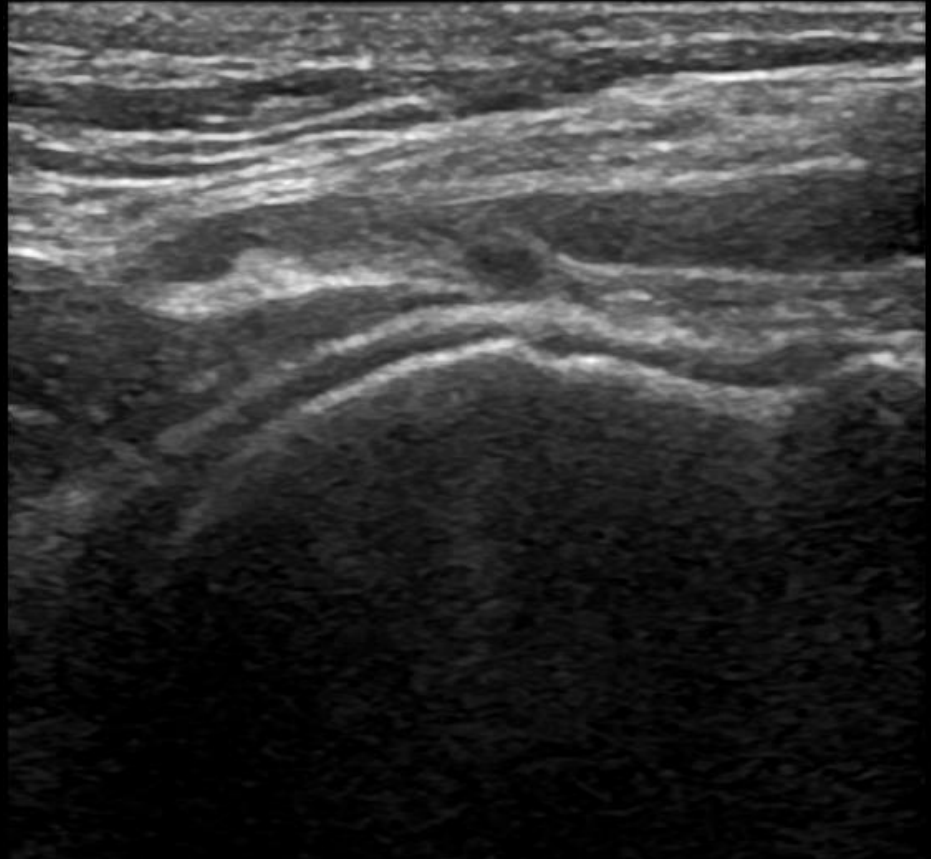
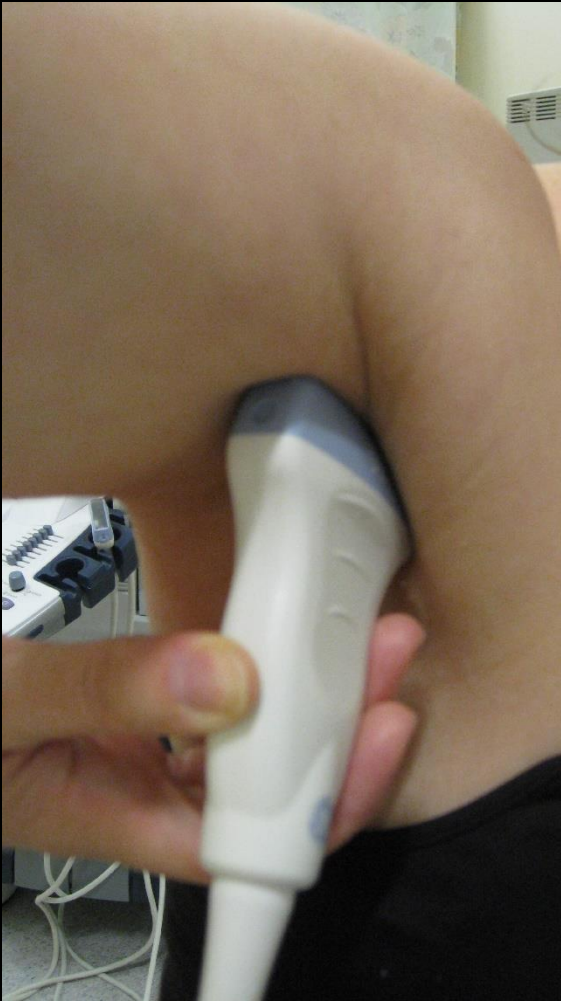MTPJ - Dorsal – PD- Grade 3



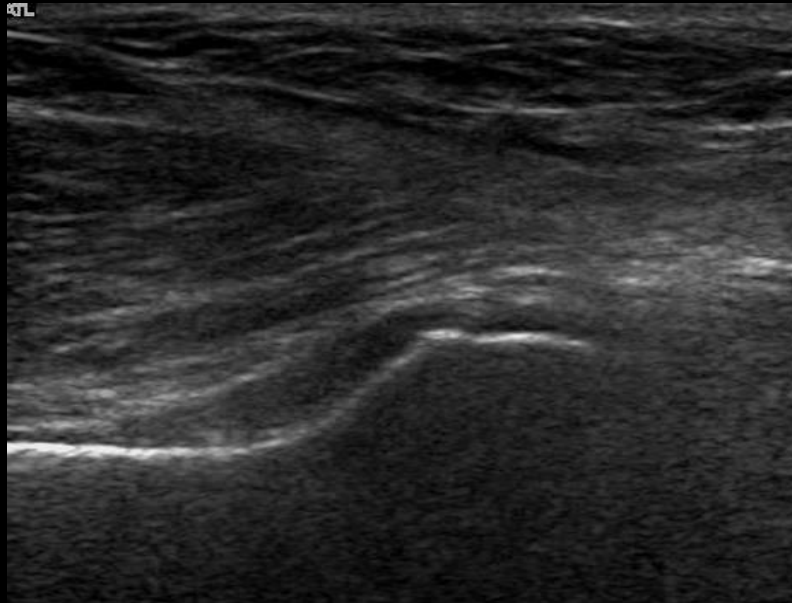
Posterior GHJ - Normal



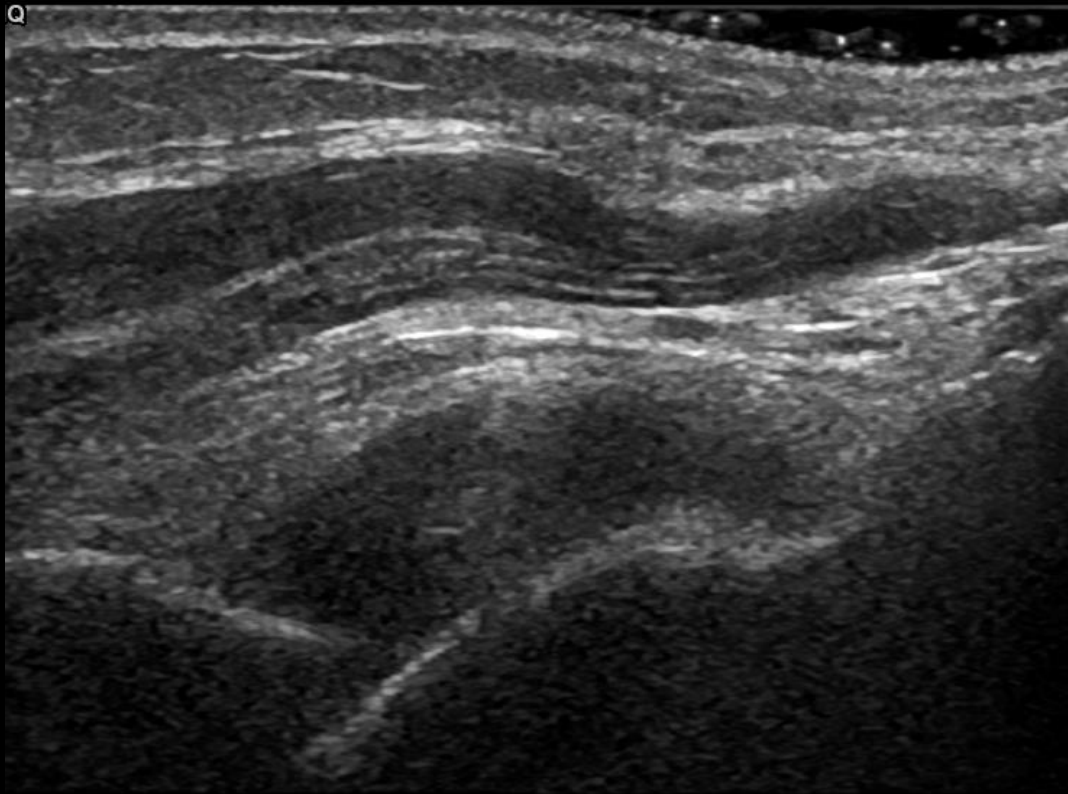
Posterior GHJ - Normal



Axillary GHJ – GS – Grade 1



Axillary GHJ – GS – Grade 3



Results

1. Sensitivity of joint effusion (JE) to change

As expected, JE showed the lowest sensitivity to change following treatment, with the earliest sign of improvement being observed at week 4. This finding is in agreement with the idea that effusion alone does not reflect a principal part of synovial activity. Smaller improvements were observed for JE over the 24-week treatment period compared with Global OMERACT-EULAR Synovitis Score (GLOESS), power Doppler (PD) and synovial hyperplasia (SH) scores.

2. Correlation between clinical scores and PDUS data

No correlations were observed between changes in 28-joint Disease Activity Score (DAS28) from baseline with changes in GLOESS or component scores, whichever joint set was used (MCPs 2–5 [table1], 22 paired or reduced 9 paired [data not shown]), or just using the 28 joints used to calculate DAS28 scores, at any time point (table 1). In addition, at all time points, very low correlations were observed between GLOESS (metacarpophalangeal joints [MCPs] 2–5) or the component scores and swollen joint counts (SJC) and tender joint counts (TJC) or combined SJC and TJC (data not shown). Furthermore, no correlations were found between early (baseline to weeks 1, 2 or 4) changes in GLOESS (whatever the joint set) or components and changes from baseline in the sum of swollen joints (MCPs 2–5, 22 paired joints, or reduced 9 paired joint set) at weeks 12 or 24 (data not shown).

Table 1 Correlation between change from baseline in DAS28 and change from baseline in PDUS scores (GLOESS [MCPs 2–5] and GLOESS for 28 joints used in DAS28 evaluation) and components

DAS28 (CRP)	n	Pearson's correlation coefficient (95% CI)
GLOESS (MCPs 2–5)		
Change from baseline to Day 7	80	0.090 (–0.133, 0.303)
Change from baseline to Day 85	85	0.150 (–0.066, 0.351)
Change from baseline to Day 169	83	0.168 (–0.050, 0.370)
GLOESS (MCPs 2–5) synovial hypertrophy		
Change from baseline to Day 7	80	0.029 (–0.193, 0.247)
Change from baseline to Day 85	85	0.122 (–0.094, 0.326)

MS ARD 2015-207709: Supplementary material

Change from baseline to Day 169	83	0.133 (−0.106, 0.320)
GLOESS (MCPs 2–5) Doppler signal		
Change from baseline to Day 7	80	0.248 (0.029, 0.442)
Change from baseline to Day 85	85	0.375 (0.173, 0.543)
Change from baseline to Day 169	83	0.217 (−0.000, 0.412)
GLOESS (MCPs 2–5) joint effusion		
Change from baseline to Day 7	80	0.127 (−0.096, 0.336)
Change from baseline to Day 85	85	0.247 (0.034, 0.436)
Change from baseline to Day 169	83	0.315 (0.104, 0.495)
GLOESS (28 joints)		
Change from baseline to Day 7	81	−0.027 (−0.244, 0.193)
Change from baseline to Day 85	85	0.188 (−0.027, 0.385)
Change from baseline to Day 169	83	0.215 (−0.002, 0.411)
GLOESS (28 joints) synovial hypertrophy		
Change from baseline to Day 7	81	−0.045 (−0.261, 0.175)
Change from baseline to Day 85	85	0.164 (−0.052, 0.363)
Change from baseline to Day 169	83	0.185 (−0.033, 0.385)
GLOESS (28 joints) Doppler signal		
Change from baseline to Day 7	81	0.217 (−0.003, 0.415)
Change from baseline to Day 85	85	0.347 (0.142, 0.520)
Change from baseline to Day 169	83	0.247 (0.031, 0.438)
GLOESS (28 joints) joint effusion		
Change from baseline to Day 7	81	0.173 (−0.048, 0.377)
Change from baseline to Day 85	85	0.271 (0.060, 0.456)
Change from baseline to Day 169	83	0.347 (0.139, 0.522)

CI, confidence interval; CRP, C-reactive protein; DAS28, 28-joint Disease Activity Score

MS ARD 2015-207709: Supplementary material

3. Safety data

Adverse events were reported in 60% of the total population (table 2), of which 21% were assessed as possibly, probably or certainly related to study drug. Seven serious adverse events (SAEs) were reported in six patients (atrial fibrillation, infective bursitis, dementia, endometriosis, pleural effusion and pulmonary fistula [in the same patient], and hypertension); two of which were considered at least possibly related to study treatment (infective bursitis, atrial fibrillation). No deaths occurred during this study, and there were no reported opportunistic infections or cases of tuberculosis. Six patients were withdrawn from the study owing to AEs (pulmonary fistula/pleural effusion, tachycardia/upper abdominal pain/dizziness/erythema multiforme [considered by the investigator to be related to study drug], foot fracture, dementia [SAE], pityriasis rosea, fever/cough). Benign malignancy (basocellular skin cancer) was reported in one patient on day 1; the patient received two infusions of study treatment before being withdrawn owing to an SAE (dementia).

Table 2 Safety summary

	Number of patients (N=104)
Deaths	0
AEs	62
Related AEs	22
Discontinuation owing to AEs	6*
SAEs	6
Related SAEs	2
Discontinuation owing to SAEs	1
Infection	20
Serious infection	1
Neoplasm (benign, malignant or unspecified)	1
Autoimmune events	2
Acute infusional events [†]	4

Safety data are presented for all patients who received at least one dose of study drug (N=104), and includes events that occurred up to 56 days post last dose. *One additional patient discontinued owing to an AE, but as the discontinuation was >56 days post last dose, this patient is not included in this table. [†]Occurring within 1 hour of infusion. AE, adverse event; SAE, serious adverse event.