

Ulcerative blepharitis in atopic patients – is *Candida* species the causative agent?

Veronika Huber-Spitzy, Kornelia Böhler-Sommeregger, E Arockar-Mettinger, G Grabner

Abstract

A total of 50 patients suffering both from atopic skin disease and different clinical forms of blepharitis have been included in this study. Microbiological investigations (for bacteria and fungi) of the lid margins were performed in all cases. In 21 (42%) of the patients an ulcerative blepharitis which heavily involved the follicles of the lashes was diagnosed. The remaining 29 cases presented with blepharitis of the squamous type. The cultures revealed that 19 of the 21 patients with ulcerative blepharitis were found to grow *Candida* species, whereas fungi could not be detected in any of the other cases of blepharitis. The frequencies of concomitant bacterial organisms found in the cultures were similar in both groups. As atopic patients are known to exhibit a defect in their cell-mediated immunity and possibly also a defective IgA antibody response it is a widely accepted assumption that these immunological changes are contributing factors to the development of a localised inflammation of the lids which is initiated by a variety of micro-organisms. We postulate that when *Candida* species happen to coincide with severe inflammation in atopic patients a blepharitis of the ulcerative type will develop or deteriorate thereby implying that these micro-organisms may play an important role in the development or deterioration of this severe chronic inflammation. It is therefore advisable to perform repeated scrapings and cultures in every case of recalcitrant blepharitis.

Atopic dermatitis is a complex multifactorial skin disease with a spectrum of abnormal immunological and non-immunological findings. A deficiency in T-cell subpopulations, an increased IgE antibody response, and a higher releasability of vasoactive mediators due to a partial blockade of the β -adrenergic receptor sites may play a role in its pathogenesis.¹ Since Coca and Cooke² introduced the term 'atopy' in 1923, hereditary factors have also been shown to play an important role in the disposition of an individual to develop the spectrum of atopic diseases. Most of these patients have a history of chronic relapsing eczematous skin disease dating from infancy which is treated with topical steroids as described by Küster.³

In 1952 Hogan^{4,5} described five cases of atopic keratoconjunctivitis which he defined as a bilateral keratoconjunctivitis associated with atopic dermatitis, occurring at a variable interval after the onset of the eczema and showing a flare-up whenever the dermatitis worsened. As Foster pointed out in 1990, and our results corroborate his observation, some patients of this series had

ocular inflammation which evolved independent of the dermatitis.⁶

Ocular complications are observed with a high frequency. In a study by Garrity and Liesegang that included 200 atopic patients 42.5% showed ocular problems such as blepharoconjunctivitis, cataracts, and corneal diseases.^{4,6-8} We now report on a total of 50 patients who suffered both from atopic skin disease and different clinical forms of blepharitis.

Material and methods

Between January 1982 and December 1990 a total of 50 atopic patients (29 male, 21 female) presented at the outpatient clinic for infectious eye diseases with the signs of chronic inflammatory changes of the lids. This report describes the pertinent clinical, microbiological, and dermatological findings.

In ulcerative blepharitis the follicles of the lashes were involved, regularly being covered by thick matted, hardened crusts. Fibrin which exudes from the base of the skin defect usually masks the presence of the ulceration.⁸ When carefully trying to remove these scales with a pair of forceps small, bleeding lesions in the area of the hair follicles appear regularly.

Squamous blepharitis was defined as a superficial and *non-destructive* inflammation of the lid margins with dry scaling being the prominent clinical feature in this subgroup. This type of lid involvement is considered to represent a localised eczematous dermatological disease.⁹

All patients were seen by the same dermatologist (KB-S). Their age ranged from 19 to 31 years (with a mean of 23.7 years). The duration of the blepharitis ranged from 5 to 36 months, with an average of 19.5 months.

All patients had a history of eczema dating from infancy sometimes combined with allergic rhinitis and asthma. Additional criteria for the dermatological diagnosis were the personal and family history of atopy (parents and first degree

University of Vienna,
Austria
2nd Department of
Ophthalmology
V Huber-Spitzy
E Arockar-Mettinger
G Grabner

2nd Department of
Dermatology
K Böhler-Sommeregger

Correspondence to:
V Huber-Spitzy.

Accepted for publication
17 October 1991

Table 1 Microbiological results

	All patients (n=50) (100%)	Patients with ulcerative blepharitis (n=21) (42%)	Patients with squamous blepharitis (n=29) (58%)
Coagulase negative			
<i>Staphylococcus</i>	21	9	12
<i>S aureus</i>	38	16	22
<i>Streptococcus</i> (A & B)	15	7	8
<i>Corynebacterium</i>	18	10	8
<i>Propionibacterium</i>	21	12	9
<i>E coli</i>	4	2	2
<i>Pseudomonas</i> sp	4	3	1
<i>Citrobacter</i>	4	4	0
<i>Candida</i> species	19	19	0

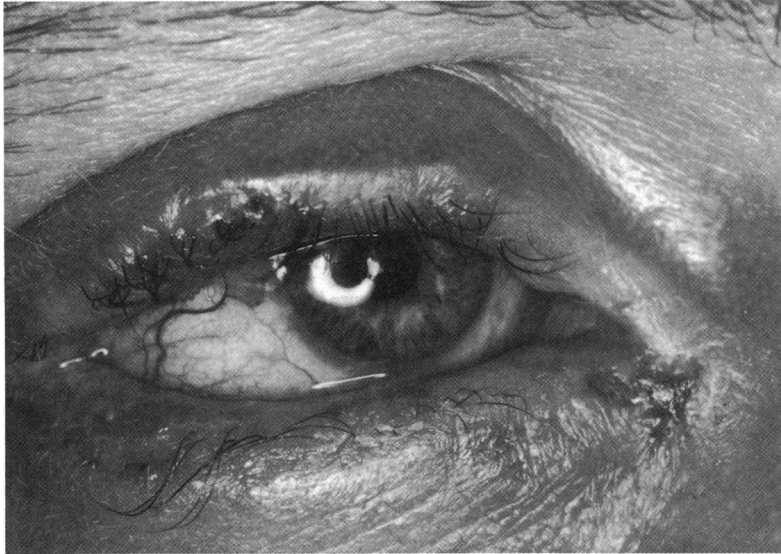


Figure 1 Ulcerative blepharitis.

relatives). The ocular diagnosis was based on the observation of a dermatitis of the lids, sometimes combined with meibomitis, trichiasis, distichiasis, and additional conjunctival and/or corneal signs such as giant papillae, follicles, or corneal scarring and neovascularisation.

Most of the patients had previously been treated unsuccessfully and had been referred for special work-up; 17 of our patients had additionally received topical steroids (12 had stopped this therapy weeks before our examination, five patients still used a corticosteroid ointment 3–6 times/day); both factors are known to contribute to fungal superinfection. Twenty one atopic patients underwent a laboratory examination including the total eosinophil count and quantitative immunoglobulins, such as IgE.

Separate samples for microbiological investigations (aerobic as well as anaerobic cultures) were harvested from all eyelids included in the study. To optimise recovery of micro-organisms the moistened sterile calcium alginate swab was passed along the anterior lid margin. For aerobic cultures different media (trypticase soy broth with 5% sheep erythrocytes, chocolate agar, manitol-salt agar, and endo agar) were used and incubated in a 5% CO₂ atmosphere for a minimum of 12 to 24 hours (if any growth was observed) and up to a maximum of 72 hours for the detection of anaerobic micro-organisms. For the culture of the latter Schaedler's broth gassed with an atmosphere of 97% CO₂ and 3% hydrogen (in GasPak Jars, BBL) was used. Fungi were cultivated on Sabouraud agar with and without inhibitors and specified by *Candida* API.

We determined the sensitivities to commonly given ophthalmic antibiotics and sulphonamides for all rapidly growing aerobic isolates by the Barry agar overlay method¹⁰ using commercially

available antimicrobial discs and Mueller Hinton agar (BBL). For *Propionibacterium acnes* the broth disc method of Wilkins and Thiel was employed.¹¹ No attempt was made to isolate *Pityrosporon ovale* or *Demodex folliculorum*.

Results

An ulcerative blepharitis was observed in 21 (42%) of the patients (Fig 1). Frequent findings were dilated blood vessels on the inner lid margins (84%) and madarosis (56%); poliosis (6%) and trichiasis (4%) were less common. Squamous blepharitis was observed in 29 (58%) of our patients. We only found signs of a concomitant meibomitis in seven of the patients with this condition. The results of aerobic and anaerobic bacterial cultures from the lids are detailed in Table 1. Within the bacterial genus *Staphylococcus aureus* and coagulase negative *Staphylococcus* (*S. epidermidis* and *S. saprophyticus*) were the most frequently isolated organisms (38 (76%) cultures out of samples with positive cultures of *S. aureus*, 21 (42%) cultures positive for coagulase negative *Staph*). The second most frequent isolates of the lids were *Corynebacterium* and *Propionibacterium*, which are considered to constitute normal inhabitants of the skin.

The culture for *Candida* species was positive in 19 samples (38%), the only affected patients being those with ulcerative blepharitis. In this group 19 of the 21 patients (90.4%) had fungal infections: *C. albicans* in 13 cases, *C. parapsilosis* four times, *C. krusei* and *C. stellatoidea* once (Table 2).

We were unable to isolate fungi from the patients with squamous blepharitis or from the conjunctival sac.

All patients with confirmed fungal infections received systemic therapy with two single doses of 100 mg ketoconazole per day and miconazole ointment topically six times a day for a duration of 6 weeks. In all cases repeated cultures after 6, 12, and 18 weeks were negative and the clinical findings considerably improved in all cases after this specific treatment. On discontinuation of therapy a relapse occurred in seven patients.

Only five of our patients (10%, four male, five female) showed severe ocular involvement. They all suffered from atopic keratoconjunctivitis as described by Foster: a chronic cicatrising conjunctivitis with serious corneal complications such as pannus formation in the superficial third of the peripheral cornea.⁶ One patient had a history of eczema herpeticum of the face and some episodes of herpetic stromal keratitis.

Serum IgE levels (normally less than 100 IU/ml) were significantly elevated in 15 of the 21 patients tested (ranged from 205 to 610 IU, mean 345, SD 45). The serum IgE level of the other six patients was normal, although all of them had a history of eczema dating from infancy combined with allergic rhinitis or asthma. There was no correlation of the IgE level with the clinical picture of blepharitis or with the progress of disease observed.

Table 2 Classification of *Candida* subtypes (n=19)

<i>C. albicans</i>	13
<i>C. parapsilosis</i>	4
<i>C. krusei</i>	1
<i>C. stellatoidea</i>	1

Discussion

To the best of our knowledge this is the first

report of a very high incidence (90.4%) of recovery of *Candida* species from the lid margins of atopic patients suffering from blepharitis of the ulcerative type.

Atopic patients are known to exhibit a defect in their cell-mediated immunity and possibly also a defective IgA antibody response.³ These immunological changes may represent some of the contributing factors for the localised inflammatory changes of the lids which are caused by a variety of micro-organisms. On the other hand it cannot be overlooked that all of these patients had a long history of lid inflammation. It might well be that the presence of ulceration provides a suitable substrate for *Candida* to colonise.

We now postulate that only when *Candida* species happen to coincide with severe inflammation in atopic patients will a blepharitis of the ulcerative type develop or deteriorate, thereby implying that these micro-organisms may play an important role in the deterioration or development of this severe chronic inflammation.^{9,12}

It is therefore advisable to perform repeated scrapings and cultures in every case of recalcitrant blepharitis. This is the only reliable way to rule out a frequent superinfection with fungi in ulcerative blepharitis and to provide specific and

adequate treatment for this recalcitrant disease.^{13,14}

- 1 Hanifin JM, Lobitz WC. Newer concepts of atopic dermatitis. *Arch Dermatol* 1977; 116: 663-70.
- 2 Coca AF, Cooke RA. On the classification of the phenomenon of hypersensitiveness. *J Immunol* 1923; 8: 163-82.
- 3 Küster W, Petersen M, Christophers E, Goos M, Sterry W. A family study of atopic dermatitis. *Arch Dermatol Res* 1990; 282: 98-102.
- 4 Hogan MJ. Atopic keratoconjunctivitis. *Trans Am Ophthalmol Soc* 1952; 50: 265-81.
- 5 Hogan MJ. Atopic keratoconjunctivitis. *Am J Ophthalmol* 1953; 36: 937-47.
- 6 Foster CS, Calonge M. Atopic keratoconjunctivitis. *Ophthalmology* 1990; 97: 992-1000.
- 7 Garrity JA, Liesegang TJ. Ocular complications of atopic dermatitis. *Can J Ophthalmol* 1984; 19: 21-4.
- 8 Ostler HB. Blepharitis. In: Duane, ed. *Clinical ophthalmology*. Revised edition, Harper and Row: Philadelphia, 1989; IV, 22: 1-7.
- 9 McCulley JP, Dougherty JM, Deneau DG. Classification of chronic blepharitis. *Ophthalmology* 1982; 89: 1173-80.
- 10 Barry AL, Garcia F, Trupp LD. An improved single disc method for testing the antibiotic susceptibility of rapidly growing pathogens. *Am J Clin Pathol* 1984; 53: 149-58.
- 11 Wilkins TD, Thiel T. Modified broth-disc method for testing the susceptibility of anaerobic bacteria. *Antimicrob Agents Chemother* 1973; 3: 350-6.
- 12 Csato M, Kendressy Sz, Judak R, Dobozy A. Inflammatory mediators are involved in the *Candida albicans* killing activity of human epidermal cells. *Arch Dermatol Res* 1990; 282: 348-50.
- 13 Dougherty JM, McCulley JP. Comparative bacteriology of chronic blepharitis. *Br J Ophthalmol* 1984; 68: 524-8.
- 14 Seal DV, McGill JJ, Jacobs A, Liakos GM, Goulding NJ. Microbial and immunological investigations of chronic non-ulcerative blepharitis and meibomianitis. *Br J Ophthalmol* 1985; 69: 604-11.