

## CASE 3

A 41-year-old white woman with bilateral Fuchs' heterochromic iridocyclitis was noted to have an iris crystal in her left eye, which had an uncomplicated cataract extraction with posterior chamber lens implantation. The patient was treated with topical timolol in both eyes for open angle glaucoma. The patient was treated with isoniazid for positive conversion of the purified protein derivative (PPD) skin test.

The best corrected visual acuity was 20/25 OD and 20/40 OS. The right cornea showed mild band keratopathy. About 100 fine keratic precipitates were scattered diffusely on the right corneal endothelium, whereas about 47 fine to medium-sized keratic precipitates were noted on the left corneal endothelium. Some of the keratic precipitates were stellate and had fine fibrin bridges. The right anterior chamber had +1 flare and occasional cells, and the left anterior chamber had +1 flare and +3 cells. Both irides showed diffuse stromal atrophy. One iris crystal was noted on the left iris near the pupillary margin at the 6 o'clock position. The right lens had a mild posterior subcapsular opacity. The posterior chamber lens implant in the left eye had a few deposits on its anterior surface. The posterior capsule had mild haze. The intraocular pressure and both fundi were normal.

## Comment

Including the three patients in this report seven patients with iris crystals have been described in the ophthalmic literature, and all patients had chronic iridocyclitis.<sup>1,2</sup> Some of the patients with iris crystals had sarcoidosis or were tested positive for HLA-B27.<sup>2</sup> In this report, we describe the presence of iris crystals in patients with idiopathic chronic iridocyclitis (case 1), chronic iridocyclitis associated with systemic pseudolymphoma (case 2), and Fuchs' heterochromic iridocyclitis (case 3). In two of our patients (cases

1 and 3), the iris crystals were in one eye only, and the other case was bilateral.

The clinical appearance of iris crystals is dramatic. Although they are minute, iris crystals are highly refractile and glisten with illumination. Iris crystals are best seen with the slit beam set at different angles since different iris crystals will glisten as the angle of the slit beam is changed. An eye may have from one to multiple iris crystals, and the number of iris crystals in an eye may change from time to time.

The pathogenesis of iris crystals remains obscure. In 1969 Iwamoto and Witmer<sup>1</sup> reported a case of chronic uveitis and iris crystals, and with electron microscopy they demonstrated that iris crystals are Russell bodies in the iris stroma. Russell bodies are precipitates of immunoglobulins in plasma cells, and sometimes these precipitates may crystallise.<sup>3</sup> We hypothesise that the characteristics of iris crystals may be due to the crystallisation of immunoglobulins that may occur in some Russell bodies.<sup>3</sup>

In 1990 Lam and Tessler<sup>2</sup> reported three cases of iris crystals associated with hypergammaglobulinaemia. Our first two cases in this report, however, did not demonstrate hypergammaglobulinaemia on serum protein electrophoresis. Therefore, iris crystals may not always be indicative of hypergammaglobulinaemia. Serum protein electrophoresis was not performed in case 3.

This work was supported in part by core grant EY 1792 from the National Eye Institute, Bethesda, MD, an unrestricted research grant from Research to Prevent Blindness, Inc, New York, and gifts from the Lions of Illinois Foundation, Maywood, IL, USA.

1 Iwamoto T, Witmer R. Light and electron microscopy on plasma cells and Russell body in the iris of a chronic uveitis patient. *Invest Ophthalmol* 1969; 8: 563-82.

2 Lam S, Tessler HH. Iris crystals and hypergammaglobulinemia. *Am J Ophthalmol* 1990; 110: 440-1.

3 Howes EL. Basic mechanisms in pathology. In: Spencer WH, ed. *Ophthalmic pathology. An atlas and textbook*. 3rd ed. Vol 1. Philadelphia: Saunders, 1985: 33.

(*Br J Ophthalmol* 1993; 77: 182-183)

## Coxsackievirus B3-associated panuveitis

Werner Förster, Alexander A Bialasiewicz, Holger Busse

## Abstract

**A 29-year-old woman suffered from headaches, diarrhoea, and high grade fever followed by a unilateral retinal vasculitis, papillitis, and chorioretinitis. Abnormal electrocardiographic findings and antibody titre dynamics strongly suggested a coxsackievirus B3 infection. With respect to prior observations on coxsackievirus B group associated uveitis this viral infection may be considered in patients with well defined extraocular manifestations and uveitis.**

(*Br J Ophthalmol* 1993; 77: 182-183)

More than 90% of coxsackievirus group B infections are either asymptomatic or result in undifferentiated febrile illness with malaise and sore throat. A number of upper respiratory syndromes, diarrhoea and abdominal pain, central nervous system, and cardiac disorders are caused by coxsackievirus B infections.<sup>1</sup> Whereas coxsackievirus A24 has long been known as a cause of acute haemorrhagic conjunctivitis,<sup>2</sup> the ophthalmic manifestations of coxsackievirus group B infections have only recently been elucidated. Infections with coxsackievirus B4 have been linked to chorioretinitis<sup>3</sup> and

University Eye Hospital  
Münster, Münster,  
Germany  
W Förster  
A A Bialasiewicz  
H Busse

Correspondence to:  
A A Bialasiewicz, University  
Eye Hospital Münster,  
Domagkstrasse 15, W-4400  
Münster, Germany.

Accepted for publication  
27 November 1992

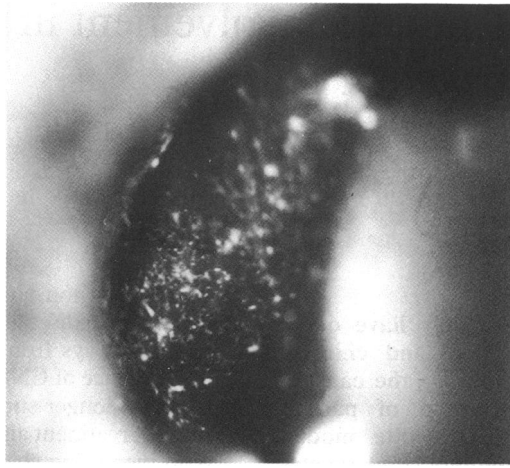

Figure 1 Patient with an anterior chamber flare and inflammatory cells in the vitreous. Visual acuity 20/30.

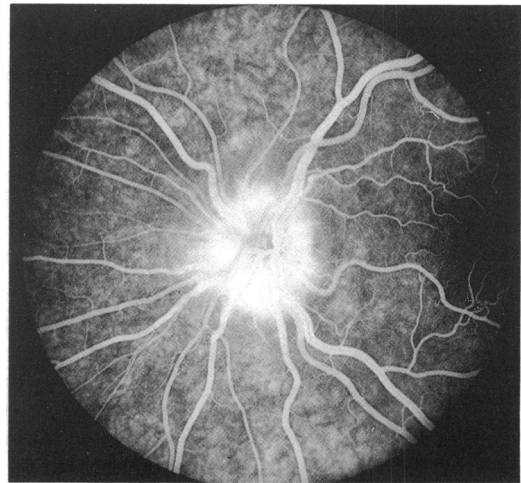


Figure 2 Same patient with a fluorescein angiography showing retinal vessel leakage underlying the vitreous infiltrate.

coxsackievirus B5 to papillitis.<sup>4</sup> We report on a patient with a coxsackievirus B3 infection and panuveitis.

#### Case report

In June 1991, a 29-year-old woman presented with a history of general fatigue, diarrhoea, abdominal pain, headache, and high grade fever. Three weeks after the onset of these symptoms she had noticed blurred vision in her left eye.

Visual acuity in her left eye was reduced to 20/30. Intraocular pressure was normal (12 mm Hg). Biomicroscopy revealed conjunctival hyperaemia, retrocorneal precipitates, and a massive inflammatory cellular infiltrate in the anterior chamber and the vitreous (Fig 1). Papillitis was observed, the macula was unremarkable and some small chorioretinal lesions in the mid-periphery of the fundus could be visualised. Fluorescein angiography revealed leakage of retinal vessels consistent with the diagnosis of retinal vasculitis and hyperfluorescence of the papilla (Fig 2).

Five weeks after presentation a neurological examination did not reveal any meningeal signs and a lumbar puncture was therefore not done; however a pathological prolongation of the P-R interval (0.30 seconds) could be verified by electrocardiography. Laboratory examination at presentation showed a white blood cell count of  $12 \times 10^9/l$ . Other laboratory tests were unremarkable. In the neutralisation test system, seroconversion for coxsackievirus B3 was noted at 1:128 (A9:negative, B1:negative, B2:1:16, B4:1:32,

B5:negative) with a subsequent decrease of two antibody titre steps in the following 2 weeks and negative results after 3 months. Simultaneously, visual acuity of the left eye improved to 20/20, and the panuveitis disappeared completely without recurrence.

#### Comment

In this patient inflammatory cells in the anterior chamber and vitreous were accompanied by retinal vasculitis, papillitis, and chorioretinitis resulting in a diagnosis of panuveitis. The antibody titre dynamics of coxsackievirus B3 in association with the clinical course and previously reported ocular<sup>1,3,4</sup> and electrocardiographic<sup>3</sup> findings in coxsackievirus group B infections suggest panuveitis to be an ocular manifestation of coxsackievirus B3 infection as well.

In a setting of systemic signs and symptoms in accordance with an abdominal viral infection, chorioretinitis, retinal vasculitis, and papillitis as well as a flare of the vitreous and anterior chamber, a coxsackievirus group B infection should be considered.

- 1 Young NA. Coxsackievirus and echovirus. In: Mandell GL, Douglas RG, Bennett JE, eds. *Principles and practice of infectious diseases*. New York: John Wiley, 1979: 1104–20.
- 2 Higgins PG, Chapman TED. Coxsackievirus A24 and acute haemorrhagic conjunctivitis in Sri Lanka. *Lancet* 1977; i: 361.
- 3 Hirakata K, Oshima T, Azuma N. Chorioretinitis induced by coxsackievirus B4 infection. *Am J Ophthalmol* 1990; 109: 225–7.
- 4 Spalton DJ, Murdoch I, Holder GE. Coxsackie B5 papillitis. *J Neurol Neurosurg Psychiatry* 1989; 52: 1310–1.