

## LETTERS TO THE EDITOR

### Calcification-like echographic pattern in uveal melanomas treated with brachytherapy

EDITOR,—In a consecutive series of 1300 patients with uveal melanomas treated with brachytherapy ( $^{106}\text{Ru}/^{106}\text{Rh}$  plaques),<sup>1</sup> three patients developed unusual echographic findings following radiation. Pretreatment echographic evaluation showed homogeneous tumour echoes with low inner reflectivity.

The patients were a 48-year-old woman, a 63-year-old man, and a 73-year-old woman. Before treatment the maximum tumour heights were 6.9 mm, 7.7 mm, and 6.2 mm respectively. The first patient received two courses of radiation with 1360 and 1000 Gy scleral contact dose within 15 months and an additional laser coagulation 6 months later. The other patients were treated once with scleral contact doses of 700 and 1000 Gy respectively. Highly reflective echoes with posterior shadowing were detected 5, 7, and 2 years after radiation in regressive residual tumours with a height of 2.7 mm, 1.2 mm, and 1.7 mm respectively (Figs 1, 2).

An increase of reflectivity usually occurs in melanomas following radiation therapy.<sup>2,3</sup> However, very high reflectivity and marked posterior shadowing are very characteristic signs of calcification and have not been described previously. Histological findings following radiation therapy include tumour

necrosis, haemorrhages, and lymphocytic infiltration but calcifications have not been observed.<sup>4,5</sup>

Two hypotheses may explain the unusual findings. Either the intraocular tumour in our patients was misdiagnosed or calcification may occur in regressive uveal melanomas. In all patients the ophthalmoscopic diagnosis of a uveal melanoma was consistent with the fluorescein angiography and echographic findings, which makes a misdiagnosis unlikely.<sup>6</sup> Other ocular tumours presenting with calcification are retinoblastomas and osteomas, which can be excluded based on the age of the patients and clinical findings. Calcification typically occurs in necrotic areas for example, in retinoblastomas calcification most probably starts in the mitochondria of degenerating tumour cells.<sup>7,8</sup> Although histological evidence cannot be presented in the successfully treated eyes of our patients, it is most likely that calcification has occurred in their necrotic residual tumours.

ULRICH KELLNER  
MICHAEL H FOERSTER  
Freie Universität Berlin,  
Klinikum Steglitz,  
Augenklinik,  
Berlin,  
Germany

NORBERT BORNFIELD  
Zentrum für Augenheilkunde,  
Universität Essen,  
Essen,  
Germany

- 1 Foerster MH, Bornfeld N, Schulz U, Wessing A, Meyer-Schwickerath G. Complications of local beta radiation of uveal melanomas. *Graefes Arch Clin Exp Ophthalmol* 1986; 230: 336–40.
- 2 Guthoff R, von Domarus D, Steinhilber U, Hallermann D. 10 Jahre Erfahrung mit der Ruthenium-106/Rhodium-106-Behandlung des malignen Melanoms der Aderhaut-Bericht über 264 bestrahlte Tumoren. *Klin Monatsbl Augenheilkd* 1986; 188: 576–83.
- 3 Eichler C, Hertel A, Lommatzsch P, Fuhrmann P. Echographische Befunde vor und nach  $\beta$ -Bestrahlung ( $^{106}\text{Ru}/^{106}\text{Ru}$ ) von Aderhautmelanomen. *Klin Monatsbl Augenheilkd* 1987; 190: 17–20.
- 4 MacFaul PA, Morgan G. Histopathological changes in malignant melanomas of the choroid after cobalt plaque therapy. *Br J Ophthalmol* 1977; 61: 221–8.
- 5 Messmer E, Bornfeld N, Foerster MH, Schilling H, Wessing A. Histopathologic findings in eyes treated with a ruthenium plaque for uveal melanoma. *Graefes Arch Clin Exp Ophthalmol* 1992; 230: 391–6.
- 6 The Collaborative Ocular Melanoma Study Group. Accuracy of diagnosis of choroidal melanomas in the Collaborative Ocular Melanoma Study, COMS report No 1. *Arch Ophthalmol* 1990; 108: 1268–73.
- 7 Spencer WH, ed. *Ophthalmic pathology: an atlas and textbook*. 3rd ed. Philadelphia: Saunders, 1985: 14–5.
- 8 Lin CCL, Tso MOM. An electron microscopic study of calcification of retinoblastoma. *Am J Ophthalmol* 1983; 96: 765–74.

### Herpetic corneal ulcers in Malawi

EDITOR,—There have been reports of large numbers of herpetic corneal ulcers in Tanzania,<sup>1,2</sup> particularly in association with measles or a history of malaria. As with many of these reports, we also must rely on clinical appearance and response to therapy for diagnosis of herpetic ulcers and we also find that the majority of these are geographic or stromal. However, our experience in Malawi is that herpetic ulcers are relatively uncommon. Malawi has a good system of ophthalmic medical assistants, active in every district. They successfully treat many bacterial corneal ulcers and refer non-healing ulcers or those they suspect of being herpetic to the central

hospitals. Thus, we would expect to see a disproportionately large number of herpetic ulcers compared to bacterial ulcers in the central hospitals. In Malawi, febrile illnesses are common (malaria is holoendemic and measles epidemics still occur) and the seroprevalence of HIV is one of the highest in Africa. All these factors would be expected to contribute to a large number of herpetic ulcers, if herpes simplex were common in the population. None the less, at the Queen Elizabeth Central Hospital, which serves the population of five million in the southern region, fewer than 10% of the corneal ulcers are presumed to be herpetic. Among the 250 children admitted to the measles ward from March 1992 to January 1993 there were no patients with corneal ulceration or herpetic mouth ulcers. Similarly, among 350 children with cerebral malaria admitted to the Malaria Research Project over the past 6 years none has had corneal ulceration or herpetic mouth ulcers. (TE Taylor, ME Molyneux, personal communication.) Although these data are not population based, they suggest that herpes simplex is not common in this population.

There is good documentation of the high prevalence of herpetic corneal ulcers in Tanzania and Nigeria.<sup>3</sup> However, the epidemiology of herpes simplex in Africa may still be too unclear to justify the assumption that it is a common cause of corneal blindness throughout the continent.

SUSAN LEWALLEN  
M C CHIRAMBO  
Queen Elizabeth Central Hospital,  
PO Box 2273,  
Blantyre,  
Malawi

- 1 Foster A, Sommer A. Corneal ulceration, measles, and childhood blindness in Tanzania. *Br J Ophthalmol* 1987; 71: 331–43.
- 2 Yorston D, Foster A. Herpetic keratitis in Tanzania: association with malaria. *Br J Ophthalmol* 1992; 76: 582–5.
- 3 Sandford-Smith JH, Whittle HC. Corneal ulceration following measles in Nigerian children. *Br J Ophthalmol* 1979; 63: 720–4.

### Glaucoma screening

EDITOR,—We were very pleased to see Mr Hitching's editorial on glaucoma screening in the June edition of the journal. Readers might like to know that the RNIB figures quoted were obtained from the *RNIB Survey into Blind and Partially Sighted Adults in Britain*, 1991 (HMSO) by Ian Bruce, Aubrey McKennell and Errol Walker. A second volume is also available on the blind and partially sighted children in Britain.

SUE GRINDEY  
RNIB Health Services Unit,  
224 Great Portland Street,  
London W1N 6AA

### Gillespie syndrome reported as bilateral congenital mydriasis

EDITOR,—Richardson and Schulenberg<sup>1</sup> reported a 2½-year-old girl with bilateral congenital mydriasis, developmental delay, and an atrophic vermiform appendix. The family have recently consulted me and I would like to suggest that this child has Gillespie syndrome, which is characterised by the triad of cerebellar ataxia, partial aniridia, and developmental delay. Gillespie syndrome is distinct from reports of autosomal dominant congenital mydriasis without other complications.<sup>2,3</sup>

The first report of this phenotype is usually attributed to Gillespie<sup>4</sup> who described a brother and sister sib pair and suggested autosomal

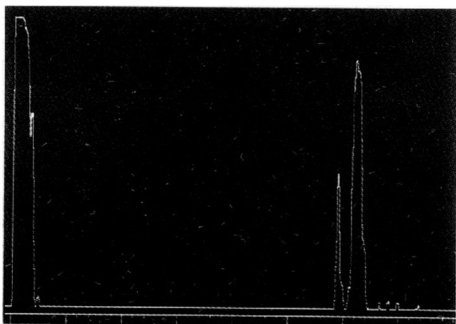


Figure 1 Echographic A-scan of regressive uveal melanoma 2 years after brachytherapy. The sensitivity is reduced to 35 dB (standard tissue sensitivity 61 dB). On the right the smaller first spike indicates the anterior surface of the residual tumour. The second spike indicates very high reflectivity within the tumour, the echoes of the sclera and orbita posterior to this signal are markedly diminished.

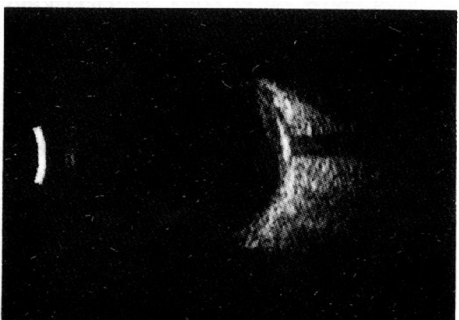

Figure 2 Echographic B-scan of the same eye at the same time as Figure 1. A highly reflective area can be seen within the residual tumour. Posterior to this area a marked shadowing is present.