

PERSPECTIVE

Fuchs' heterochromic cyclitis: review of the literature on the pathogenetic mechanisms

E La Hey, P T V M de Jong, A Kijlstra

Fuchs' theory

Ernst Fuchs, who first described this disease in 1906, assumed that the syndrome was caused by a noxious factor of unknown origin, which was active from fetal or early postnatal life.¹ First, the normal development of uveal pigmentation would be inhibited, resulting in heterochromia (Fig 1). Later, the eye would respond to this pathological agent by a low grade inflammation. Many objections were raised against Fuchs' theory. The heterochromia was not always congenital and there were no signs of overt ocular inflammation.

Sympathetic theories

The sympathetic theories are based on the fact that sympathetic lesions may be followed by iris hypochromia. Bistis introduced the idea that some 'trophic' defect in the sympathetic nerve system inhibited the normal process of uveal pigmentation.^{2,3}

Two other conditions have also been associated with Fuchs' heterochromic cyclitis (FHC) and a sympathetic defect - 'status dysraphicus' and progressive facial hemiatrophy (Parry Romberg syndrome).^{2,4,5} 'Status dysraphicus' was described as a microform of syringomyelia, which was believed to be due to a faulty closure of the primitive neural tube. Sometimes FHC was its sole manifestation.² Other abnormalities frequently reported to be part of 'status dysraphicus' were^{6,7,8}: (1) Marfan syndrome and the Parry Romberg syndrome; (2) skeletal abnormalities, such as kyphoscoliosis and 'funnel chest'; (3) Horner's syndrome, pigment asymmetry of the nipples; (4) sensory and motor neuron disturbances, such as acrocyanosis, involvement of the fifth, sixth, and seventh cranial nerves.

In 1973, Loewenfeld and Thompson² rejected the sympathetic theory. In their literature review of 1746 cases with FHC, only 25 cases (1.4%) with FHC and Horner's syndrome were found. This was said to be too low an incidence to indicate a relation between FHC and the occurrence of a sympathetic defect (Horner's syndrome).² Loewenfeld and Thompson, however, did not compare this figure (1.4%) with the product of the prevalence of the separate diseases in the general population, which is necessary when a clinical (epidemiological) association is investigated. No evidence was found for the existence of 'trophic sympathetic nerve fibers' and it was proved that 'status dysraphicus' was a manufactured syndrome without existence in reality.²

However, since 1973, four more patients with FHC and the syndrome of Parry Romberg have been reported.⁹⁻¹¹ In two other cases Horner's syndrome and FHC developed consecutively in the same eye after stellate ganglionectomy.^{12,13} Five patients with unilateral FHC and ipsilateral Horner's syndrome were reported.¹⁴ Pupillary changes, Horner's syndrome, and heterochromia are often reported in patients with hemifacial atrophy, and are all signs of an impaired sympa-

thetic nervous system.¹⁵ The leakage seen on the iris fluorescein angiographic studies in FHC may be caused by a disturbance in the iris vessel innervation, which is solely derived from the sympathetic nerve system.¹⁶⁻¹⁸ Electron microscopic studies in FHC have suggested that the hypochromia may result from a defective melanin production, caused by abnormal adrenergic innervation.¹⁹

Laties,^{20,21} Ehinger,²² and others²³⁻²⁵ have demonstrated a direct adrenergic innervation of iris stromal melanocytes. For mammals this is extraordinary, because skin melanocytes have no innervation.²⁰ After denervation of the sympathetic nervous system on one side in young rabbits²⁰ a significant decrease in activity of the enzyme tyrosinase was found in the ipsilateral, discoloured iris tissue. Moss and Cirkelair demonstrated hemifacial atrophy after unilateral cervical sympathectomy in young rats.²⁶ Evidence for a neurovascular defect involved in the pathogenesis of hemifacial atrophy was

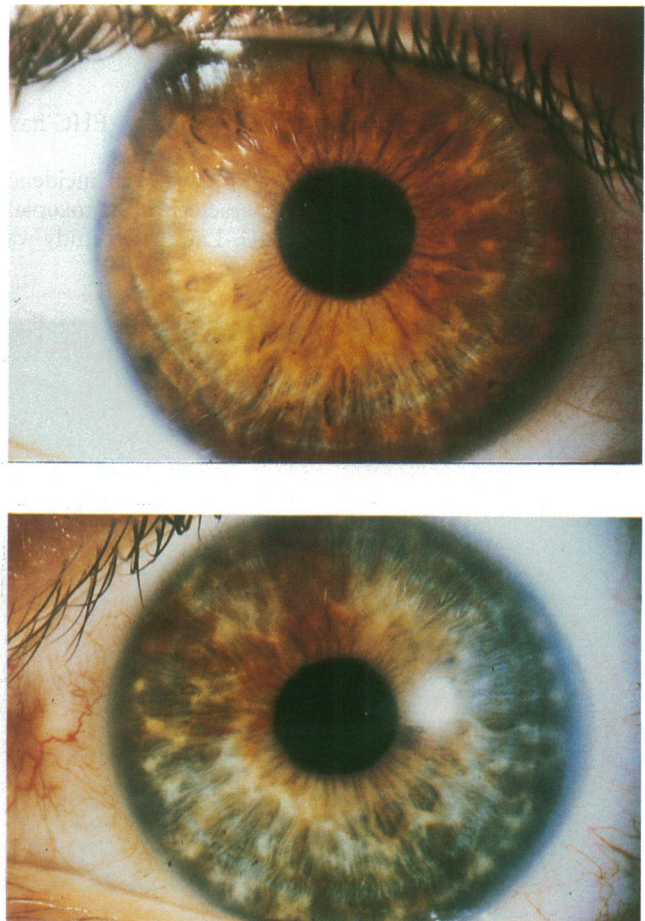


Figure 1 Eyes of a patient with Fuchs' heterochromic cyclitis. (A) Normal eye, (B) cyclitic eye.

found in a recent electron microscopic study on human skin biopsy specimens.²²

The iris hypopigmentation in FHC and Horner's syndrome may be due to a common factor: a defective production of melanin granules caused by inadequate function of the adrenergic nerves. Furthermore, defective adrenergic innervation of blood vessels in FHC may cause increased permeability of the blood-aqueous barrier with subsequent leaking of proteins, cells, and inflammatory mediators into the aqueous.

Hereditary theory

Because two types of heterochromia are dominantly hereditary, namely 'simple' uncomplicated heterochromia and heterochromia in Waardenburg syndrome, it was thought that all types of heterochromia, including FHC, were hereditary.²

In 1973, Loewenfeld and Thompson performed a review of 1500 cases with FHC and found only five families with two cases of FHC.² Dernouchamps found six familial cases in the 550 cases with FHC described by members of the IUSG.²⁸ The proportion of familial cases is thus very small and does not provide adequate proof for the hereditary theory in FHC. In 1956, Makley²⁹ described monozygotic twins who both developed FHC. Recently, another pair of monozygotic twins was reported, of which only one child had FHC.³⁰ Studies on HLA typing in patients with FHC have shown no significant deviation in the distribution of HLA-A or B antigens in FHC compared with normal healthy blood donors.^{31,32} The frequency of HLA-CW3 and HLA-DRW53 was, however, decreased in patients with FHC compared with healthy controls and a possible role for HLA-linked genetic factors in the pathogenesis was suggested.³² Further reports with larger series of patients are necessary to confirm this assumption.

Association with ocular toxoplasmosis

Three theories explaining the fundus lesions in FHC have thus far been proposed.

(1) In 1982, de Abreu *et al*³³ reported a high incidence (56.5%) of chorioretinal lesions characteristic of toxoplasmosis in their 23 patients with FHC. Later, this study was

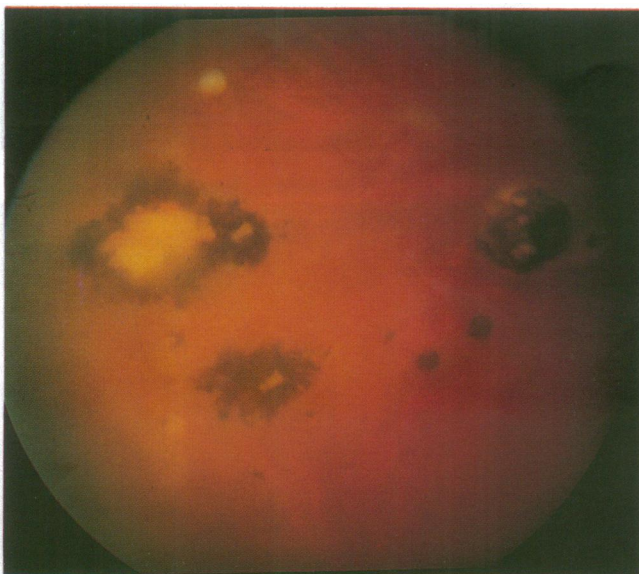


Figure 2 Fundus lesions were defined as characteristic for toxoplasmosis if they were one to three disc diameters in size, with a white centre and hyperpigmented borders, and flat or depressed. This patient with unilateral Fuchs' heterochromic cyclitis had such lesions in the ipsilateral eye.

confirmed by other authors.³⁴⁻³⁸ It was suggested that these fundus lesions were caused by a (previous) *Toxoplasma gondii* infection.³³ Until now, only few patients with FHC and active *Toxoplasma* retinochoroiditis have been described,^{33-35, 37, 39, 40} who truly support the association between FHC and ocular toxoplasmosis.

The reported prevalence of toxoplasmosis-like lesions in FHC varies considerably between the studies: 7.5 to 65%.³³⁻³⁸ This may be due to the fact that lesions in the peripheral retina are often missed in studies based on retrospective analysis. Furthermore, not all authors used the same criteria and some authors³⁵ did not even mention their definition of a 'toxoplasmosis-like' chorioretinal scar (Fig 2). Another explanation may be that the prevalence of *Toxoplasma* retinochoroiditis differs between populations⁴¹ as shown by a difference in prevalence of antibodies against *Toxoplasma*

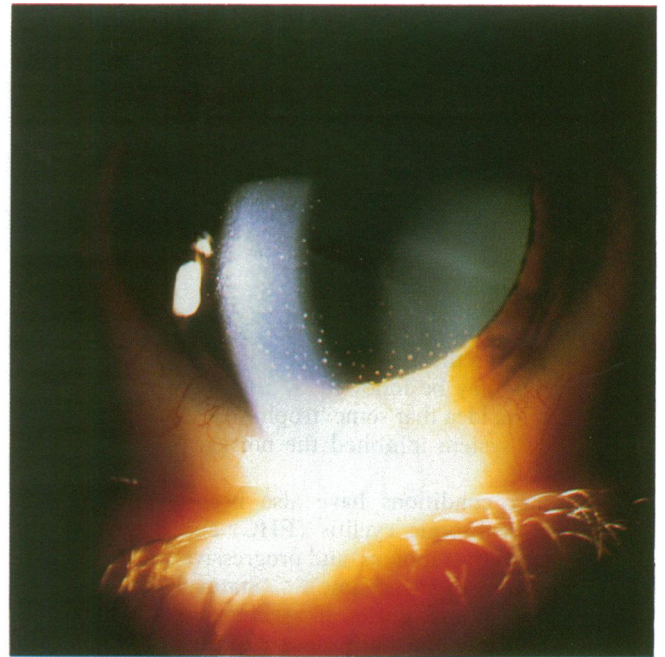

Fig 3A

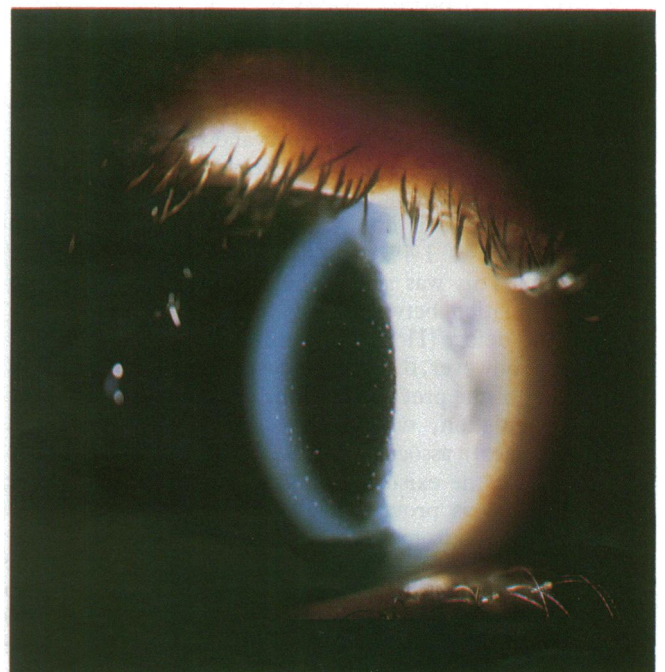


Fig 3B

Figure 3 (A and B) Characteristic small translucent keratic precipitates scattered on the entire endothelium.

gondii.⁴²⁻⁴⁴ Moreover, *Toxoplasma gondii* strains may vary in their virulence.⁴⁵ Therefore, it is important that a control group from the same population is studied simultaneously. This was done in four studies.³⁴⁻³⁶⁻³⁸ A significantly higher percentage of patients with FHC had chorioretinal scars consistent with ocular toxoplasmosis than these control groups.

In a recent study,³⁸ the association between FHC and toxoplasmosis-like scars could not be substantiated by laboratory tests for toxoplasmosis.³⁸ No active chorioretinal lesions, however, were present in the patients with FHC at the time of sampling.³⁸ Moreover, *Toxoplasma* serology has no definite diagnostic value for ocular toxoplasmosis, since in the general population a high prevalence of positive titres also exists. In addition, even in children with definite ocular toxoplasmosis a negative Sabin-Feldman dye test was sometimes encountered.

(2) Schwab³⁴ recently reported that in five of his 16 patients with FHC and toxoplasmosis-like lesions the typical corneal precipitates (Fig 3) were absent. Patients with ocular toxoplasmosis sometimes have clinical findings closely resembling those of FHC.³⁴⁻³⁷ Schwab therefore suggested that ocular toxoplasmosis can create a chronic condition that can resemble FHC, but not have the same pathogenesis.³⁴ This idea needs further investigation.

(3) In addition to toxoplasmosis-like scars, non-specific chorioretinal scars and histoplasmosis-like scars were found in patients with FHC.³⁶⁻³⁸⁻⁴⁷ Arffa and Schlaegel³⁶ described two patients with FHC who had fundus lesions characteristic of toxoplasmosis, but negative titres for toxoplasmosis in undiluted serum. They suggested that the chorioretinal lesions could result from autoimmunity against retinal or choroidal antigens.³⁶ In support of this hypothesis, La Hey *et al*⁴⁸ found that a significantly higher percentage of patients with FHC had a positive cellular autoimmune response to human retinal S antigen than healthy controls or other patients with anterior uveitis. However, no chorioretinal scars were seen in five out of six cases of FHC with a positive immune response to S antigen.⁴⁸ Probably the immune sensitisation against S antigen in these patients is a secondary autoimmune (epi-) phenomenon and does not cause the chorioretinal lesions. Recently, the presence of messenger RNA (mRNA) of S antigen was demonstrated in irides obtained from patients with uveitis but not from control irides.⁴⁹ This finding may indicate a possible role for S antigen in anterior segment inflammation and could account for the fact that some patients with FHC without chorioretinal scars had a positive cellular immune response to S antigen.

Vascular theory

The first vascular abnormality described in patients with FHC was the characteristic filiform haemorrhage (Amsler's sign) seen after anterior chamber paracentesis.⁵⁰ Later, iris fluorescein angiographic studies¹⁶⁻¹⁸ showed leakage from iris vessels and areas of ischaemia, associated with neovascularisation. Earlier, light microscopic studies had shown abnormal hyalinisation of the iris vessel walls, with narrowing of the vessel lumen.¹⁻⁶⁻⁵¹⁻⁵³

It was suggested that an immune complex vasculitis caused the vascular abnormalities in the iris.⁴ This was based on the detection of circulating immune complexes in the aqueous humour and serum of patients with FHC.⁵⁴⁻⁵⁵ However, an unusual technique to detect these immune complexes was used.⁵⁴ It is therefore necessary to confirm these findings with standard immune complex assays.

Patients with FHC are generally free of the more commonly encountered systemic manifestations of immune complex vasculitis, such as arthritis, glomerulonephritis, or scleritis. Moreover, FHC is usually a unilateral disease.

Thus, it seems more likely that intraocular factors may be responsible for the local formation of immune complexes in the iris vessel wall. As suggested by O'Connor,⁵¹ plasma cells demonstrated in the iris¹⁻²⁹⁻⁵¹⁻⁵³⁻⁵⁶⁻⁵⁷ may somehow escape the normally imposed regulation by T lymphocytes. An intraocular 'B cell factory' may result, which produces a large amount of immunoglobulins and low affinity antibodies with subsequent intraocular immune complex formation.⁵¹⁻⁵⁵

Recently, deposits of immunoglobulins and complement, indicating the presence of immune complexes, were found in the vessel walls of the iris from patients with FHC.⁵⁸ However, no light microscopic evidence for an inflammatory vascular process could be detected.⁵⁸ These immune deposits were also found in other types of uveitis, but not in the irides of patients with glaucoma without uveitis. Further studies are necessary to determine the pathogenetic role of these immune deposits and to find out whether they result from local formation or originate from the circulation.

Immunological theory

The hypothesis that a degradation of uveal tissue following an infection would cause an autoimmune reaction against this (altered) tissue, was one of the earliest immunological theories. It was based on the finding of anti-uvea autoantibodies at high concentrations in the aqueous humour of patients with FHC.⁵⁹ In a more recent study, however, no autoantibodies against human iris tissue could be demonstrated in any of the serum samples obtained from 27 patients with FHC.⁶⁰

In 1960, an increased level of the gammaglobulin fraction, which later appeared as a relative excess of IgG, was found in the aqueous humour of patients with FHC.⁶¹⁻⁶² Murray *et al*⁶³ confirmed these findings of intraocular IgG production. He also demonstrated oligoclonal IgG bands, mainly of the IgG1 subclass, in the aqueous humour of 57% of his patients with FHC. No oligoclonal IgG response was found in the aqueous humour of other patients with uveitis. Furthermore, Murray *et al* demonstrated a local production of the cytokine interleukin 6 (IL-6), in the aqueous humour of 63% of the patients with FHC, but also in 70% of the other types of uveitis.⁶⁴

In a recent immunohistochemical study⁵⁷ interleukin 2 receptor negative T helper and T suppressor lymphocytes, B lymphocytes, and plasma cells were demonstrated in four out of eight irides from patients with FHC. Similar findings, however, were also observed in patients with other types of uveitis.

Seventy per cent of all patients with FHC showed a cellular autoimmune response against a major corneal antigen (54 kDa; aldehyde dehydrogenase).⁶⁵ Autoantibodies against corneal epithelium were recently demonstrated in almost 90% of the patients with FHC.⁶⁰

No abnormalities have been detected in any of the following immunological parameters in the peripheral blood of patients with FHC: immunoglobulin G, IgA, IgM, rheumatoid factor, C reactive protein, antinuclear antibodies, anti-smooth muscle antibodies, antigestric parietal cell antibodies, antilens antibodies, total lymphocyte count, total number of T cells, number of helper or suppressor T cells, or soluble serum ICAM-1, a circulating adhesion molecule.⁵⁵⁻⁶⁶⁻⁶⁸

Authors' hypothesis

FHC (Fig 4) seems a complex disease with various clinical features and multiple causes. The high incidence of cellular immunity⁶⁵ and humoral immunity⁶⁰ against corneal antigens may be associated with the typical keratic precipitates. It is tempting to speculate that the diffuse scattering of these keratic precipitates on the corneal endothelium in FHC represents (cellular) immune responses to (a) corneal anti-

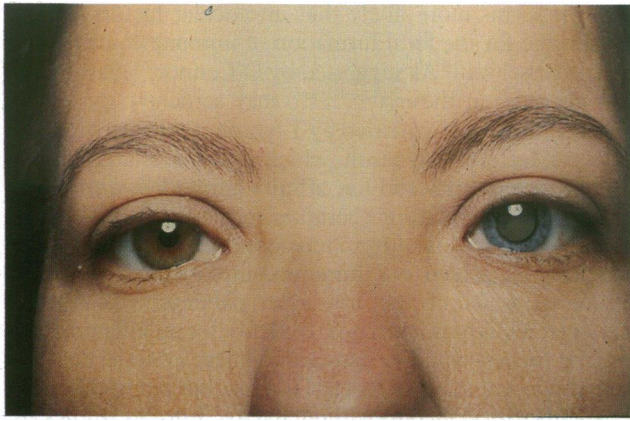

Figure 4 Patient with Fuchs' heterochromic cyclitis and cataract of the left eye.

gen(s), in comparison with the usually inferior distribution of keratic precipitates in other forms of anterior uveitis. Indeed, as reported by Foets,^{69,70} human corneal endothelial cells should be considered as 'active' immunomodulating cells because of their ability to express MHC class II antigens and immune adhesion molecules. The sensitisation against retinal S antigen found in patients with FHC,⁴⁸ is even more conspicuous. Arrocker⁷¹ and Murray⁷² independently demonstrated that a high proportion of patients with FHC had an increased level of interleukin 2 receptor (IL-2R), a marker of (T) lymphocytic activation. Such a high incidence of cellular autoimmunity against various ocular antigens is remarkable.

One has to keep in mind that the eye is an immunologically privileged site, as shown by the ACAID (anterior chamber associated immune deviation) phenomenon: when soluble antigens are placed within the anterior chamber, a systemic antigen specific inhibition of delayed type hypersensitivity (DTH) to this antigen occurs.⁷³ Also within the anterior chamber itself, expression of cell mediated immunity of

DTH is strongly inhibited.^{74,75} The aqueous humour in normal eyes seems to be a powerful inhibitor of certain aspects of antigen driven T cell function, a capacity which may be largely conferred by the cytokine transforming growth factor β (TGF- β) secreted by iris and ciliary body parenchymal cells, and the neuropeptides, α -melanocyte stimulating hormone (α -MSH) and vasoactive intestinal peptide (VIP), produced by ocular neurons.^{76,77} Intracameral injections of a subinflammatory dose of interferon γ (IFN- γ), a cytokine that antagonises TGF- β , resulted in a disturbance of this immunosuppressive microenvironment and the development of severe intraocular inflammation.⁷⁸

In FHC, this immunosuppressive mechanism (ACAID), may be diminished; the increased lymphocytic sensitisation found in these patients points in this direction. Perhaps the concentration of the immunosuppressive TGF- β is decreased as a result of the atrophic process of the iris, also affecting the parenchymal cells.

Until now, also in studies using modern sensitive techniques, no specific (immuno-) histopathological abnormalities were found in the irides of patients with FHC.^{57,58} The detection of oligoclonal IgG bands in the aqueous humour of these patients⁶³ seems to be the only specific (immunological) abnormality detected until now. It may imply that a small number of intraocular B cells is stimulated by an (as yet unidentified) specific antigen, which may be part of an infectious agent or an intraocular autoantigen. This B cell stimulation may be the result of interleukin 6 (IL-6) production, demonstrated in the aqueous humour of patients with FHC.⁶⁴

It was found that IL-6 significantly upregulated the expression of ICAM-1 on skin melanocytes, an adhesion molecule involved in the process of antigen presentation.⁷⁹ Skin melanocytes have recently been shown to be capable of processing and presenting antigenic peptide fragments (after stimulation with IFN- γ) to cytotoxic T cell clones in an MHC-II restricted manner.⁸⁰ Such melanocytes may thus

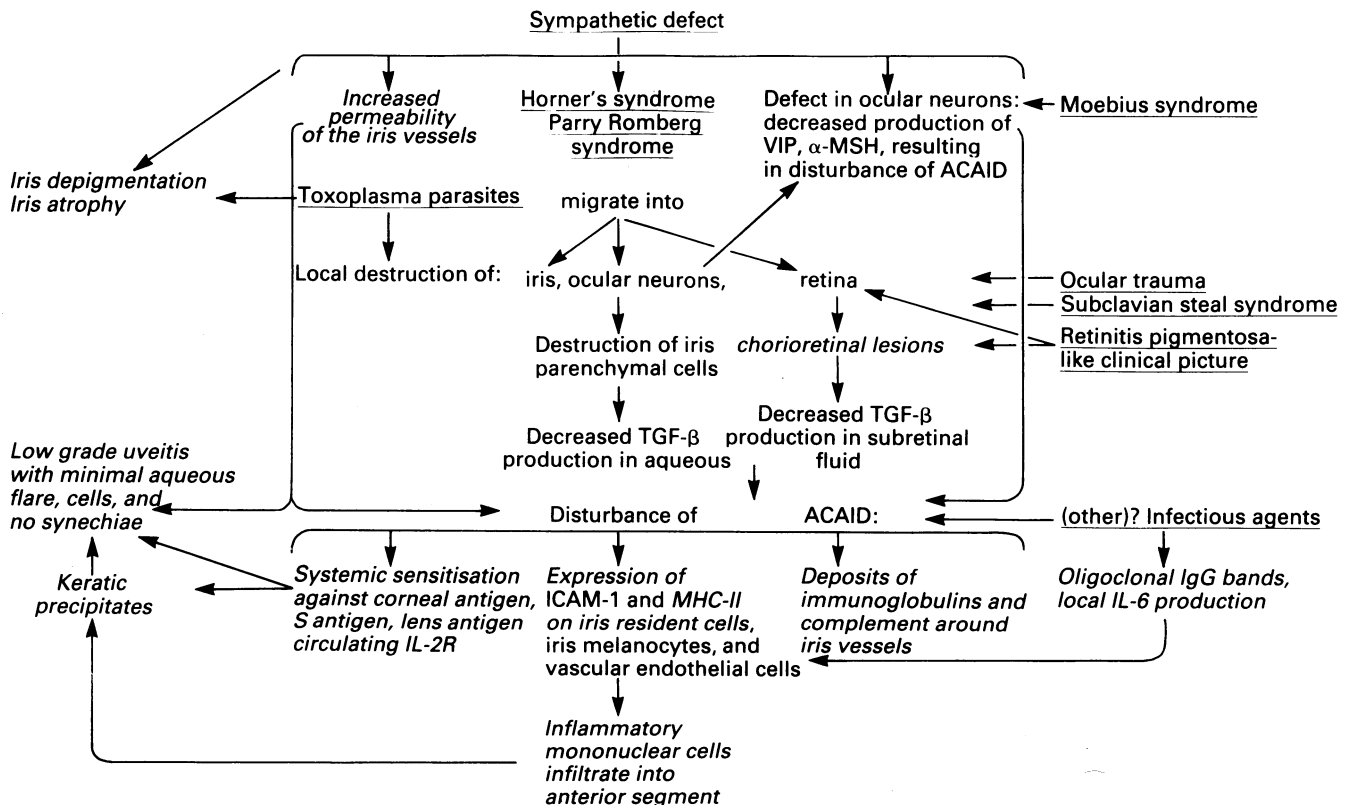


Figure 5 Schematic diagram of Fuchs' heterochromic cyclitis as secondary phenomenon. Underlined are the causes which may lead to Fuchs' heterochromic cyclitis. Clinical and (immuno)histopathological findings in this eye disease are in italic. All other findings and pathogenetic mechanisms in this diagram are hypothetical.

function as target cells in T cell mediated (auto)immune reactions, leading to the destruction of these melanocytes with areas of depigmentation of the skin, as may be seen in vitiligo, a presumed autoimmune disease.⁸⁰ Whether autoimmune reactions against melanocytes play a role in FHC has not yet been investigated.

Evidence accumulates that the iris hypopigmentation and increased vascular permeability of the iris vessels in FHC may be caused by inadequate function of adrenergic nerves.^{14 16-19 25 26} Such an adrenergic defect may be congenital or it may be secondary to an inflammatory or autoimmune process of the iris. No autoantibodies against iris tissue, however, could be demonstrated in patients with FHC.⁶⁰ The release of neuropeptides may be disturbed owing to a defect of the sympathetic nerve system. Subsequently, the function of (vascular) endothelial cells and the immunosuppressive microenvironment of the aqueous humour may be altered. Because the stromal melanocytes of the iris are derived from the neural crest, it is important to remark that TGF- β has been suggested to play a crucial role in the differentiation of neural crest cells into the connective tissues of the eye during embryogenesis.⁸¹

Via a complex pathway of a secondary (auto)immune response, a congenital *Toxoplasma gondii* infection may be responsible for the secondary development of FHC in a small subset of patients. Nussenblatt⁸² suggested that the inflammatory retinal response in ocular toxoplasmosis is, at least in part, autoimmune. Also, in FHC a secondary autoimmune response may play a role. When a mother is infected during pregnancy, the neurotrophic *Toxoplasma* parasites may migrate into the retina. In utero, in patients with FHC, the *Toxoplasma* parasites may also have migrated into the iris. Toxoplasmal cysts have been found in the iris.⁸³ By causing a local destruction of these tissues (iris, retina), a release of potent ocular antigens into the circulation may result, leading to a sensitisation against retinal (S) antigen(s) and/or iris antigens. A cellular autoimmune response to S antigen could be demonstrated in patients with FHC.⁴⁸ Whether a cellular immune response against iris antigens exists in patients with FHC has not been investigated. One can also imagine that if the *Toxoplasma* parasites have gained access to the iris during pregnancy, they may have altered the production of TGF- β and the neuropeptides α -MSH and VIP, by a local destruction of the iris and ocular neurons. This may lead to a disturbance of the immunosuppressive properties of the aqueous humour (ACAID) and subsequently the development of an anterior uveitis. Indeed, recently TGF- β was found to be decreased in experimental uveitis.⁸⁴

In addition to toxoplasmosis, FHC has been reported in combination with a retinitis pigmentosa-like clinical picture,⁸⁵⁻⁸⁷ ocular trauma,^{35 88} the subclavian steal syndrome,⁸⁹ hemifacial atrophy,^{9-11 90} Horner's syndrome,¹²⁻¹⁴ and Moebius syndrome.⁹¹ The term FHC is merely descriptive; there is (still) no diagnostic test for this eye disease. Moreover, it is hardly likely that the clinical 'syndrome' of FHC has a single aetiology. Many pathogenetic mechanisms have been proposed, which all made sense in some aspects. FHC may have multiple causes. A number of different abnormalities may trigger the eye, which may have only a limited set of uveoretinal responses, to react in a particular (path)way, yielding the clinical end state of FHC. Such a stimulus may be immunological, infectious, or a combination of both. It may cause the release of potent autoantigens, leading to a common pathway of a secondary autoimmune uveitis that becomes self perpetuating. FHC is therefore probably a secondary phenomenon with a spectrum of clinical features and multiple causes (Fig 5).

E LA HEY
A KIJLSTRA

Department of Ophthalmology-Immunology,
The Netherlands Ophthalmic Research Institute,
Amsterdam

E LA HEY
P T V M DE JONG

Department of Ophthalmology,
Erasmus University,
Rotterdam

A KIJLSTRA

Department of Ophthalmology,
University of Amsterdam,
The Netherlands

- Fuchs E. Ueber komplikationen der heterochromie. *Z Augenheilkd* 1906; 15: 191-212.
- Loewenfeld IE, Thompson HS. Fuchs' heterochromic cyclitis: a critical review of the literature. II. Aetiology and mechanism. *Surv Ophthalmol* 1973; 17: 2-61.
- Bistis J. La paralysie du sympathique dans l'etiology de l'heterochromie. *Arch Ophthalmol* 1912; 9: 631-2.
- Bremer F. Klinische untersuchungen zur aetiology der syringomyelie und 'status dysraphicus'. *Dtsch Z Nervenheilkd* 1926; 95: 1-103.
- Passow A. Hornersyndrom, heterochromie und status dysraphicus, ein symptomkomplex. *Arch Augenheilkd* 1933; 197: 1-51.
- Franceschetti A. Heterochromic cyclitis. *Am J Ophthalmol* 1955; 39: 50-8.
- Hollwich F. Zur differentialdiagnose der heterochromiezyklitis. *Klin Monatsbl Augenheilkd* 1963; 142: 129-39.
- Hollwich F. Heterochromia complicata Fuchs'. *Klin Monatsbl Augenheilkd* 1988; 192: 87-96.
- Jones NP. Fuchs' heterochromic uveitis: a reappraisal of the clinical spectrum. *Eye* 1991; 5: 649-61.
- Fulmek R. Hemiatrophia progressiva faciei (Romberg-syndrome) mit gleichzeitiger heterochromia complicata (Fuchs' syndrom). *Klin Monatsbl Augenheilkd* 1974; 164: 615-28.
- La Hey E, Baarsma GS. Fuchs' heterochromic cyclitis and retinal vascular abnormalities in progressive hemifacial atrophy. *Eye* 1993; 7: 426-8.
- Calmettes ML, Deodati R, Amalric P. Un cas d'association d'heterochromie de Fuchs' et de syndrome de Claude Bernard Horner. *Rev Oto-Neuro-Ophthalmol* 1953; 25: 399-400.
- Makley TA, Abbot K. Neurogenic heterochromia: report of an interesting case. *Am J Ophthalmol* 1965; 59: 927-8.
- Regenbogen LS, Naveh-Floman N. Glaucoma in Fuchs' heterochromic cyclitis associated with congenital Horner's syndrome. *Br J Ophthalmol* 1987; 71: 844-9.
- Hoang-Xuan T, Foster S, Jakobiec FA, Tauber J, de la Maza MS, Krebs W. Romberg's progressive hemifacial atrophy: an association with sclera melting. *Cornea* 1991; 10: 361-6.
- Saari M, Vourre I, Nieminen H. Fuchs' heterochromic cyclitis. A simultaneous bilateral fluorescein angiographic study of the iris. *Br J Ophthalmol* 1978; 62: 715-21.
- Bernsmeier H, Kluxen G, Friedburg D. Irisangiographische befunde bei heterochromia complicata Fuchs'. *Ber Dtsch Ophthalmol Ges* 1981; 78: 49-51.
- Berger BB, Tessler HH, Kottow MH. Anterior segment ischemia in Fuchs' heterochromic cyclitis. *Arch Ophthalmol* 1980; 98: 499-501.
- Melamed S, Lahav M, Sandbank U, Yassur Y, Ben-Sira I. Fuchs' heterochromic iridocyclitis: an electron microscopic study of the iris. *Invest Ophthalmol Vis Sci* 1978; 17: 1193-9.
- Laties AM, Lerner AB. Iris colour and relationship of tyrosinase activity to adrenergic innervation. *Nature* 1975; 225: 152-3.
- Laties AM. Specific neurohistology comes of age: a look back and a look forward. *Invest Ophthalmol Vis Sci* 1972; 11: 555-84.
- Ehinger B. Adrenergic nerves to the eye and to related structures in man and in the cynomolgus monkey (*Macaca irus*). *Invest Ophthalmol Vis Sci* 1966; 5: 42-52.
- Ringvold A. An electron microscopic study of the iris stroma in monkey and rabbit with particular reference to intercellular contacts and sympathetic innervation of anterior layer cells. *Exp Eye Res* 1975; 20: 349-65.
- Opin L, O'Donnel FE. Adrenergic influence on iris stromal pigmentation: evidence for alpha-adrenergic receptors. *Invest Ophthalmol Vis Sci* 1982; 23: 528-30.
- Beckers HJM, Klooster J, Vrensen GFJM, Lamers WPMA. Sympathetic innervation of the rat's eye: an electron microscopic autoradiographic tracing study. *Graefes Arch Clin Exp Ophthalmol* (in press).
- Moss ML, Cirkelair GJ. Progressive facial hemiatrophy following cervical sympathectomy in the rat. *Arch Oral Biol* 1960; 1: 254-8.
- Pensler JM, Murphy GF, Mulliken JB. Clinical and ultrastructural studies of Romberg's hemifacial atrophy. *Plast Reconstr Surg* 1990; 85: 669-74.
- Dernouchamps JP. Fuchs' heterochromic cyclitis: an IUSG study about 550 cases. In: Saari KM, ed. *Uveitis update*. Amsterdam: Elsevier, 1984: 129-35.
- Makley TA. Heterochromic cyclitis in identical twins. *Am J Ophthalmol* 1956; 41: 768-72.
- Jones NP, Read AP. Is there a genetic basis for Fuchs' heterochromic uveitis? Discordance in monozygotic twins. *Br J Ophthalmol* 1992; 76: 22-4.
- Saari M, Vourre I, Pakarinen A, Tilikainen A. Immunological and immunogenetic studies on Fuchs' heterochromic cyclitis. In: Shimity K, Oosterhuis JA, eds. *Concilium ophthalmologicum, Kyoto 1978. Int Congress series*. Amsterdam: Excerpta Medica, 1978: 971-3.
- De Bruyere M, Dernouchamps JP, Sokal G. HLA-antigens in Fuchs' heterochromic iridocyclitis. *Am J Ophthalmol* 1986; 102: 392-3.
- De Abreu ML, Belfort R, Hirata PS. Fuchs' heterochromic cyclitis and ocular toxoplasmosis. *Am J Ophthalmol* 1982; 93: 739-44.
- Schwab JR. The epidemiologic association of Fuchs' heterochromic iridocyclitis and ocular toxoplasmosis. *Am J Ophthalmol* 1991; 111: 356-62.
- Saraux H, Laroche L, Le Hoang P. Secondary Fuchs' heterochromic cyclitis: a new approach to an old disease. *Ophthalmologica* 1985; 190: 193-8.
- Arffa RC, Schlaegel TF. Chorioretinal scars in Fuchs' heterochromic iridocyclitis. *Arch Ophthalmol* 1984; 102: 1153-5.
- Pezzi PP, Niuuta A, Abdulaziz M, Paroli MP. Fuchs' heterochromic iridocyclitis and toxoplasmic retinochoroiditis. *Int J Ophthalmol* 1987; 1/2: 97-101.
- La Hey E, Rothova A, Baarsma GS, de Vries J, van Knapen F, Kijlstra A. Fuchs' heterochromic cyclitis is not associated with ocular toxoplasmosis. *Arch Ophthalmol* 1992; 110: 806-11.
- La Hey E, Rothova A. Fuchs' heterochromic cyclitis in congenital ocular toxoplasmosis. *Br J Ophthalmol* 1991; 6: 372-3.

- 40 La Hey E, Baarsma GS. Contralateral active ocular toxoplasmosis in Fuchs' heterochromic cyclitis. *Br J Ophthalmol* 1993; 77: 455-6.
- 41 Henderly DE, Gensler AJ, Smith RE, Rao NA. Changing patterns of uveitis. *Am J Ophthalmol* 1987; 103: 131-7.
- 42 van der Veen J, Polak MF. Prevalence of toxoplasma antibodies according to age with comments on the risk of prenatal infection. *J Hyg* 1980; 85: 165-74.
- 43 Holland GN, Engstrom RE. Ocular toxoplasmosis in the United States. In: Belfort R, Petrilli AMN, Nussenblatt R, eds. *World uveitis symposium*. Sao Paulo: Livraria Roca Ltda, 1988: 315-22.
- 44 Glasner PD, Silveira C, Kruszon-Moran D, Martins MC, Burnier M, Silveira S, et al. An unusually high prevalence of ocular toxoplasmosis in Southern Brazil. *Am J Ophthalmol* 1992; 114: 136-44.
- 45 Sibley LD, Boothroyd JC. Virulent strains of *Toxoplasma gondii* comprise a single clonal lineage. *Nature* 1992; 359: 82-5.
- 46 Loewer-Sieger DH, Rothova A, Koppe JG, Kijlstra A. Congenital toxoplasmosis, a prospective study based on 1821 pregnant women. In: Saari KM, ed. *Uveitis update*. Amsterdam: Elsevier, 1984; 203-7.
- 47 Tabbut BR, Howard HT, Williams D. Fuchs' heterochromic iridocyclitis in blacks. *Arch Ophthalmol* 1988; 106: 1688-90.
- 48 La Hey E, Broersma L, van der Gaag R, Baarsma GS, Rothova A, Kijlstra A. Does S-antigen play a role in Fuchs' heterochromic cyclitis? *Br J Ophthalmol* 1993; 77: 436-9.
- 49 Chan CC, Li O, Kiuchi T, Shinohara T, Nussenblatt RB. Detection of the mRNA of S-antigen from irises of uveitic patients. *Invest Ophthalmol Vis Sci* 1991; 32: 96.
- 50 Amsler M, Verrey F. Heterochromie de Fuchs' et fragilité vasculaire. *Ophthalmologica* 1946; 111: 177-81.
- 51 O'Connor GR. Doane lecture: heterochromic iridocyclitis. *Trans Ophthalmol Soc UK* 1985; 104: 219-31.
- 52 Goldberg MF, Erozan YS, Duke JR, Frost JK. Cytopathologic and histopathologic aspects of Fuchs' heterochromic iridocyclitis. *Arch Ophthalmol* 1965; 74: 604-9.
- 53 Wobman P. Die heterochromiecyklitis Fuchs'. Elektronenmikroskopische studie von 9 irisbiopsien. *Graefes Klin Exp Ophthalmol* 1976; 199: 167-78.
- 54 Dernouchamps JP, Vaerman JP, Michiels J, Masson P. Immune complexes in the aqueous humour and serum. *Am J Ophthalmol* 1977; 24-31.
- 55 Murray PI, Dinning WJ, Rahi AHS. Immune responses in heterochromic cyclitis. In: Secchi AG, Fregona J, eds. *Modern trends in immunology and immunopathology of the eye*. Milan: Mason Publishing, 1989; 295-7.
- 56 McCartney ACE, Bull TB, Spalton DJ. Fuchs' heterochromic cyclitis: an electron microscopy study. *Trans Ophthalmol Soc UK* 1986; 105: 324-9.
- 57 Murray PI, Mooy CM, Visser-de Jong E, Baarsma GS, de Vries J, de Jong PTVM, et al. Immunohistochemical analysis of iris biopsy specimens from patients with Fuchs' heterochromic cyclitis. *Am J Ophthalmol* 1990; 109: 394-9.
- 58 La Hey E, Mooy CM, Baarsma GS, de Vries J, de Jong PTVM, Kijlstra A. Immune deposits in iris biopsy specimens from patients with Fuchs' heterochromic iridocyclitis. *Am J Ophthalmol* 1992; 113: 75-80.
- 59 Remky H. Auto-antigens, facteurs iridogènes de l'iritis. *Bull Mem Soc Fr Ophthalmol* 1965; 78: 401-11.
- 60 La Hey E, Baarsma GS, Rothova A, Broersma L, van der Gaag R, Kijlstra A. High incidence of corneal epithelium antibodies in Fuchs' heterochromic cyclitis. *Br J Ophthalmol* 1988; 72: 921-5.
- 61 Francois J, Rabae M. Microelectrophoresis on agar of normal and pathological aqueous humour. *Arch Ophthalmol* 1960; 63: 836-49.
- 62 Dernouchamps JP. The proteins of the aqueous humour. *Doc Ophthalmol* 1982; 53: 193-248.
- 63 Murray PI, Hoekzema R, Luyendijk L, Konings S, Kijlstra A. Analysis of aqueous humour immunoglobulin G in uveitis by enzyme-linked immunosorbent assay, isoelectric focusing, and immunoblotting. *Invest Ophthalmol Vis Sci* 1990; 31: 2129-35.
- 64 Murray PI, Hoekzema R, van Haren MAC, de Hon FD, Kijlstra A. Aqueous humour interleukin-6 levels in uveitis. *Invest Ophthalmol Vis Sci* 1990; 5: 917-20.
- 65 van der Gaag R, Broersma L, Rothova A, Baarsma GS, Kijlstra A. Immunity to a corneal antigen in Fuchs' heterochromic cyclitis patients. *Invest Ophthalmol Vis Sci* 1989; 30: 443-8.
- 66 Murray PI, Dinning WJ, Rahi AHS. T-lymphocyte subpopulations in uveitis. *Br J Ophthalmol* 1984; 68: 746-9.
- 67 Murray PI. Serum autoantibodies in uveitis. *Br J Ophthalmol* 1986; 70: 266-8.
- 68 Arrock-Mettinger E, Steurer-Georgiew L, Steurer M, Huber-Spitzky V, Hoesl E, Grabner G, et al. Circulating ICAM-1 levels in serum of uveitis patients. *Curr Eye Res* 1992; 11 (suppl): 161-6.
- 69 Foets BJJ, van den Oord JJ, Billiau A, van Damme J, Missotten L. Heterogeneous induction of MHC class II antigens on corneal endothelium by IFN- γ . *Invest Ophthalmol Vis Sci* 1991; 32: 341-5.
- 70 Foets BJJ, van den Oord JJ, Volpes R, Missotten L. In situ immunohistochemical analysis of cell adhesion molecules on human corneal endothelial cells. *Br J Ophthalmol* 1992; 76: 205-9.
- 71 Arock-Mettinger E, Asenbauer T, Ulbrich S, Grabner G. Serum interleukin receptor levels in uveitis. *Curr Eye Res* 1990; 9 (suppl): 25-9.
- 72 Murray PI, Young DW. Soluble interleukin-2 receptor in retinal vasculitis. *Curr Eye Res* 1992; 11 (suppl): 193-5.
- 73 Streilein JW, Niederkorn JY, Shaddock JA. Systemic immune unresponsiveness induced in adult mice by anterior chamber presentation of minor histocompatibility antigens. *J Exp Med* 1980; 152: 1121-5.
- 74 Streilein JW. Immune regulation and the eye: a dangerous compromise. *FASEB J* 1987; 1: 199-208.
- 75 Neiderkorn JY. Immune privilege and immune regulation in the eye. *Adv Immunol* 1990; 48: 191-226.
- 76 Streilein JW, Wilbanks GA, Taylor A, Cousins SW. Eye-derived cytokines and the immunosuppressive intraocular micro-environment. A review. *Curr Eye Res* 1992; 11 (suppl): 41-7.
- 77 Taylor AW, Streilein JW, Cousins SW. Neuropeptides contribute to the immunosuppressive activity of aqueous humour. *Invest Ophthalmol Vis Sci* 1993; 34: 903.
- 78 Cousins SW, Trattler WB, Streilein JW. Immune privilege and suppression of immunogenic inflammation in the anterior chamber of the eye. *Curr Eye Res* 1991; 10: 287-97.
- 79 Kirnbauer R, Charvat B, Schauer E, Kock A, Urbanski A, Forster E, et al. Modulation of intercellular adhesion-molecule-1 expression on human melanocytes and melanoma cells: evidence for a regulatory role of IL-6, IL-7, TNF- β and UVB light. *J Invest Dermatol* 1992; 98: 320-6.
- 80 Le Poole C, Mutis T, van den Wijngaard RMJGJ, Westerhof W, Ottenhof T, de Vries RRP, et al. A novel, antigen presenting function of melanocytes and its possible relation to hypopigmentary disorders. (Submitted for publication.)
- 81 Tripathi BJ, Tripathi RC, Livingston AM, Borisuth NSC. The role of growth factors in the embryogenesis and differentiation of the eye. *Am J Ophthalmol* 1991; 192: 442-71.
- 82 Nussenblatt RB. Uveitis. In: Nussenblatt RB, Palestine AG, eds. *Fundamentals and clinical practice*. Chicago: Year Book Medical Publishers, 1989.
- 83 Rehder JR, Burnier M, Pavesio CE, Kim MK, Riguero M, Petrilli AM, et al. Acute unilateral toxoplasmic iridocyclitis in an AIDS patient. *Am J Ophthalmol* 1988; 106: 740-1.
- 84 Rocha G, Baines MG, Deschenes J, Duclos AJ, Anteck E. Transforming growth factor- β levels in aqueous humour during experimentally induced uveitis. *Ocular Immunol Inflamm* 1994 (in press).
- 85 Francois J, Mastilovic B. L'heterochromie de Fuchs' associee aux heredo-degenerescences chorioiretiennes. *Ann Oculist* 1961; 94: 385-96.
- 86 Winkler A. Retinitis pigmentosa sine pigmento auf dem einen und retinitis pigmentosa mit heterochromie-iridocyclitis auf dem anderen auge. *Klin Monatsbl Augenheilkd* 1940; 105: 594-600.
- 87 Vourre I, Saari M, Tilikainen I, Rasanen O. Fuchs' heterochromic cyclitis associated with retinitis pigmentosa: a family study. *Can J Ophthalmol* 1979; 14: 10-6.
- 88 Vadot E. Cyclite heterochromique de Fuchs post-traumatique. *Bull Soc Ophthalmol Fr* 1981; 81: 665-7.
- 89 Donoso LA, Eiferman RA, Magargal LE. Fuchs' heterochromic cyclitis associated with subclavian steal syndrome. *Ann Ophthalmol* 1981; 13: 1153-5.
- 90 Sugar HS, Banks TL. Fuchs' heterochromic cyclitis associated with facial hemiatrophy (sklerodermie en coupe de sabre). *Am J Ophthalmol* 1964; 57: 627-32.
- 91 Huber A, Kraus-Mackiw E. Heterochromiezyklitis Fuchs bei Moebius syndrom. *Klin Monatsbl Augenheilkd* 1981; 178: 182-5.