

# External beam radiotherapy for retinoblastoma: I Whole eye technique

J L Hungerford, N M G Toma, P N Plowman, J E Kingston

## Abstract

**A retrospective analysis has been performed of the results of external beam radiotherapy for retinoblastoma using a whole eye technique. Local tumour control has been assessed in a consecutive series of 175 eyes in 142 children all of whom received external beam radiotherapy as the primary treatment for retinoblastoma. Follow up ranged from 2 to 17 years (median 9 years). Tumour control rates have been analysed with respect to the Reese Ellsworth classification and the series includes eyes in groups I to V. Focal salvage therapy was given for persistent, recurrent, or new tumours after radiotherapy. Following whole eye radiotherapy alone, the overall ocular cure rate was 57%, though with salvage therapy 80% of eyes could be preserved.**

(*Br J Ophthalmol* 1995; 79: 109-111)

Retinoblastoma is a rare ocular neoplasm which accounts for only 3% of childhood cancer. Although enucleation remains the standard treatment for advanced unilateral retinoblastoma and for the worse eye in most bilateral cases, many eyes can now be preserved by conservative therapy. The methods employed include external beam radiotherapy, radiation brachytherapy using episcleral radioactive plaques, cryotherapy, and photocoagulation. Using various combinations of these conservative treatment methods, overall local tumour cure rates for the eye have ranged between 80% and 90% depending on the extent of tumour involvement.<sup>1-5</sup>

Until 1985 the whole eye was usually irradiated in Britain.<sup>2,6</sup> Since 1986 a reliable and reproducible lens sparing technique has become available which allows the whole retina to be treated without producing anterior segment side effects which include lagophthalmos, dry eye, and cataract.<sup>7-9</sup> The results of whole eye external beam radiotherapy have been analysed in order to make objective comparisons with those of the newer lens sparing technique and, in particular, to establish that it is safe to spare the anterior segment. A non-current series of patients treated by the whole eye technique up to 1985 has been chosen to eliminate bias of selection because all suitable tumours after that date received the lens sparing approach. Possible doubts about the tumour control status of retinoblastomas which had received other forms of treatment before radiotherapy have been eliminated by considering only those eyes for which irradiation was the primary treatment.

## Patients and methods

The case records have been reviewed of a consecutive series of children who received primary whole eye external beam radiotherapy for retinoblastoma between 1970 and 1985. All eyes which had undergone any form of prior focal treatment were excluded from the retrospective analysis. The indications for whole eye external beam radiotherapy were those described by Bedford.<sup>2</sup> Complete follow up data were available for all the children.

Before radiotherapy was given, all eyes were graded according to the Reese-Ellsworth classification<sup>10</sup> on the basis of binocular indirect ophthalmoscopic examination with scleral indentation performed under general anaesthesia.

When only one eye required treatment but the contralateral eye was to be retained, a direct anterior field was employed using special applicators mounted on a telecobalt machine (Fig 1).<sup>11</sup> When the contralateral eye had been removed, a lateral field was applied using a linear accelerator so that the exit beam travelled through the enucleated socket in preference to passing through the brain. When both eyes required external beam radiotherapy simultaneously, parallel opposed lateral portals were employed, again using a linear accelerator (Fig 2).<sup>11</sup> Three fractionation schedules were employed. Early in the study period children received 3500 cGy (35 Gy) in nine or 10 fractions over 21 days. Later treatments employed 3600 cGy in 12 fractions over 28 days. Towards the end of the study a tumour dose of 4000 cGy was given in 20 fractions over

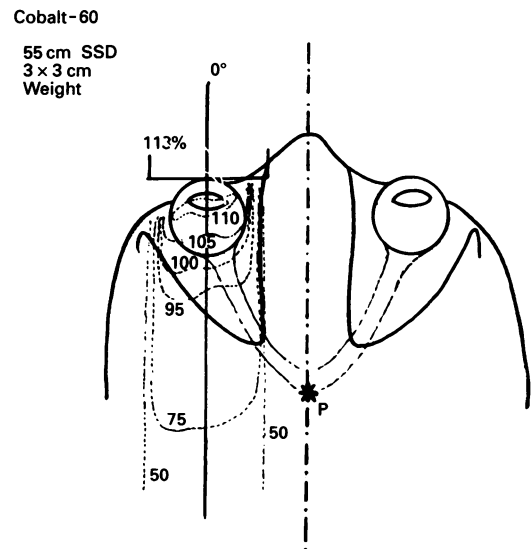


Figure 1 Isodose plot of anterior cobalt field used for whole eye external beam radiotherapy of one eye in retinoblastoma.

St Bartholomew's  
Hospital, London

Department of  
Ophthalmology  
J L Hungerford  
N M G Toma

Department of  
Radiotherapy  
P N Plowman

Department of  
Paediatric Oncology  
J E Kingston

Correspondence to:  
John Hungerford,  
Department of  
Ophthalmology, St  
Bartholomew's Hospital,  
West Smithfield, London  
EC1A 7BE.

Accepted for publication  
11 August 1994

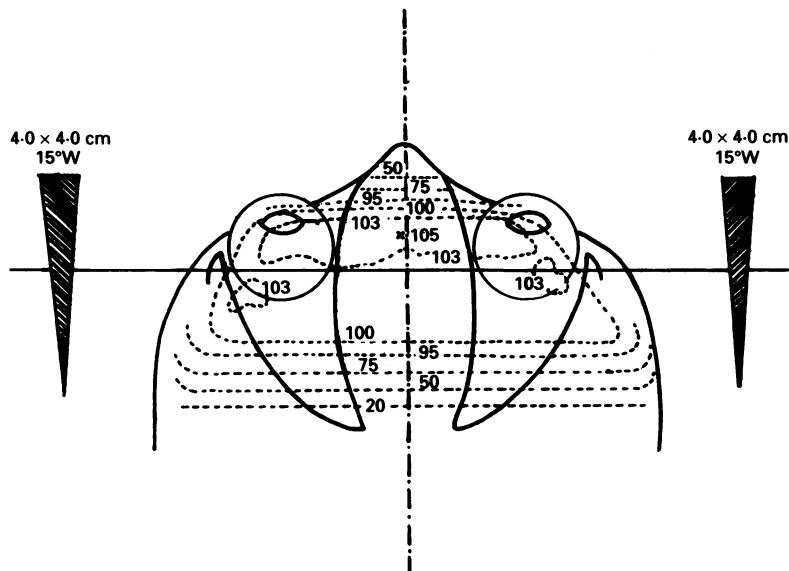


Figure 2 Isodose plot of horizontally opposed linear accelerator fields used for whole eye external beam radiotherapy of both eyes simultaneously in retinoblastoma.

28 days. During this later period, a few patients with very advanced tumour in an only eye received 4400 cGy in 22 fractions over 30 days.

Persistent tumours, recurrences, and new tumours after external beam radiotherapy were often amenable to focal treatments and in these circumstances the majority of eyes could be salvaged by various combinations of indirect xenon arc photocoagulation, triple freeze cryotherapy, and radioactive scleral plaque therapy. The results of whole eye external beam radiotherapy alone and those of the treatment combined with salvage focal therapy have been analysed separately.

### Results

During the period of the study 142 children underwent whole eye external beam radiotherapy as the primary treatment of their disease. A total of 175 eyes were irradiated. All of the treated children in this non-current series have been followed for more than 2 years with periods of follow up ranging from 2 to 17 years (median 9 years).

Figure 3 summarises the results of whole eye external beam radiotherapy alone. This treatment was successful in 99 eyes (57%). Treatment failure (failure to control tumour growth or local recurrence) was seen in 67 eyes (38%). New tumours developed in nine eyes (5%). Twenty two per cent of these new

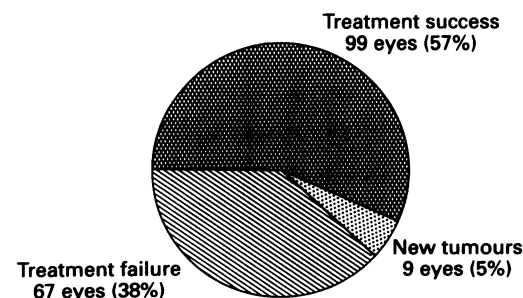


Figure 3 Initial results of whole eye external beam radiotherapy.

Table 1 Results of whole eye radiotherapy alone and in combination with salvage focal therapy

Reese-Ellsworth group	Success rate of primary radiotherapy	Salvage rate of failures and new tumours by focal therapy	Overall success rate including salvage by focal therapy
I	14/16 (88%)	2/2 (100%)	16/16 (100%)
II	31/55 (56%)	15/24 (62%)	46/55 (84%)
III	40/68 (59%)	16/28 (57%)	56/68 (82%)
IV	1/7 (14%)	2/6 (34%)	3/7 (43%)
V	13/29 (45%)	6/16 (37%)	19/29 (66%)
Total	99/175 (57%)	41/76 (54%)	140/175 (80%)

lesions arose anterior to the equator. In those eyes in which treatment failure and/or new tumour development occurred following primary whole eye radiotherapy, 78% were within the first year and 95% within the first 2 years after radiotherapy. Table 1 lists the initial success rate following whole eye radiotherapy alone, the salvage rate in those eyes requiring further treatment, and the overall success rate by Reese-Ellsworth group. Of the 76 eyes with persistent or new tumour, 41 (54%) could be salvaged by focal therapy so that, overall, 140 of the 175 eyes (80%) were retained. An only eye with an extensive recurrence in the vitreous received a second course of whole eye external beam radiotherapy but this eye was not saved.

Thirty five eyes (20%) required enucleation. Most (32 out of 35) were removed because of failure of both external beam radiotherapy and salvage treatment. Three eyes with satisfactory tumour control required enucleation for neovascular glaucoma secondary to radiation related choroidoretinal ischaemia. All had received their radiotherapy in nine or 10 fractions. In each case, histopathological examination of the enucleated eye demonstrated no evidence of active tumour. Table 2 lists the overall success rate of external beam radiotherapy alone for each of the fractionation schedules.

All of the 140 eyes retained following treatment by the whole eye technique developed cataract requiring lens aspiration within 2 years of radiotherapy.

### Discussion

The present study analyses the results of whole eye external beam radiotherapy used as the primary treatment modality for retinoblastoma. The results of focal salvage therapy are also analysed but none of the children received any other form of treatment before their radiotherapy. This study format was chosen to ensure that valid comparisons could be made subsequently between the results of whole eye external beam radiotherapy and those of a parallel study of lens sparing external beam radiotherapy.<sup>12</sup>

Table 2 Effects of radiation dose and fractionation on response

Radiation dose and fractionation	Tumour control rate after primary whole eye radiotherapy alone
3500 cGy in 9 or 10 fractions	51%
3600 cGy in 12 fractions	57%
4000 to 4400 cGy in 20 fractions	64%

Table 3 Comparison of reported eye preservation rates with results of present study

Reese-Ellsworth group	Eye preservation rate		
	New York <sup>3</sup> 1965-72 Follow up 3-8 years	Essen <sup>5</sup> 1973-7 Follow up 0-5 years	London 1970-85 Follow up 2-17 years
I	91% (39/43)	100% (2/2)	100% (16/16)
II	83% (29/35)	94% (17/18)	84% (46/55)
III	82% (46/56)	86% (18/21)	82% (56/68)
IV	62% (13/21)	65% (11/17)	43% (3/7)
V	29% (22/75)	33% (1/3)	66% (19/29)

The end point of the present study is preservation of the eye.

Following whole eye external beam radiotherapy, local tumour control was achieved in most but not in all eyes. There were several possible reasons for failure to achieve or sustain local tumour control. True failure occurred when one or more tumours failed to regress following treatment or when apparently regressed tumours subsequently recurred. In some eyes the treated tumours were controlled but new lesions developed. These were not strictly failures but were classified as such for the purposes of this study. Similarly, eyes lost from side effects were classified as failures. Most retinoblastomas which appear inert 9 months after external beam radiotherapy are probably cured<sup>4</sup> and the 2 year minimum follow up interval ensures complete or near complete ascertainment of failures.

The fractionation schedules of external beam radiotherapy changed substantially during the period of the study. Although the total dose increased with greater fractionation, the nominal standard dose formula was applied and the three dose prescriptions are equivalent in terms of their ability to kill tumour cells. Nevertheless, the fractionation of many of the early treatments in this series would now be regarded as suboptimal from the point of view of side effects: three eyes were lost from side effects attributable to insufficient fractionation.

There are no strictly comparable earlier studies of whole eye external beam radiotherapy.<sup>13</sup> Two large series have been reported but the treatment methods, follow up intervals, and the criteria by which a local cure is determined differ in each<sup>3,5</sup> and in the present study. However, most eyes in both earlier series were treated initially by megavoltage external beam radiotherapy and subsequently by focal methods where necessary. Allowing for the differences outlined, the overall results of treatment in the three groups of patients summarised in Table 3 are strikingly similar, though there were too few eyes in Reese-Ellsworth groups I and V in the Essen series and in group IV in the present series to draw valid conclusions. Group V patients in the present study fared better than in the New York series. This may have resulted from improvements in fractionation resulting in fewer eyes lost from complications of radiotherapy in the absence of active tumour.

Alternatively or additionally, more advanced group V eyes may have been selected for enucleation.

All of the 140 eyes which were saved developed significant cataract. Several authors<sup>6,14-19</sup> have reported the development of cataract in the majority of eyes, usually beginning about 18 months after treatment<sup>2</sup> and therefore rarely interfering with ophthalmoscopic assessment during the critical risk period for tumour recurrence.<sup>19</sup>

Overall, 80% of eyes in Reese-Ellsworth groups I to V were preserved by whole eye external beam radiotherapy either alone or in combination with salvage treatment. When comparing the results of lens sparing radiotherapy with those of the whole eye technique in terms of preserving the eye, it is important to recognise that the strict selection criteria applied when sparing the anterior segment, limit the use of the newer method mainly to eyes in Reese-Ellsworth groups I to III. The eye preservation rate for groups I to III after whole eye radiotherapy with or without salvage was 85% and it is this value which sets the standard by which the lens and anterior segment sparing technique must be judged.

- Sanders BM, Draper GJ, Kingston JE. Retinoblastoma in Great Britain 1969-80: incidence, treatment, and survival. *Br J Ophthalmol* 1988; 72: 576-83.
- Bedford MA, Bedotto C, MacFaul PA. Retinoblastoma: a study of 139 cases. *Br J Ophthalmol* 1971; 55: 19-27.
- Ellsworth RM. Retinoblastoma. *Mod Prob Ophthalmol* 1977; 18: 94-100.
- Egbert PR, Donaldson SS, Moazed K, Rosenthal AR. Visual results and ocular complications following radiotherapy for retinoblastoma. *Arch Ophthalmol* 1978; 96: 1826-30.
- Höpping W, Schmitt G, Havers W, Meyer-Schwickerath G. Die Therapie des Retinoblastoms. *Bericht Dtsche Ophthalmol Gesellschaft* 1979; 76: 143-9.
- Skeggs DBL, Williams IG. The treatment of advanced retinoblastoma by means of external irradiation combined with chemotherapy. *Clin Radiol* 1966; 17: 169-72.
- Schipper J, Tan KEWP, Van Peperzeel HA. Treatment of retinoblastoma by precision megavoltage radiation therapy. *Radiat Oncol* 1985; 3: 117-32.
- Schipper J. An Accurate and simple method for megavoltage radiation therapy of retinoblastoma. *Radiother Oncol* 1983; 1: 31-41.
- Harnett AN, Hungerford JL, Lambert GD, Hirst A, Darlison R, Hart BL, et al. Improved external beam radiotherapy for the treatment of retinoblastoma. *Br J Radiol* 1987; 60: 753-60.
- Reese AB, Ellsworth RM. The evaluation and current concept of retinoblastoma therapy. *Trans Am Acad Ophthalmol Otolaryngol* 1963; 67: 164-72.
- Hungerford J, Kingston J, Plowman N. Tumours of the eye and orbit. In: Vouite PA, Barrett A, Bloom HJG, Lemerle J, Neidhardt MK, eds. *Cancer in children*. Berlin: Springer-Verlag, 1986: 223-37.
- Toma NMG, Hungerford JL, Plowman PN, Kingston JE, Doughty D. External beam radiotherapy for retinoblastoma: II Lens-sparing technique. *Br J Ophthalmol* 1995; 79: 112-7.
- Schipper J. Retinoblastoma: a medical and experimental study. Thesis. University of Utrecht, 1980.
- MacFaul PA, Bedford MA. Ocular complications after therapeutic irradiation. *Br J Ophthalmol* 1970; 54: 237-47.
- Bedford MA, Freeman JE. Retinoblastoma. In: Bloom HJG, Lemerle J, Neidhardt MK, Vouite PA, eds. *Cancer in children*. Berlin: Springer-Verlag, 1975: 120.
- Migdal C. Bilateral retinoblastoma: the prognosis for vision. *Br J Ophthalmol* 1983; 67: 592-5.
- Howarth C, Meyer D, Hustu HO, Johnson WW, Shanks E, Pratt C. Stage-related combined modality treatment of retinoblastoma. Results of a prospective study. *Cancer* 1980; 45: 851-8.
- Freeman CR, Esseltine DL, Whitehead VM, Chevalier L, Little JM. Retinoblastoma: the case for radiotherapy and for adjuvant chemotherapy. *Cancer* 1980; 46: 1913-8.
- Footo RL, Garretson BR, Schomberg PJ, Buskirk SJ, Robertson DM, Earle JD. External beam irradiation for retinoblastoma: patterns of failure and dose-response analysis. *Int J Radiat Oncol Biol Physics* 1989; 16: 823-30.