

## PERSPECTIVE

## X linked retinoschisis

N D L George, J R W Yates, A T Moore

**Background**

Haas first described what is now acknowledged as being X linked retinoschisis (XLRS) nearly a century ago in a paper entitled 'Ueber das Zusammenvorkommen von Veränderungen der Retina und Choroidea'.<sup>1</sup> Accompanying his description of the disease in two males was a beautiful drawing of the typical radiating cystic maculopathy. The fact that subsequent authors failed to observe these macular changes and instead described the peripheral retinal features of the disease<sup>2-4</sup> is testimony perhaps to his shrewd powers of observation. Although Haas believed the retinal and choroidal changes were inflammatory in origin, Pagenstecher published a pedigree some 15 years later which showed an X linked pattern of inheritance.<sup>5</sup> The variable clinical manifestations of the disease are exemplified by the wide variety of names that have been ascribed to XLRS in the past. 'Anterior retinal dialysis',<sup>6</sup> 'neuroretinal disease in males',<sup>7</sup> 'congenital cystic detachment of the retina',<sup>2</sup> and 'congenital vascular veils'<sup>8</sup> were variously used to describe the condition before Jager coined the term X linked retinoschisis.<sup>9</sup> There are no other systemic associations and experience does not support Jager's assertion that all affected patients were 'from their early youth very difficult and extremely irritable persons'!

**Clinical features**

XLRS has been described worldwide in white,<sup>10</sup> black,<sup>11</sup> 12 and Asian people.<sup>13</sup> Although considered a rare condition it is much underdiagnosed and is among the commonest causes of juvenile macular degeneration.<sup>10</sup> The largest series of patients has been described in Finland where

XLRS had a carrier prevalence of 14 per 10 000 population<sup>14</sup> and it was considered to be the commonest X linked condition in that country before the increased recognition of fragile X syndrome.<sup>15</sup> XLRS is fully penetrant<sup>14</sup> and although retinal signs have been described in infants as young as 3 months of age,<sup>16</sup> 17 affected males usually present at school age when reading difficulties are detected. Less commonly the disorder may present in early infancy with squint, nystagmus, and bilateral highly elevated bullous retinoschisis often with haemorrhage within the schisis cavity or into the vitreous.<sup>18</sup> 19 The bullous peripheral retinoschisis may subsequently undergo spontaneous reattachment<sup>20</sup> leaving pigment demarcation lines and a visual prognosis that is often better than the initial appearance would suggest.<sup>21</sup>

Foveal schisis (Figs 1A and B) is characteristic of XLRS occurring in 98-100% of patients, according to Deutman.<sup>10</sup> Although macular changes are present in all affected patients others have found the typical foveal schisis to be present in only about 70% of patients.<sup>22</sup> Foveal schisis is most common in younger patients but pigment demarcation lines<sup>12</sup> 19 23 and macular colobomas<sup>3</sup> 24 25 are also seen. In older patients the typical radiating striae regress leaving a somewhat blunted foveal reflex.<sup>10</sup> This probably accounts for the normal maculae reported in some affected patients who nevertheless had reduced visual acuity.<sup>3</sup> 26 In patients over 50 years of age macular pigmentary changes and retinal pigment epithelial (RPE) atrophy are common (Fig 2). Some authors have described the coalescence of foveal microcysts to form macrocysts owing to the breakdown of intraretinal septae and have correlated this with progressive failure in vision.<sup>27</sup>

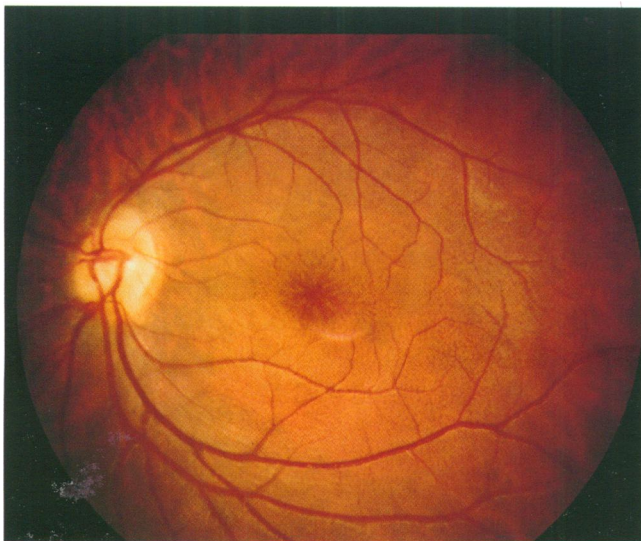


Fig 1A

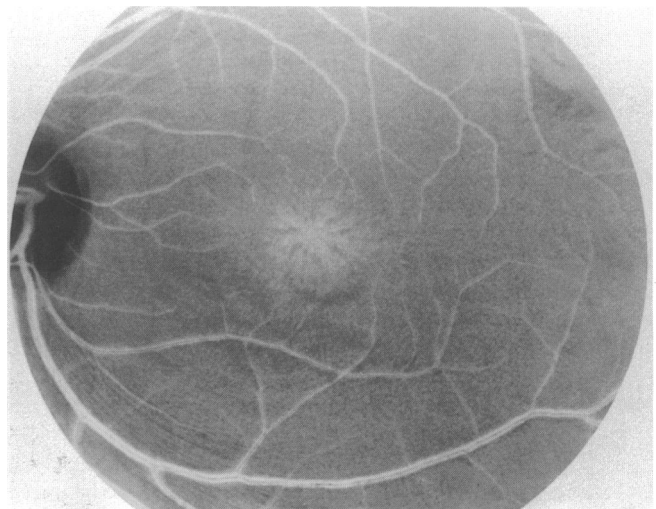
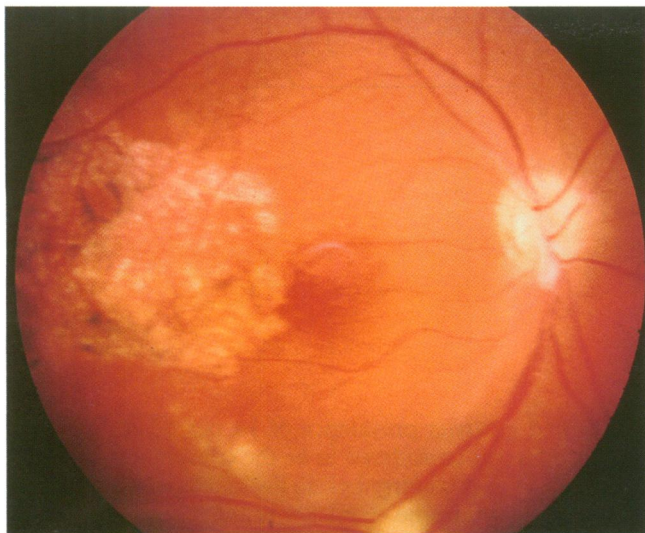
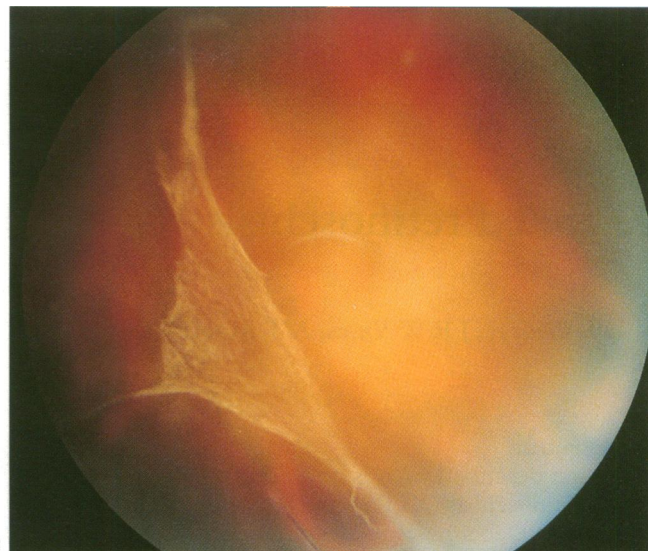

Fig 1B

Figure 1 (A and B) An 18-year-old male with X linked retinoschisis showing the typical foveal schisis. The superficial radiating striae are best appreciated when examined under red-free conditions.



**Figure 2** Pigment epithelial disruption at the right macula associated with advancing macular dystrophy. Typical foveal schisis was present in the left eye.



**Figure 4** A vitreous veil in X linked retinoschisis.

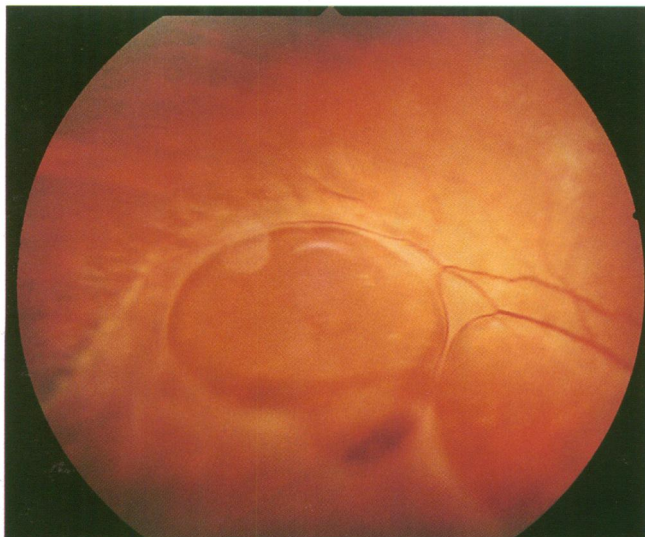
Peripheral retinoschisis is present in around 50% of patients.<sup>10 22</sup> The splitting occurs in the superficial layers of the retina and as such retinal vessels may lie in either the outer or inner leaf or cross from one to the other through the schisis cavity. The inner leaf of the schisis tends to fragment with time leaving large inner leaf breaks (Fig 3) and membranous remnants on the posterior hyaloid face, so called vitreous veils<sup>28 29</sup> (Fig 4). Often the inner leaf breaks are so large that only unsupported retinal vessels are seen coursing through the vitreous cavity. In contrast with senile retinoschisis, outer leaf breaks are rare in XLRS. Vascular changes are a prominent feature of the peripheral retina in XLRS: perivascular sheathing<sup>23</sup> (Fig 5), dendritiform patterns,<sup>30</sup> microvascular anomalies, and even neovascularisation<sup>31 32</sup> have been reported. A superficial silvery reflex arising from the vitreoretinal interface (Fig 6) may also be seen<sup>10 26</sup> and a tapetal reflex in association with the Mizuo phenomenon has been described.<sup>33</sup> Other unusual manifestations of the disease include dragging of the retinal vessels,<sup>34</sup> subretinal exudates,<sup>19</sup> and retinal flecks.<sup>35</sup> Refractive errors are common, usually hypermetropia<sup>22 36</sup> and strabismus is present in up to 29% of patients.<sup>10 22</sup>

Vitreous haemorrhage and retinal detachment are the most serious complications of XLRS. About 20% of patients develop retinal detachment,<sup>22 37 38</sup> although

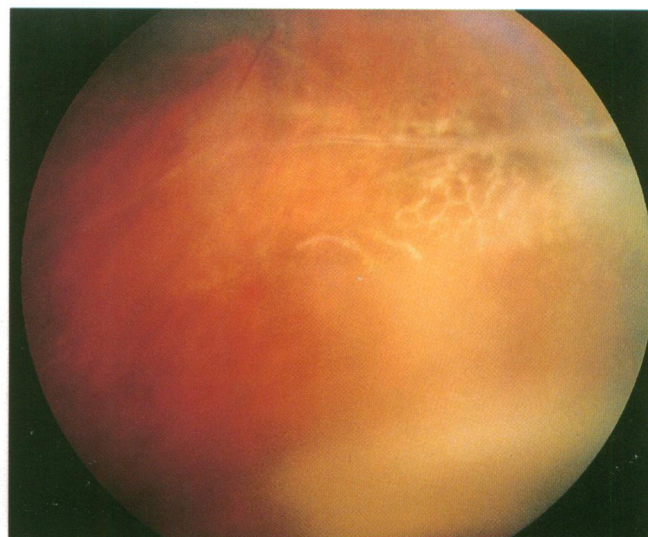
Deutman reported it in none of his patients.<sup>10</sup> Fluid may gain access to the subretinal space either through outer leaf breaks in areas of peripheral retinoschisis with inner leaf holes or through full thickness retinal tears following vitreous detachment.<sup>39</sup> Vitreous haemorrhage occurs in up to 40%<sup>37</sup> and usually results from rupture of unsupported retinal vessels or rarely from neovascularisation.<sup>32</sup> Neovascular glaucoma has occasionally been reported following vitreous haemorrhage<sup>40</sup> or retinal detachment<sup>39 41</sup> in XLRS.

#### Differential diagnosis

Foveal schisis is not confined to XLRS. It is also a feature of Goldmann-Favre syndrome but the pattern is much coarser than in XLRS.<sup>42</sup> The autosomal recessive inheritance, severe nyctalopia, pigmentary retinopathy, and reduced a- and b-waves on the electroretinogram (ERG) help to differentiate this condition.<sup>43</sup> Rarely foveal schisis may be a feature of rod-cone dystrophy<sup>44</sup> or be inherited as an autosomal dominant<sup>45</sup> or recessive<sup>46</sup> condition. In determining the mode of inheritance it is important to exclude consanguinity which has been the explanation for apparent male to male transmission and females manifesting the disease in XLRS families.<sup>28 47 48</sup> Females with Turner's syndrome (XO) may also manifest the disease.<sup>49</sup>



**Figure 3** Large inner leaf breaks in an area of peripheral retinoschisis. Unsupported retinal vessels are seen bridging the inner leaf break.



**Figure 5** Sheathed retinal vessels and dendritiform patterns in an area of shallow peripheral retinoschisis.

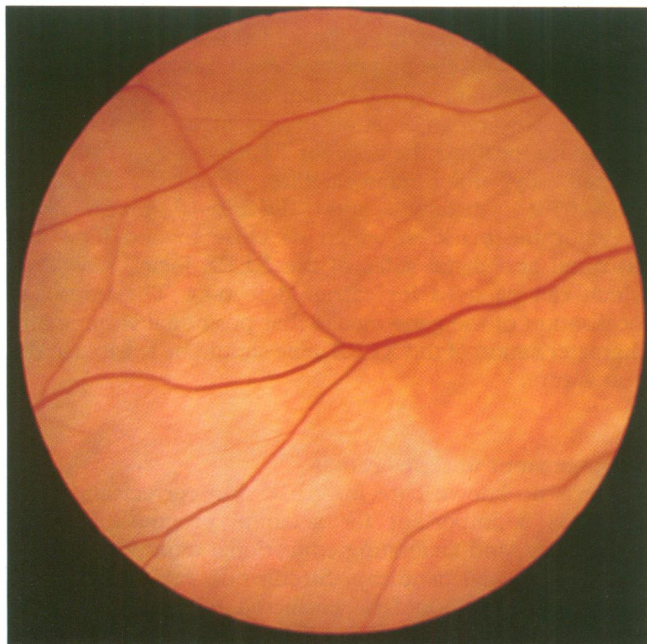


Figure 6 A superficial silvery reflex arising from the vitreoretinal interface in a 19-year-old male with X linked retinoschisis.

More usually, however, the foveal changes are subtle and the patient is misdiagnosed as having refractive or strabismic amblyopia. When other peripheral retinal features are more prominent the disease may be misdiagnosed as retinal dialysis, congenital infection, retinal vasculitis,<sup>50</sup> or other retinal dystrophies such as Stargardt's disease<sup>51</sup> and X linked retinitis pigmentosa. Usually a careful examination of other family members will reveal the presence of typical foveal schisis and the diagnosis of XLRS may be confirmed on electrophysiology.

### Pathology

There have been few good reports on histopathology in XLRS. Most have described the pathology in eyes enucleated because of rubeotic glaucoma<sup>52-53</sup> or leucocoria simulating retinoblastoma.<sup>54-55</sup> Two reports from eyes enucleated at post mortem are probably the most representative of the pathology.<sup>52-56</sup> Although these were from patients with definite X linked inheritance, both were in their sixth decade and as such may represent an advanced stage of the pathology. In XLRS the splitting occurs in the superficial layers, the inner limiting membrane (ILM) and nerve fibre layer (NFL),<sup>52-54</sup> in contrast with senile retinoschisis where the outer plexiform layer splits. Yanoff reported a child with a family history of XLRS, who presented with leucocoria and subsequently underwent enucleation to exclude retinoblastoma.<sup>54</sup> A retro-lental mass was composed of vitreous and fibrous tissue, to which was attached the inner leaf of the schisis cavity containing inner limiting membrane and remnants of nerve fibre layer. There are no reports on the pathology of the foveal schisis. In a report of a 60-year-old man, Manschott describes the macula as having a thickened, folded ILM with degeneration of the NFL and atrophy of the pigment epithelium.<sup>56</sup> Degeneration of the photoreceptors and RPE was thought to be secondary to the degenerative process in the adjacent neurosensory retina. An amorphous proteinaceous material, which was hyaluronidase negative, has been described within the schisis cavity, adjacent retina and around the blood vessels.<sup>52</sup> Electron microscopy demonstrated that this material contained filaments of similar periodicity to that of vitreous and was seen to blend with the basement membrane of Müller cells. Condon considered that the

intraretinal filaments are produced by defective Müller cells and that their extracellular accumulation leads to degeneration of these cells and subsequent schisis formation.<sup>52</sup> An accumulation of this material could perhaps account for the tense bullous retinoschisis cavities seen in infancy, which may subsequently discharge into the vitreous cavity through inner leaf breaks and result in flattening of the schisis.

### Electrophysiology and psychophysics

A characteristic reduction in the b-wave amplitude of the ERG is seen in all patients with XLRS.<sup>10 22 57 58</sup> The full field ERG abnormalities seen even in patients with schisis confined to the fovea, indicate widespread retinal dysfunction. Although the a-wave is normal in the early stages of the disease indicating that the photoreceptors are not primarily involved, older affected patients may show a reduction in the a-wave<sup>59</sup> and electro-oculogram (EOG)<sup>57</sup> reflecting secondary involvement of photoreceptors and RPE. Other conditions, such as congenital stationary nightblindness,<sup>60</sup> Duchenne muscular dystrophy,<sup>61 62</sup> and some cone dystrophies<sup>63</sup> exhibit a reduced b-wave but these conditions may be distinguished from XLRS by their clinical features and psychophysical tests.

Studies using intraretinal microelectrodes in the mud-puppy have demonstrated that the Müller cell has a similar intensity-response curve to the b-wave of the ERG.<sup>64</sup> Other components of the ERG that are known to arise from inner or middle retina are affected in XLRS: both the cone and rod oscillatory potentials (OPs) and the scotopic threshold response (STR) – a small electronegative response that is produced at stimuli so dim that the scotopic b-wave is not evident – are absent.<sup>58 65</sup> There is wide disparity between the reduction in electrophysiological and psychophysical responses: while the STR and b-wave may be profoundly reduced, absolute thresholds<sup>58 65</sup> and dark adaptation curves<sup>10 66</sup> are normal or only minimally elevated.

The psychophysical determination of rod-cone interaction has been of interest in identifying the site of the abnormality in XLRS. In normal individuals, the ability of cones to perceive flicker deteriorates as rods dark adapt.<sup>67</sup> Conversely, when dark adapted rods are exposed to dim light this function improves. This normal suppressive rod-cone interaction is thought to be mediated by postsynaptic feedback onto cones via horizontal cells and may be absent in some affected males<sup>66 68</sup> and obligate carriers of XLRS.<sup>69</sup> However, variable results have been reported in affected males<sup>66 70</sup> and the test seems to be dependent on the method used to demonstrate the rod-cone interaction.

### Pathophysiology

The underlying biological abnormality in XLRS is unknown. A primary defect within the Müller cell would concur with observations of histopathology<sup>52</sup> and electrophysiology.<sup>58</sup> The Müller cell, the principal glial cell of the retina, spans the full depth of the retina and is in intimate contact with photoreceptors and cells of the middle retinal layers.<sup>71</sup> Its basement membrane forms part of the ILM.<sup>72</sup> A defect in this cell may therefore be expected to affect neural processing in the middle and inner retinal layers as well as produce structural defects in the ILM and NFL. The Müller cell has been shown to be central to the migration and organisation of other retinal cells during development,<sup>73 74</sup> possibly via a Müller cell derived diffusible factor.<sup>75</sup> A gene defect in the Müller cell could therefore account for the whole host of structural and physiological abnormalities found in XLRS. Further evidence for a

Müller cell defect has been presented by de Jong *et al*<sup>33</sup>; they demonstrated the Mizuo phenomenon in five patients who had XLR5 and a tapetal reflex. A similar change in retinal colour had been shown on leakage of potassium ions from a microelectrode in the cat and monkey retina. In the normal situation light exposure results in hyperpolarisation of the photoreceptors and an increase in extracellular potassium ions, whereas in the dark adapted state the photoreceptors depolarise and the extracellular potassium ion concentration is lower.<sup>76</sup> The Müller cell transports the potassium ions from the outer retina into the vitreous cavity via its endfoot processes.<sup>77</sup> In XLR5 the inability of defective Müller cells to mop up the increased extracellular potassium ions on exposure to light could account for the tapetal reflex and Mizuo phenomenon observed in this disease.<sup>33</sup>

Other theories of pathophysiology have been proposed. Ewing *et al* postulated a vascular theory to the development of XLR5, based upon choroidal filling defects and slowing of the retinal circulation demonstrated by fluorescein angiography in some patients.<sup>78</sup> They proposed that the retinoschisis resulted from delayed development of the retinal and choroidal vasculature in which the retina outgrows its blood supply inferotemporally. The demonstration of capillary dropout in schitic as well as non-schitic areas of the retina has also supported this theory,<sup>79</sup> but it would not explain the presence of foveal schisis. Schepens believed that the vitreous plays an important role on the basis that peripheral retinoschisis tended to flatten following vitreous detachment.<sup>38</sup> It was thought that vitreous traction could cause splitting of the retina by inadequate growth or by shrinkage of an abnormally adherent vitreous gel.

#### Carrier state

In other X linked ocular diseases such as X linked ocular albinism, X linked retinitis pigmentosa, and choroideraemia, female heterozygotes may express some features of the disease.<sup>80</sup> This is due to the random inactivation of one X chromosome in every cell (lyonisation) so that the normal copy or the disease gene is inactivated in approximately half of all cells.<sup>81</sup> Although some female carriers of XLR5 have been reported to show signs of the disease<sup>25 26 82</sup> close scrutiny of these reports shows that many of the features reported such as macular degeneration, lattice, and senile retinoschisis are normal findings within the general population. Most large series have reported that there are no pathognomonic features of the carrier state<sup>10 83 84</sup> and the ERG, OPs, and STR are all normal in obligate carriers.<sup>65</sup> It is unclear why female heterozygotes do not express any clinical abnormalities, but it may be related to the subtlety of the retinal changes in affected males. In fact, Arden *et al* demonstrated that some female carriers do show a lack of normal rod-cone interaction on psychophysical testing<sup>69</sup> but this test has not proved to be of practical value. Carrier detection of XLR5 therefore currently relies on genetic linkage studies using polymorphic markers that flank the disease locus.

#### Molecular genetics

The locus for XLR5 has been localised to the Xp22 region of the distal short arm of the X chromosome with no evidence of genetic heterogeneity.<sup>15 17 85-88</sup> A multitude of highly polymorphic microsatellite markers has recently become available in this region.<sup>89-92</sup> These dinucleotide repeat sequences show great variation in length within the general population, which makes them ideal for tracking the disease gene for the purposes of carrier detection or

gene mapping. They have the added advantage that they can be used with the polymerase chain reaction (PCR), so that small amounts of DNA can be amplified rapidly for analysis. Key recombination events in two British pedigrees have localised the gene for XLR5 to a 2-3 cM region flanked by the microsatellite markers (DXS207, DXS1053) distally and DXS999 proximally.<sup>93</sup> Polymorphic markers, which lie close to and flank the proximal and distal sides of the XLR5 locus, now exist which can be used for carrier detection. The improved localisation of the gene means that positional cloning and characterisation of the XLR5 gene should be feasible in the near future.

#### Management and prognosis

There is no known cure for XLR5 but correct and early diagnosis is important for accurate prognosis, genetic counselling, and facilitating educational requirements in a child with visual handicap. Strabismus, refractive errors, and amblyopia should be corrected to maximise visual potential. Attempts to flatten peripheral retinoschisis by treating the outer leaf with laser photocoagulation have led to a high incidence of retinal detachment,<sup>22 41 94</sup> but pan-retinal photocoagulation has been used successfully to treat disc and peripheral new vessels.<sup>31 32</sup> Vitreous haemorrhage usually clears spontaneously, although vitrectomy may be required to reduce the risk of amblyopia in young children if the haemorrhage is particularly dense or persistent.<sup>39</sup> Variable success rates have been reported following scleral buckling for retinal detachment<sup>22 39</sup> and vitrectomy with internal tamponade offers the best outcome.<sup>39 95</sup> In one case internal tamponade of an outer leaf break was facilitated by the removal of the whole of the inner leaf of the schisis cavity without deleterious effect.<sup>39</sup>

Young patients affected by XLR5 show moderate visual impairment.<sup>96</sup> Visual acuity is usually in the 6/12 to 6/24 range<sup>14 22</sup> and some patients have been reported with normal acuity.<sup>10</sup> The disease is probably slowly progressive<sup>10 14</sup> but others report stable vision in uncomplicated cases.<sup>22 84</sup> Most patients, however, retain reasonable vision until their fifth or sixth decades when some deterioration does occur due to macular atrophy. Total blindness is an exception,<sup>10</sup> although Forsius reported that all patients over 70 years of age had a visual acuity of less than 6/60.<sup>14</sup>

#### Future

At present the underlying molecular defect in XLR5 is unknown. However, steady progress in mapping the Xp22 region should lead to the cloning and characterisation of the gene for XLR5. This would permit reliable carrier detection and will also enhance our understanding of the role of the Müller cell in the pathology of XLR5 leading to possible therapies in the future.

NDLG is grateful to the Guide Dogs for the Blind Association for their financial support.

N D L GEORGE

Department of Ophthalmology and  
Department of Clinical Genetics,  
Addenbrooke's NHS Hospital Trust, Cambridge

J R W YATES

Department of Clinical Genetics,  
Addenbrooke's NHS Hospital Trust,  
Cambridge and Department of Pathology,  
Cambridge University

A T MOORE

Department of Ophthalmology,  
Addenbrooke's NHS Hospital Trust,  
Cambridge and Moorfields Eye Hospital, London

Correspondence to: Mr N D L George, Department of Ophthalmology, St James's University Hospital, Beckett Street, Leeds LS9 7TF.

- 1 Haas J. Ueber das Zusammenkommen von Veränderungen der Retina und Choroidea. *Arch Augenheilkd* 1898; 37: 343-8.
- 2 Magnus JA. Case of retinal detachment in a child (cystic ?congenital). *Trans Ophthalmol Soc UK* 1951; 71: 728-30.
- 3 Sorsby A, Klein M, Gann JH, Siggins G. Unusual retinal detachment, possibly sex-linked. *Br J Ophthalmol* 1951; 35: 1-10.
- 4 MacRae A. Congenital vascular veils in the vitreous. *Trans Ophthalmol Soc UK* 1954; 74: 187-206.
- 5 Pagenstecher HE. Ueber eine unter dem Bilde der Natzhauterblösung verlaufende, erbliche Erkrankung der Retina. *Graefes Arch Ophthalmol* 1913; 86: 457-62.
- 6 Anderson JR. Anterior dialysis of the retina: disinsertion or avulsion at ora serrata. *Br J Ophthalmol* 1932; 16: 641-70; 705-27.
- 7 Thomson E. Memorandum regarding a family in which neuroretinal disease of an unusual kind occurred only in males. *Br J Ophthalmol* 1932; 16: 681-6.
- 8 Mann I, Macrae A. Congenital vascular veils in the vitreous. *Br J Ophthalmol* 1938; 22: 1-10.
- 9 Jager GM. A hereditary retinal disease. *Trans Ophthalmol Soc UK* 1953; 73: 617-9.
- 10 Deutman AF. Sex-linked juvenile retinoschisis. In: Deutman AF, ed. *The hereditary dystrophies of the posterior pole of the eye*. Assen, the Netherlands: Van Gorcum, 1971: 48-98.
- 11 Ide CH, Wilson RJ. Juvenile retinoschisis. *Br J Ophthalmol* 1973; 57: 560-2.
- 12 Constantaras AA, Dobbie JG, Choromokas EA, Frenkel M. Juvenile sex-linked recessive retinoschisis in a black family. *Am J Ophthalmol* 1972; 74: 1166-78.
- 13 Miyake Y, Miyake S, Yanagida K. X-chromosomal congenital retinoschisis. *Acta Soc Ophthalmol Jpn* 1981; 83: 97-112.
- 14 Forsius H, Krause U, Helve J, Vuopala V, Mustonen E, Vainio-Mattila B, et al. Visual acuity in 183 cases of X-chromosomal retinoschisis. *Can J Ophthalmol* 1973; 8: 385-93.
- 15 Alitalo T, Forsius H, Karna J, Frants RR, Eriksson AW, Wood S, et al. Linkage relationships and gene order around the locus for X-linked retinoschisis. *Am J Hum Genet* 1988; 43: 476-83.
- 16 Arklfeld DF, Brockhurst RJ. Vascularised vitreous membranes in congenital retinoschisis. *Retina* 1987; 7: 20-3.
- 17 Sieving PA, Bingham EL, Roth MS, Young MR, Boehnke M, Kuo C, et al. Linkage relationship of X-linked juvenile retinoschisis, with Xp22.1-p22.3 probes. *Am J Hum Genet* 1990; 47: 616-21.
- 18 Conway BP, Welch RB. X-chromosomal-linked juvenile retinoschisis with haemorrhagic retinal cyst. *Am J Ophthalmol* 1977; 83: 853-5.
- 19 Greven CM, Moreno RJ, Tasman W. Unusual manifestations of X-linked retinoschisis. *Trans Am Ophthalmol Soc* 1990; 88: 211-28.
- 20 Kawano K, Tanaka K, Murakami F, Ohba N. Congenital hereditary retinoschisis: evolution at initial stage. *Graefes Arch Clin Exp Ophthalmol* 1981; 217: 315-23.
- 21 George NDL, Yates JRW, Bradshaw K, Moore AT. Infantile presentation of X linked retinoschisis. *Br J Ophthalmol* 1995; 79: 653-7.
- 22 Kellner U, Brummer S, Foerster MH, Wessing A. X-linked congenital retinoschisis. *Graefes Arch Clin Exp Ophthalmol* 1990; 228: 432-7.
- 23 Balian JV, Falls HF. Congenital vascular veils in the vitreous. *Arch Ophthalmol* 1960; 63: 92-101.
- 24 Levy J. Inherited retinal detachment. *Br J Ophthalmol* 1952; 36: 626-36.
- 25 Sabates F. Juvenile retinoschisis. *Am J Ophthalmol* 1966; 62: 683-8.
- 26 Gieser EP, Falls HF. Hereditary retinoschisis. *Am J Ophthalmol* 1961; 51: 1193-200.
- 27 Harris GS, Yeung JWS. Maculopathy of sex-linked juvenile retinoschisis. *Can J Ophthalmol* 1976; 11: 1-10.
- 28 Forsius H, Vainio-Mattila B, Eriksson A. X-linked retinoschisis. *Br J Ophthalmol* 1962; 46: 678-81.
- 29 Basmadjian G, Labelle P, Dumas J. The natural evolution of juvenile retinoschisis. *Can J Ophthalmol* 1973; 8: 33-7.
- 30 Bengtsson B, Linder B. Sex-linked hereditary juvenile retinoschisis. *Acta Ophthalmol* 1967; 45: 411-23.
- 31 Brodrick JD, Wyatt HT. Hereditary X-linked retinoschisis. *Br J Ophthalmol* 1973; 57: 551-9.
- 32 Pearson R, Jagger J. Sex linked retinoschisis with optic disc and peripheral retinal neovascularisation. *Br J Ophthalmol* 1989; 73: 311-3.
- 33 de Jong PT, Zrenner E, van Meel GJ, Keunen JEE, van Norren D. Mizuo phenomenon in X-linked retinoschisis. *Arch Ophthalmol* 1991; 109: 1104-8.
- 34 Tasman W, Greven C, Moreno R. Nasal retinal dragging in X-linked retinoschisis. *Graefes Arch Clin Exp Ophthalmol* 1991; 229: 319-22.
- 35 van Schooneveld M, Miyake Y. Fundus albipunctatus-like lesions in juvenile retinoschisis. *Br J Ophthalmol* 1994; 78: 659-61.
- 36 Verdauger J. Juvenile retinal detachment. *Am J Ophthalmol* 1982; 93: 145-56.
- 37 Kraushar MF, Schepens CL, Kaplan JA, Freeman HM. Congenital retinoschisis. In: Bellows JG, ed. *Contemporary ophthalmology honoring Sir Stewart Duke-Elder*. Baltimore: Williams and Wilkins, 1972: 265-90.
- 38 Schepens CL. Congenital retinoschisis. *Klin Oczna* 1988; 90: 127-32.
- 39 Regillo CD, Tasman WS, Brown GC. Surgical management of complications associated with X-linked retinoschisis. *Arch Ophthalmol* 1993; 111: 1080-6.
- 40 Hung JY, Hilton GF. Neovascular glaucoma in a patient with X-linked juvenile retinoschisis. *Ann Ophthalmol* 1980; 12: 1054-5.
- 41 Brockhurst R. Photocoagulation in congenital retinoschisis. *Arch Ophthalmol* 1970; 84: 158-65.
- 42 Nasr YG, Cherfan GM, Michels RG, Wilkinson CP. Goldmann-Favre maculopathy. *Retina* 1990; 10: 178-80.
- 43 Fishman GA, Jampol LM, Goldberg MF. Diagnostic features of Favre-Goldmann syndrome. *Br J Ophthalmol* 1976; 60: 345-53.
- 44 Noble KG, Carr RE, Siegel IM. Familial foveal retinoschisis associated with a rod-cone dystrophy. *Am J Ophthalmol* 1978; 85: 551-7.
- 45 Yassur Y, Nissenkorn I, Ben-Sira I, Kaffe S, Goodman RM. Autosomal dominant inheritance of retinoschisis. *Am J Ophthalmol* 1982; 94: 338-43.
- 46 Lewis RA, Lee GB, Martonyi CL, Barnett JM, Falls HF. Familial foveal retinoschisis. *Arch Ophthalmol* 1977; 95: 1190-6.
- 47 Newton MS, Collyer S, Phillips CI. Male proband with X-linked retinoschisis apparently inherited from his father's family. *J Med Genet* 1991; 28: 213-6.
- 48 Yamaguchi K, Hara S. Autosomal juvenile retinoschisis without foveal retinoschisis. *Br J Ophthalmol* 1989; 73: 470-3.
- 49 Hommura S, Nakano H. A family of foveal retinoschisis including a female with Turner's syndrome. *Jpn J Clin Ophthalmol* 1982; 36: 291.
- 50 Barut C. Périphérolite rétinienne associée à des lésions maculaires constatée chez deux frères et évoluant depuis l'enfance. *Bull Soc Ophthal Fr* 1955; 55: 185-8.
- 51 Peralta S, Santori M. Degenerazione maculare centrale tipo Stargardt associata ad alterazioni vitreali congenite. *Ann Ottal* 1967; 93: 237-42.
- 52 Condon GP, Brownstein S, Wang N, Kearns AF, Ewing CC. Congenital hereditary (juvenile X-linked) retinoschisis: histopathologic and ultrastructural findings in three eyes. *Arch Ophthalmol* 1986; 104: 576-83.
- 53 Manschot WA. Pathology of hereditary juvenile retinoschisis. *Arch Ophthalmol* 1972; 88: 131-7.
- 54 Yanoff M, Rahn EK, Zimmerman LE. Histopathology of juvenile retinoschisis. *Arch Ophthalmol* 1968; 79: 49-53.
- 55 Laatikainen L, Tarkkanen A, Saksela T. Hereditary X-linked retinoschisis and bilateral congenital retinal detachment. *Retina* 1987; 7: 24-7.
- 56 Manschot WA. Pathology of hereditary conditions related to retinal detachment. *Ophthalmologica* 1971; 162: 223-34.
- 57 Tanino T, Katsumi O, Hirose T. Electrophysiological similarities between two eyes with X-linked recessive retinoschisis. *Doc Ophthalmol* 1985; 60: 149-61.
- 58 Peachey NS, Fishman GA, Derlacki DJ, Brigell MG. Psychophysical and electroretinographic findings in X-linked juvenile retinoschisis. *Arch Ophthalmol* 1987; 105: 513-6.
- 59 Miyake Y, Shirogama N, Ota I, Horiguchi M. Focal macular electroretinogram in X-linked congenital retinoschisis. *Invest Ophthalmol Vis Sci* 1993; 34: 512-5.
- 60 Miyake Y, Yagasaki K, Horiguchi M, Kawase Y. Congenital stationary night blindness with negative electroretinogram: a new classification. *Arch Ophthalmol* 1986; 104: 1013-20.
- 61 De Becker I, Riddell DC, Dooley JM, Tremblay F. Correlation between electroretinogram findings and molecular analysis in the Duchenne muscular dystrophy phenotype. *Br J Ophthalmol* 1994; 78: 719-22.
- 62 Pillers D-AM, Bulman DE, Weleber RG, Sigesmund DA, Musarella MA, Powell BR, et al. Dystrophin expression in the human retina is required for normal function as defined by electroretinography. *Nature Genet* 1993; 4: 82-6.
- 63 Kellner U, Foerster MH. Cone dystrophies with negative photopic electroretinogram. *Br J Ophthalmol* 1993; 77: 404-9.
- 64 Miller RF, Dowling JE. Intracellular responses of the Müller (glial) cells of the mudpuppy retina: their relation to the b-wave of the electroretinogram. *J Neurophysiol* 1970; 33: 323-41.
- 65 Murayama K, Kuo CY, Sieving PA. Abnormal threshold ERG response in X-linked juvenile retinoschisis: evidence for a proximal retinal origin of the human STR. *Clin Vis Sci* 1991; 6: 317-22.
- 66 Arden GB, Hogg CR. Rod-cone interactions and analysis of retinal disease. *Br J Ophthalmol* 1985; 69: 404-15.
- 67 Goldberg SH, Frumkes TE, Nygaard RW. Inhibitory influence of unstimulated rods in the human retina: evidence provided by examining cone flicker. *Science* 1983; 221: 180-1.
- 68 Arden GB, Hogg CR. Absence of rod-cone interaction in nyctalopia and retinoschisis. *J Physiol (Lond)* 1984; 353: 19P.
- 69 Arden GB, Gorin MB, Polkinghorne PJ, Jay M, Bird AC. Detection of the carrier state of X-linked retinoschisis. *Am J Ophthalmol* 1988; 105: 590-5.
- 70 Alexander KR, Fisherman GA. Rod-cone interaction in flicker perimetry: evidence for a distal retinal locus. *Doc Ophthalmol* 1985; 60: 3-36.
- 71 Gardner-Medwin AR. A foot in the vitreous fluid. *Nature*. 1984; 309: 173.
- 72 Foos RY. Vitreoretinal juncture: topographical variations. *Invest Ophthalmol Vis Sci* 1972; 11: 801-8.
- 73 Reichenbach A, Stolzenburg JU, Eberhardt W, Chao TI, Dettmer D, Hertz L. What do retinal Müller (glial) cells do for their neuronal 'small siblings'? *J Chem Neuroanat* 1993; 6: 201-13.
- 74 Reichenbach A, Ziegler M, Schnitzer J, Pritz-Hohmeier S, Schaaf P, Schober W, et al. Development of the rabbit retina. V: the question of 'columnar units'. *Dev Brain Res* 1994; 79: 72-84.
- 75 Barnstable CJ. A molecular view of retinal development. *Mol Neurobiol* 1987; 1: 9-45.
- 76 Karowski CJ, Proenza LM. Relationship between Müller cell responses, a local transretinal potential and potassium flux. *J Neurophysiol* 1977; 40: 244-59.
- 77 Newman EA. Regional specialization of retinal glial cell membrane. *Nature* 1984; 309: 155-7.
- 78 Ewing CC, Cullen AP. Fluorescein angiography in X-chromosomal maculopathy with retinoschisis (juvenile hereditary retinoschisis). *Can J Ophthalmol* 1972; 7: 19-28.
- 79 Green JL, Jampol LM. Vascular opacification and leakage in X-linked (juvenile) retinoschisis. *Br J Ophthalmol* 1979; 63: 368-73.
- 80 Goodman P, Rippes H, Siegel IM. Sex-linked ocular disorders: trait expressivity in males and carrier females. *Arch Ophthalmol* 1965; 73: 387-98.
- 81 Lyon MF. Sex chromatin and gene action in the mammalian X chromosome. *Am J Hum Genet* 1962; 14: 135-48.
- 82 Kaplan J, Pelet A, Hentati H, Jeanpierre M, Briard ML, Journel H, et al. Contribution to carrier detection and genetic counselling in X linked retinoschisis. *J Med Genet* 1991; 28: 383-8.
- 83 Vainio-Mattila B, Eriksson AW, Forsius H. X-chromosomal recessive retinoschisis in the region of Pori. *Acta Ophthalmol* 1969; 47: 1135-48.
- 84 Ewing CC, Ives EJ. Juvenile hereditary retinoschisis. *Trans Ophthalmol Soc UK* 1969; 89: 29-39.
- 85 Alitalo T, Kruse TA, Ahrens P, Albertsen HM, Eriksson AW, de la Chapelle A. Genetic mapping of 12 marker loci in the Xp22.3-p21.2 region. *Hum Genet* 1991; 86: 599-603.
- 86 Alitalo T, Kruse TA, de la Chapelle A. Refined localisation of the gene causing X-linked juvenile retinoschisis. *Genomics* 1991; 9: 505-10.
- 87 Wieacker P, Wienkert TF, Dallapiccola B, Bender K, Davies KE, Ropers HH. Linkage relationships between retinoschisis, Xg, and a cloned DNA sequence from the distal short arm of the X chromosome. *Hum Genet* 1983; 64: 143-5.
- 88 Dahl N, Goonewardena P, Chotai J, Anvret M, Pettersson U. DNA linkage analysis of X-linked retinoschisis. *Hum Genet* 1988; 78: 228-32.
- 89 Rowe PS, Goulding J, Read A, Mountford R, Hanauer A, Oudet C, et al. New markers for linkage analysis of X-linked hypophosphataemic rickets. *Hum Genet* 1993; 91: 571-5.
- 90 Rowe PS, Goulding J, Read A, Lehrach H, Francis F, Hanauer A, et al.

- Refining the genetic map for the region flanking the X-linked hypophosphataemic rickets locus (Xp22.1-22.2). *Hum Genet* 1994; **93**: 291-4.
- 91 Biancalana V, Briard ML, David A, Gilgenkrantz S, Kaplan J, Mathieu M, *et al.* Confirmation and refinement of the genetic localisation of the Coffin-Lowry syndrome locus. *Am J Hum Genet* 1992; **50**: 981-7.
- 92 Biancalana V, Trivier E, Weber C, Weissenbach J, Rowe PSN, O'Riordan JLH, *et al.* Construction of a high resolution linkage map for Xp22.1-22.2 and refinement of genetic localisation of the Coffin-Lowry Syndrome gene. *Genomics* 1994; **22**: 617-25.
- 93 George NDL, Payne SJ, Barton D, Moore AT, Yates JRW. Genetic mapping of X-linked retinoschisis. *5th X chromosome workshop*. Heidelberg, Germany: 1994: 83.
- 94 Turut P, Francois P, Castier P, Milazzo S. Analysis of results in the treatment of peripheral retinoschisis in sex-linked congenital retinoschisis. *Graefes Arch Clin Exp Ophthalmol* 1989; **27**: 328-31.
- 95 Schulman J, Peyman GA, Jednock N, Larson B. Indications for vitrectomy in congenital retinoschisis. *Br J Ophthalmol* 1985; **69**: 482-6.
- 96 Rudanko SL, Flage T, Hansen E, Rosenberg T, Vigosson G, Riise R. Visual impairment in Nordic children V. X-linked juvenile retinoschisis. *Acta Ophthalmol* 1993; **71**: 586-9.