

right eye and 1-0 left eye. Slit-lamp examination showed cells and flare in the right anterior chamber with retrocorneal precipitates and cellular infiltration of the posterior vitreous. Funduscopy revealed bilateral disseminated intraretinal haemorrhages. The right fundus showed exudative retinal detachment of the upper nasal quadrant with an underlying whitish mass forming a horizontal level which changed according to the patient's position (Fig 1).

Ultrasound A-scan in upright position of the patient showed a 100% high spike due to retinal detachment and medium to highly reflective subretinal spikes at the bottom of the subretinal space. The latter were the results of irregular acoustic interfaces² caused by cellular (leucocytic) sedimentation (Fig 2). Ultrasound B-scan in the upright position confirmed the findings of A-scan investigation (Fig 2). A gravity dependent behaviour of subretinal cellular elements was clearly demonstrated as the higher reflective elements moved upwards and finally mixed with the lower reflective elements while the patient's position was gradually changed horizontally.

A few weeks after diagnosis of leukaemic retinopathy platelets dropped to $80 \times 10^9/l$. The patient deteriorated suffering from incurable fever and died.

COMMENT

The above described ophthalmic findings represent ocular involvement in leukaemia. As pointed out by Rosenthal³ and Decker *et al*⁴ the iritis-like signs are based on iris infiltration of leukaemic cells which invade the aqueous humour and may precipitate on the endothelium or even form a hypopyon. Paracentesis and cytological examination can confirm the diagnosis which was not possible in our severely debilitated patient. The fundus changes correspond well to the signs of leukaemic retinopathy.^{5,6} Guyer *et al* found an association between the presence of intraretinal haemorrhages and thrombocytopenia.⁷ In our patient, however, the manifestation of intraretinal haemorrhages preceded the decrease of platelets. As Fischer *et al* stated leukaemic cells can obstruct small vessels if the white cell count exceeds $150 \times 10^9/l$. Leukostasis leads to ischaemia and rupture of small vessels.⁸ This mechanism might explain intraretinal haemorrhage without thrombocytopenia. Serous retinal detachment has been found as part of leukaemic retinopathy.⁹ A subretinal hypopyon-like aggregation of cellular elements as shown on ultrasound, however, is rare and has not been reported in the literature to the best of our knowledge.

As there was no consent to postmortem examination the ophthalmic diagnosis could not be proved. As ocular signs and symptoms did not worsen but slightly improved after chemotherapy bacterial or fungal intraocular infection, which had to be considered, did not seem probable. The rapid fatal outcome after onset of ocular involvement in our patient confirms the statement of Rosenthal that leukaemic retinal infiltration combined with a high leucocyte count is 'an ominous prognostic sign'.³

H D SCHWORM
J E NASEMANN
S SCHRIEVER

University Eye Hospital Munich,
Germany

Correspondence to: Hermann Dieter Schworm, MD, University Eye Hospital, Mathildenstrasse 8, 80336 Munich, Germany.

Accepted for publication 24 April 1995

- Ohkoshi K, Tsiaras WG. Prognostic importance of ophthalmic manifestations in childhood leukaemia. *Br J Ophthalmol* 1992; **76**: 651-5.
- Ossoinig KC. Standardized echography: basic principles, clinical applications and results. *Int Ophthalmol Clin* 1979; **19**: 127-210.
- Rosenthal AR. Ocular manifestations of leukemia. *Ophthalmology* 1983; **90**: 899-905.
- Decker EB, Burnstine RA. Leukemic relapse presenting as acute unilateral hypopyon in acute lymphocytic leukemia. *Ann Ophthalmol* 1993; **25**: 346-9.
- Allen RA, Straatsma BR. Ocular involvement in leukemia and allied disorders. *Arch Ophthalmol* 1961; **66**: 490-508.
- Cunningham RD. Retinopathy of the blood dyscrasias. In: *Duane's clinical ophthalmology*. Philadelphia: Lippincott, 1989: Vol 3, Chap 18:5.
- Guyer DR, Schachat AP, Vitale S, Markowitz JA, Braine H, Burke PJ, *et al*. Leukemic retinopathy - relationship between fundus lesions and hematologic parameters at diagnosis. *Ophthalmology* 1989; **96**: 860-4.
- Fischer R, Schäfer HE. Die pathologische Anatomie der Leukosen. In: Gross R, van de Loo J, eds. *Leukämie*. Berlin, Heidelberg, New York: Springer, 1972: S1-24.
- Kincaid MC, Green WR, Kelley JS. Acute ocular leukemia. *Am J Ophthalmol* 1979; **87**: 698-702.

Pseudomonas keratitis associated with biofilm formation on a disposable soft contact lens

EDITOR,—A 26-year-old woman attended the casualty department at Moorfields Eye Hospital with a 1 week history of a sore left eye. The patient had been wearing Acuvue contact lenses (Vistakon, Johnson & Johnson, Berks) for myopic correction for 5 months. Lenses had not been disposed of according to the manufacturer's recommendations, and the same pair of contact lenses had been used for the past 5 months. Lenses were worn on an extended wear basis for 7 days, followed by disinfection using Oxsept 1 and 2 (Allergan, High Wycombe, Bucks). No surfactant cleaner was used before disinfection.

On admission, her left visual acuity was hand movements. She had a large corneal abscess with a 3 mm hypopyon (Fig 1). Microbiological analysis of the corneal scrape identified the causative organism as *Pseudomonas aeruginosa*. Part of the worn lens was macerated using a tissue homogeniser and culture of the homogenate recovered *Pseudomonas aeruginosa*, with similar antibiotic sensitivities as the isolate from the cornea. A second part was fixed in 2.5% glutaraldehyde with 0.05% ruthenium red for electron microscopy. Scanning electron microscopy of the posterior surface of the contact lens revealed widespread bacterial colonisation, with rod-shaped organisms embedded within an extensive extracellular matrix (Fig 2). Microbiological analysis of the contact lens storage case revealed a mixed confluent culture of *Pseudomonas aeruginosa* and *Serratia marcescens*. Culture of the disinfection and spray saline solution revealed no microbial growth. Sampling of body sites

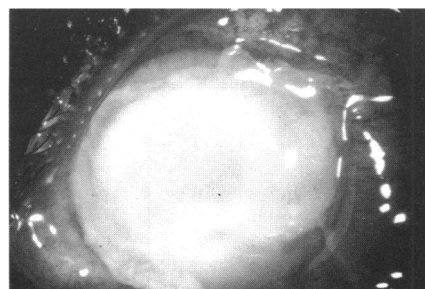


Figure 1 Large corneal abscess with dense corneal infiltrate and 3 mm hypopyon in the left eye.

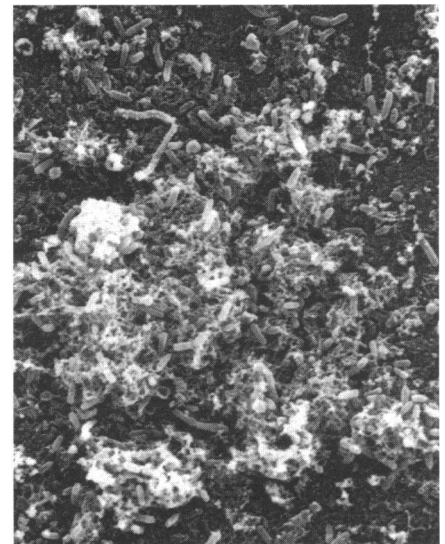


Figure 2 Scanning electron micrograph showing widespread colonisation of the posterior lens surface by rod shaped organisms which are embedded within a sponge-like extracellular matrix (magnification $\times 1180$).

including fingers, toe web, and throat revealed no persistent patient carriage of this organism. Microbiological analysis of the domestic water supply revealed no easily identifiable environmental source for this organism.

Initial treatment comprised intensive unpreserved ticarcillin drops (1%) every 30 minutes and systemic ciprofloxacin for 12 days. One week after admission, the patient was discharged and continued with ticarcillin drops hourly and gentamicin ointment at night. After a further week, there was healing of the corneal epithelial defect and the therapy was modified to ticarcillin drops 2 hourly, dexamethasone drops four times a day, and gentamicin ointment at night. Two weeks later, the corneal epithelialisation was complete and the topical treatment was slowly reduced. Five months later, the patient underwent successful penetrating keratoplasty, with a resultant visual acuity of 6/9.

COMMENT

Extended wear of contact lenses is a major predisposing factor for microbial keratitis and has a greater risk of disease compared with other modes of contact lens wear.¹ In this case, involving a disposable contact lens wearer, non-compliance with both the surfactant cleaning regime and contact lens disposal may have been additional associated risk factors.²

Bacterial colonisation of the contact lens by organisms similar to those recovered from the cornea, suggests the potential role of the contact lens as a vector for pathogenic organisms. Such colonisation may prolong the retention time of organisms at the ocular surface and production of an extracellular matrix (glycocalyx) may protect adherent organisms from host defence mechanisms and from the antimicrobial effects of contact lens disinfection systems. Bacteria within a biofilm on contact lens storage cases have been shown to be significantly more resistant to contact lens disinfection regimes compared with planktonic organisms.³

The role of the bacterial biofilm in the pathogenesis of contact lens related keratitis is not well understood. Prevention of persistent colonisation of contact lenses either by establishing the source of organisms, by modifying

contact lens material or coating characteristics, or by the use of topical antiadhesive agents, may help to eliminate the problem. Additionally, improved patient education and compliance are required.

This study was supported by a Moorfields Eye Hospital locally organised research grant and the Guide Dogs for the Blind Association.

F STAPLETON
Department of Optometry and Visual Science,
City University, London

F STAPLETON
J DART
Department of Clinical Science
and Electron Microscopy Unit,
Institute of Ophthalmology,
University of London

J DART
Moorfields Eye Hospital,
City Road, London

Correspondence to: Dr F Stapleton, Department of Optometry and Visual Science, City University, 311-321 Goswell Road, London EC1V 7DD.

Accepted for publication 17 May 1995

- 1 Dart JKG, Stapleton F, Minassian D. Contact lenses and other risk factors for microbial keratitis. *Lancet* 1991; **38**: 650-3.
- 2 Radford CF, Dart JKG, Minassian D. The risk of microbial keratitis with daily-wear and extended-wear use of disposable lenses. *Invest Ophthalmol Vis Sci* 1994; **35** (suppl): 2163.
- 3 Wilson LA, Sawant AD, Ahern DG. Comparative efficacies of soft contact lens disinfectant solutions against microbial films in lens cases. *Arch Ophthalmol* 1991; **109**: 1155-7.

Bilateral vitreous cysts in an 80-year-old man

EDITOR,—Vitreous cysts were first described at the end of the last century.¹ They are regarded as ocular curiosities because they are usually asymptomatic and clinical reports are rare. Vitreous cysts can be found in both men and women. There are reports describing unilateral cysts in patients ranging from childhood to young adults. Here we report a case of bilateral vitreous cysts in an 80-year-old patient.

CASE REPORT

An 80-year-old man came to our clinic complaining of seeing floaters in his left eye which moved with eye movements. There was myopia of -3.5 dioptres in the right eye and -4.5 in the left eye. Corrected visual acuity was counting fingers at 2.5 metres in his right eye and 20/40 in his left. Slit-lamp examination showed senile cataract in both eyes. No other relevant alterations in the anterior pole were found. Ophthalmoscopic examination disclosed posterior vitreous detachment and senile macular degeneration in both eyes. There was a vitreous cyst in the right eye of about 3 mm located in the posterior pole. This cyst moved freely but its position was restricted to a circumscribed region. Another vitreous cyst of approximately the same size was found in the left eye, also freely moving in the vitreous. Both cysts were translucent, with some pigment on their walls and were slightly wrinkled (Fig 1). Their surroundings were free of any inflammatory signs. B-scan ultrasonography confirmed the posterior vitreous detachment and demonstrated a well defined anterior and posterior wall in the cyst in the right eye. The walls of the cyst in the left eye were less sharply defined (Fig 2). The patient did not report any history of trauma or visual symptoms that could be related to the cysts.

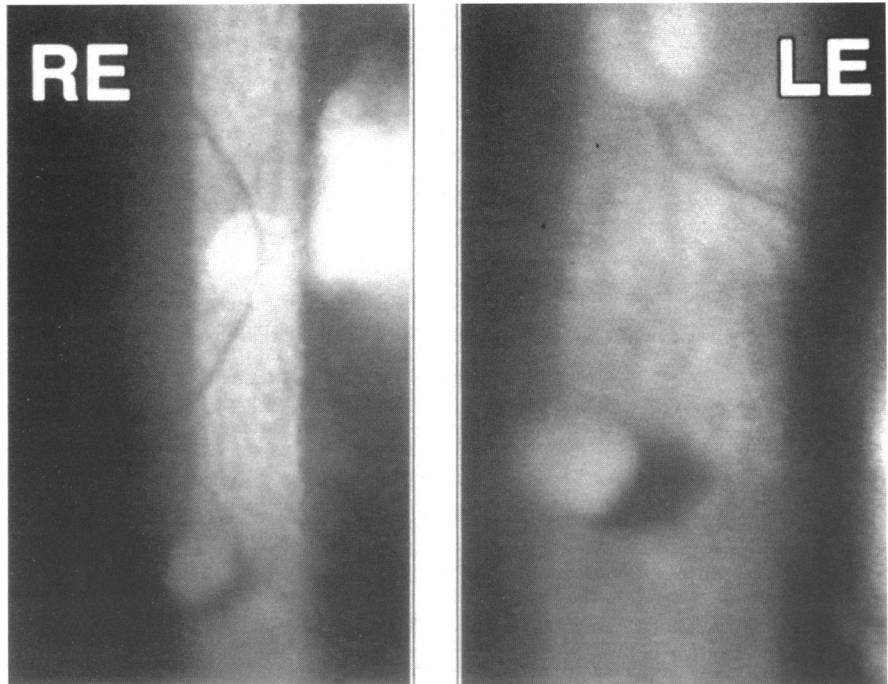


Figure 1 Right (RE) and left (LE) eye fundus view showing the vitreous cysts.

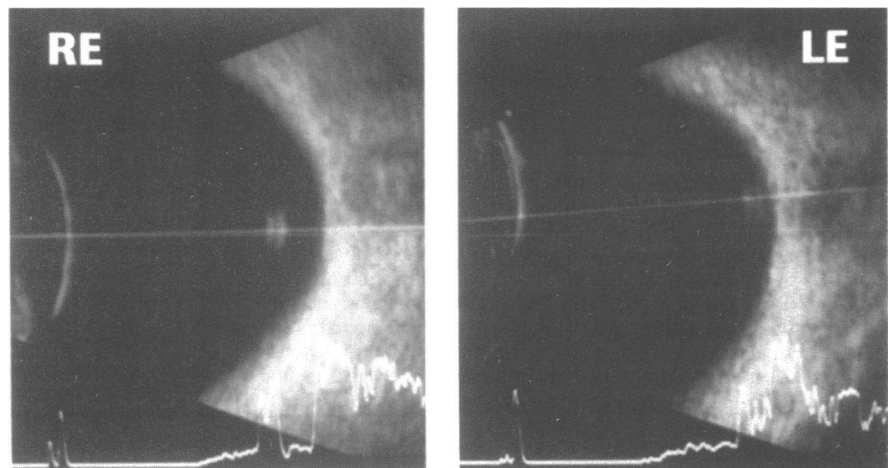


Figure 2 B-scan ultrasonography of the right eye (RE) and left eye (LE) showing the vitreous cysts.

COMMENT

Although a developmental origin for such cysts has been proposed, their aetiology is still unclear. They may represent remnants of the hyaloid artery, its glial sheets, or the fetal cleft. Vitreous cysts have also been reported as part of an autosomal dominant hereditary vitreo-retinopathy² and combined with juvenile retinoschisis.³ A histopathological report⁴ suggests that vitreous cysts have their origin in the pigmented ciliary epithelium as a consequence of trauma or inflammatory eye diseases.

To our knowledge this is the first description of bilateral vitreous cysts in an elderly person. Previous reports of such cysts relate to infants, children, or young adult patients. The case we present showed two vitreous cysts, one in each eye, of a very similar appearance. Since the patient had no history of trauma or eye disease other than senile macular degeneration, and since the cysts were present in both eyes, we believe that vitreous cysts are of developmental origin. An interesting observation is that vitreous cysts may be asymptomatic for a long period of time, and probably many of them remain so throughout the patient's life. This is perhaps the reason why vitreous cysts are very often an incidental finding. In our case both cysts were asymptomatic until the patient reached 80 years of

age. Even at this time only the cyst in his left eye produced floaters, while the cyst in the right eye remained asymptomatic. We believe the symptoms appeared because the posterior vitreous detachment produced a displacement of the cyst from its original position. This was not the case in the right eye, where, although a posterior vitreous detachment was present, probably this did not cause sufficient displacement of the cyst to produce floaters.

Surgical removal or laser photocystotomy have been performed on cysts that produced significant visual limitation.^{4,5} In our case no treatment was carried out on the right eye because symptoms were not present. Since we judged that the symptoms caused by the cyst in his left eye were minor, no attempt was made to remove or destroy the cyst. We emphasise that the origin of vitreous cysts may be developmental and that in the absence of visual disturbances they should be left untreated as symptoms and complications are unlikely.

L SANTOS
F GONZALEZ
C CAPEANS
A SUAREZ
M SANCHEZ-SALORIO
Instituto de Galego Oftalmoxia
F GONZALEZ
Departamento de Fisiología, Facultad de Medicina,
Complejo Hospitalario Universitario de Santiago,
Santiago de Compostela, Spain