

Figure 1 (A) Photograph of right eye showing corneal protrusion. (B) Slit-lamp photograph of same eye showing band of clear corneal thinning 1–2 mm above limbus.

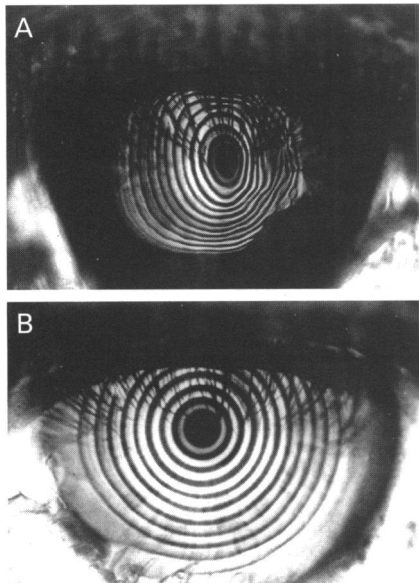


Figure 2 (A) Corneoscope photograph of right eye demonstrating marked, against the rule astigmatism. (B) Corneoscope photograph of left eye demonstrating sphericity.

thinning, or abnormal protrusion. The dilated fundus examination was unremarkable in both eyes. Intraocular pressures were 10 and 15 mm Hg right and left eye, respectively, by pneumotometry. Keratometry was 40.75 by 53.5 × 180 right eye and 42.5 by 42.50 left eye. Corneoscope photographs revealed marked against the rule astigmatism in the right eye and no apparent corneal astigmatism in the left (Fig 2).

#### COMMENT

This patient was noted to have corneal findings in the right eye consistent with PMD including a clear, narrow band of corneal thinning above the inferior limbus with maximal anterior displacement and apparently normal thickness cornea above this thinned band. Corneal topography shows fairly regular against the rule astigmatism. These findings are all present only in the right eye. The left eye shows no evidence of degeneration and is without astigmatism by keratometry and corneoscopy. Other possible causes of the peripheral corneal thinning observed in the right eye include Tierren's degeneration, Mooren's ulcer, rheumatoid corneal thinning, keratoconus, and keratoglobus.

This case can be distinguished from Tierren's degeneration by the absence of vascular invasion or lipid infiltration. The lack of corneal ulceration or systemic connective tissue disease makes Mooren's ulcer or rheumatoid aetiologies unlikely. This case differs from keratoconus in that the maximal

protrusion occurs above the area of thinning, whereas in keratoconus the maximal protrusion occurs in the thinned area. Also, the iron lines typical of keratoconus are absent here. In keratoglobus thinning and protrusion occur over the entire cornea rather than in one area as in this case.

The unilateral presentation in this case is unusual, for PMD is considered a bilateral condition.<sup>1,2</sup> Although bilateral conditions often present asymmetrically in degree or time, the left eye in this case shows no signs of corneal involvement 30 years after the first eye became symptomatic and past the age that PMD typically is diagnosed. Cases of unilateral PMD associated with other corneal thinning disorders such as keratoconus in the opposite eye have been reported,<sup>3,4</sup> but this is the first case of isolated unilateral PMD in an elderly patient.

BRET B WAGENHORST  
Columbia, SC 29209, USA

Accepted for publication 24 May 1996

- 1 Krachmer JH. Pellucid marginal corneal degeneration. *Arch Ophthalmol* 1978;96:1217–21.
- 2 Krachmer JH, Feder RS, Belin MW. Keratoconus and related noninflammatory corneal thinning disorders. *Surv Ophthalmol* 1984;28:293–322.
- 3 Lisch K. Torische Vorwölbung der Hornhaut. *Klin Monatsbl Augenheilkd* 1970;157:523–8.
- 4 Nagy M, Vigvary L. Beiträge zur Aetiologie der degeneratio marginalis pellucida corneae. *Klin Monatsbl Augenheilkd* 1972;161:604–11.

#### Amikacin may be drug of choice in *Nocardia* keratitis

EDITOR.—While *Nocardia* infections usually follow a self limiting course, rapid extension of the primary focus and dissemination have been reported in immunosuppressed patients.<sup>1</sup> Owing to the more frequent use of immunosuppressive drugs, *Nocardia* infections are diagnosed with increasing frequency.<sup>2</sup> Case reports have recently encouraged the use of topical amikacin in *Nocardia* keratitis.<sup>3</sup> We present another patient with this condition treated successfully with topical amikacin.

#### CASE REPORT

A 31-year-old man noticed a foreign body sensation in the right eye after drilling into the ceiling of a decayed building. He presented to a local ophthalmologist, who removed two metal fragments from the right cornea. Although a treatment with norfloxacin eye-drops, subconjunctival corticosteroid, and antibiotic injections was initiated, symptoms were progressively aggravated. Three weeks later, a central corneal infiltrate had developed. Oral fluconazole, 200 mg a day, and topical kanamycin ointment were added to the treatment.

Five weeks later, the patient presented to the university eye clinic. The uncorrected visual acuity (UCVA) was 20/200 in the right and 20/20 in the left eye. Slit-lamp examination of the right cornea disclosed a central, subepithelial infiltrate with two satellite lesions (Fig 1). A corneal scraping was performed immediately. The Gram stain revealed Gram positive coccoid elements. Presuming keratomycosis, the patient was put on topical amphotericin 0.5% hourly. Two weeks later, the UCVA of the right eye had diminished to hand movement as a result of expansion of the lesion. Material from a second scraping was examined in 10% potas-

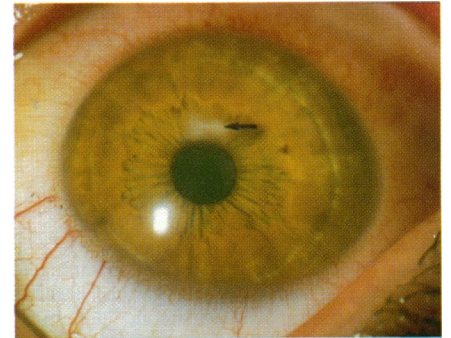


Figure 1 Slit-lamp photograph, showing the central corneal infiltrate (arrow). Two satellites can be discerned. The corresponding visual acuity was 20/200.

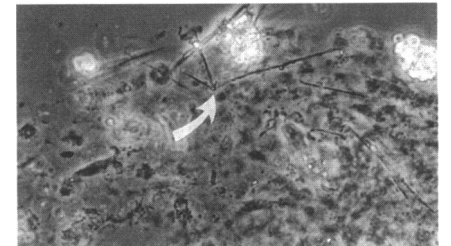


Figure 2 Light microscopy of corneal scraping material in potassium hydroxide solution: *Nocardia* organisms appear as rectangular branching rods (arrow) surrounded by corneal debris.

sium hydroxide solution by light microscopy (Fig 2). Long rectangular elements were discerned between stromal debris. Meanwhile, culture of material from the first scraping revealed *Nocardia* species. Further subclassification was impossible owing to scarcity of material and slow growth of the organism. Subsequently, the patient was put on topical amikacin 5% every 2 hours and amphotericin 0.5% five times a day.

Two months later, scar tissue was observed in the subepithelial corneal stroma and best corrected visual acuity had recovered to 20/25.

#### COMMENT

Exogenous ocular inoculation by *Nocardia* species usually affects the cornea. An intact immune response is critical for the eradication of *Nocardia* infections. Topical steroids were reported to aggravate the disintegration of corneal tissue.<sup>4</sup>

*Nocardia* keratitis can result in permanent reduction of visual acuity due to corneal scarring. Unfortunately, an exact differentiation between yeast-like fungi, diphtheroids, *Nocardia*, and non-tuberculous mycobacteria is not possible by light microscopy. Culture often fails to isolate the organism and antibiotic sensitivity test results do not correlate with the clinical response in keratitis.<sup>5</sup> However, early detection and treatment of *Nocardia* are critical for a satisfactory outcome.

Sulphonamides have been used as first choice therapy in *Nocardia* keratitis in the past, but results have been controversial.<sup>4</sup> Better clinical responses of *Nocardia* keratitis have been reported with topical trimethoprim-sulphamethoxazole,<sup>6</sup> but susceptibility tests suggested a 92.5% resistance of *Nocardia asteroides* to trimethoprim-sulphamethoxazole.<sup>2</sup>

Amikacin is the treatment of choice in human disseminated nocardiosis.<sup>2</sup> In vitro susceptibility tests failed to detect resistance of *Nocardia* to amikacin.<sup>2</sup> Although paratotoxicity of topical amikacin 10% has been observed

in a rabbit model,<sup>7</sup> we did not encounter side effects in our patient. The favourable outcome of the case presented suggests that topical amikacin should be considered an effective and safe drug for the treatment of *Nocardia* keratitis.

PETER OLIVER DENK  
 SOLON THANOS  
 HANS-JÜRGEN THIEL

University Eye Clinic, Tübingen, Germany

Correspondence to: Oliver Denk, Schleichstrasse 12, 72076 Tübingen, Germany.

Accepted for publication 28 June 1996

- Boiron P, Provost F, Chevrier G, Dupont B. Review of nocardial infections in France 1987-1990. *Eur J Clin Microbiol Infect Dis* 1992; 11:709-14.
- Chen CJ. *Nocardia asteroides* endophthalmitis. *Ophthalmic Surg* 1983;14:502-5.
- Dewsnup DH, Wright DN. In vitro susceptibility of *Nocardia asteroides* to 25 antimicrobial agents. *Antimicrob Agents Chemother* 1984;25: 165-7.
- Douglas RM, Grove DJ, Elliott J, Looke DFM, Jordan AS. Corneal ulceration due to *Nocardia asteroides*. *Aust NZ J Ophthalmol* 1991;19:317-20.
- Helm CJ, Holland GN, Lin R, Berlin OGW, Bruckner DA. Comparison of topical antibiotics for treating mycobacterium fortuitum keratitis in an animal model. *Am J Ophthalmol* 1993;116: 700-7.
- Hirst LW, Harrison GK, Merz WG, Stark WJ. *Nocardia asteroides* keratitis. *Br J Ophthalmol* 1979;63:449-54.
- Husain N, Matoba AY, Wilhelmus KR, Jones DB. Isolation and therapy of *Nocardia* keratitis. *Invest Ophthalmol Vis Sci* 1995;36 (Suppl):S155.

### Recurrent systemic B cell lymphoma of the iris

EDITOR.—Recognised clinical findings of intraocular lymphoma include vitritis, solid retinal pigment epithelial detachments, diffuse retinal and choroidal infiltrates, retinal haemorrhage, perivasculitis, retinal necrosis, and optic neuritis.<sup>1</sup> Anterior uveitis secondary to posterior segment intraocular lymphoma is recognised, but isolated primary or recurrent iris lymphoma is rare. We report a case of non-Hodgkin's lymphoma involving only the iris.

#### CASE REPORT

A 25-year-old white woman reported blurred vision in the right eye for 3 weeks. Eighteen months earlier, she had presented with a right seventh nerve palsy and was found to have a right nasopharyngeal and parapharyngeal mass extending posteriorly to the right carotid sheath with perineural spread. Biopsy revealed diffuse large B cell lymphoma and lumbar puncture was positive for malignant lymphocytes. She was managed with systemic cyclophosphamide, vincristine, and doxorubicin, and intrathecal methotrexate and cytarabine, followed by external beam radiotherapy to the nasopharyngeal area with eye shielding. At completion of therapy, all repeat studies including cerebrospinal fluid examination were normal and she remained in remission until presentation 18 months later.

On examination, the visual acuity was 20/30 in the right eye and 20/20 in the left. Intraocular pressures were 16 mm Hg in both eyes. The left eye was normal, the right showed central corneal oedema with fine diffuse keratic precipitates and moderate cells and flare in the anterior chamber. The entire right iris was thickened and a diffuse solid mass was present superiorly (Fig 1). There was noticeable iris heterochromia, with the right iris

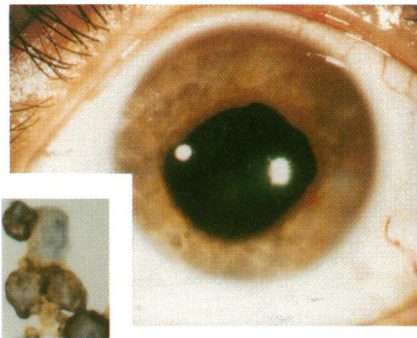


Figure 1 Slit-lamp photograph of the right eye showing diffuse nodular iris thickening. Inset: high power photomicrograph of cytological specimen showing lymphoma cells and positive immunocytochemical staining for the pan B cell marker CD20 (L26).

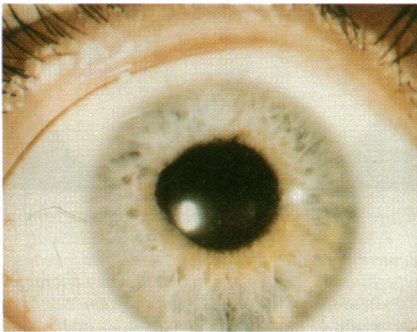


Figure 2 Slit-lamp photograph of the right iris showing iris crypts and mild persistent ectropion uvea 3 months after radiotherapy. There is no residual iris thickening.

brown and the left iris blue. Ectropion uvea was present superiorly, but there was no iris neovascularisation or lens abnormality. The posterior segment examination was unremarkable. Systemic examination was normal. Uncomplicated fine needle aspiration biopsy of the solid mass was performed via a superior temporal approach. Cytological evaluation of the specimen showed the presence of large atypical lymphocytes, morphologically compatible with non-Hodgkin's lymphoma. Immunocytochemical studies revealed positive staining of the cells for CD20 (L26) (Fig 1: inset), a pan B cell marker, and negative staining for CD45RO (UCHL1), a pan T cell marker. The patient underwent anterior external beam radiotherapy to the right iris, receiving 1980 cGy in 11 equal fractions. Three months later, the visual acuity was 20/20 and there was no thickening of the iris in the right eye, although the iris was less mobile than the left and there was some persistent ectropion uvea of the pupillary margin (Fig 2).

#### COMMENT

Anterior segment intraocular lymphoma in the presence of a normal fundus is rare. The first case reported was one in which an iris nodule was confirmed to be a lymphomatous lesion histopathologically after enucleation.<sup>2</sup> To our knowledge, six other cases have been fully reported,<sup>2-5</sup> two presenting with non-granulomatous uveitis,<sup>3,4</sup> one with neovascular glaucoma,<sup>2</sup> and three with diffuse iris thickening.<sup>3,5</sup> In all six cases, as well as in this case, the iris lymphoma was associated with systemic non-Hodgkin's lymphoma, which had been previously diagnosed in five, rather than primary CNS lymphoma. This is not surprising as systemic lymphoma is typically associated with uveal tract ocular involvement,

whereas primary CNS lymphoma frequently involves the retina and optic nerve. However, it was unusual that all four of the six cases that reported cell type were T cell lymphoma<sup>3,5</sup> since only 5% of systemic lymphoma is of T cell or mycosis fungoides origin. As more cases of iris lymphoma are categorised accurately by immunofluorescent cell surface marker antigens, and as our case suggests, B cell iris lymphoma may be diagnosed more frequently. The mechanism of involvement of the right iris from the ipsilateral nasopharynx could have included direct extension along the sympathetic chain, CNS spread secondary to perineural involvement, or metastasis.

Three reported patients were treated with systemic chemotherapy,<sup>3,4</sup> two because of simultaneous recurrence of systemic lymphoma,<sup>2,3</sup> two were enucleated,<sup>3,5</sup> and one was treated with external beam radiotherapy.<sup>3</sup> One patient treated by systemic chemotherapy had progression of the ocular lesion but the other three cases treated conservatively regressed after therapy.

While combination chemotherapy is indicated for iris lymphoma with systemic involvement, we suggest external beam radiotherapy may be justified in isolated ocular cases. Radiation induced cataract is expected although this may not be a major consideration if life expectancy is short.

Support provided by the Eye Tumor Research Foundation, Philadelphia, PA, USA.

PHILIP G HYKIN  
 Ocular Oncology Service and the Retina Service,  
 Wills Eye Hospital,  
 Thomas Jefferson University, Philadelphia, PA, USA

JERRY A SHIELDS  
 CAROL L SHIELDS  
 Ocular Oncology Service, Wills Eye Hospital,  
 Thomas Jefferson University, Philadelphia, PA, USA

HORMOZ EHYA  
 Department of Pathology, Fox Chase Cancer Center,  
 Philadelphia, PA, USA

ELIZABETH SIDERIDES  
 St Joseph Medical Centre, Stamford, CT, USA

Correspondence to: Jerry A Shields, MD, Ocular Oncology Service, Wills Eye Hospital, 900 Walnut Street, Philadelphia, PA 19107, USA.

Accepted for publication 28 June 1996

- Shields JA, Shields CL. *Intraocular tumors: a text and atlas*. Philadelphia: WB Saunders, 1992:498-510.
- Locasio JA. Neoplastic causes of anterior segment inflammation. *Int Ophthalmol Clin* 1983; 23:111-21.
- Goldey SH, Stern GA, Oblon DJ, Mendenhall NP, Smith LJ, Duque RE. Immunophenotypic characterisation of an unusual T-cell lymphoma presenting as anterior uveitis. *Arch Ophthalmol* 1989;107:1349-53.
- Hanamura A, Maeda H, Kuwayama W, Takano Y. Infiltration into the aqueous humor in a patient with malignant lymphoma. *Jap J Clin Haematol* 1992;33:1845-50.
- Jensen OA, Johansen S, Kiss K. Intraocular T-cell lymphoma mimicking intraocular disease. *Graefes Arch Clin Exp Ophthalmol* 1994;32: 148-52.

### Treatment of subfoveal pigment epithelial detachments with distant extrafoveal choroidal neovascular membranes

EDITOR.—Subfoveal retinal pigment epithelial detachments larger than 1 disc diameter in patients over the age of 55 have a poor visual prognosis.<sup>1</sup> Laser photocoagulation of a contiguous extrafoveal choroidal neovascular membrane sometimes causes flattening of a retinal pigment epithelial detachment and