

**NORMAL RETINAL VASCULAR PATTERN\***  
**ARTERIOVENOUS RATIO AS A MEASURE OF ARTERIAL CALIBRE**

BY

N. L. STOKOE

*Department of Ophthalmology, University of Edinburgh, and Royal Infirmary, Edinburgh*

AND

R. W. D. TURNER

*Department of Medicine, University of Edinburgh, and Western General Hospital, Edinburgh*

THIS paper is the first of a series on the retinal vessels and is concerned with the normal range of the retinal vascular pattern. It is intended to serve as a foundation for a long-term study of the vascular changes in patients undergoing treatment for hypertension. In particular, its purpose is to expose fallacies in the customary method of assessing arteriolar calibre by the arteriovenous ratio and to discuss diffuse arteriolar narrowing as an early sign of hypertension.

In recent years the number of patients with severe hypertensive disease has considerably decreased. Presumably this is mainly due to the efficacy of modern anti-hypertensive drugs and the increasing tendency to treat patients relatively early before secondary changes have occurred. At all events, the proportion of patients with papilloedema and advanced hypertensive retinopathy or with severe clinical manifestations such as encephalopathy has decreased and, unless seen at the late stage of renal failure or following some important complication such as cerebral haemorrhage, most patients under treatment now survive at least for many years. As a result, the retinal changes of hypertension described in textbooks are unbalanced and there should be greater emphasis on the relatively early vascular changes than on retinopathy.

All physicians regard the fundus as an important guide to prognosis and take this into consideration in deciding whether or not the patient should be treated. The ophthalmologist who is requested to give an opinion is now frequently confronted with an earlier stage in the retinal picture in the form of pure arteriolar changes with minimal, if any, exudates or haemorrhages. It is clear, however, that there is much confusion with regard to the earlier changes which involve arteriolar calibre, tortuosity, or straightening, and the arteriovenous crossings.

From our observations there can be no doubt that there is considerable variation in calibre and tortuosity throughout the healthy population and this may, in part, account for conflicting statements in published work.

---

\* Received for publication January 28, 1965.

### Ageing

According to Ballantyne (1937), Friedenwald (1947), and Leishman (1952), the retinal arterioles become narrower and straighter with ageing; according to Elwyn (1954) they become wider and more tortuous; according to Vogelius and Bechgaard (1950) narrower, but not more tortuous; and according to Wolff (1953) narrower and more tortuous. Pines (1929), however, states that the calibre and tortuosity are unchanged with increasing age.

### Hypertension

Fishberg (1954) states that increased tortuosity of the arterioles is a frequent manifestation of hypertensive arteriosclerosis, but healthy vessels may also be quite tortuous, so that caution must be exercised. He says that, in his experience, it has been rare for the retinal arterioles in a patient with pronounced hypertension not to be narrowed, and such vessels are often found in youthful patients in whom the elevation of pressure has been modest and even intermittent.

Ballantyne (1937) states that widening and tortuosity of the arterioles may be an early sign of hypertension, but Leishman (1957) describes these changes as late phenomena due to loss of resilience from sclerosis.

Crick (1951) maintains that in younger age-groups (under 55 years) hypertension may be associated with arteriolosclerosis in which the vessels are full and tortuous and subject to spasm, and that later they tend to become narrowed and straighter.

Wagener (1935) considers that the initial changes in the retinal arterioles in hypertension are narrowing, pallor of the entire width of the arteriolar column, and accentuation of the reflex stripe. Gowers (1876) states that narrowing of the arterioles is the first change in the fundus in hypertension. Shelburne (1957) includes marked generalized constriction, in addition to marked segmental constriction of the arterioles and moderate or definite arteriovenous nicking, in a triad of retinal arteriolar lesions peculiar to hypertensive disease. He qualifies this observation by stating that slight or moderate general and segmental arteriolar constriction, although common in hypertensive disease, may also be found in non-hypertensive patients, especially the aged.

Boyd and de Margerie (1960) find a weak tendency for arteriolar calibre to decrease with increasing age and a rather stronger tendency for it to decrease with increasing blood pressure, especially in younger subjects. However, there is such a wide scatter and so much overlapping in all age-groups and at all levels of blood pressure that they consider that this change will be of little value in practice.

In its report to the American Ophthalmological Society (Wagener, Clay, and Gipner, 1947), a Committee appointed to classify hypertensive disease of the retina concluded that three distinct types of alteration occur in the retinal arterioles in the phases of hypertensive disease:

- (a) Generalized narrowing (probably representing increased tone in the arterioles).
- (b) Sclerosis (organic thickening of the wall of the arterioles indicated by reflex enhancement and arteriovenous crossing changes).
- (c) Focal constriction ("spasm").

It is evident that there is much confusion and conflict of opinion, but probably most workers consider narrowing of the retinal arterioles to be an important early manifestation of hypertension. This, in fact, constitutes part of Group 1 of the widely used Keith–Wagener classification (Keith, Wagener, and Barker, 1939). Although this classification is in almost universal use by physicians, it is often misquoted.

### Keith–Wagener Classification

The original grouping recommended by Keith, Wagener, and Barker (1939) was not confined to retinal changes but included the clinical picture. The essence of the classification as regards the fundi is as follows:

Group 1.—Mild narrowing or sclerosis of the retinal arterioles.

Group 2.—Moderate to marked sclerosis of the retinal arterioles with exaggerated light reflex, arteriovenous compression, and irregular narrowing of the arterioles.

Group 3.—The above changes together with exudates, haemorrhages, and retinal oedema.

Group 4.—Measurable oedema of the disc in addition to the changes of Group 3.

They mention that thrombosis of the retinal veins may occur in Group 2.

Although the introduction of this classification did much to emphasize the importance and value of examination of the fundi in patients with hypertension it has, paradoxically, become responsible for much relatively casual examination and description. In order that serial comparisons can be made, as previously emphasized (Turner, 1959), we are certain that it is more valuable to describe the fundus changes in detail rather than by numerical grading. The changes may not be the same in the two eyes or in different quadrants of the same eye. In view of the contradictory statements, to which reference has been made above, especially as regards the early retinal signs in hypertension and the emphasis placed on diffuse arteriolar narrowing, we considered it important to establish the normal range of the retinal vascular pattern as a preliminary to a long-term study of the vascular changes in patients undergoing treatment for hypertension.

In order to assess whether the retinal arterioles are narrowed, it is common practice to estimate the arteriovenous ratio, but sufficient care is rarely taken to ensure that the two vessels are of a comparable order of division, because this is difficult, tedious, time-consuming, and often impossible by casual ophthalmoscopy. In fact, it has been surprising to find how often there is difficulty, even by careful study of good quality retinal photographs.

The ratio has been normally regarded as 2 : 3 (Leatham, 1949), 2 : 3 to 3 : 4 (Gowers, 1879; Fishberg, 1954), 3 : 5 to 5 : 5 (Nicholls, Turnbull, and Evelyn, 1956), and 4 : 5 or 5 : 5 (Wood, 1956).

Although the shortcomings of the arteriovenous ratio as an index of arteriolar calibre have been pointed out before (Evelyn, Nicholls, and Turnbull, 1958; Turner, 1959), one of the main purposes of this paper is to expose these fallacies in detail and to examine whether it is feasible to estimate the presence of arteriolar narrowing ophthalmoscopically without recourse to special methods of measurement. It has been our conviction that, unless extreme, narrowing is difficult or impossible to assess

by ordinary ophthalmoscopy. In the classification employed by Scheie (1953), which grades the changes of hypertension and arteriosclerosis separately, it is admitted that Grade 1 changes of arteriolar narrowing may be overlooked if the patient has not been referred with the diagnosis of hypertension.

### Anatomy

The retinal vessels distal to the second divisions of the central artery are arteriolar in structure rather than arterial (Friedenwald, 1940) and consequently more important than the larger, more central vessels as regards changes due to hypertension. However, in this paper, for purposes of description and according to common practice, the more convenient terms "artery" and "vein" are used throughout rather than the more accurate ones of "arteriole" and "venule".

The central artery, on entering the eye, divides into branches, termed by Duke-Elder (1932) the superior and inferior papillary arteries, each of which gives off temporal and nasal branches near the upper and lower borders of the disc (Fig. 1).

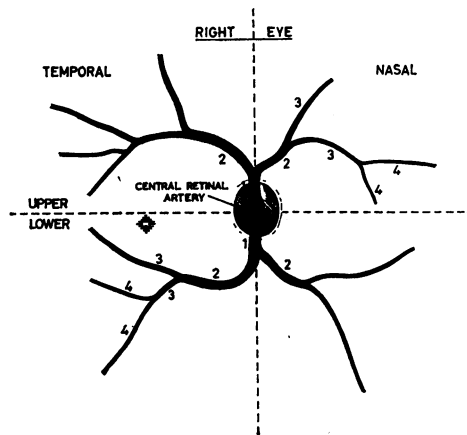


FIG. 1.—Conventional distribution of central retinal artery. The numbers indicate the order of division of each branch (primary, secondary, tertiary, or quaternary).

The larger and more central veins usually run in fairly close association with the arteries, but more peripherally they tend to be dissociated. The temporal and nasal veins unite to form the superior and inferior papillary veins which, in turn, unite to form the central retinal vein at the level of the lamina cribrosa. This takes place proximal to the division of the artery into its primary branches, which usually occurs in the retinal portion of the optic nerve, as pointed out by Wolff (1948).

The selection of comparable artery and vein for assessment of the arteriovenous ratio depends on the hypothesis that the central retinal artery and vein have a similar and proportionate order of branching. Clearly an artery of second order must be accompanied by a vein of the same order for accurate comparison. Where an artery divides unequally and there is a similar inequality in the division of the vein, the larger arterial branch must be compared with the larger venous branch and the

smaller with the smaller (Figs 2 and 3). In our studies of large numbers of retinal photographs it soon became obvious that a simple branching of this kind seldom occurs in more than two of the four quadrants in each eye and frequently is not present in any.

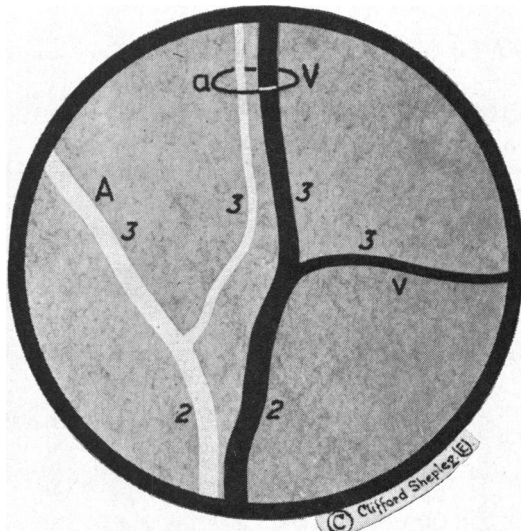
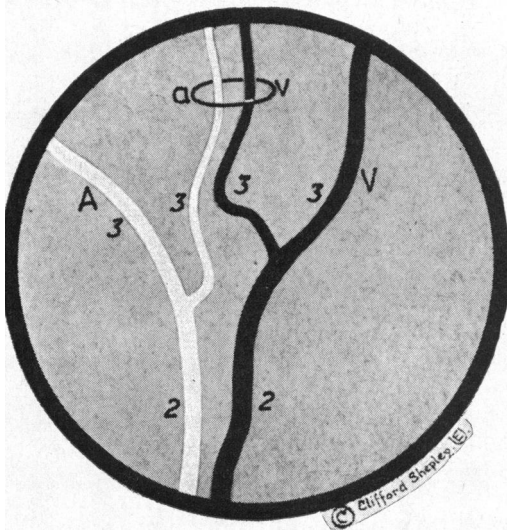


FIG. 2.—Mirror pattern in vessels of the same order of division. The homologous (similarly orientated) branches are A and v, a and V. In estimating the A-V ratio, the smaller branches a and v or the larger A and V must be compared, even though they are non-homologous.

FIG. 3.—Vessels of the same order of division. In estimating the A-V ratio, the homologous branches A and V or a and v (not the looped pair) must be compared, even though they are not in close proximity.

Although it is true that superficially acceptable pairing of the largest vessels may be present in most quadrants, closer examination often reveals that the vessels selected are not, in fact, of a comparable order of division, and the analysis is frequently complicated by the presence of smaller vessels which are nevertheless of important size from the point of view of blood supply.

#### Method and Clinical Material

In order to test the validity of our clinical impression that the selection of comparable vessels by ophthalmoscopy for the estimation of the arteriovenous ratio, apart from being laborious and difficult, is often inaccurate, this project was begun by one of us in conjunction with Dr. de Margerie. Studies were made by the present authors of a random selection of 10 retinal photographs in each of 8 decades from a series of 646 photographs of normal persons, taken by Dr. de Margerie, to whom we are indebted for their further use. This series of 80 photographs (Group A) extended to  $2\frac{1}{2}$  disc diameters from the edge of the optic disc. In order to determine whether the examination of more peripheral fields would facilitate the selection of comparable pairs of vessels for the assessment of the A-V ratio, a further series of 40 fundi were studied. These were selected at random from 200 panoramic retinal photographs which we took with the Bausch and Lomb (carbon arc) or new Zeiss (electronic flash) fundus cameras of normal persons (Group B). These incorporated a field extending to at least 5 disc diameters from the edge of the optic disc. Figs 4 to 11 on pp. 26-32 represent the photographs in Group A and Figs 12 and 13 on p. 33, those in Group B.

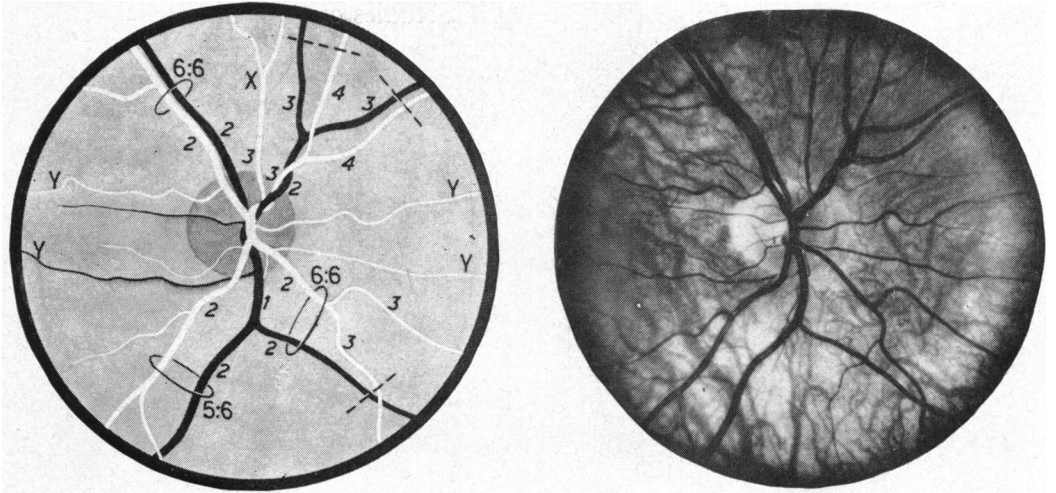


FIG. 4.—Group A. Under 10 years. Loops indicate comparable pairs. Broken lines indicate non-comparable pairs. This convention is used in all diagrams.

*Upper half:* Comparable branching in upper temporal quadrant. Non-comparable branching in upper nasal quadrant, unless X is ignored. X cannot be ignored because other vessels of similar size are included. YYY would be ignored as they are small and there are similar vessels in both halves.

*Lower half:* Comparable branching in lower temporal quadrant. Non-comparable branching in lower nasal quadrant except close to disc.

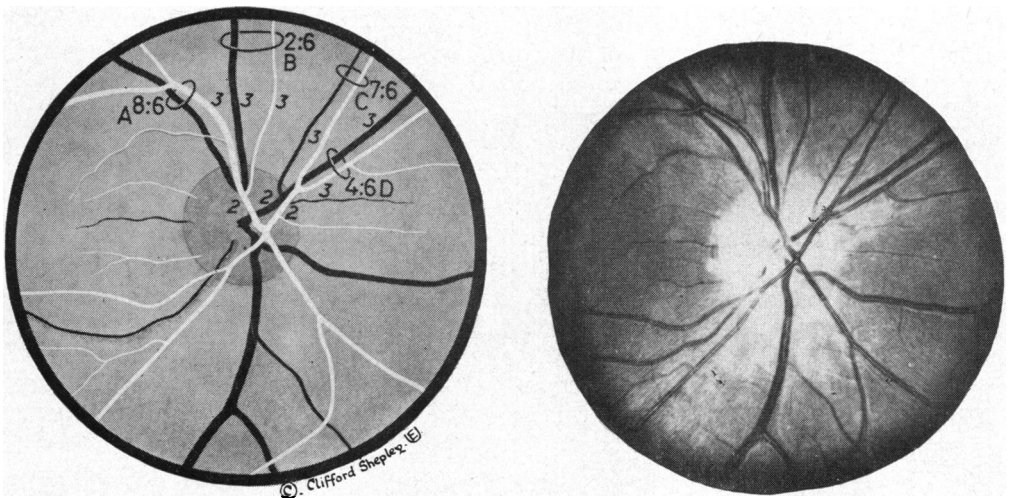


FIG. 5(a).—Group A. 10 to 19 years.

*Upper half:* Varying ratios in upper temporal and upper nasal quadrants. In practice the pair B would be ignored because the artery is small. C and D give different ratios but D and not C would be taken in practice because the vessels are larger.

*Lower half:* Asymmetrical venous drainage makes pairing impossible.





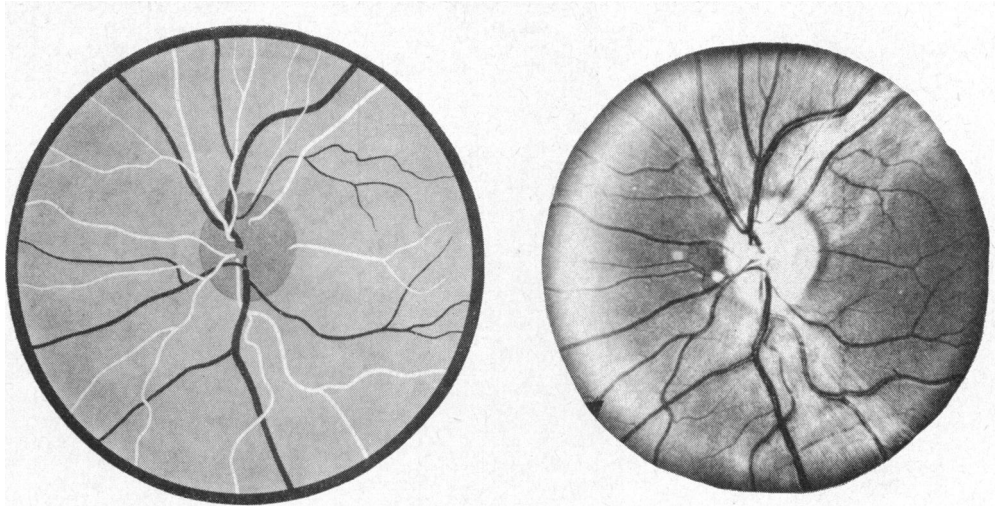


FIG. 6(b).—Group A. 20 to 29 years.  
Complex multiple branching; analysis impossible. Contrast with Fig. 9(b).

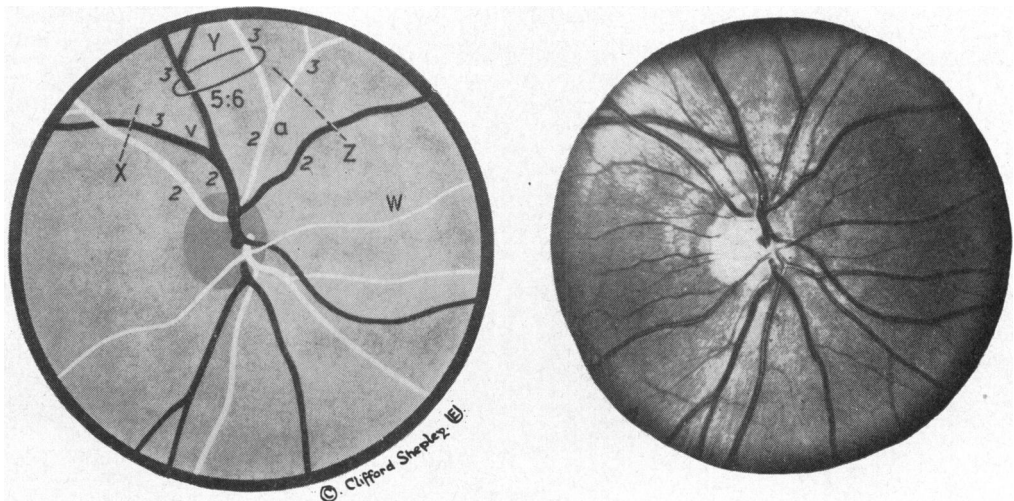


FIG. 7(a).—Group A. 30 to 39 years.

*Upper half:* In temporal quadrant vein divides (at v) but artery divides much more peripherally. In nasal quadrant artery divides (at a) but vein does not. Good example of mirror pattern (see Fig. 2). Comparable pairing at Y, although not strictly homologous. Non-comparable pairing at X and Z.

*Lower half:* Complex early branching makes comparison impossible. Artery at W with origin from inferior papillary artery supplies upper nasal quadrant.



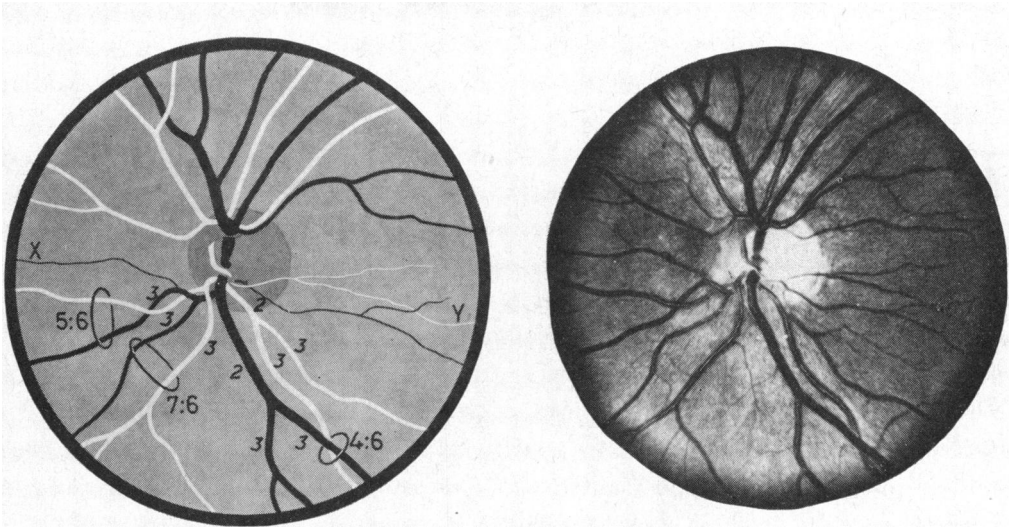


FIG. 7(b).—Group A. 30 to 39 years.

*Upper half:* Complex early branching makes comparison impossible.

*Lower half:* Variable ratios in comparable branches provided that X and Y are excluded.

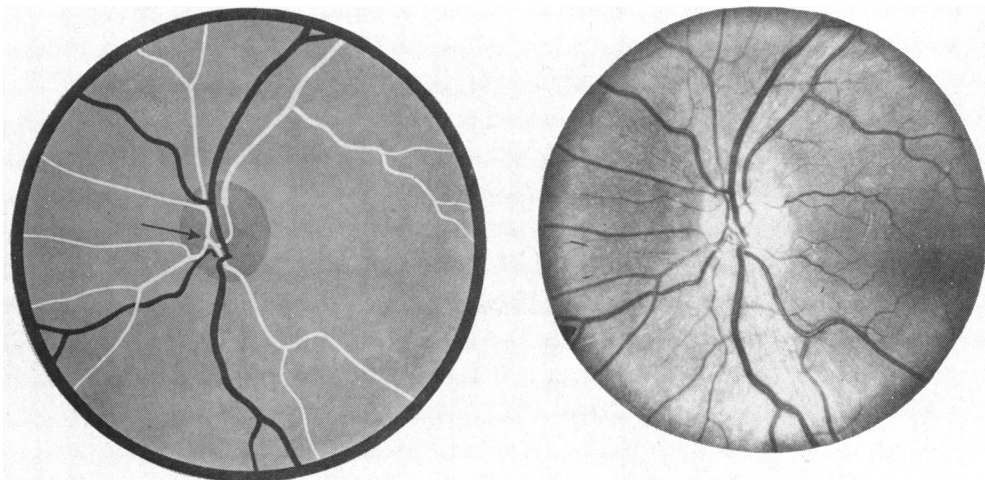


FIG. 7(c).—Group A. 30 to 39 years.

Anomalous arterial supply to nasal quadrants; upper and lower nasal arteries arise from common stem.

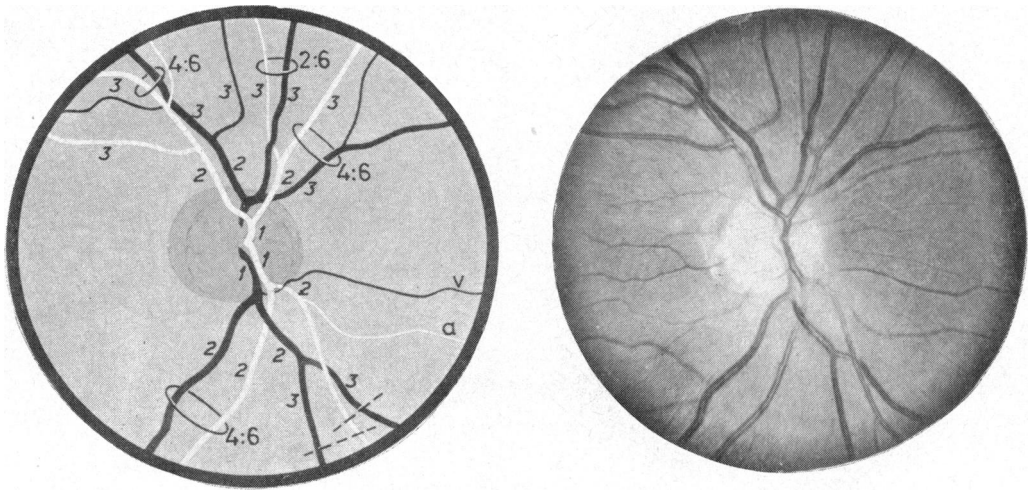


FIG. 8.—Group A. 40 to 49 years.

*Upper temporal:* Mirror pattern (see Fig. 2) but acceptable pairing.

*Lower nasal:* In practice a would be ignored, being of small size and in any case paired with v, leaving one artery and two veins which are not acceptable for pairing. If a is included there would be two pairs with different A-V ratios.

This illustrates the arbitrariness of selection.

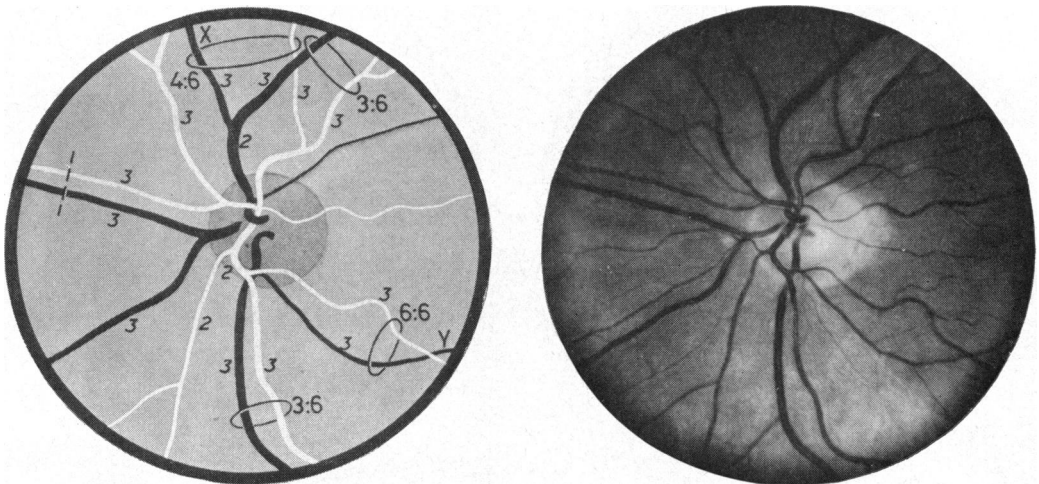


FIG. 9(a).—Group A. 50 to 59 years.

*Nasal half:* Common stem for upper and lower nasal veins but not for nasal arteries.

*Temporal half:* Ratios of main pairs 3 : 6. Vessels X (4 : 6) and Y (6 : 6) would normally not be considered.

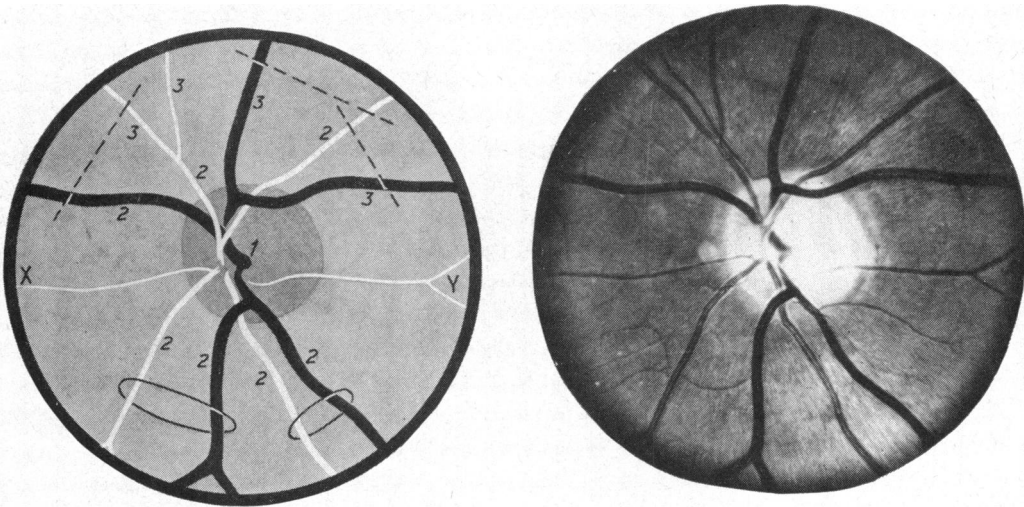


FIG. 9(b).—Group A. 50 to 59 years.

*Upper half:* Two arteries to one vein in nasal quadrant. One artery to two veins in temporal quadrant. Note paucity of branching in all quadrants (contrast with Fig. 6(b)). X and Y have been ignored because these vessels are small compared with the main vessels.

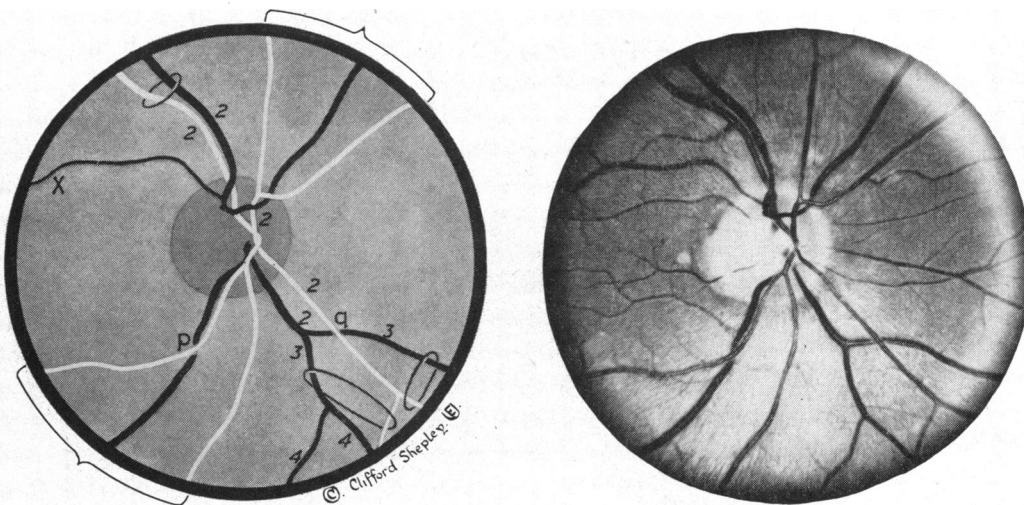


FIG. 10.—Group A. 60 to 69 years.

*Upper temporal:* Pairing only acceptable in this quadrant if fairly large branch X is ignored.

*Upper nasal:* Two arteries to one vein.

*Lower temporal:* Two arteries to one vein as in upper nasal. Note concealment of vein at A-V crossing (p) in a patient without hypertension.

*Lower nasal:* Concealment of vein at q.

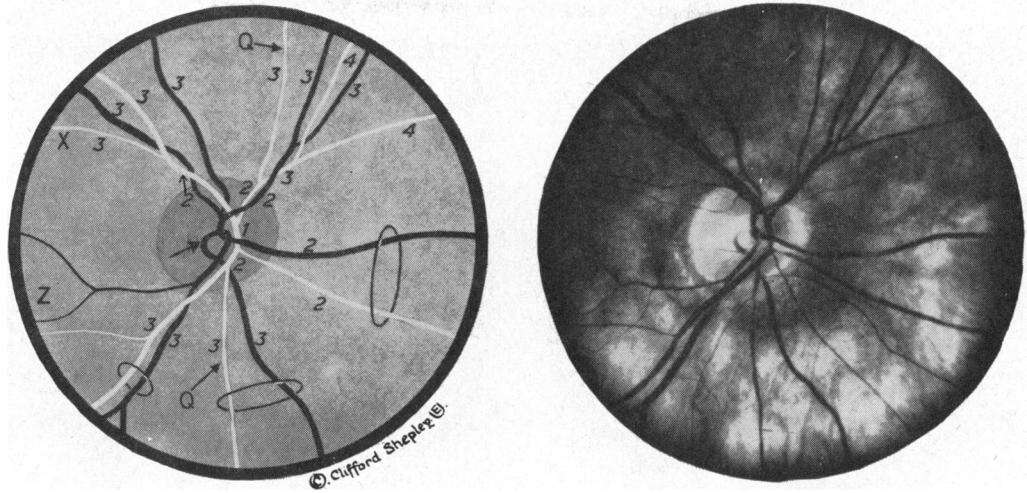


FIG. 11(a).—Group A. 70 to 79 years.

*Upper temporal:* Comparable pairing would only be possible if small vessel X is included.  
*Lower half:* Functional pairing appears to be satisfactory but it is impossible to be certain of the precise origin of the vein owing to an abnormal loop (arrow) at the centre of the disc. Note arterial calibre variations without hypertension in some vessels (Q, Q). Small vessels as at Z have been ignored.

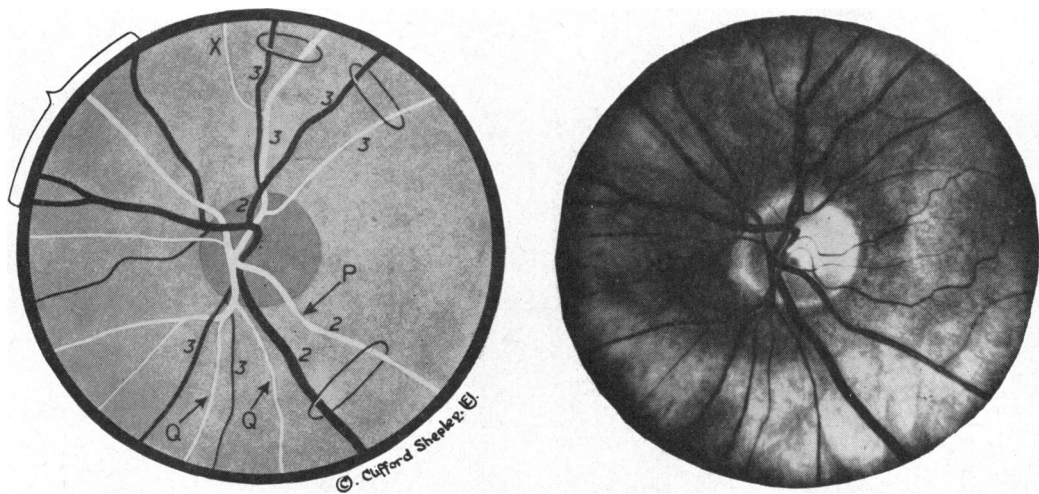


FIG. 11(b).—Group A. 70 to 79 years.

*Upper temporal:* Small vessel X is ignored.  
*Upper nasal:* Two veins to one artery.  
*Lower half:* Arterial calibre variations without hypertension. Focal narrowing (P). Beading from multiple calibre variations (Q).

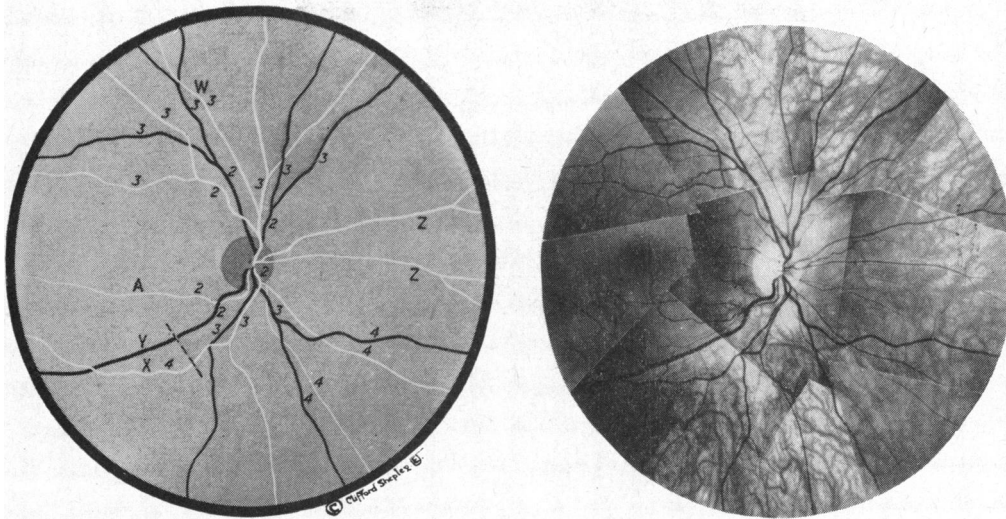


FIG. 12.—Group B. (1) The vessels at Z have to be ignored in order to make any attempt at analysing the order of division. They are of fairly large size so that this is an arbitrary decision. (2) The main arteries to the upper half divide asymmetrically. (3) There is overlapping of the distribution of arterial supply between the quadrants of the upper and nasal halves. (4) The lower temporal vessel X superficially appears to match the vein Y but the order of division is dissimilar even if A is ignored. (5) The arteries are too fine for consideration in the lower nasal quadrant.

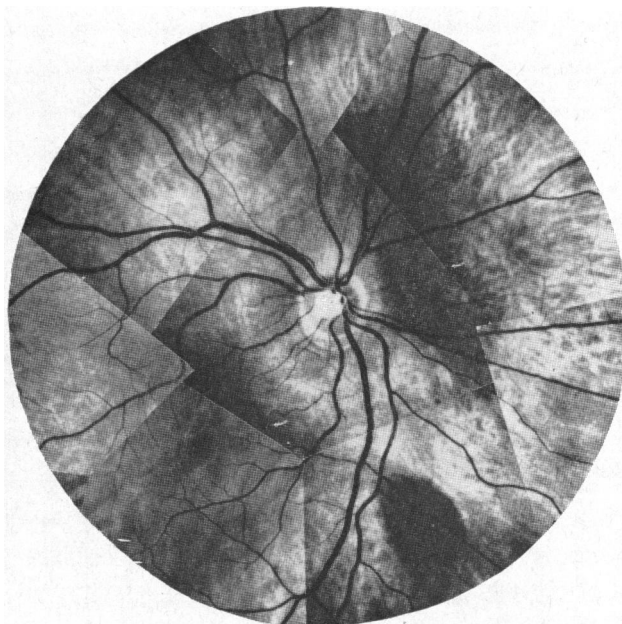


FIG. 13.—The division of the central retinal artery into superior and inferior papillary arteries is concealed. The determination of branching order for assessment of A-V ratio is mere guesswork.



Each retinal photograph was sketched and the vessels numbered according to their order of division as referred to in the section on anatomy (see Figs). Taking into account the numerous difficulties discussed below, an attempt was made in each quadrant to select an artery and vein of a comparable order of division for assessment of the A-V ratio. Comparable vessels have a similar order of branching (secondary, tertiary, or quaternary) and a similar orientation, that is to say, lie in reasonable proximity one to another. Vessels which could only be paired in close proximity to the disc, that is within one-half disc diameter of the margin, were subtracted from the final count because, in clinical practice, the appearance of vessel calibre close to the disc may be influenced by glial tissue or perivascular sheathing and, as previously mentioned, may not be arteriolar in structure. Ratios were determined by visual inspection of retinal photographs by each observer and, in cases of doubt, a magnifying lens with attached scale was used.

### Difficulties in Choosing Comparable Vessels

There are numerous difficulties which may be encountered in choosing comparable pairs of retinal vessels:

- (1) An upper branch may supply a lower quadrant or vice versa (Fig. 7a at W).
- (2) Some tributaries or branches have no paired artery (Fig. 10 at X) or vein (Fig. 6a at W).
- (3) There may be two arteries to one vein (Fig. 10) or one artery to two veins (Fig. 9b).
- (4) Multiple branching may occur making the selection of comparable pairs impossible (Fig. 6b).
- (5) An artery may divide equally into two branches, but its companion vein disproportionately or vice versa (Fig. 5a at C and D). For this reason ratios may vary, not only between the quadrants in the same fundus, but also in different parts of the same quadrant.
- (6) The artery and vein may each branch unequally (Fig. 6a at X, Y, Z). It is obviously necessary to compare the two wider vessels and the two narrower even though, strictly speaking, they are not homologous branches.
- (7) Although trifurcations are rare, the origins of successive branches from the same trunk are sometimes very close together, particularly near the entrance of the optic nerve. This makes the assessment of branching order difficult or impossible (Fig. 7b, upper half).
- (8) When the central retinal artery divides early or the central vein begins late (proximal to the lamina cribrosa) the determination of branching order becomes mere guesswork because the central portion of the superior and inferior papillary vessels and sometimes their first branches are concealed (Fig. 13).
- (9) Sometimes the upper and lower arteries to the nasal quadrants arise from a common stem near the disc (Fig. 7c). In other cases there is a similar venous anomaly (Fig. 9a).
- (10) Small unpaired retinal arteries (apart from cilio-retinals) frequently run to right or left from the margin of the disc in the horizontal meridian and, in order to make a practical analysis, such vessels have to be ignored (Fig. 4 at Y and Fig. 9b at Y).
- (11) Numerous other small branches which are really off-shoots rather than divisions of the major vessels likewise have to be ignored (Fig. 7b at X). However, the border line between a small branch which should be ignored and a rather larger branch which has to be included, being of functional significance, is arbitrary.

The selection of paired vessels is rarely facilitated by considering a wider panoramic field, because arborization increases towards the periphery (Fig. 12).

In summary, it is concluded that there are many common variants to the retinal vascular branching system and a simple symmetrical arterial and venous pattern is unusual.

**Results**

In Group A (Table I), out of 80 fundi examined, no comparable pairs could be found in 10, comparable pairs were found in only one quadrant of each of 14, and at best in only two quadrants of each of 34 fundi. In Group B (Table II), out of 40 fundi no comparable pairs could be found in 6, comparable vessels were found in only one quadrant of each of 15, and at best in only two quadrants of each of 17 fundi. Expressed in another way, comparable pairs of vessels were present only in 153 out of 320 quadrants examined (48 per cent.) in Group A (Table III) and in 56 out of 160 (35 per cent.) in Group B (Table IV).

TABLE I

GROUP A. AVAILABILITY OF COMPARABLE PAIRS OF VESSELS IN NORMAL FUNDI WITH FIELD UP TO 2½ DISC DIAMETERS FROM DISC MARGIN. RANDOM SELECTION OF 10 EYES PER DECADE (FROM A TOTAL OF 646)

Available Quadrants	Number of Eyes with Comparable Pairs in Each Decade								
	<10 years	10-19 years	20-29 years	30-39 years	40-49 years	50-59 years	60-69 years	70-79 years	Total
None	1	3	1	1	0	2	0	2	10
One	2	3	1	1	3	1	2	1	14
Two	5	2	6	4	4	4	5	4	34
Three	1	2	1	4	3	2	1	3	17
Four	1	0	1	0	0	1	2	0	5

TABLE II

GROUP B. AVAILABILITY OF COMPARABLE PAIRS OF VESSELS IN NORMAL FUNDI IN FIELDS UP TO 5-6 DISC DIAMETERS FROM THE DISC MARGIN. RANDOM SELECTION OF 20 PATIENTS (40 EYES FROM A TOTAL OF 200)

No. of Quadrants in Each Eye with a Comparable Pair of Vessels	No. of Eyes with a Comparable Pair of Vessels
0	6
1	15
2	17
3	1
4	1

These figures of 48 per cent. and 35 per cent. are, in fact, weighted against our conclusions because in border-line cases vessels were, as a matter of practical policy, accepted as comparable.

Finally, retinal photographs selected at random from each of the eight decades in Group A and one sample from Group B have been reproduced, together with a



descriptive analysis, in order to illustrate difficulties involved in selecting comparable vessels for the purpose of measuring the A-V ratio (Figs 4 to 12).

It will be noted that, in some cases, the A-V ratio may vary not only between different quadrants of the same fundus but also between vessels of the same quadrant (Figs 5a, 5b). As already pointed out, misleading ratios may be obtained if two non-homologous branches are compared (Fig. 3), or two homologous branches in a mirror pattern (Fig. 2), even though these have the same order of division.

TABLE III  
GROUP A. AVAILABILITY OF COMPARABLE PAIRS OF VESSELS IN 80 NORMAL FUNDI (320 QUADRANTS)  
WITH THE ORDER OF DIVISION AT WHICH ACCEPTABLE PAIRING OCCURRED

Decades (yrs.)	Total No. of Quadrants with Comparable Pairs				Order of Division with Acceptable Pairing											
	Temporal	Nasal	Total	*	2 0 3 0	*2 0 3 0	0 3* 2 3	2 0 2 2*	0 0 2 3	4 0 3 0	3 0 2 3	*2 0 0 0	3 3 2 2	*2 2* 2 3		
< 10	13	6	19	7	2 0 3 0	*2 0 3 0	0 3* 2 3	2 0 2 2*	0 0 2 3	4 0 3 0	3 0 2 3	*2 0 0 0	3 3 2 2	*2 2* 2 3		
10-19	6	7	13	5	3 3 0 0	0 2 2 2	0 0 0 0	*2 2* 0 2	*2 0 2 0	*3 3 0 0	3 0 3 2	0 0 *2 0	3 2 0 0	0 0 0 0		
20-29	12	8	20	3	2 0 2 0	0 0 2 2	*2 0 2 0	*2 0 2 2	3 3 3 4	3 0 2 2	0 0 3 2	2 0 0 2	0 2* 3 2	0 0 0 0		
30-39	10	11	21	1	0 3 2 3	3 0 3 3	3 0 0 0	*2 2 2 2	0 0 3 3	0 3 2 3	0 0 0 0	2 3 0 0	0 0 2 2	0 0 3 3		
40-49	12	8	20	7	*2 0 *2 3	*2 0 2 2*	3 3 0 0	0 0 2 2	2 4 3 0	0 0 2 0	3 3 2 0	*2 0 2 2	0 3 2 2*	2 2* 2 2		
50-59	10	9	19	4	3 0 3 0	2 3 *2 2	3 2* *2 2	0 0 0 0	0 0 2 2	0 0 0 2	0 2* 0 0	3 0 2 2	0 0 3 3	2 3 2 3		
60-69	12	11	23	2	2 3 0 0	1 0 0 0	3 3 3 3	0 3 2 0	0 2 3 0	2 0 *2 2	3 2* 0 2	0 0 3 0	3 3 0 3	3 3 3 3		
70-79	13	5	18	3	3 2* 3 3	3 0 2 0	3 0 2 2	0 0 0 0	2 0 3 2*	0 0 0 0	0 3 0 0	2 0 2 2*	0 3 2 2	2 0 2 0		
Total	88	65	153	32												

Random selection of 10 eyes in each of 8 decades taken from 646 patients. The numbers in the third column represent the order of division in each quadrant at which acceptable pairing of an artery and vein occurred.

0 = no comparable pairs. \* = excluded because acceptable pairing only possible near the disc (see text).

Temporal half on left, thus:

Upper temporal	Upper nasal
Lower temporal	Lower nasal

Comparable pairs only present in 153 out of 320 quadrants (48 per cent.). They occur more frequently in the temporal half.

It will be seen from Table III that it is rather easier to obtain comparable vessels on the temporal side of the fundus. This is because vessels in the temporal half of the retina tend to be wider and not so erratic in their branching. As will be subsequently shown in a later study, satisfactory arteriovenous crossings are likewise easier to find on the temporal side.

Taking a larger field and pairing artery and vein further from the disc increases the problem of selection, because arborization and the number of small unpaired vessels increases.

TABLE IV  
GROUP B. AVAILABILITY OF COMPARABLE PAIRS OF VESSELS IN 20 NORMAL SUBJECTS  
(160 QUADRANTS)

Case No.	LEFT EYE					RIGHT EYE					Total No. of Quadrants with Comparable Pairs
	No. of Quadrants with Comparable Pairs and Order of Division at which they occurred			No. of Quadrants with no Comparable Pairs	Not Acceptable*	No. of Quadrants with Comparable Pairs and Order of Division at which they occurred			No. of Quadrants with no Comparable Pairs	Not Acceptable*	
	2nd order	3rd order	4th order			2nd order	3rd order	4th order			
1	2	2	0	0	0	1	1	0	2	0	6
2	0	2	0	2	0	0	1	0	2	1	3
3	0	1	0	2	1	0	1	0	2	1	2
4	0	2	0	2	0	1	0	0	2	1	3
5	0	0	0	4	0	0	1	0	2	1	1
6	0	1	0	3	0	0	1	1	1	1	3
7	2	0	0	1	1	0	1	0	3	0	3
8	0	2	0	2	0	0	0	0	4	0	2
9	0	2	0	2	0	0	1	0	3	0	3
10	0	1	0	3	0	0	0	0	4	0	1
11	1	1	0	2	0	0	0	0	4	0	2
12	1	0	0	3	0	1	1	0	1	1	3
13	0	2	1	1	0	0	1	1	2	0	5
14	0	0	0	4	0	0	1	0	3	0	1
15	0	1	0	3	0	0	0	0	4	0	1
16	0	1	0	3	0	0	2	0	2	0	3
17	2	0	0	2	0	1	1	0	2	0	4
18	1	1	0	2	0	0	2	0	2	0	4
19	0	1	0	2	1	1	0	1	1	1	3
20	0	1	0	3	0	1	1	0	2	0	3
Total	9	21	1	46	3	6	16	3	48	7	56

This table indicates the number of fundus quadrants in series B with a comparable pair of vessels and the order of division at which they occurred. Comparable pairs only present in 56 out of 160 quadrants (35 per cent.).

\* = Excluded because acceptable pairing only possible near the disc (see text).

As illustrated in Figs 11a, b, variations in arterial calibre may occur in elderly normotensive subjects. In high myopes, both arteries and veins may be conspicuously narrowed, presumably due to post-equatorial elongation of the globe.

It is quite clear from our analysis of a random selection of 120 photographs taken from the total collection of 800, that the range of arterial calibre in each decade is so wide that, in the individual case at any age, no pronouncement can be made as regards absolute calibre.

### Discussion

Although aware of its shortcomings, Nicholls, Turnbull, and Evelyn (1956) used the A-V ratio to evaluate arterial calibre in patients with hypertension. They found little difference in the Keith-Wagener Groups 1, 2, and 3, and only in Group 4 was

there an appreciable reduction in calibre. They concluded that arterial calibre is not a good index of the degree of hypertension nor of the time it has existed. Later (Evelyn, Nicholls, and Turnbull, 1958) they stated: "In the case of generalized arteriolar narrowing as measured by the A-V ratio, the margin of error, though quite small, is relatively large when compared with the magnitude of the difference between normotensives and hypertensives (in the absence of papilloedema)."

We consider that a ratio is never desirable as an index of change in that there are two variables. However, it is conceded that the veins are relatively constant in calibre unless there is some complicating condition such as raised intracranial pressure associated with papilloedema, or central or local venous obstruction in the retina.

It will be appreciated that only a very slight degree of vasoconstriction over a large vascular bed is sufficient to account for a severe degree of hypertension, because the blood pressure varies directly with the cardiac output but inversely as the fourth power of the radius of the vessel. An overall reduction in calibre of no more than one-sixteenth could produce a blood pressure of twice normal (240/160), and it would hardly be possible to appreciate such a slight degree of narrowing by ophthalmoscopy.

From the evidence produced in this paper as regards the A-V ratio, it is clear that the frequently quoted sign of diffuse narrowing of the retinal arteries as an early manifestation of hypertension is unreliable unless extreme, as may occur in acute toxæmia of pregnancy or acute glomerulonephritis, particularly when judged by impression on casual ophthalmoscopy. Owing to variations in the pattern of branching, estimates of absolute calibre in different fundi, even if measured with a graticule, are at best an approximation and can be no more than an average value for the individual person. Even monozygotic twins with similar discs, maculae, and refractive errors may show dissimilar retinal vascular patterns and, according to Wood (1948), the normal optic disc may be classified into ten distinct types based on the distribution of the main branches of the central retinal artery.

Although the prognosis of hypertensive disease cannot be based solely on examination of the fundi, the retinal vessels are an important ancillary guide as to whether or not an individual patient should be treated on a life-long basis with preparations which are all associated with unpleasant or serious side-effects. If, in a given case, the retinal vessels are within the normal range, then it should at least be seriously considered whether treatment is necessary at all. The decision will, of course, be made in the light of all the clinical information including age, sex, family history, fixity of diastolic pressures, and evidence of left ventricular hypertrophy.

Irregularities in arterial calibre, as we have shown, may occur in elderly normotensive subjects, but there is general agreement that marked focal constrictions or variations in calibre in middle-aged and younger persons are a reliable indication of hypertensive disease.

Instead of the usual practice of describing the fundi as "Keith-Wagener Group 1 or 2" and so on, or vaguely referring to arterial narrowing or reflex enhancement, the four quadrants in each fundus should be carefully examined through fully dilated pupils and the exact changes of calibre variation, sheathing, or arteriovenous crossing abnormalities should be recorded with a note of their severity.

### Summary

(1) The number of patients attending hospital with hypertensive retinopathy has decreased owing to the efficacy of modern treatment, and there should be greater emphasis on the relatively early vascular changes than on retinopathy.

(2) There can be certainty over local variations in arteriolar calibre and in changes at the arteriovenous crossings, but not as regards diffuse narrowing, straightening, or tortuosity, owing to wide variations in the normal population and difficulties of measurement.

(3) There are fallacies in the customary method of assessing arteriolar calibre by the arteriovenous ratio.

(4) In view of the contradictory statements in published work and the emphasis placed on diffuse arteriolar narrowing, it was considered important to study the normal retinal vascular pattern as a preliminary to serial observations on the vascular changes in patients undergoing treatment for hypertension.

(5) The arteriovenous ratio is obviously useless as a guide to arteriolar calibre unless two vessels of a comparable order of division are selected, but it has been shown that this is difficult, tedious, and often impossible by casual ophthalmoscopy, or even by retinal photography.

(6) A random selection of 10 fundi in each of 8 decades taken from a series of 646 central retinal photographs in normal persons, and a random selection of 40 fundi from 200 panoramic retinal photographs were studied.

(7) In the first group of 80 fundi comparable pairs could not be found in any quadrant in 10, and in only one quadrant in each of 14 cases. In the second group comparable pairs could not be found in any quadrant in 6, and in only one quadrant in each of 15 cases. Comparable pairs were found only in 48 per cent. of the total quadrants in the first group and in 35 per cent. in the second.

(8) In some cases the arteriovenous ratio varied not only between different quadrants of the same fundus, but also between vessels of the same quadrant.

(9) Numerous difficulties in choosing comparable pairs of vessels are described and illustrated.

(10) Reasons are given for abandoning the classification of Keith, Wagener, and Barker (1939). It is better to describe the changes present in each quadrant and their severity. This also facilitates serial comparison.

(11) It is clear that the frequently quoted sign of diffuse narrowing of the retinal arterioles as an early manifestation of hypertension is unreliable.

We are indebted to Mr. Ronald Stewart and Mr. Paul Bisson of the Edinburgh University Department of Medical Photography for the photographic work, and to Mr. Clifford Shepley of the Edinburgh University Department of Medical Illustration for the fundus drawings.

This project is being supported by the Scottish Hospital Endowments Research Trust, and the W. H. Ross Foundation (Scotland) for the Study of Prevention of Blindness.

## REFERENCES

- BALLANTYNE, A. J. (1937). *Trans. ophthalm. Soc. U.K.*, **57**, 301.
- BOYD, T. A. S., and DE MARGERIE, J. (1960). *Trans. Canad. ophthalm. Soc.*, **23**, 65.
- CRICK, R. P. (1951). In "Systemic Ophthalmology", ed. A. Sorsby, p. 528. Butterworth, London.
- DUKE-ELDER, W. S. (1932). "Text-book of Ophthalmology", vol. I, p. 141. Kimpton, London.
- ELWYN, H. (1954). "Diseases of the Retina", 2nd ed., p. 17. Blakiston, New York.
- EVELYN, K. A., NICHOLLS, J. V. V., and TURNBULL, W. (1958). *Amer. J. Ophthalm.*, **45**, no. 4, pt 2, p. 165.
- FISHBERG, A. N. (1954). "Hypertension and Nephritis", 5th ed., pp. 367, 384. Lea and Febiger, Philadelphia.
- FRIEDENWALD, J. S. (1940). In "Modern Trends in Ophthalmology", ed. F. Ridley and A. Sorsby, p. 77. Butterworth, London.
- (1947). *Arch. Ophthalm. (Chicago)*, **37**, 403.
- GOWERS, W. R. (1876). *Brit. med. J.*, **2**, 743.
- (1879). "A Manual and Atlas of Medical Ophthalmoscopy", p. 9. Churchill, London.
- KEITH, N. M., WAGENER, H. P., and BARKER, N. W. (1939). *Amer. J. med. Sci.*, **197**, 332.
- LEATHAM, A. (1949). *Quart. J. Med.*, **18**, 203.
- LEISHMAN, R. (1952). *Proc. roy. Soc. Med.*, **45**, 419.
- (1957). *Brit. J. Ophthalm.*, **41**, 641.
- NICHOLLS, J. V. V., TURNBULL, W., and EVELYN, K. A., (1956). *Trans. Canad. ophthalm. Soc.*, **7**, 37.
- PINES, N. (1929). *Brit. J. Ophthalm.*, **13**, 161.
- SCHIE, H. G. (1953). *Arch. Ophthalm. (Chicago)*, **49**, 117.
- SHELBURNE, S. A. (1957). *Ann. intern. Med.*, **47**, 1154.
- TURNER, R. W. D. (1959). *Lancet*, **1**, 897.
- VOGELIUS, H., and BECHGAARD, P. (1950). *Brit. J. Ophthalm.*, **34**, 404.
- WAGENER, H. P. (1935). In "The Kidney in Health and Disease", ed. H. BERGLUND and G. MEDES, ch. 37. Kimpton, London.
- CLAY, G. E., and GIPNER, J. F. (1947). *Trans. Amer. ophthalm. Soc.*, **45**, 57.
- WOLFF, E. (1948). "The Anatomy of the Eye and Orbit", 3rd ed., p. 110. Lewis, London.
- (1953). "Diseases of the Eye", 4th ed., p. 78. Cassell, London.
- WOOD, E. H. (1948). *Arch. Ophthalm. (Chicago)*, **39**, 305.
- WOOD, P. (1956). "Diseases of the Heart and Circulation", 2nd ed. Eyre and Spottiswoode, London.