

COMMUNICATIONS

COATS'S DISEASE: DEFINITION AND PATHOGENESIS*†

BY

W. A. MANSCHOT AND W. C. DE BRUIJN

From the Central Pathological Laboratory, Municipal Hospitals, Rotterdam, The Netherlands

It is remarkable that only one or two writers on Coats's disease appear to have been aware of the fact that Coats had written TWO articles on retinal disease with massive exudation: (1) his primary paper which appeared in the English language (1908), and (2) his final article which was published 4 years later (1912) in the German language. In the second paper, which has apparently been overlooked by most students of Coats's disease, the author gave evidence that his opinion had changed somewhat in the intervening years. In 1908 Coats divided his cases into two groups: those with and those without gross vascular disease and also mentioned "a very peculiar group, perhaps related to these two, which is characterized by the formation of large arteriovenous communications". In his final paper Coats placed his two former groups together because the similarities between the two groups were probably greater than the differences ("die Ähnlichkeiten sind wahrscheinlich grösser als die Unterschiede . . . ich werde sie zusammengruppieren"), and he eliminated the third group because von Hippel had shown that this condition was in fact a retinal angiomatosis and, therefore, quite different from that described by Coats ("... der Zustand ist in Wahrheit eine Angiomatosis der Retina und daher verschieden von den hier berichteten Fällen. Aus diesen Grund unterlasse ich weitere Betrachtung dieser Gruppe").

In 1912 Coats also emphasized that the disease almost invariably occurred in young people. He mentioned that white masses of exudate below the retinal vessels were often encountered in the macular region in elderly subjects, but that these were mostly connected with senile vascular disease of a different aetiology ("Die Krankheit kommt fast immer bei jungen Menschen vor. Es ist richtig, dass sich weisse Exsudatmassen unter den retinalen Gefässen nicht selten in der Macula bei alten Personen finden, aber diese Fälle sind meist verbunden mit seniler Gefässerkrankung . . . ihre Ätiologie ist verschieden").

Coats (1912) thus defined *one* sharply-outlined form of exudative retinitis, *clinically* characterized as follows:

- (1) Occurrence in infantile or juvenile male patients;
- (2) Unilaterality;
- (3) Absence of systemic diseases;
- (4) Exudates below the retinal vessels;
- (5) Retinal haemorrhages;
- (6) Slow progression to retinal detachment, cataract, atrophy, or glaucoma.

* Received for publication October 21, 1966.

† Address for reprints: W. A. Manschot, M.D., Nieuwe Binnenweg 157, Rotterdam 3, The Netherlands.

As *histological* characteristics Coats enumerated:

- (1) Retinal haemorrhages penetrating into the subretinal space;
- (2) Subretinal fibrous tissue;
- (3) Cystic retinal degeneration;
- (4) Vascular anomalies, *i.e.* dilatation, hyaline thickening, endothelial proliferation, and thrombosis;
- (5) Proliferation of pigment epithelium;
- (6) Subretinal accumulation of foam cells.

It thus seems unwarranted on historical grounds to distinguish both juvenile and adult forms of Coats's disease as do Woods and Duke (1963). These authors' own exhaustive investigations appear to contradict this view. In "adult cases" they found hypercholesterolaemia and a history of a repeated or protracted uveitis, but no evidence of these factors could be found in any of their infantile cases. Other authors have even labelled probable cases of toxoplasmosis in adults as Coats's disease (François, Rabaey, Evans, and de Vos, 1956; Rieger, 1960; Berengo and Frezzotti, 1962). The inclusion of adult cases of exudative retinitis, whatever their aetiology, in the diagnosis of Coats's disease can only cause confusion.

Another misconception may follow from the recent introduction by Henkind and Morgan (1966) of the term "Coats's lesion". These authors gave a histopathological description of four adult cases of peripheral retinal angioma with exudative retinitis. Pathologically these cases may warrant the definition "Coats's lesion", because they satisfy the histological criteria of Coats's disease, *viz.* exudative retinopathy with gross localized disease of the retinal vessels. Clinical ophthalmologists, however, will not be so happy with this new term, which further confuses the already overworked concept of Coats's disease; as Woods and Duke (1963) stated: "this syndrome, originally so well described by a master ophthalmologist, has become increasingly ill-defined".

The diagnosis "Coats's disease" should be restricted to cases of exudative retinitis associated with vascular retinal anomalies in children. Exudative retinitis in adults should only be labelled with Coats's name when the disorder has originated in childhood.

Two cases of Coats's disease are presented below. Case 1 demonstrates the typical histological features of the disease in early childhood, and Case 2 is a very early one and seems to provide some relevant information on the pathogenesis of the disorder.

Case Reports

Case 1.—A 4½-year-old boy, had a divergent right eye with a dense cataract; perception of light was dubious. A linear extraction of the lens was performed. Fundoscopy 4 days after the operation revealed greenish-grey masses, a local retinal detachment, and some retinal haemorrhages. The left eye was normal. Because the diagnosis of retinoblastoma could not be excluded, the eye was enucleated 7 days after the extraction of the lens.

Pathological Examination (Lab. No. 0-128)

MACROSCOPICAL APPEARANCE.—The retina in the calottes appeared thickened on both sides of the globe and showed yellowish areas. Frozen sections of this retina were strongly positive for the presence of fat (Sudan staining). The eye was cut in horizontal serial sections (Fig. 1, opposite).

MICROSCOPICAL APPEARANCE.—The angle of the anterior chamber was closed. Small remnants of the evacuated lens substance remained in the periphery of the lens capsule. No inflammatory reaction was present in the anterior uvea.

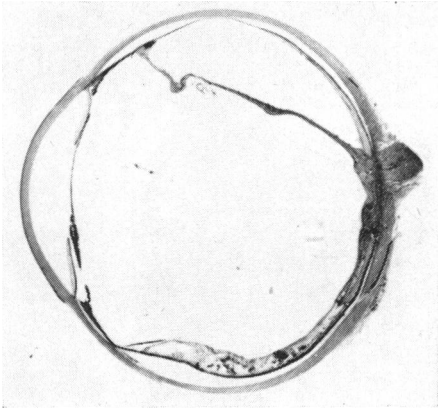


FIG. 1.—Case 1. Low-power photomicrograph of a whole section of the eye. Haematoxylin and eosin. $\times 2.6$.

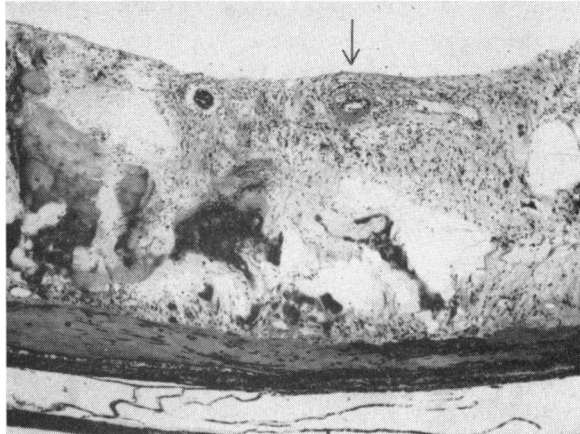


FIG. 2.—Case 1. Higher-power view of the thickened retina with large amounts of exudate, cystic degeneration, vascular anomalies and subretinal fibrosis. Haematoxylin and eosin. $\times 40$.

One half of the retina was detached but this was largely due to artefact because only a small amount of subretinal albuminous fluid was present. The detached retina was thinned, without exudates or haemorrhages, but with diffuse small cystic degeneration and a few lipoidal and pigment-containing macrophages. The ganglion cell layer, the inner nuclear layer, and the layer of rods and cones had all disappeared. The non-detached part of the retina was extremely thickened at its periphery by severe cystic degeneration and by a large amount of serous fluid and some haemorrhages (Fig. 2). Its central part consisted predominantly of innumerable cysts of all sizes, most of which were filled with exudate, while its posterior part contained only small cysts, oedema, and lipoidal macrophages. The central part contained a number of dilated arterioles with a homogeneously thickened wall (fibrinous vasculosis) and dilated thin-walled vessels. Some of the thickened arterioles showed swollen endothelial cells and lipoidal cells and vacuoles in their outer layers (Fig. 3). Fusing of these vacuoles caused a disruption between the medial and adventitial layers, eventually leading to the formation of dissecting aneurysms. A rather dense perivascular eosinophilic infiltration was present in many sections. The post-equatorial segment harboured a thick area of irregular subretinal fibrosis with tumour-like nodules containing cholesterol clefts. The optic disc was oedematous. The retinal pigment epithelium showed minor local proliferations. Pigmented cells were present in the subretinal fibrous tissue. The choroid was rather heavily infiltrated by lymphocytes.

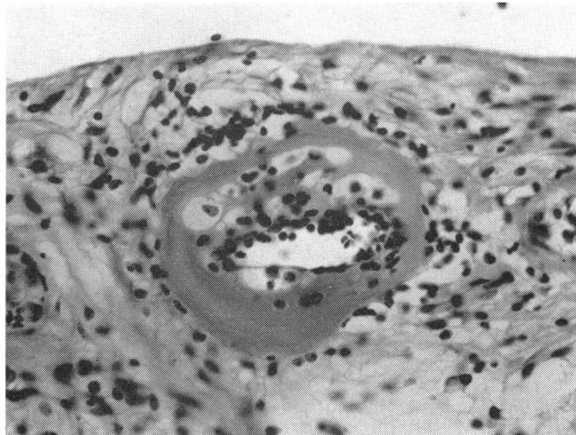


FIG. 3.—Case 1. Detail of Fig. 2, showing fibrinous vasculosis with lipoidal cells within the markedly thickened wall. Haematoxylin and eosin. $\times 288$.

Case 2.—A 3½-year-old boy, showed large exudates all over the retina and small whitish spots in the macular region of the right eye. No haemorrhages were found but a small number of abnormal, tortuous vessels was visible in various parts of the retina. Vision was perception of light only. The eye was enucleated because by examination under general anaesthesia a diagnosis of retinoblastoma could not be excluded.

Pathological Examination (Lab. No. 0·184)

MACROSCOPICAL APPEARANCE.—The retina was thickened and showed large whitish areas. Frozen sections of the retina of both calottes contained small amounts of fat (Sudan-staining). The eye was cut in horizontal serial sections. (Fig. 4).

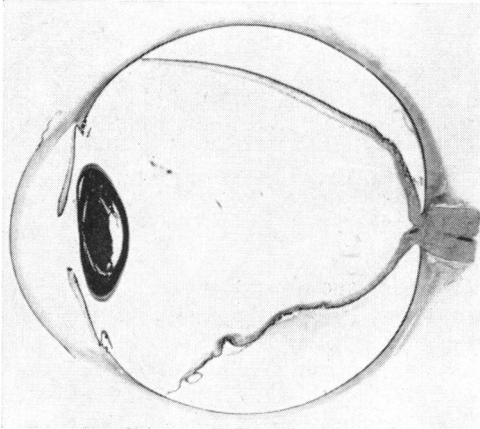


FIG. 4.—Case 2. Low-power photomicrograph of a whole section of the eye. Haematoxylin and eosin. $\times 2\cdot6$.

MICROSCOPICAL APPEARANCE.—The anterior segment showed no abnormality. The retina was completely detached. This was considered to be largely due to artefact as only a little subretinal exudate and no subretinal haemorrhage were present. The main pathological lesions were as follows:

(1) *Changes caused by abundant retinal exudate.*—The entire retina was markedly thickened by oedema and large quantities of eosinophilic PAS-positive exudate (Fig. 5). The pressure exerted

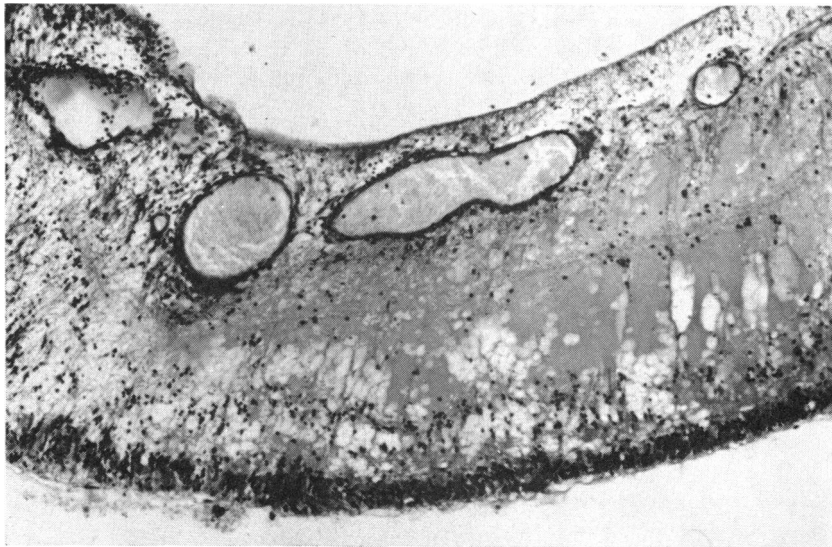


FIG. 5.—Case 2. Higher-power view of the thickened retina with eosinophilic PAS-positive exudate and dilated vessels without markedly thickened basement membrane. Periodic acid-Schiff. $\times 88$.

by this fluid had caused diffuse cystic degeneration. The oedema was notably accumulated around the vessels where cavities had formed (Fig. 6). Extensive areas of the external retinal layers were densely infiltrated by lipoidal macrophages. A sector of the retinal periphery was almost completely replaced by enormous accumulations of fluid. A giant cyst had developed near the central border of this degenerate area.

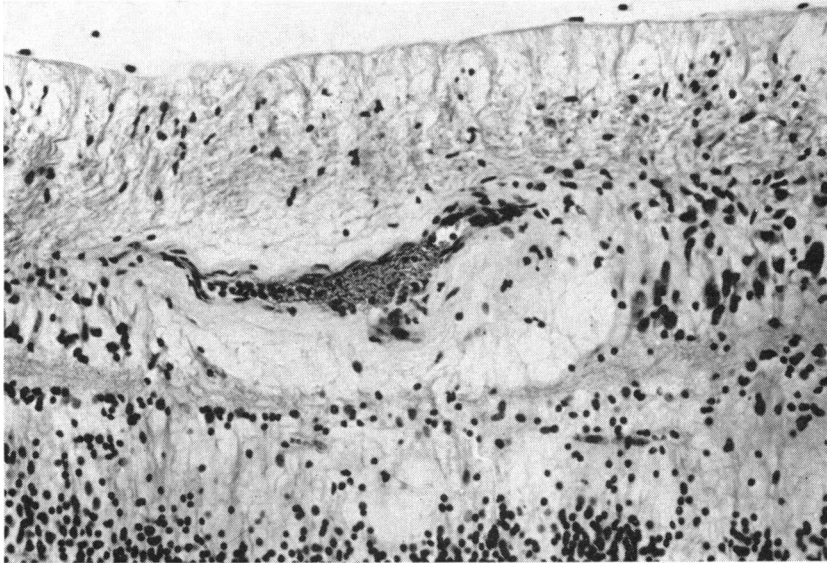


FIG. 6.—Case 2. Perivascular oedema in internal retinal layers. Haematoxylin and eosin. $\times 175$.

(2) *Anomalous retinal vessels.*—Telangiectatic malformations of the inner retinal vessels were present in the vicinity of the degenerate peripheral retina (Fig. 5). Most of these dilated thin-walled vessels consisted only of a non-oedematous endothelial layer (Fig. 7). A few dilated thin-walled vessels were also present elsewhere in the retina and were also surrounded by oedematous tissue. Erythrocytes were found escaping between the endothelial cells and were dispersed throughout the internal retinal layers, but no large intraretinal haemorrhages were present. It was evident that at numerous sites in the inner retinal layers the walls of the smaller branches of the retinal vascular system showed an abnormal permeability for serum, plasma, and blood cells. PAS-staining revealed that the endothelium of the telangiectatic vessels was surrounded by only a thin PAS-positive basement membrane. The membrane was nowhere markedly thickened and a narrowing of the vascular lumina had not occurred. Some of the larger vessels in the posterior part of the retina showed a dense perivascular lymphocytic infiltration.

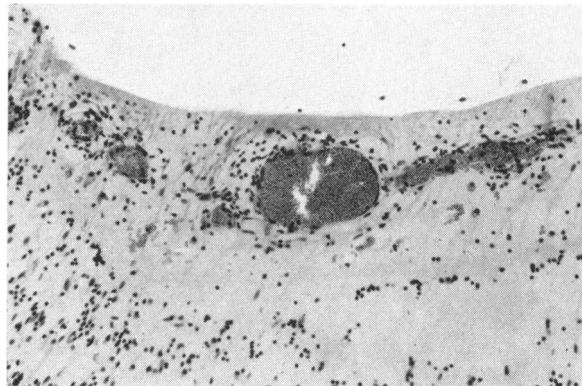


FIG. 7.—Case 2. Telangiectatic malformation and accumulation of fluid in retinal periphery. Haematoxylin and eosin. $\times 130$.

(3) *Subretinal fibroblastic proliferation.*—The external retinal layers showed minor folds which seemed to be caused by a thin subretinal fibroblastic layer which at many places consisted of only one or two cell layers (Fig. 8). Elsewhere this layer appeared somewhat thicker and showed fibroblastic processes, some of which were connected with the retina without apparent continuity with intraretinal structures. A number of subretinal fibroblastic cells contained pigment granules.

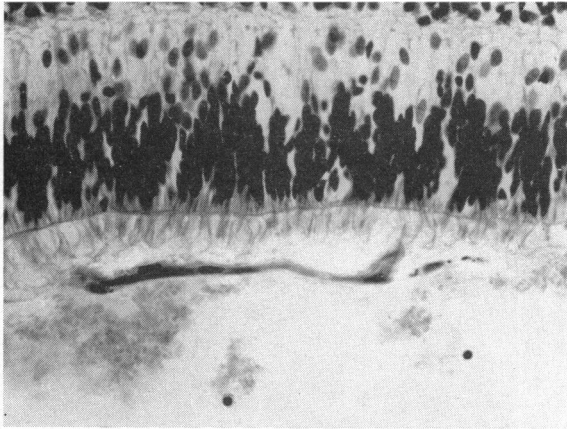


FIG. 8.—Case 2. Single layer of subretinal fibroblasts; some of the cells contain pigment granules. Haematoxylin and eosin. $\times 288$.

(4) *Proliferation of pigment epithelium.*—An accumulation of swollen, detached pigment epithelium cells was present in the posterior part of the subretinal space. This accumulation was partly surrounded and infiltrated by fibroblasts and lay within a coagulum of serous exudate; its centre contained a cholesterol granuloma. Elsewhere in the subretinal space many solitary cells were found, most of which were either detached pigment epithelium cells or lipoidal macrophages containing phagocytosed pigment granules. A number of these cells showed the morphological aspects of fibroblasts containing pigment granules. Transitional stages between pigment epithelium cells and fibroblasts could be found and the impression was gained that some of the fibroblasts which produced the subretinal fibrous tissue originated from detached pigment epithelium cells (Fig. 9).

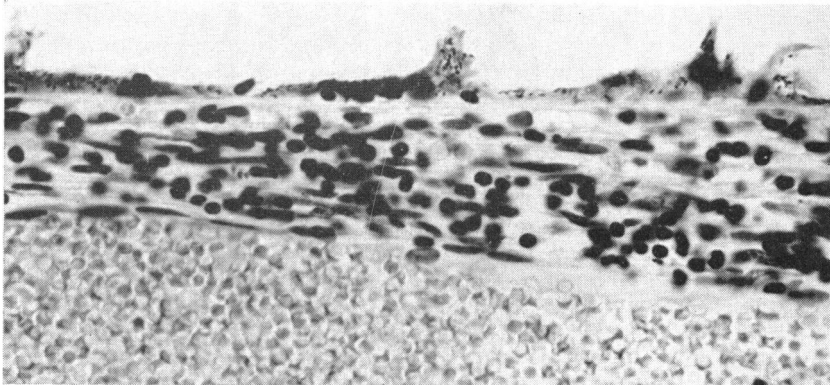


FIG. 9.—Case 2. Detaching pigment epithelium cells. Haematoxylin and eosin. $\times 450$.

The greater part of the pigment epithelium appeared unaffected. In the vicinity of the subretinal mass of swollen pigment epithelium cells, however, the pigment epithelium was either absent or markedly flattened, while elsewhere proliferations of pigment epithelium were found with detaching cells.

The choroid seemed unaffected, except for a minor thickening at the site of the diseased pigment epithelium.

In an attempt to confirm the impression gained by light microscopy that some of the intraretinal and subretinal lipoidal macrophages, and of the cells producing the subretinal fibrous tissue are dedifferentiated pigment epithelium cells, two small areas of the remaining nitrocellulose block, containing respectively intraretinal "ghost"-cells and subretinal membrane together with "ghost"-cells, were removed for electron microscopy and re-embedded in an Epon-mixture by the method of Luft (1961) *via* an 1·2-epoxy propane treatment. It was realized that the previous formalin fixation would prevent demonstration of cell membranes under electron microscopy. On the other hand, electron microscopy would enable the distinction to be made between fibroblasts containing phagocytosed pigment granules and detached pigment epithelium cells, since phagocytosed pigment granules are known to be situated in the cytoplasm within small vacuoles, while native pigment granules are expected to be directly embedded in cytoplasm.

Electron Microscopy of the Subretinal and Intraretinal Cells

(a) Cells without native pigment granules but with empty, presumably lipid vacuoles of all sizes and with phagocytosed pigment granules within small vacuoles. These cells are considered to be retinal histiocytes or phagocytosing pigment epithelium cells which have lost their native pigment.

(b) Cells with native pigment granules, directly embedded in cytoplasm, and with empty vacuoles (Figs 10 and 11, overleaf). Some of these cells show in addition phagocytosed pigment granules. These cells are considered to be phagocytosing pigment epithelium cells.

(c) Cells with native pigment granules and with fibres in or adjacent to their cytoplasm (Fig. 12, overleaf).

These cells are considered to be pigment epithelium cells which have taken on a fibre-producing faculty.

(d) Typical fibroblasts which have probably migrated from the retina into the subretinal space.

Discussion

Both these cases appear to satisfy all the clinical and histological criteria enumerated by Coats (1912), except for the absence of large intraretinal haemorrhages penetrating into the subretinal space which Coats thought to be the primary lesion. The presence of fat in frozen sections of the retina in the calottes seems a reliable indication for a preliminary diagnosis in the first stage of the histological examination. This diagnosis may be confirmed eventually in the microscopical sections by the presence of:

- (a) Thickening of the retina by oedema, exudates, lipoidal macrophages, haemorrhages, and cyst formation.
- (b) Abnormal retinal vessels, predominantly in the retinal periphery.
- (c) Subretinal fibrosis, "ghost"-cells, and cholesterol clefts.
- (d) Local proliferations of pigment epithelium.
- (e) Retinal detachment and its sequelae.

It is often necessary to study a large number of sections, preferably serial sections, otherwise the criteria mentioned under (b) and (d) may be missed.

A number of questions on the pathogenesis of Coats's disease demand more detailed discussion, *viz.*:

- (1) Are retinal haemorrhages the primary lesion?
- (2) Are congenital vascular anomalies the primary lesion?
- (3) What is the role and origin of the lipoidal macrophages ("ghost"-cells)?
- (4) What is the origin of the subretinal fibrosis?

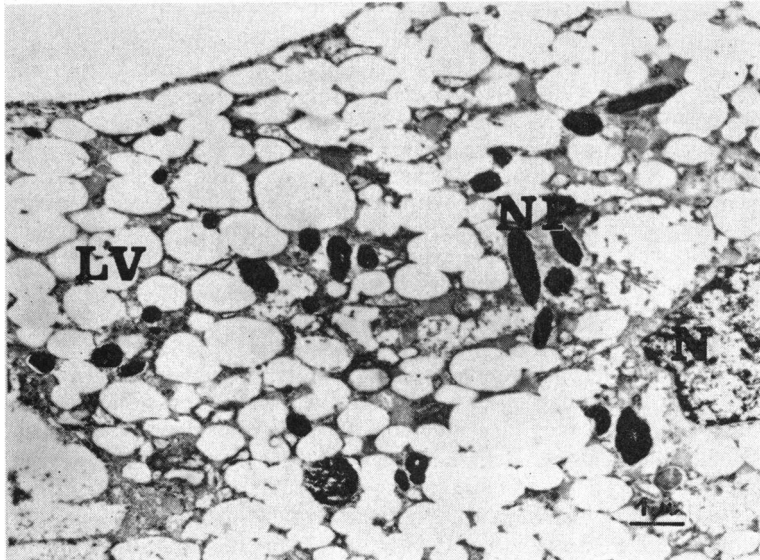


FIG. 10.—Case 2. Electron-microphotograph of a subretinal "ghost"-cell, showing numerous empty vacuoles (LV). Nearly all pigment granules (NP) are directly embedded in the cytoplasm and represent the native pigment of this cell. The cell nucleus (N) is visible on right.

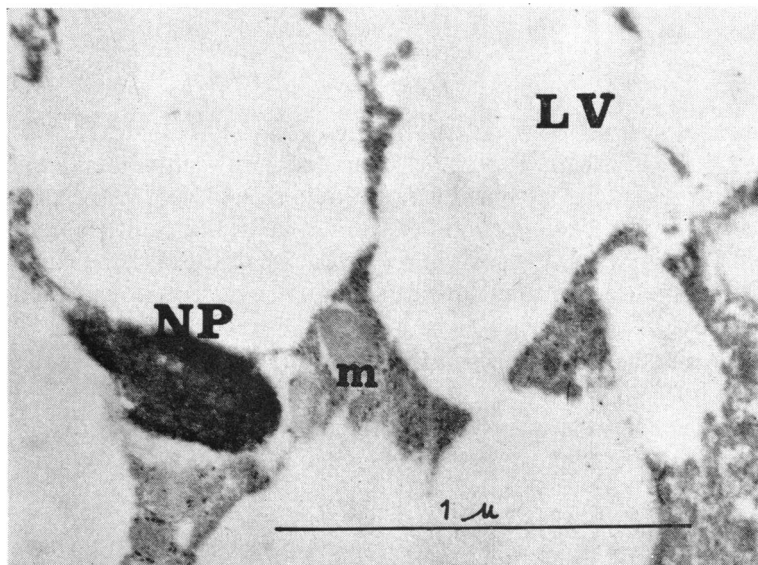


FIG. 11.—Case 2. Electron-microphotograph of the cytoplasm of an intraretinal "ghost"-cell with a native pigment granule (NP). A mitochondrion (m) is visible in the centre.

(1) Retinal Haemorrhages.—Coats's conviction that retinal haemorrhages were the primary lesion originated from his false premise that "the presence of cholesterol" crystals in a tissue is almost to be regarded as diagnostic of preceding haemorrhage (1908). This premise was strongly doubted by Leber (1916). It must be mentioned, however, that Coats did not have the opportunity of histological examination of

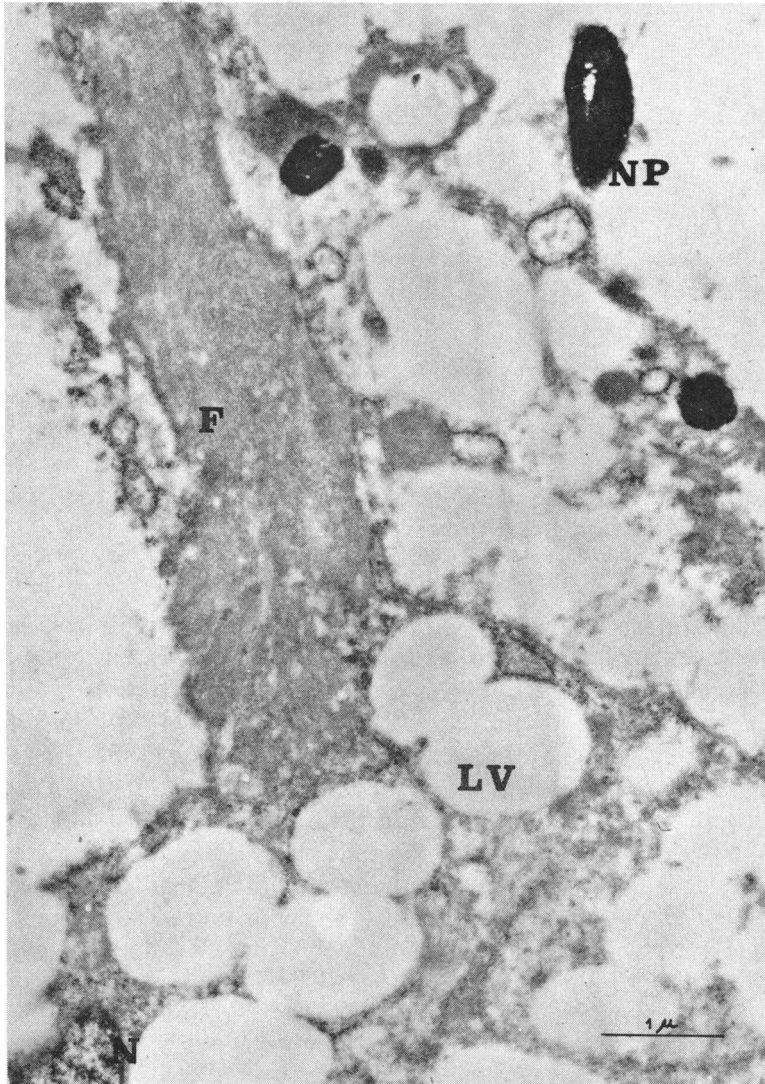


FIG. 12.—Case 2. Electron-micrograph of part of a subretinal “ghost”-cell with fibrous material (F) within the cytoplasm. The cell nucleus (N) is visible lower left.

early cases without subretinal fibrosis. Marshall and Michaelson (1933), who showed four such early cases, concluded that “haemorrhages obviously played a very minor role in the process”. Their conclusion is fully confirmed by our Case 2, a very early case, showing abundant retinal exudate and only minor haemorrhages.

It is concluded that *intraretinal haemorrhages are not obligatory for the pathogenesis of Coats's disease.*

(2) **Retinal Telangiectasis.**—Nearly all recent writers on Coats's disease, including Reese (1956), Brini (1957), Tour (1957), Sugar (1958), Bauer (1959), Imre (1962), Gomez Morales (1965), and Henkind and Morgan (1966), are convinced that

vascular changes are the actual cause of the disease. Reese observed two cases progress from the early stage of telangiectasis retinae to the typical clinical and histological picture of Coats's disease and asserted that Leber's retinal degeneration with multiple aneurysms and Coats's disease were one and the same condition. Our Case 2, like many others in the literature, endorses this view.

It now seems possible to simplify the classification of Coats's disease given by Duke-Elder (1940). He then wrote that Coats's disease was by no means a clinical entity but embraced a considerable number of conditions: (1) external haemorrhagic retinitis, (2) external exudative retinitis, (3) angiomatosis retinae (von Hippel-Lindau), and (4) retinal degeneration with multiple miliary aneurysms (Leber's disease).

Coats (1912) had already unified his groups I and II, which are more or less identical with Duke-Elder's groups (2) and (1), and had eliminated angiomatosis retinae (Duke-Elder's group (3)). If we accept Leber's retinal degeneration as the initial stage of Coats's disease, Duke-Elder's four categories can be reduced to one sharply defined clinical and pathological entity:

Exudative retinitis in childhood due to congenital vascular anomalies.

Retinal telangiectasis may be regarded as a congenital malformation. Many authors have speculated on its pathogenesis. Junius (1934) suggested a series of minute physico-chemical changes in the walls of the small arterioles. Reese (1956) thought that a thickening of the basement membrane by PAS-positive material represented the causative factor in all retinal changes. Wise (1957, 1961) was of the opinion that the vascular anomalies are the response to a local hypoxia. Imre (1962) thought that a disturbed balance of the endocrine system was the causative factor. Duke (1963) suggested that in juvenile cases the intermediate action of the acid mucopolysaccharide was the dominant factor leading to the deposition of cholesterol in the tissues, and concluded that the deposition of a PAS-positive mucopolysaccharide in the retinal arterioles and telangiectases, as supposed by Reese, had no part in the pathogenesis of the condition. This last conclusion is confirmed by our Case 2, but the problem of the pathogenesis of congenital retinal telangiectases still remains unsolved.

The earliest described histological signs of the congenital vascular anomaly are dilated thin-walled retinal vessels, notably in the retinal periphery, and the abnormal permeability of the walls of these vessels for plasma and erythrocytes. All other vascular changes seem to represent secondary changes, *viz.* fibrinous or hyaline thickening of the vessel wall, oedematous swollen endothelial cells, subintimal PAS-positive thickening of the basement membrane, intramural lipoidal cells and vacuoles, eventually fusing into dissecting aneurysms, obliterative changes, and perivasculitis.

It is concluded that *the primary lesion in Coats's disease is a congenital retinal telangiectasis. Arterio-capillary shunts cause abnormal high intravascular pressure which gives rise to leakage of serum, plasma, and blood cells. Intraretinal accumulation of fluid causes the formation of cysts and the degeneration of retinal elements resulting in deposits of lipid material which attract scavenger cells.*

(3) **Lipoidal Macrophages ("Ghost" Cells).**—Much difference of opinion has arisen on the origin and role of these scavenger cells in the pathogenesis of Coats's disease. Coats described them as degenerate leucocytes, but Leber (1916) thought that they were pigment epithelium cells and recognized their relation to the phagocytosis of lipids and their metamorphosis into fibroblasts. Marshall and Michaelson (1933) suggested that the "ghost" cells were histiocytes or macrophages arising from the reticulo-endothelial system, and this view has recently been supported by Woods and Duke (1963). Duke-Elder (1940), however, adhered to Leber's view, stating that the pigment epithelium cells "assume a preponderant role in the formation of the exudate mass, first as macrophages, and then by changing to fibroblasts and laying down fibrous tissue".

The electron microscopic study of the intraretinal lipoidal macrophages and of the subretinal exudate mass and fibrous tissue in our Case 2 fully endorses this opinion. Very many intra- and subretinal "ghost" cells were found to contain native pigment granules, an absolute proof that they are actually pigment epithelium cells which have taken on the faculty of phagocytosis. Other lipoidal macrophages did not contain native pigment granules and may have been histiocytes.

In many sections the pigment epithelium was of normal appearance, but in many others areas of proliferation could be found.

It is concluded that leakage of retinal exudate into the subretinal space provokes proliferation of pigment epithelium. Detached pigment epithelium cells can dedifferentiate into cells which assume the faculty of phagocytosis and become macrophages ("ghost" cells), which also infiltrate the retina. Other subretinal macrophages may be histiocytes which have migrated from the retina.

(4) **Subretinal Fibrosis.**—An interesting aspect of our Case 2 is the very early stage of subretinal fibrosis. In many places the subretinal fibrous membrane consisted of no more than one or two cell layers. It was noticed that some of its cells contained pigment granules and the impression was obtained that at least part of the subretinal fibrous tissue originated from detached pigment epithelium cells. Transitional stages between normal pigment epithelium cells and fibroblasts were found. Mitotic figures were seen at the margin of the subretinal membrane (Fig. 13, overleaf).

Electron microscopy of the subretinal tissue revealed newly-formed fibres in close relation to cells with native pigment granules in their cytoplasm. Prior formalin fixation of the eye, however, prevented the observation of cell membranes and made it impossible to obtain valid proof that these fibres were actually produced by pigment epithelium cells. Moreover, many typical fibroblasts, which had probably migrated from the retina, were recognizable between the detached pigment epithelium cells.

Thus, although the origin of subretinal fibroblasts from pigment epithelium could not be proved with certainty, it is to be assumed that in part at least this origin is highly probable.

It is noteworthy that even the extremely thin subretinal fibrous layer in Case 2 had caused minor folds in the outer retinal layers. This explains how local retinal detachments may be found in the early stages of Coats's disease.

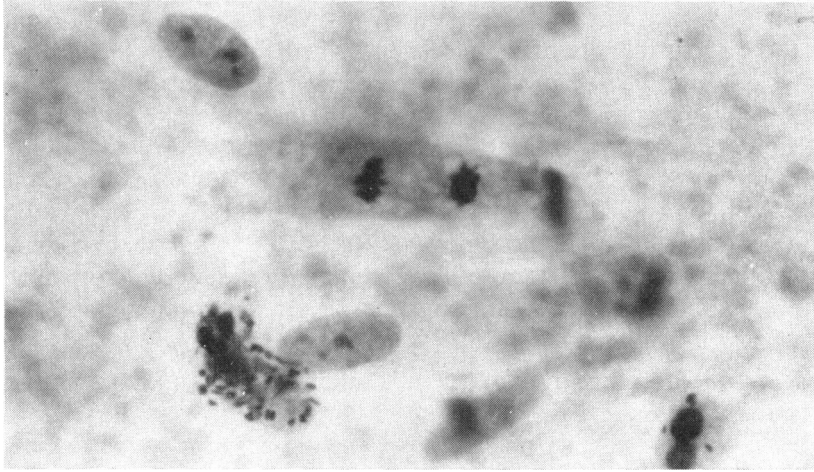


FIG. 13.—Case 2. Mitosis at the margin of the subretinal layer. Haematoxylin and eosin. $\times 865$.

It is concluded that *detached pigment epithelium cells may assume a fibre-producing faculty and may, together with fibroblasts which have migrated from the retina, lay down subretinal fibrous tissue. The subretinal tissue causes retinal folds in the earliest stage of its development, and these are followed by retinal detachment with its eventual sequelae.*

Summary

In his second article published in German in 1912, Coats stated that all cases of retinal disease with massive exudation, previously described by him in 1908, belonged to ONE exudative retinal disorder which originated in childhood. *Coats's disease is therefore to be defined as exudative retinitis in childhood associated with congenital retinal telangiectasis.* Cases of exudative retinitis in adults may be labelled with Coats's name only when the disorder has started in childhood as Coats's disease. In order to avoid confusion, the designation "Coats's lesion" for exudative retinopathy in adults of whatever aetiology should be discontinued.

Intraretinal haemorrhages are not obligatory in the pathogenesis of Coats's disease. The primary lesion is a congenital retinal telangiectasis. Arterio-capillary shunts cause an abnormally high intravascular pressure which gives rise to leakage of serum, plasma, and blood cells. Intraretinal accumulation of fluid causes formation of cysts and degeneration of retinal elements resulting in lipid deposits which attract scavenger cells. Leakage of exudate into the subretinal space provokes proliferation of pigment epithelium cells. Detached pigment epithelium cells can dedifferentiate into cells which assume the faculty of phagocytosis and become macrophages ("ghost" cells). Other subretinal macrophages may be histiocytes which have migrated from the retina. Detached pigment epithelium cells can also adopt a fibre-producing faculty and, together with fibroblasts which have migrated from the retina, lay down subretinal fibrous tissue. The subretinal tissue causes retinal folds in the earliest stages of its development and these are followed by retinal detachment with its sequelae.

The technical assistance of Miss D. Popken, Mr. W. van Mourik, and Mr. P. van Breejen, and the photographic assistance of Miss C. Scheele and Miss L. Iburg are gratefully acknowledged.

REFERENCES

- BAUER, F. (1959). *v. Graefes Arch. Ophthalm.*, **161**, 373.
 BERENGO A., and FREZZOTTI, R. (1962). *Fortschr. Augenheilk.*, **12**, 265.
 BRINI, A. (1957). *Bull. Soc. Ophthal. Fr.*, p. 148.
 COATS, G. (1908). *Roy. Lond. ophthal. Hosp. Rep.*, **17**, 440.
 ——— (1912). *v. Graefes Arch. Ophthalm.*, **81**, 275.
 DUKE, J. R. (1963). *Trans. Amer. ophthal. Soc.*, **61**, 492.
 DUKE-ELDER, S. (1940). "Text-book of Ophthalmology", vol. 3, p. 2611. Kimpton, London.
 FRANÇOIS, J., RABAËY, M., EVANS, L., and DE VOS, E. (1956). *Ophthalmologica (Basel)*, **132**, 1.
 GOMEZ MORALES, A. (1965). *Amer. J. Ophthalm.*, **60**, 855.
 HENKIND, P., and MORGAN, G. (1966). *Brit. J. Ophthalm.*, **50**, 2.
 IMRE, G. (1962). *Amer. J. Ophthal.*, **54**, 175.
 JUNIUS, P. (1934). *Klin. Mbl. Augenheilk.*, **92**, 748.
 LEBER, T. (1916). In "Graefe-Saemisch-Hess Handbuch der gesamten Augenheilkunde", 2nd ed., band 7, teil 2, kap XA, II hälfte, p. 1267. Engelmann, Leipzig.
 LUFT, J. H. (1961). *J. biophys. biochem. Cytol.*, **9**, 409.
 MARSHALL, J., and MICHAELSON, I. C. (1933). *Trans. ophthal. Soc. U.K.*, **53**, 102.
 REESE, A. B. (1956). *Amer. J. Ophthalm.*, **42**, 1.
 RIEGER, H. (1960). *v. Graefes Arch. Ophthalm.*, **162**, 178.
 SUGAR, H. S. (1958). *Amer. J. Ophthalm.*, **45**, 508.
 TOUR, R. L. (1957). *Ibid.*, **43**, 426.
 WISE, G. N. (1957). *A.M.A. Arch. Ophthalm.*, **58**, 735.
 ——— (1961). *Amer. J. Ophthalm.*, **52**, 637.
 WOODS, A. C., and DUKE, J. R. (1963). *Brit. J. Ophthalm.*, **47**, 385.