

## A NEW OCULAR SYNDROME\*†

BY

P. C. WELLINGS

*Department of Ophthalmology, Wellington Hospital, New Zealand*

TO DESCRIBE a new syndrome on the basis of one case is perhaps to be somewhat presumptive, but in this case the features appear to fit together so well that such presumption may be justified. There is good evidence that this syndrome, which, as far as I am aware, has not been described before, results from bilateral isolated lesions of the ciliary ganglia and/or short ciliary nerves.

### Case Report

A 33-year-old woman had been generally well and had had no eye troubles until she suddenly became aware that she could not focus on print clearly when she picked up the newspaper one evening. During the next 3 weeks, before her admission to hospital, her vision became slightly more blurred, both for distance and near. She also was troubled by glare and for a few days after her initial symptom noticed some discomfort behind her eyes, especially on ocular movements. For a few days also she had a frontal headache which was accompanied by some tenderness of her scalp in this region.

*Past History.*—For some years she had suffered from mild asthma and a chronic eczema. For the last 4 years she had had frequent “cold sores” around her mouth. Hydrocortisone ointment had been used for a long time on her eczema and “cold sores” but, apart from oral contraceptives, she had been given no other medication recently.

*Family History.*—There was no family history of eye troubles or any other significant illness.

*Clinical Findings.*—The patient appeared generally fit and well, but ophthalmological examination revealed that she had fixed, slightly dilated pupils, the left pupil being also slightly oval (Fig. 1, overleaf).

The pupils reacted neither to light nor to convergence, even if prolonged. The visual acuity was 6/60 in both eyes, but this could be corrected in both eyes to 6/12 with +1 D sph. Retinoscopy at 1 metre revealed that +2 D was required for neutralization for both distance and near. There was anaesthesia of both corneae, over the surface of which, in the interpalpebral area especially, was a marked superficial punctate keratitis. There was, however, no evidence of any more widespread involvement of the trigeminal nerves. Firm padding over the closed eyes for a few hours produced a noticeable improvement of the superficial punctate keratitis. The media of both eyes were clear. Ophthalmoscopic examination revealed a generally pale appearance of the posterior fundus with fine radiating lines around the macula and disc suggestive of some retinal oedema in this region (Fig. 2, overleaf).

The remainder of the fundus was unremarkable. The visual fields and external ocular movements were normal. The intra-ocular pressure was 10 to 12 mm. Hg in both eyes (applanation). There was no proptosis.

---

\* Received for publication June 12, 1967.

† Address for reprints: c/o Bank of New Zealand, 54–62 Regent Street, London, W.1.

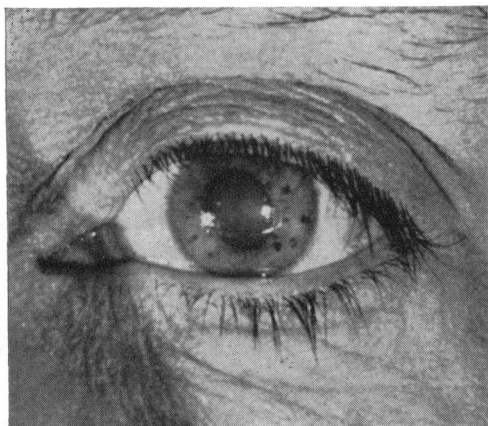


FIG. 1.—Appearance of left pupil.

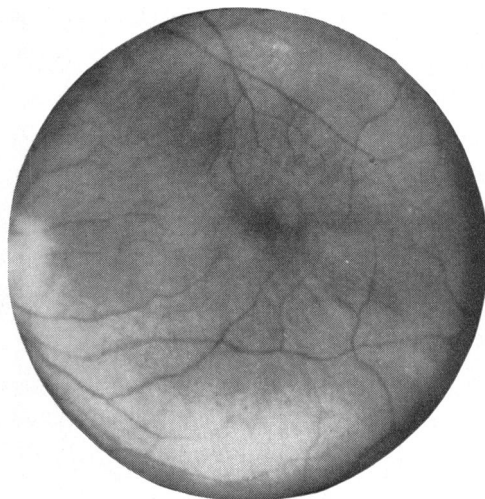


FIG. 2.—Ophthalmoscopic appearance of retina, suggestive of macular oedema.

Neurological examination and general clinical examination revealed no other features except for a very mild widespread eczema and a recent herpetic vesicle near the mouth.

*Clinical Course.*—At the time of writing, 4 weeks after her admission to hospital (7 weeks after her first symptom), the clinical features were essentially unchanged.

#### Comment

The essential features which this patient demonstrates bilaterally are thus:

- (1) Fixed, slightly dilated pupils;
- (2) Cycloplegia;
- (3) Corneal anaesthesia with superficial punctate keratitis in exposed areas;
- (4) Low intra-ocular pressure;
- (5) Retinal oedema at the posterior pole.

There is only one site where a single lesion could be responsible for the first three lesions in each eye, *viz.* the ciliary ganglion (or short ciliary nerves arising from it). Such a lesion would thus produce interruption of the parasympathetic fibres to the iris and ciliary body, sympathetic fibres to the iris (although usually not all of them), and sensory fibres from the cornea. By measuring the effect on the iris and ciliary muscle of certain pharmacological agents, it is possible to ascertain whether the lesion is preganglionic, postganglionic, or within the end-organ itself. Such a trial was performed on this patient.

#### Pharmacological Trials

##### Method

In all cases the effects of the drugs on the patient were compared with the effects on healthy young adult volunteers. Each drug was administered by four drops, each at minute intervals, into the conjunctival sac.

## Results

(A) *On the Iris Response.*—This was measured accurately by measuring the pupillary diameter on the Goldmann perimeter telescope. The results are shown in Table I (overleaf).

(B) *On the Ciliary Muscle Response.*—The response of the ciliary muscle to parasympathomimetic drugs was measured by the dioptric power of the minus lens required to return the subject to the emmetropic state—to which was added in the case of the patient a further 1 dioptre to allow for the cycloplegia. Emmetropia was measured subjectively by testing the visual acuity at 6 metres and checking with the duochrome chart. The drugs used in this part of the trial were stronger in order to obtain a more easily measured response. The results are shown in Table II (overleaf).

## Conclusions

In all cases the end-organ shows a heightened response to its effector substance or effector-like substance (mecholyl, pilocarpine, adrenaline)—*i.e.* the typical response of an organ deprived of its post-ganglionic nerve supply. In support of this finding, in all cases, the end-organ shows a diminished response to drugs of which the actions depend on the potentiation of the effector substance secreted by the post-ganglionic fibres (eserine, cocaine). That there is any response at all to eserine may at first appear unusual. However, there is some evidence that, if the sympathetic fibres, as well as the parasympathetic fibres, to the pupil are interrupted, eserine retains some action on the pupil (Weinstein, 1955). Loss of the sympathetic supply has been shown to diminish the cholinesterase content of the iris, and this effect combined with the administration of eserine probably allows enough acetylcholine from other sources to build up, produce an effect on the pupil, and thus constrict it.

## Further Investigations

The following investigations carried out in an attempt to find a cause for this syndrome were, on the whole, unrewarding:

*Blood Count* (Hb, ESR, WBC)—normal except for a persistent eosinophilia of 5–7 per cent. (which may have been a reflection of the patient's chronic eczema and asthma)

*Urine* (cells, protein, sugar)—normal

*X rays* (skull, sinuses, chest)—normal

*Blood Titres* (W.R., Kahn, brucella, leptospiral, toxoplasma)—negative

*Glucose Tolerance Test*—normal

*Mantoux Test*—positive to 1/1000

*Cerebrospinal Fluid* (cells, protein, colloidal gold)—normal

*Viral Cultures* (of conjunctival scrapings)—negative.

## Discussion

The above pharmacological trials suggest that the fixed pupils and cycloplegia are due to lesions of the ciliary ganglia or short ciliary nerves. This would therefore explain also the corneal anaesthesia and superficial punctate keratitis. The connexion between lesions of the ciliary ganglia and the other two features of this syndrome, *viz.* low intra-ocular pressure and retinal oedema, is not so clear.

TABLE I  
EFFECT OF DRUGS ON IRIS RESPONSE IN PATIENT AND CONTROLS

Type of Drug		Time		Pupillary Diameter (mm.)	
				Patient	Controls
Parasympathomimetic	Mecholyl (acetyl- methyl- choline chloride) 2.5 per cent.	Before Medication		5.0	
		After	15 min.	1.0	No change
			30 min.	1.0	
			45 min.	1.0	
			90 min.	1.0	
			3 hrs	1.0	
	6 hrs	2.0			
	Eserine 0.1 per cent.	Before Medication		5.0	
		After	15 min.	5.0	1.5
			30 min.	3.0	1.5
45 min.			2.0	1.5	
90 min.			1.5	1.5	
3 hrs			1.5	1.5	
6 hrs	1.5	1.5			
18 hrs	3.0	2.0			
Sympathomimetic	Adrenaline 1/1,000	Before Medication		5.0	
		After	15 min.	7.0	No change
			30 min.	9.0	
			45 min.	9.0	
			90 min.	8.0	
			3 hrs	8.0	
	6 hrs	7.0			
	Cocaine 1 per cent.	Before Medication		5.0	
		After	15 min.	No change	7.0
			30 min.		6.0
45 min.			5.5		
90 min.	5.5				
3 hrs	5.0				

TABLE II  
EFFECT OF DRUGS ON CILIARY MUSCLE RESPONSE IN PATIENT AND CONTROLS

Drug	Time		Ciliary Spasm (dioptries)	
			Patient	Controls
Pilocarpine 4 per cent.	After	45 min.	6.5 (1)	4.5 (2)
		90 min.	6.5	0.0
		3 hrs	6.5	
		6 hrs	6.0	
		18 hrs	0.5	
		24 hrs	0.0	
Eserine 1 per cent.	After	45 min.	3.5 (3)	8.0 (4)
		90 min.	0.0	2.0
		3 hrs		1.0
		6 hrs		0.0

NOTES: Ciliary spasm representing in:

- (1) about 80 per cent. of the theoretical accommodative power of 8 dioptries (age 33 yrs) maintained for at least 6 hrs.
- (2) about 40 per cent. of the theoretical accommodative power of 11 dioptries (age 20 yrs) maintained for only about 1 hr.
- (3) about 44 per cent. of theoretical accommodative power of 8 dioptries maintained for only about 1 hr.
- (4) about 65 per cent. of theoretical accommodative power of 11.5 dioptries (age 18 yrs) not passing off for over 3 hrs.

The role of the ciliary ganglion and its neural connexions in the control of intra-ocular pressure does not yet appear to have been clearly worked out in the human subject. If lesions of the ciliary ganglia do alter intra-ocular pressure, there is some evidence that they would produce a fall in pressure (Weinstein, 1958; Schmerl and Steinberg, 1949). Other workers (Greaves and Perkins, 1952, 1953) demonstrated, however, that the central connexions of the ciliary ganglia in rabbits had little effect on the intra-ocular pressure.

The retinal oedema may be a manifestation of a disturbance of vasomotor control of intra-ocular vessels resulting from a lesion of the ciliary ganglion. There is some evidence that the sympathetic fibres produce vasoconstriction of the chorio-capillaris in rabbits (Greaves and Perkins, 1952). However, it is also to be noted that sudden falls in the intra-ocular pressure, as occur for example in the operative treatment of glaucoma, have been shown to produce oedema of the macular region (Dellaporta, 1955; Miller, 1963) and this mechanism may be a factor in the production of the retinal oedema in this case. It would certainly be convenient to be able to blame a single lesion in the ciliary ganglion for all five features of the syndrome, but it may yet be discovered that one aetiological agent produces lesions in more than one site, *e.g.* the ciliary ganglion and intra-ocular sites; but I consider this less likely.

There is so far no clear evidence for the aetiology of this syndrome, but it is to be noted that the patient suffers from herpes simplex lesions around her mouth, into which lesions she has been in the habit of rubbing a steroid ointment. Could it be that the ubiquitous herpes simplex virus has localized in the ciliary ganglia?

#### Summary

A case is presented of a new ocular syndrome comprising the following bilateral features:

- (1) Fixed, slightly dilated pupils;
- (2) Cycloplegia;
- (3) Corneal anaesthesia with superficial punctate keratitis;
- (4) Low intra-ocular pressure;
- (5) Retinal oedema at the posterior pole.

Evidence is presented suggesting that these features are due in part, if not entirely, to bilateral lesions of the ciliary ganglia. The herpes simplex virus is suggested as a possible aetiological agent.

My thanks are due to Mr. Randal Elliott and the staff of the Eye Ward, Wellington Hospital, New Zealand, for advice and help.

#### REFERENCES

- DELLAPORTA, A. (1955). *Amer. J. Ophthalm.*, **40**, 781.  
 GREAVES, D. P., and PERKINS, E. S. (1952). *Brit. J. Ophthalm.*, **36**, 258.  
 ———, ——— (1953). *Ibid.*, **37**, 54.  
 MILLER, S. J. H. (1963). *Ibid.*, **47**, 211.  
 SCHMERL, E., and STEINBERG, B. (1949). *Amer. J. Ophthalm.*, **32**, 947.  
 WEINSTEIN, P. (1955). *Ibid.*, **40**, 202.