

COMMUNICATIONS

REIS-BÜCKLERS' DYSTROPHY*† A CLINICO-PATHOLOGICAL STUDY

BY

N. S. C. RICE, N. ASHTON, B. JAY, AND R. K. BLACH

Departments of Clinical Ophthalmology and Pathology, Institute of Ophthalmology, University of London

BÜCKLERS (1949) described a corneal dystrophy affecting members of a German family, characterized by opacification in the region of Bowman's membrane and recurrent epithelial erosions. The mode of transmission appeared to be dominant. Some members of the same family had been described previously by Reis (1917). Similar cases have been reported by Verdi and Filippone (1958), Collier (1962), Paufigue, Bonnet, Bigonnet, Didier-Laurent, and Laurent (1964), Grayson and Wilbrandt (1966), and Griffith and Fine (1967).

The literature contains only four previous reports on the histopathology of Reis-Bücklers' dystrophy where this diagnosis had been made clinically. The first was reported by Verdi and Filippone (1958); the second is simply an illustration of the clinical and histological appearances by Jones (1962); the third report, which included three cases examined histologically, was made by Paufigue and Bonnet (1966); the fourth was an electron microscopical study by Griffith and Fine (1967).

A histological report by Vancea and Lazarescu (1958) was accepted by Paufigue and Bonnet (1966) as an example of Reis-Bücklers' dystrophy; this diagnosis, however, was not made by the authors, who described the condition as "plexiform" degeneration. The histology of a case strongly resembling Reis-Bücklers' dystrophy was reported by Grayson and Wilbrandt (1966), but they pointed out one or two clinical differences and compared the histological findings with a case of epithelial dystrophy, without involvement of Bowman's membrane, described by Stocker and Holt (1955). Whatever the true diagnosis in these latter cases, they all showed interesting pathological features, some of which were also observed in the present study; we shall, however, in the following discussion refer especially to the histology of those cases actually described as Reis-Bücklers' dystrophy.

Both Verdi and Filippone (1958) and Paufigue and Bonnet (1966) agree that the pathological changes are confined to the anterior cornea. Both groups of workers describe irregularity, separation, and degeneration of the epithelium, especially involving the basal layers, with necrosis and final disintegration of Bowman's membrane. According to Paufigue and Bonnet (1966), Bowman's membrane is replaced by tissue of irregular thickness and variable staining reactions, which infiltrates the most superficial layers of the stroma.

* Received for publication January 30, 1968.

† Address for reprints: Prof. N. Ashton, Department of Pathology, Institute of Ophthalmology, Judd St., London, W.C.1.

Nodular formations develop which appear to be embedded in the epithelium, and there is keratoplastic condensation at the contact of the two tissues. Similar changes were illustrated by Jones (1962). Verdi and Filippone (1958) believed the initial lesion to be necrosis of Bowman's membrane and the epithelial changes to be secondary; the granular detritus from the disintegrating membrane was then evacuated across the epithelium, so producing ulceration. The inconstant parenchymal injury, when it occurs, develops many years later.

Griffith and Fine (1967) reported a probable early Reis-Bücklers' type of superficial corneal dystrophy in a male patient aged 28 years. A superficial keratectomy was performed providing them with material for a limited histopathological and electron microscopical study (the first such report in the literature). As seen by light microscopy, Bowman's membrane was largely replaced by a moderately cellular, fibrillar material, confined mostly to the layer normally occupied by the membrane. No deposits were seen between the remaining Bowman's membrane and the epithelium, nor between the fibrillar material and the epithelium. PAS-staining showed no change in the epithelial basement membrane where Bowman's membrane was intact, but elsewhere, except for a few small islands, both layers were absent. Electron microscopy confirmed these findings. Frequently the epithelial basement membrane appeared poorly defined or absent, sometimes ending abruptly with a sudden termination of hemidesmosomes. No excess basement membrane material was seen. The collagen fibrils of Bowman's membrane, where present, had lost their normal homogeneous arrangement and tended to aggregate into well-defined groups; areas of dense nonfibrillar material and membrane-bound cell portions were frequently found. Elsewhere Bowman's membrane had been completely replaced by cellular fibrous tissue and there were many areas of increased densification in and around the collagen fibrils. The epithelial cells appeared normal. Masses of closely packed delicate fibrils were found in the junctional areas between Bowman's membrane and the adjacent stroma and were thought to be due to fibrillar degeneration as seen in lattice dystrophy (McTigue and Fine, 1964). In conclusion Griffith and Fine (1967) felt unable to say, on this single examination, which changes were primary and which secondary, but they believed the earliest change to be disorganization of the collagen fibrils of Bowman's membrane followed by its replacement with fibrocellular tissue. According to them the epithelial changes could be either a secondary regeneration or degeneration, and the appearance of filamentary degeneration of collagen might add support to Bücklers' suggestion that this superficial corneal dystrophy is related to lattice dystrophy.

The purpose of this present paper is to report the occurrence of Reis-Bücklers' dystrophy in an English family and to describe the light and electron microscopical appearances of the cornea.

Clinical Manifestations

Family History

The family is of English stock and originates from the neighbourhood of Maidenhead, Berkshire; 25 individuals in four generations have been affected (Fig. 1, opposite). Eighteen members have been examined, ten affected and eight unaffected. Information about Generation I is incomplete; some of the siblings of I₂ were thought, by younger members of the family, to have been affected, but efforts to trace them have been unsuccessful. There is no family history of consanguinity.

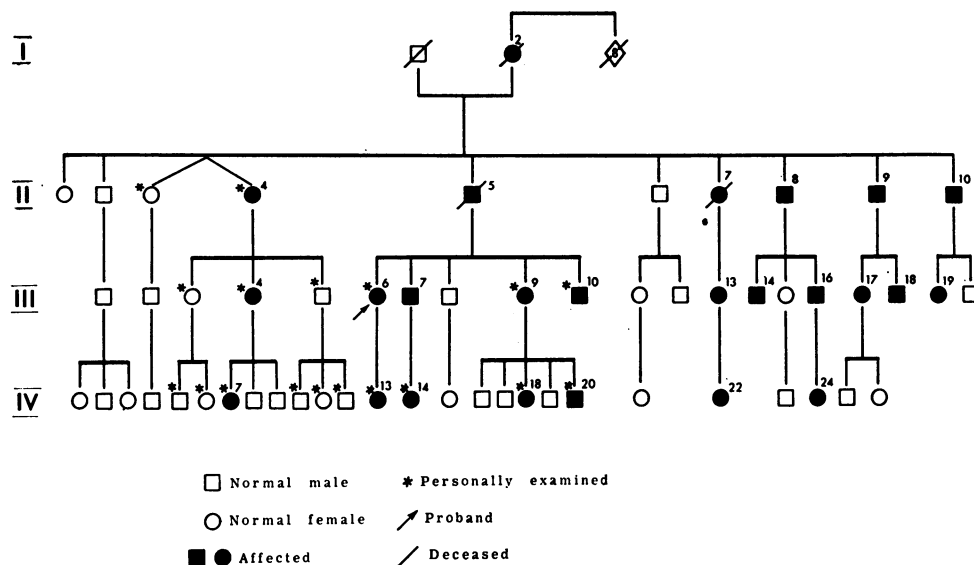


FIG. 1.—Pedigree of affected family, showing 25 affected persons in four generations.

Symptoms

The symptoms of those affected were striking and involved recurrent attacks of acute pain and photophobia due to corneal epithelial erosions. The symptoms usually lasted a week during which time the patient was in considerable distress. The attacks started in infancy, in most cases before the age of 2 years; they occurred two or three times a year until the second or third decade, when they became less frequent and usually ceased. It is noteworthy that the patient aged 70 (II₄) has had no attacks since the age of 14. Only two of the patients examined (III₉ and III₁₀) have continued to experience troublesome attacks into the fourth decade; they have found that in recent years the symptoms have taken longer (up to 3 weeks) to subside. Those affected are aware that minor trauma may precipitate the symptoms and some attacks started during sleep. Most of the affected adults were aware of some deterioration of vision in the third decade. The condition was always bilateral.

Physical Signs

The corneae of those affected showed an essentially similar appearance (Fig. 2, overleaf). In the region of Bowman's membrane there was a striking grey-white opacification arranged symmetrically in the two eyes. Over the central 6-7 mm. of the cornea the opacities were arranged in a delicate pattern of ring forms; when viewed by diffuse illumination using the broad beam of the slit lamp, the appearance resembled that of curdled milk. When examined in optical section the opacities presented numerous peaks projecting into the epithelium; however, although the posterior aspect of the epithelium conformed to the configuration of the opacities, the surface was smooth and intact in all cases. Towards the periphery of the cornea the opacity showed a fine granularity which extended to within 2-3 mm. of the limbus. When viewed by retro-illumination the whole cornea appeared as frosted glass.

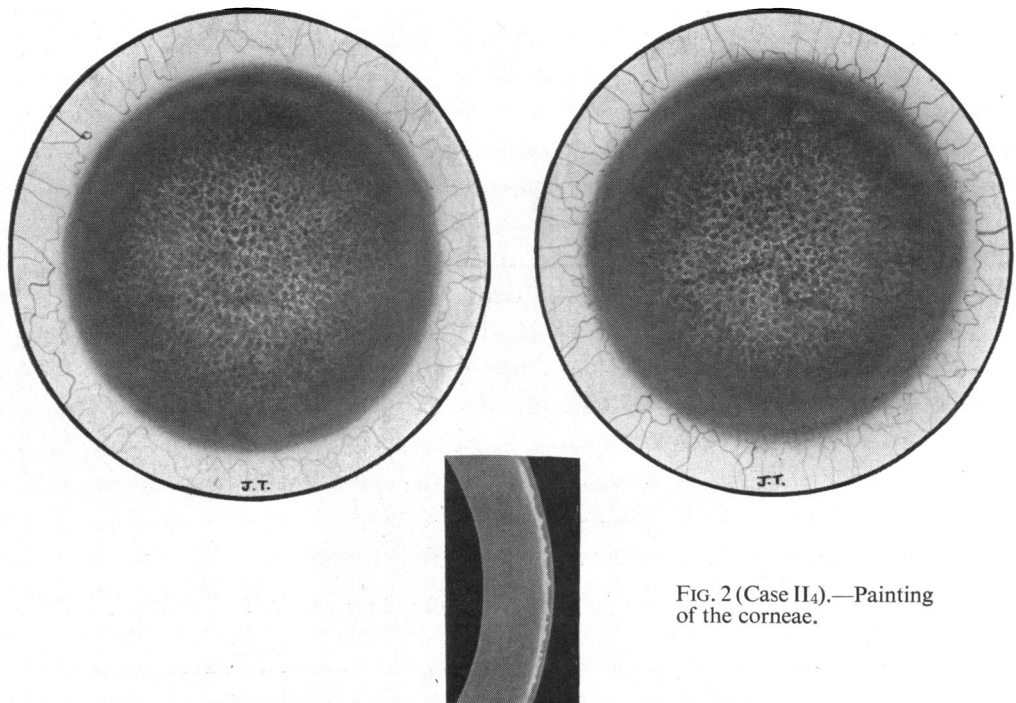


FIG. 2 (Case II₄).—Painting of the corneae.

In general, the opacification of the cornea was denser in the adults than in the children; in the child aged 2½ (IV₁₄) only a rather faint haze in the region of Bowman's membrane could be detected. The impression gained was that the opacification became progressively denser until the late second or early third decade. Support for this is given by one patient (IV₁₃) who was examined at Moorfields Eye Hospital when she was aged 3; at that time "no obvious corneal dystrophy" was recorded, whereas now at the age of 18 both corneae show pronounced opacification. Three patients have been observed during attacks and were found to have large central epithelial erosions, thus confirming the mechanism of the acute symptoms.

One patient (III₉) deviated from this general description in that her right cornea showed some diffuse scarring in the anterior half of the stroma. In addition, there was a round patch of brown pigment on the posterior corneal surface and a hole in the nasal part of the iris. She gave no history of trauma to account for this and no sign of a perforating corneal or scleral wound could be found; there was no clinical or radiological evidence of a retained intra-ocular foreign body.

All five of the affected adults showed some reduction of visual acuity after correction of refractive errors. The reduction was in general consistent with the degree of opacification of the cornea, although a certain amount of irregular astigmatism probably played some part. None of the eight asymptomatic members of the family showed any ocular abnormality. In particular, the corneae were clear and had normal sensation. No members of the family examined showed any defects apart from those found in the eyes.

Treatment

In two patients (III₉ and III₁₀) it was felt that, because of the persistence of troublesome attacks of epithelial erosion into middle life, surgical treatment was indicated. Accordingly

8.0 × 0.3 mm. lamellar keratoplasties were performed on the right eye of each patient (Fig. 3). It was noted that when the trephine was applied to the cornea of patient III₁₀ the whole epithelium was obviously loose and moved freely over the underlying tissues. The operations were performed 18 months ago and up to the present time no attacks of epithelial erosion have recurred in the grafted eyes.

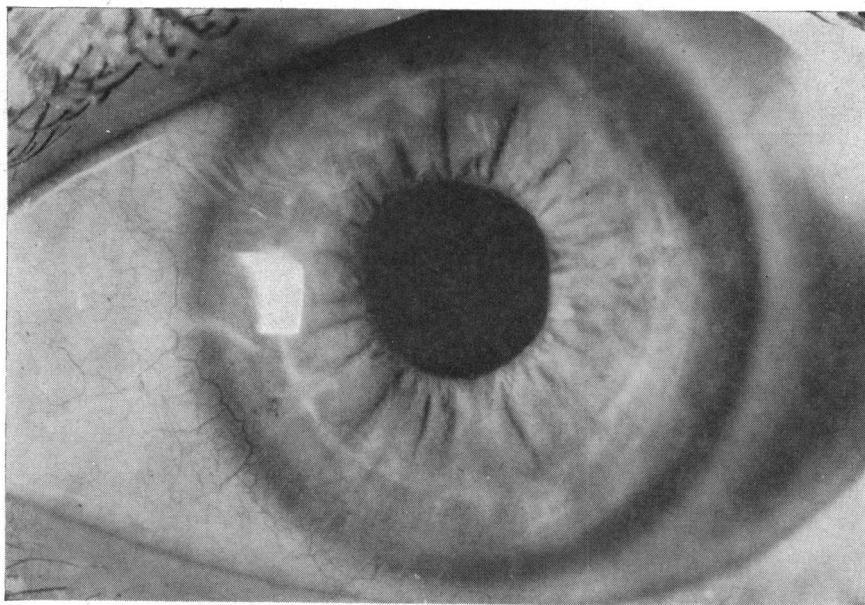


FIG. 3 (Case III₁₀).—Photograph of right cornea, showing lamellar graft.

The visual results of lamellar keratoplasty have, however, been disappointing (6/24 and 6/36 corrected) because of irregular astigmatism. It is therefore our opinion that, in cases of Reis-Bücklers' dystrophy which require surgery, the treatment of choice is either a deep lamellar or penetrating keratoplasty.

Pathology

Material and Methods

Representative portions of the corneal disc obtained from patients III₉ and III₁₀ were:

- (a) Fixed in 10 per cent. formol saline, embedded in paraffin, and serial sectioned;
- (b) Fixed in 2.5 per cent. glutaraldehyde in N/10 sodium bicarbonate buffer (pH 7.4), embedded in paraffin, and serial sectioned;
- (c) Fixed in 2.5 per cent. glutaraldehyde in N/10 sodium bicarbonate buffer (pH 7.4) and post-fixed in 1 per cent. osmium tetroxide in N/10 sodium bicarbonate buffer and embedded in Epon or Araldite;

or

- (d) Fixed in Zetterqvist's osmium tetroxide and embedded in Epon or Araldite.

The paraffin serial sections were stained as follows: haematoxylin and eosin, periodic acid-Schiff and haematoxylin (PASH), Masson's trichrome, phosphotungstic acid haematoxylin (PTAH), colloidal iron reaction (Rinehart-Abul-Haj modification), Alcian blue and nuclear fast red, toluidine blue, Best's carmine stain before and after treatment with

diastase, Wilder's reticulum stain, Congo red, methyl violet. Stained and unstained sections were examined for birefringence with polarized light. Thick sections of the Epon or Araldite-embedded material were stained with toluidine blue and examined by light microscopy, and thin sections from these blocks were stained for 20 minutes in 5 per cent. uranyl acetate in 1 per cent. acetic acid followed by 0.4 per cent. lead citrate in N/10 sodium hydroxide for 5 minutes, and examined with an AEI EM 6 electron microscope.

The findings are set out in detail below and are summarized in the Table.

TABLE
ANTERIOR STROMAL TISSUE

Stain	Case III ₉	Case III ₁₀
PASH	Variable	Negative
Masson's stain	Red—inconstant	Red—inconstant
PTAH	Blue—inconstant	Blue—inconstant
Toluidine blue	Orthochromatic	Orthochromatic
Colloidal iron stain	Negative	Negative
Alcian blue	Negative	Negative
Wilder's silver stain	Negative	Negative
Congo red	Negative for amyloid	Negative for amyloid
Methyl violet	Negative for amyloid	Negative for amyloid
Polarized light	Non-refrigent	Non-refrigent

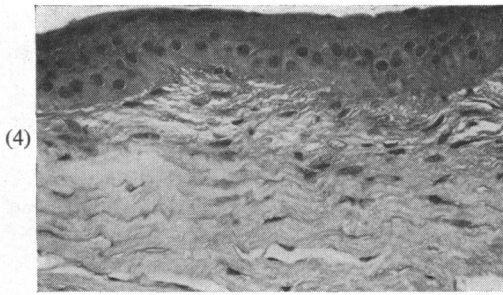
Case III₁₀ (31319/66)

(1) Formalin-fixed Tissue. Paraffin Sections

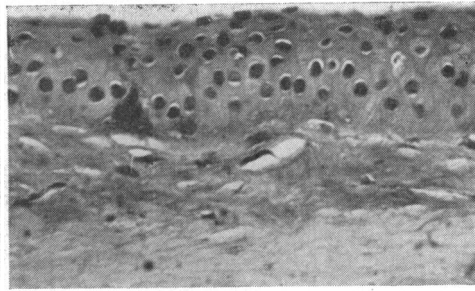
HAEMATOXYLIN AND EOSIN.—Sections showed a lamellar corneal disc with pronounced irregularity of the epithelium due to alternating areas of hyperplasia and atrophy. The normal epithelial architecture was lost, the nuclei being scattered haphazardly, and the cytoplasm, especially in some cells, was unusually abundant and eosinophilic. This disruption in cellular arrangement had resulted in an apparent irregularity of the size of epithelial nuclei in any one plane of section, but there were in addition, at scattered points in the basal layers of the epithelium, degenerate cells with disintegrating nuclei, cytoplasmic vacuoles, and eosinophilic inclusions, associated with extracellular debris. These cells stained more intensely with haematoxylin than their neighbours. In these degenerate areas the epithelium was sometimes detached from the stroma, producing small elongated oval spaces. Bowman's membrane was completely absent and replaced by strongly eosinophilic fibres arranged in wisps or strands, which extended inwards into the superficial corneal stroma, and outwardly appeared to fuse with the epithelium (where this was not detached) and to be continuous with minute perpendicular streams into the epithelium. There were scattered foci of proliferating keratocytes in the subepithelial stroma; no inflammatory cells were present. The main pathological changes were thus superficial, but deeper in the stroma there was minimal irregularity of the lamellae and of the nuclei of the keratocytes (Figs 4, 5, and 6, opposite).

PASH.—The abnormal superficial eosinophilic fibres were PAS-negative. Where the basement membrane could be discerned it was of normal thickness; in some places it was deficient and at others absent. In a few of the lacunae, formed by epithelial detachment, there was an accumulation of PAS-positive material continuous with the basement membrane (Fig. 7, opposite).

MASSON'S TRICHROME.—The eosinophilic fibres in the subepithelial stroma stained red, but irregularly and inconstantly. Red staining was also evident in the cytoplasm of some epithelial cells.



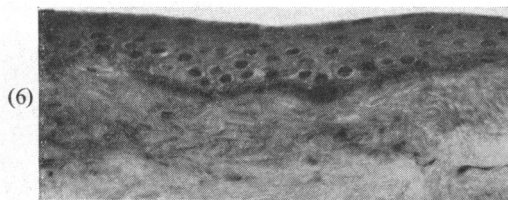
(4)



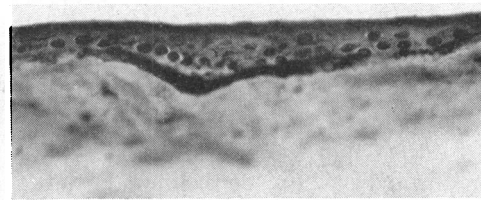
(5)

FIG. 4 (Case III₁₀).—Irregularity of corneal epithelium and loss of Bowman's membrane with fibrous replacement and numerous keratocytes. Haematoxylin and eosin. $\times 225$.

FIG. 5 (Case III₁₀).—Thickened and irregular epithelium, darkly staining cells in the basal layer, subepithelial debris, loss of Bowman's membrane, and eosinophilic staining in the anterior stroma. Haematoxylin and eosin. $\times 275$.



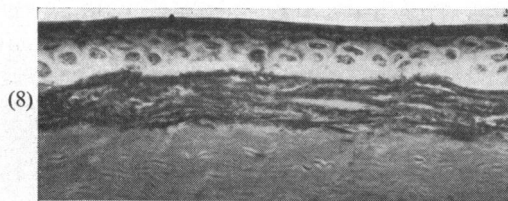
(6)



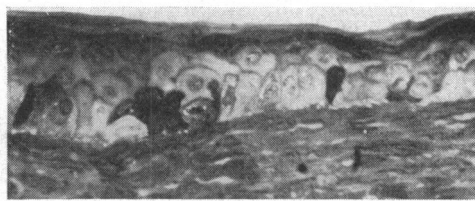(7)

FIG. 6 (Case III₁₀).—Irregular epithelium, subepithelial fluid debris, loss of Bowman's membrane, and eosinophilic staining in the fibrous anterior stroma. Haematoxylin and eosin. $\times 225$.

FIG. 7 (Case III₁₀).—Subepithelial fluid debris stains positively with periodic acid-Schiff stain. $\times 225$



(8)



(9)

FIG. 8 (Case III₁₀).—Loss of Bowman's membrane; the replacing fibrous tissue stains blue with phosphotungstic acid haematoxylin. $\times 275$.

FIG. 9 (Case III₁₀).—Araldite section, showing several irregular darkly-staining cells in the basal layers. Bowman's membrane is absent. Toluidine blue. $\times 275$.

PTAH.—This stain gave inconstant results according to the method used, but when the section was incubated in the stain at 56°C. for 90 minutes, the anterior stromal lamellae in the region of Bowman's membrane stained blue (Fig. 8, above).

COLLOIDAL IRON AND ALCIAN BLUE.—Both gave negative results.

TOLUIDINE BLUE.—The corneal stroma was metachromatic whereas the epithelium and subepithelial stroma were orthochromatic.

CONGO RED.—Negative for amyloid.

METHYL VIOLET.—Negative for amyloid.

Polarized light showed no abnormal birefringent material.

(2) *Glutaraldehyde-fixed. Paraffin Sections*

HAEMATOXYLIN AND EOSIN.—These showed similar appearances to those in the formalin-fixed tissue, except that there was less evidence of epithelial detachment, suggesting that this might in part have been due to artefact.

PASH.—These sections differed in some important respects from the formalin-fixed tissue. Although the anterior stroma was still PAS-negative, there was a very striking focal deposition of PAS-positive material in the anatomical situation of the basement membrane; PAS-positive material was also seen between the epithelial cells and in the flattened epithelial layers.

(3) *Electron Microscopy (EM 250)*

LIGHT MICROSCOPY of embedded sections at low magnification.

Fixed in glutaraldehyde (embedded in Araldite and stained with toluidine blue). The epithelium appeared irregular and showed disintegrating "dark" basal cells apparently forming subepithelial granular material. Bowman's membrane was absent (Fig. 9, see p. 583). The subepithelial stroma showed an irregular increase in density.

Fixed in osmium tetroxide (embedded in Araldite and stained with toluidine blue) showed similar appearances, but no subepithelial debris was found at this level of section.

ULTRASTRUCTURE

In the hyperplastic epithelium the most pronounced changes were seen in the basal layers where there were groups of cells showing an extreme degree of electron density ("dark cells"). Many of these cells appeared to have ruptured posteriorly and their disintegrating cytoplasmic contents formed an irregular layer of debris between the epithelium and underlying stroma. Within this debris numerous degenerate mitochondria, vesicles, and amorphous and particulate electron-dense material (glycogen granules) with occasional nuclear fragments were seen. Other basal cells and some wing cells showed pronounced nuclear clumping, separation of nuclear membranes, swollen mitochondria, vacuolated endoplasmic reticulum, dispersed ribosomes, and abundant glycogen granules. In areas where the basal cells had ruptured, their plasma membranes and hemidesmosomes could sometimes be discerned still attached to the stroma; elsewhere they had disappeared.

The normal feltwork of the fibres of Bowman's membrane was absent and replaced by a coarser mass of collagen fibres, some of which were considerably more electron-dense than others; this increase in density in any particular fibre was so sharply demarcated that in low magnifications it gave the impression of irregular deposits of electron-dense material. In addition to these electron-dense fibres of regular calibre, there were numerous electron-dense fibrils of finer calibre (about 80 Å), either scattered among the larger fibres or aggregated into irregular masses. Sections stained with uranyl acetate and lead citrate showed particularly well the intermingled dense and lucent fibres (Figs 10, 11, 12, and 13, opposite and overleaf).

Case III₉ (31778/66)

(1) *Formalin-fixed Tissue. Paraffin Sections*

HAEMATOXYLIN AND EOSIN.—Sections showed a lamellar corneal disc in which the epithelium was irregular, being thicker than normal in some areas and atrophic in others, resulting in a markedly corrugated base. In the basal layers pale swollen cells and shrunken, deeply-staining

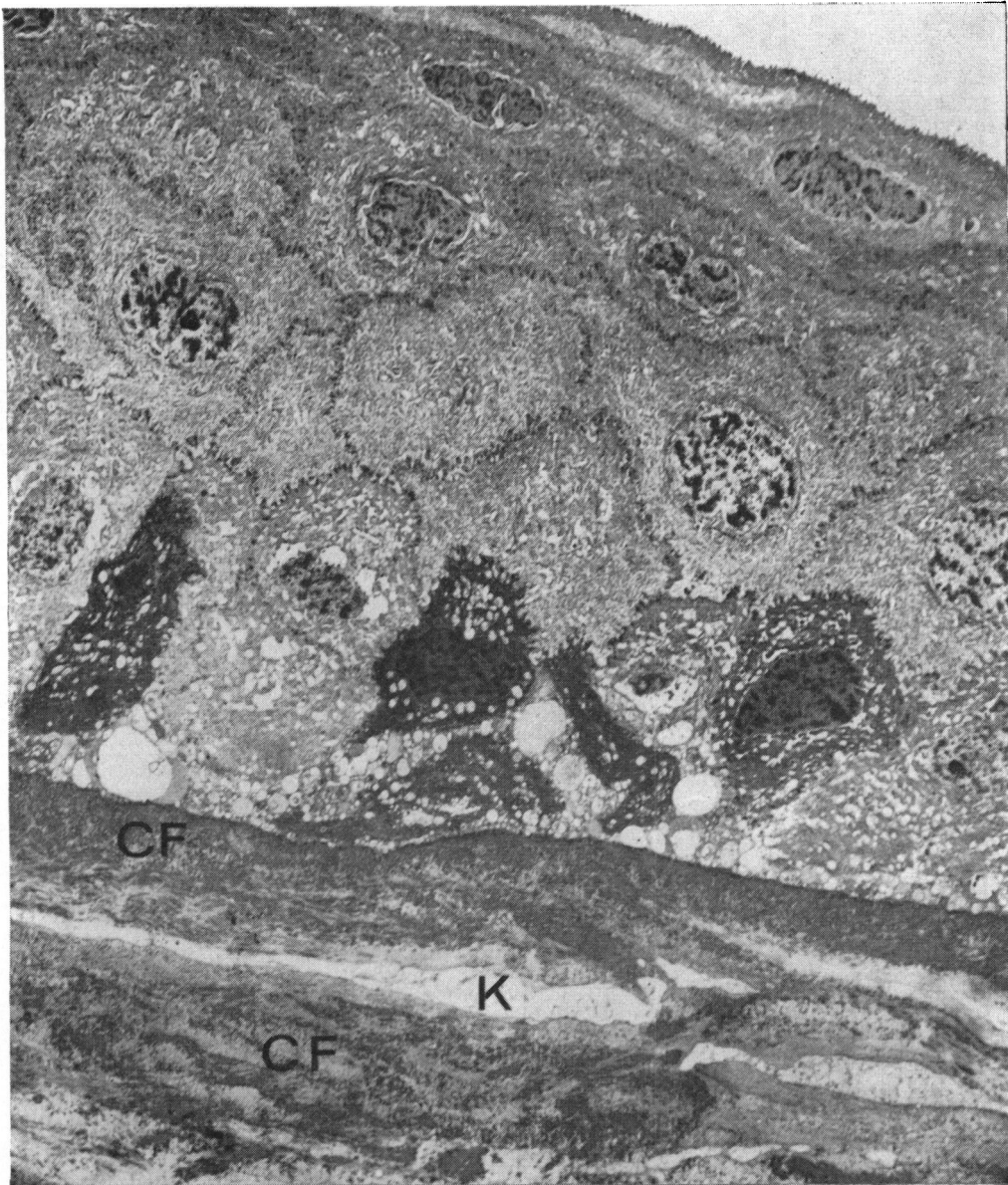

FIG. 10 (Case III₁₀).—Electron micrograph, showing epithelium and underlying stroma. The basal epithelial cells show vesiculation and separation of nuclear membranes. Numerous "dark cells" are present, some of which have ruptured, releasing their contents and detaching the epithelium. Bowman's membrane is absent and the replacing collagen (CF) shows electron-dense patches and numerous active keratocytes (K). Glutaraldehyde/O₂O₄/Araldite/uranyl acetate/lead citrate. $\times 2,800$.

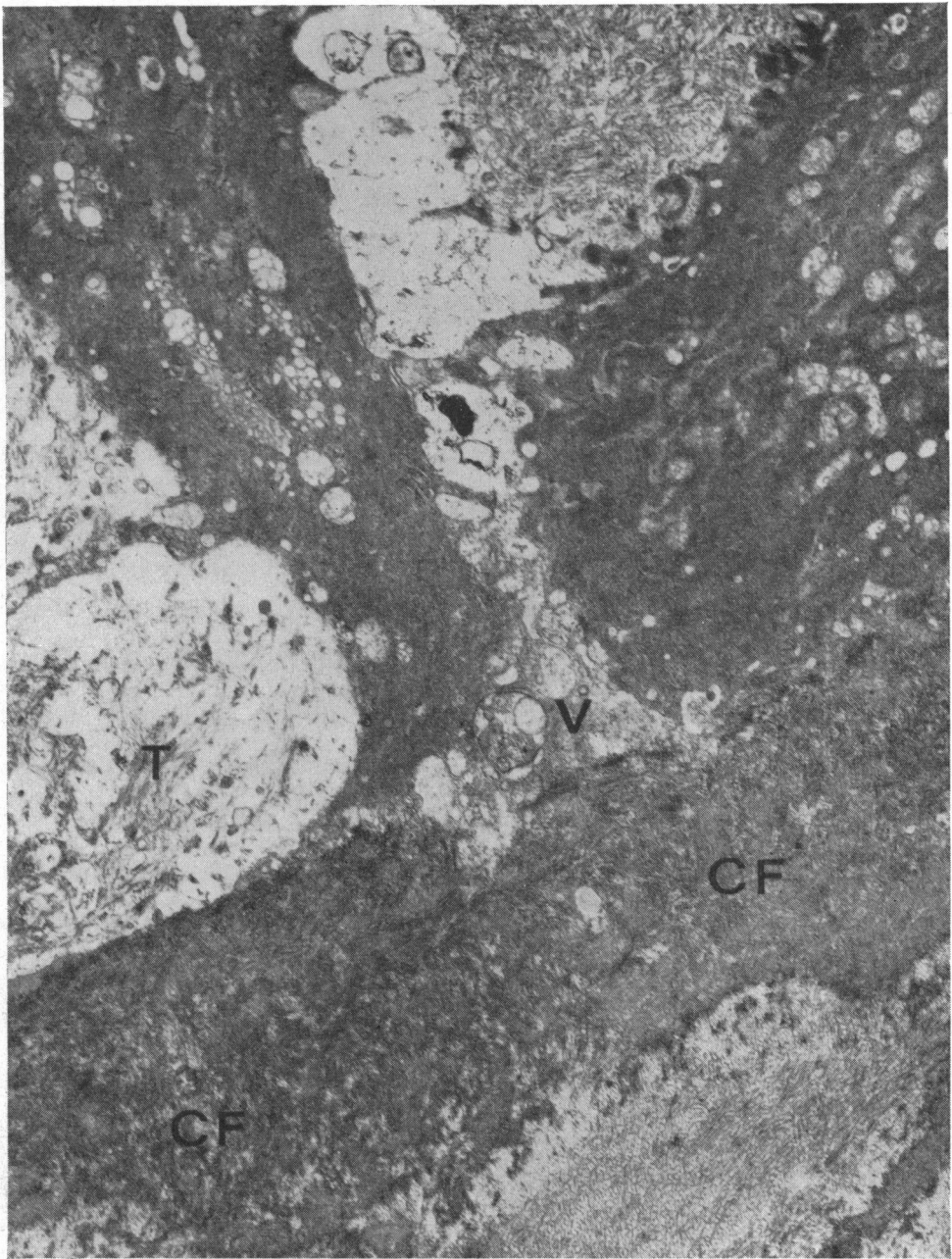


FIG. 11 (Case III₁₀).—Electron micrograph, showing epitheliolysis in the basal layer. Degenerate mitochondria can be seen in the dense cytoplasm of the "dark cells" (upper left and upper right), and cellular remnants, including tonofibrils (T) and vesicles (V), are present in the extracellular debris. Bowman's membrane is replaced with collagen fibres (CF) of varying electron-density. Glutaraldehyde/O₈O₄/Araldite/uranyl acetate/lead citrate. $\times 11,250$.

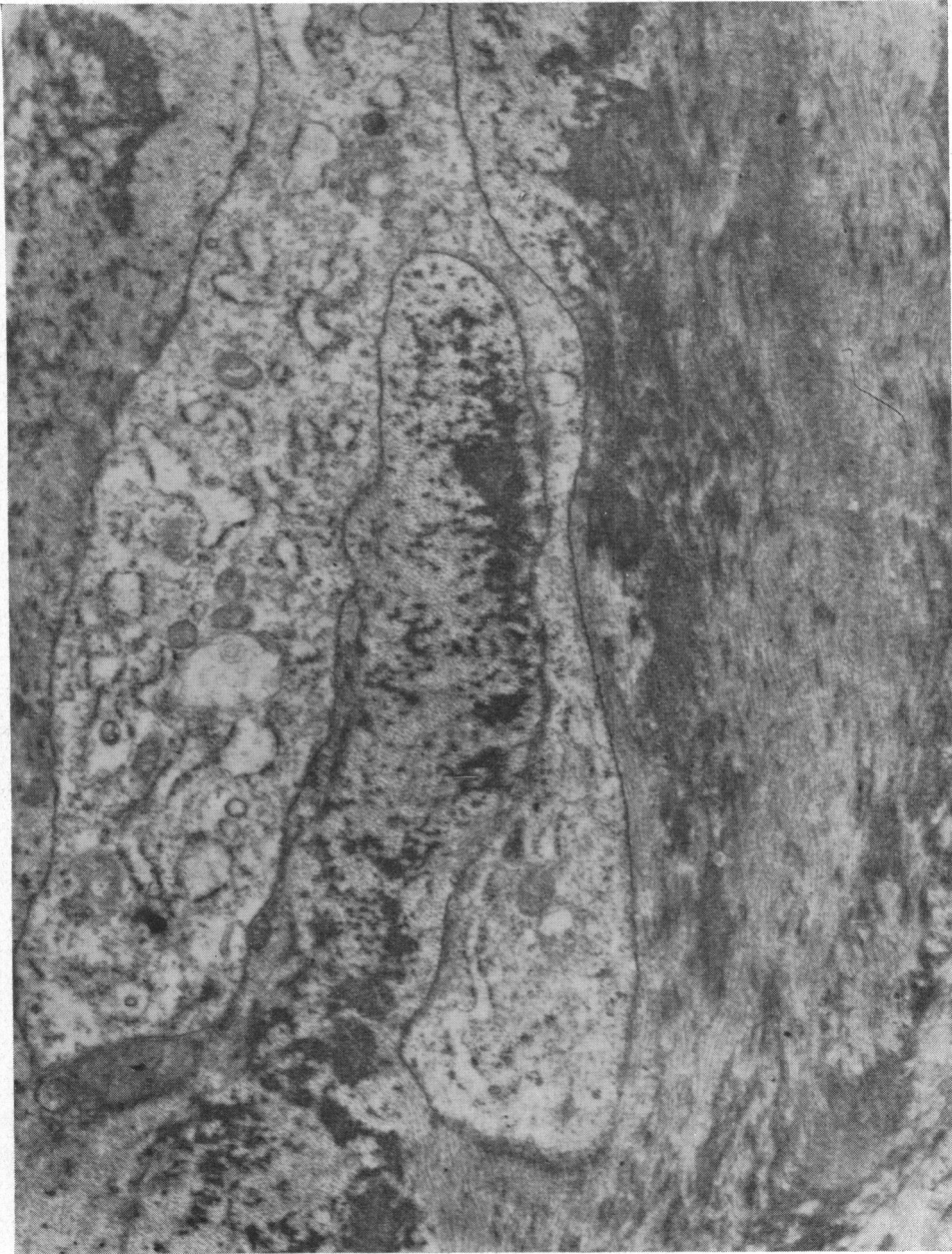

FIG. 12 (Case III₁₀).—Electron micrograph, showing an active keratocyte with abundant dilated rough surface endoplasmic reticulum lying in collagen fibres of different electron-densities. Glutaraldehyde/O₃O₄/Araldite/uranyl acetate. × 16,600.

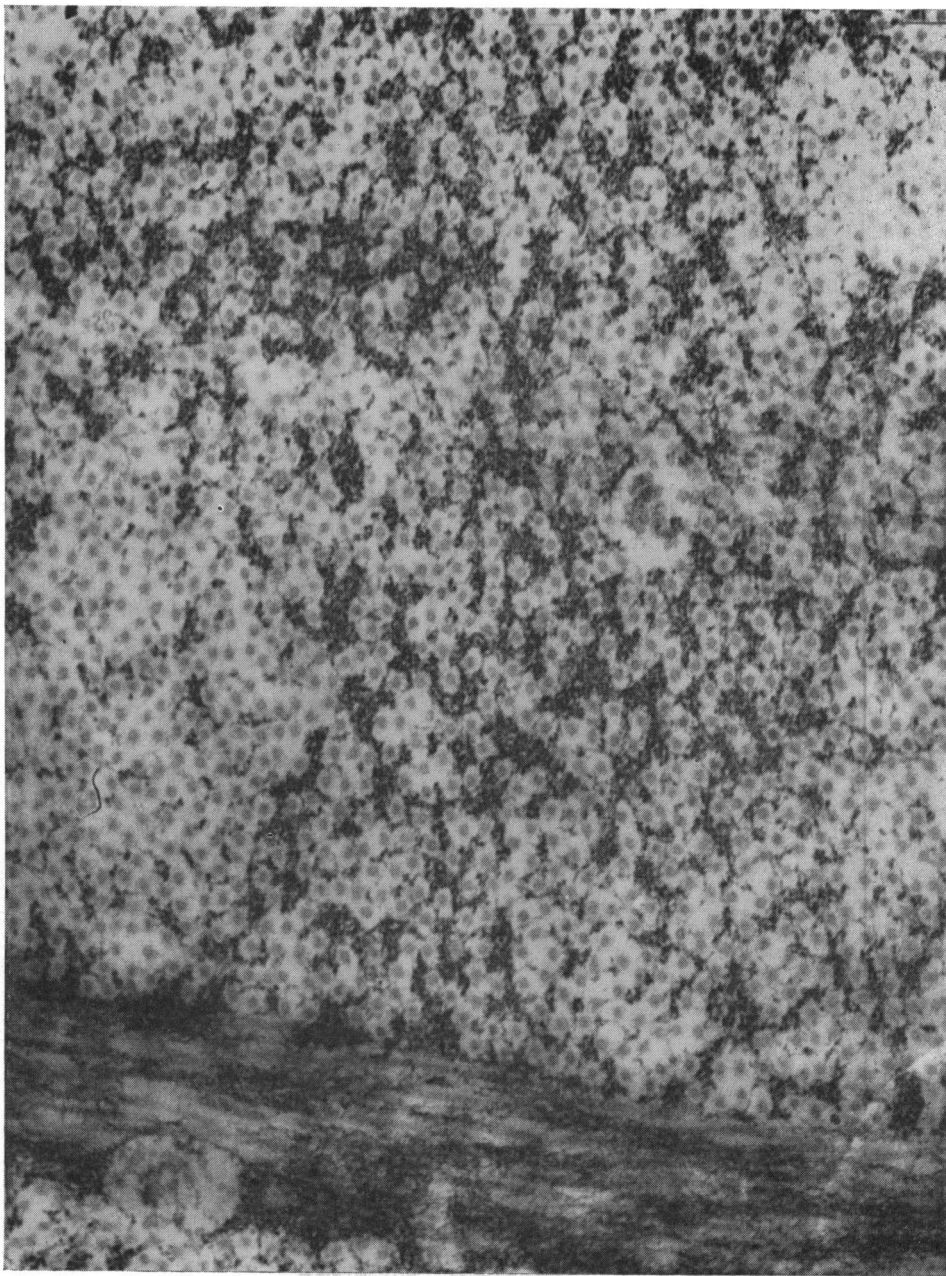


FIG. 13 (Case III₁₀).—High-power view of anterior corneal stroma. Bundles of electron-dense fibrils (about 80 Å) are intermingled with regular collagen fibres (200–250 Å). O₅O₄/Araldite/uranyl acetate/lead citrate. × 67,000.

cells were seen. Areas of shallow detachment of the epithelium were present. Bowman's membrane was almost entirely absent (fragments remained in a few sections) and the anterior lamellae stained intensely with eosin and appeared of greater density than normal, but there were no deposits in the stroma. No other significant abnormality was present.

PASH.—This staining showed a patchy deposit of PAS-positive granular material (particularly evident where the epithelium was detached) in the anatomical situation of the basement membrane (Figs 14 and 15, overleaf). Minute vacuoles and an occasional fragmented nucleus could be seen in this material. Similar PAS-positive material was also seen intercellularly in some areas of the epithelium and in the flattened superficial cells. All this PAS-positive material stained for glycogen with BEST'S CARMINE STAIN and became negative after digestion with diastase. The anterior stromal lamellae varied in their PAS-staining, but there was nothing to suggest an abnormal deposition of PAS-positive material anywhere in the stroma.

MASSON'S TRICHROME.—The abnormal anterior lamellae stained red, but irregularly and inconstantly, and in some areas there was little or no red staining in the anterior stroma.

PTAH.—The results were inconstant, but, as in the previous case, incubation with the stain at 56°C. for 90 minutes showed a patchy, light blue staining of the anterior stromal fibres, mainly at the periphery of the section.

COLLOIDAL IRON (Rinehart-Abul-Haj modification) AND ALCIAN BLUE.—Both these stains gave completely negative results.

TOLUIDINE BLUE.—The corneal stroma stained metachromatically, whereas the epithelium and subepithelial stroma were orthochromatic.

WILDER'S STAIN.—No argyrophilic fibres.

CONGO RED.—Negative for amyloid.

METHYL VIOLET.—Negative for amyloid.

Polarized light showed no abnormal birefringent material.

(2) *Glutaraldehyde-fixed. Paraffin Sections*

HAEMATOXYLIN AND EOSIN.—These showed no additional features, but the increased density of the anterior stroma was more evident.

PASH.—These appeared as already described.

(3) *Electron Microscopy (EM 251 A and B)*

LIGHT MICROSCOPY of embedded sections at low magnification.

Fixed in glutaraldehyde (embedded in Araldite-Epon and stained with toluidine blue). The epithelium showed several darkly-staining cells especially in the basal layer, and some intercellular material. Bowman's membrane was absent throughout, and numerous keratocytes, some vacuolated, were seen. Dense fibrous material was present in the subepithelial region.

Fixed in osmium tetroxide (embedded in Epon and stained with toluidine blue). One level of section showed an irregular and partially detached epithelium with subepithelial vacuolated material. Another level showed a greatly thickened epithelium which was otherwise normal. No darkly-staining cells were seen. Bowman's membrane was absent throughout and the anterior stroma was denser than normal and contained numerous keratocytes (Fig. 16, overleaf).

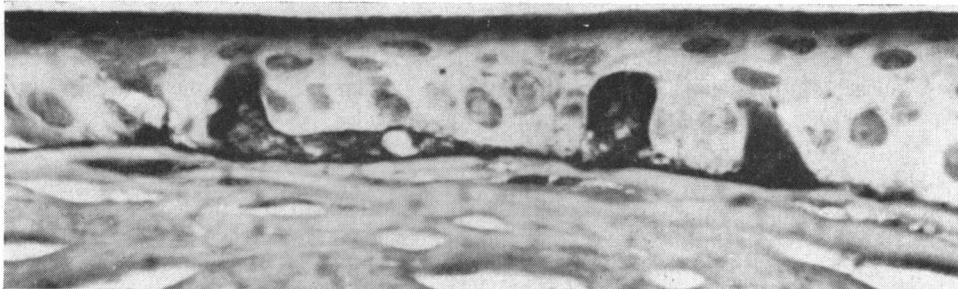


FIG. 14 (Case III₉).—Irregular epithelium and subepithelial PAS-positive fluid debris extending into the epithelium. Bowman's membrane is absent. Periodic acid-Schiff and haematoxylin (PASH). $\times 550$.

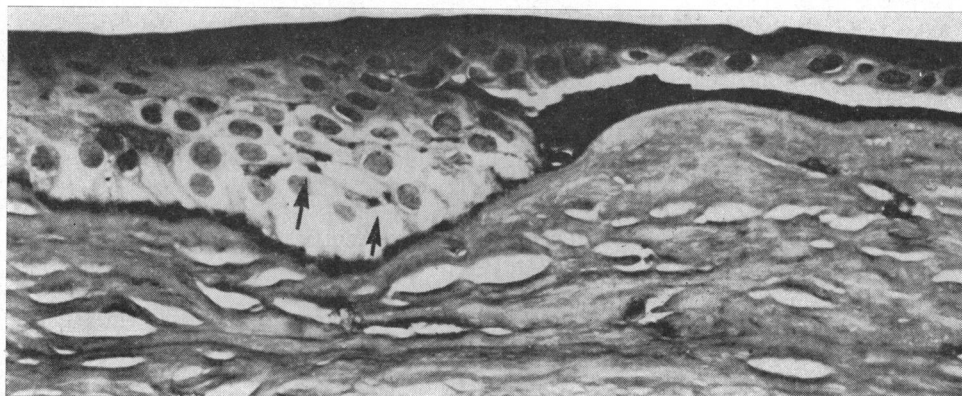


FIG. 15 (Case III₉).—Irregular epithelium detached by subepithelial PAS-positive fluid, which is also seen intercellularly (arrows). Bowman's membrane is absent. PASH. $\times 330$.

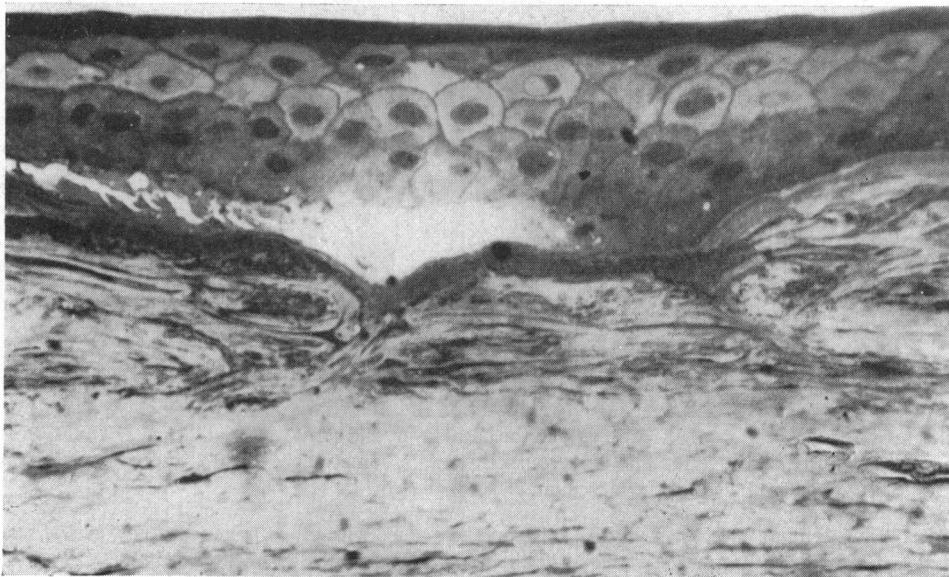


FIG. 16 (Case III₉).—Epon section, showing epithelial detachment, subepithelial fluid debris, absent Bowman's membrane, and numerous keratocytes in the fibrous anterior stroma. Toluidine blue. $\times 450$.

ULTRASTRUCTURE

Membrane bound vesicles were present in the cytoplasm of the basal cells, with clumping of nuclear chromatin and separation of the membranes of the nuclear envelope forming prominent perinuclear cisternae. Numerous shrunken cells of intense electron-density and showing little or no internal structure ("dark cells") were present in the basal layer. Occasionally epithelial cells were separated by granular material of varying electron-density. In some areas the epithelium was elevated by a subepithelial granular material containing amorphous debris, which had originated from cellular disintegration. The inner plasma membranes of these ruptured basal cells, together with the basement membrane and hemidesmosomes, were still attached to the underlying stroma. There was no thickening of the basement membrane, and in some areas it was deficient; here also the hemidesmosomes were absent and isolated processes of epithelial cells protruded into the adjacent stroma. There were many corrugations in the basal cell layer, the peaks of which were related to vertical condensations of tonofibrils in the cells; at these points the stroma appeared to be drawn upwards indenting the cell membranes. Bowman's membrane was absent and was replaced by disorientated masses of collagen fibres showing irregular and sharply demarcated zones of increased electron-density which, on higher magnification, were seen to be due partly to an increase in the density of the regular collagen fibres and partly to the presence of dense microfibrils (40–80 Å) intermingled with normal fibres and aggregated into masses. Numerous keratocytes, a few degenerate and others in various stages of activity, were seen among the collagenous tissue. Where the epithelial basement membrane was intact it lay directly upon this abnormal collagen (Figs 17, 18, 19, 20, and 21, overleaf).

Discussion

Clinical Features

There can be no doubt that the corneal dystrophy described in this English family is the same as that described by Bücklers and now usually referred to as Reis-Bücklers' dystrophy; apart from a few minor differences the clinical pictures are identical. The points in which the two families differ are as follows. In Bücklers' family the visual acuity was more profoundly affected, but the fact that his cases also showed a high degree of myopia may be significant. With regard to the clinical course, while both families ceased having attacks of epithelial erosion in the second or third decades, in Bücklers' cases the attacks recurred in the fifth decade; neither of our patients aged 45 and 70 have experienced this. Bücklers described limbal abnormalities in his cases, the palisades being abnormally long and white; our cases do not show this. These minor variations do not alter our opinion that the two families have the same condition; rather, they illustrate well how the same corneal dystrophy occurring in different families, while showing the same essential features, often manifests variations characteristic of a particular pedigree.

The cases of Verdi and Filippone (1958), Paufique and others (1964), Grayson and Wilbrandt (1966), and Griffith and Fine (1967), also appear to conform to the same general clinical pattern. This is true of the corneae in the cases reported by Collier (1962), but his family also had developmental anomalies of the irides; this may be significant in relation to our Case (III₉), who has one abnormal iris.

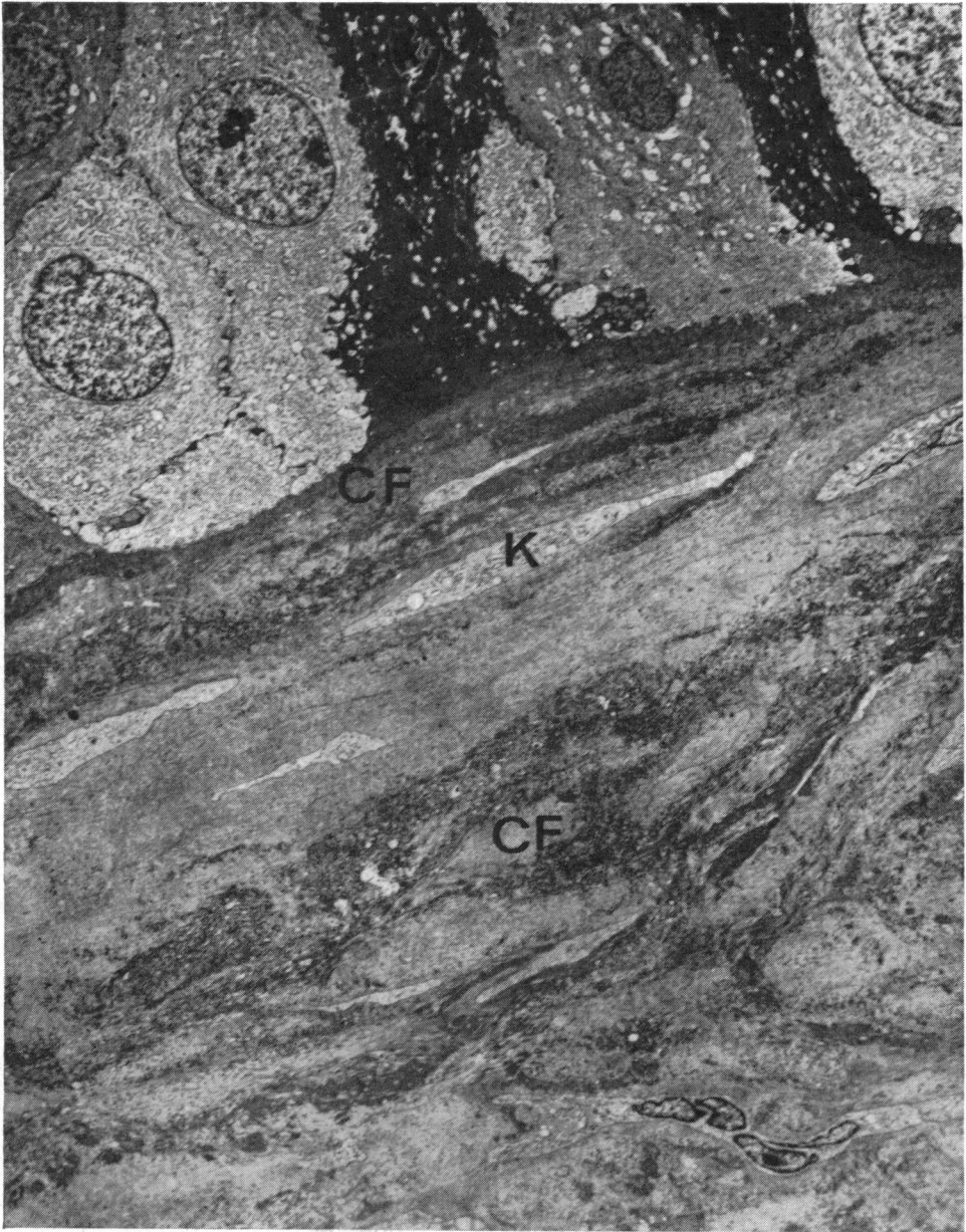


FIG. 17 (Case III₉).—Electron micrograph. The basal cells of the epithelium show vesiculation of the cytoplasm and clumping of nuclear chromatin; some are shrunken and extremely electron-dense ("dark cells").—Bowman's membrane is absent and replaced by disorientated collagen fibres of varying electron density (CF) containing numerous active keratocytes (K). Glutaraldehyde/O₃O₄/Araldite Epon/uranyl acetate/lead citrate. $\times 3,580$.

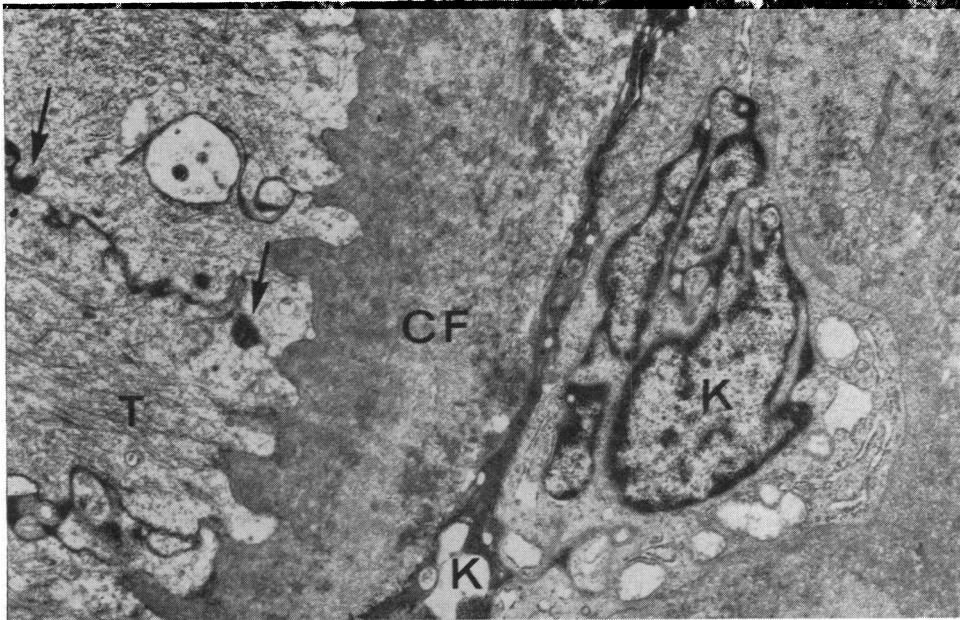


FIG. 18 (Case III₉).—Electron micrograph, showing corrugations at the junction of the basal epithelial layer and stroma. The peaks are related to vertical condensations of tonofibrils (T). Electron-dense material is present between the cells (arrows). Bowman's membrane is absent. Two keratocytes (K), one degenerate and the other active, showing dilated sacs of endoplasmic reticulum. The surrounding collagen fibres (CF) show electron-dense areas. Glutaraldehyde/O₆O₄/Araldite Epon/uranyl acetate/lead citrate. $\times 10,200$.

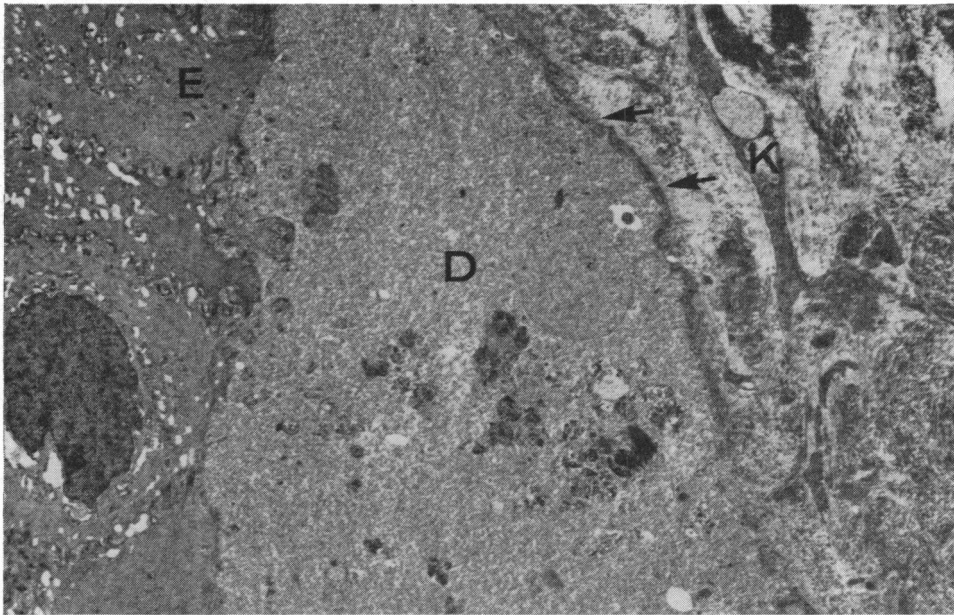


FIG. 19 (Case III₉).—Electron micrograph, showing epithelial detachment (E). The underlying debris (D) in which cellular fragments can be recognized originates from epitheliolysis. Remnants of hemidesmosomes and basement membrane are still present on the stromal surface (arrows). Electron-dense areas are present in the irregular collagen fibres which replace Bowman's membrane. A degenerate keratocyte (K) is present. Glutaraldehyde/O₆O₄/Araldite Epon/uranyl acetate/lead citrate. $\times 3,000$.

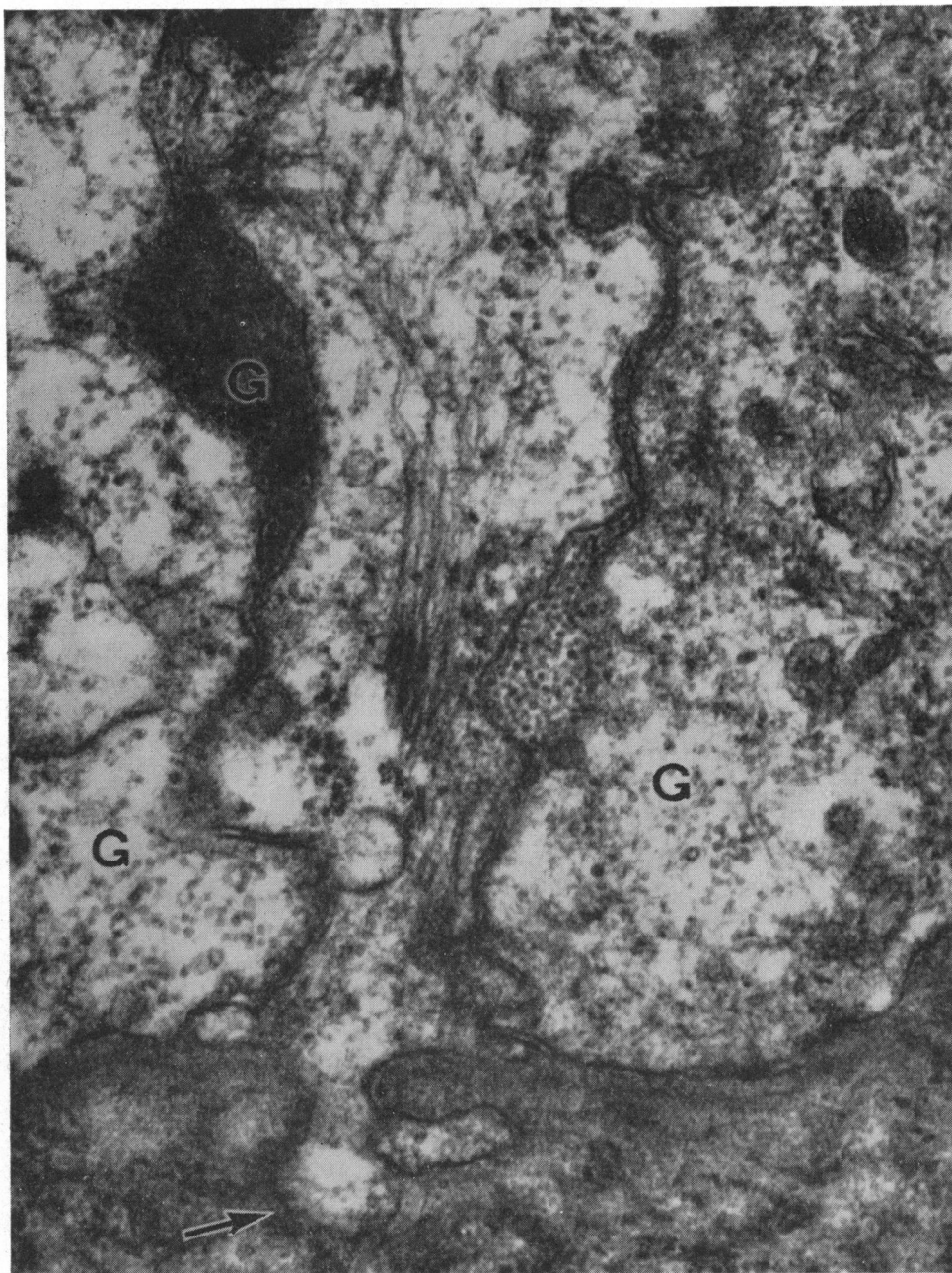


FIG. 20 (Case III₉).—Electron micrograph, showing granular material (G) between the basal epithelial cells and within their cytoplasm. Histochemically these proved to be glycogen granules. The basement membrane is normal, except at one point where the cytoplasm protrudes into the stroma (arrow). Glutaraldehyde/O₃O₄/Araldite Epon/uranyl acetate/lead citrate. $\times 65,000$.

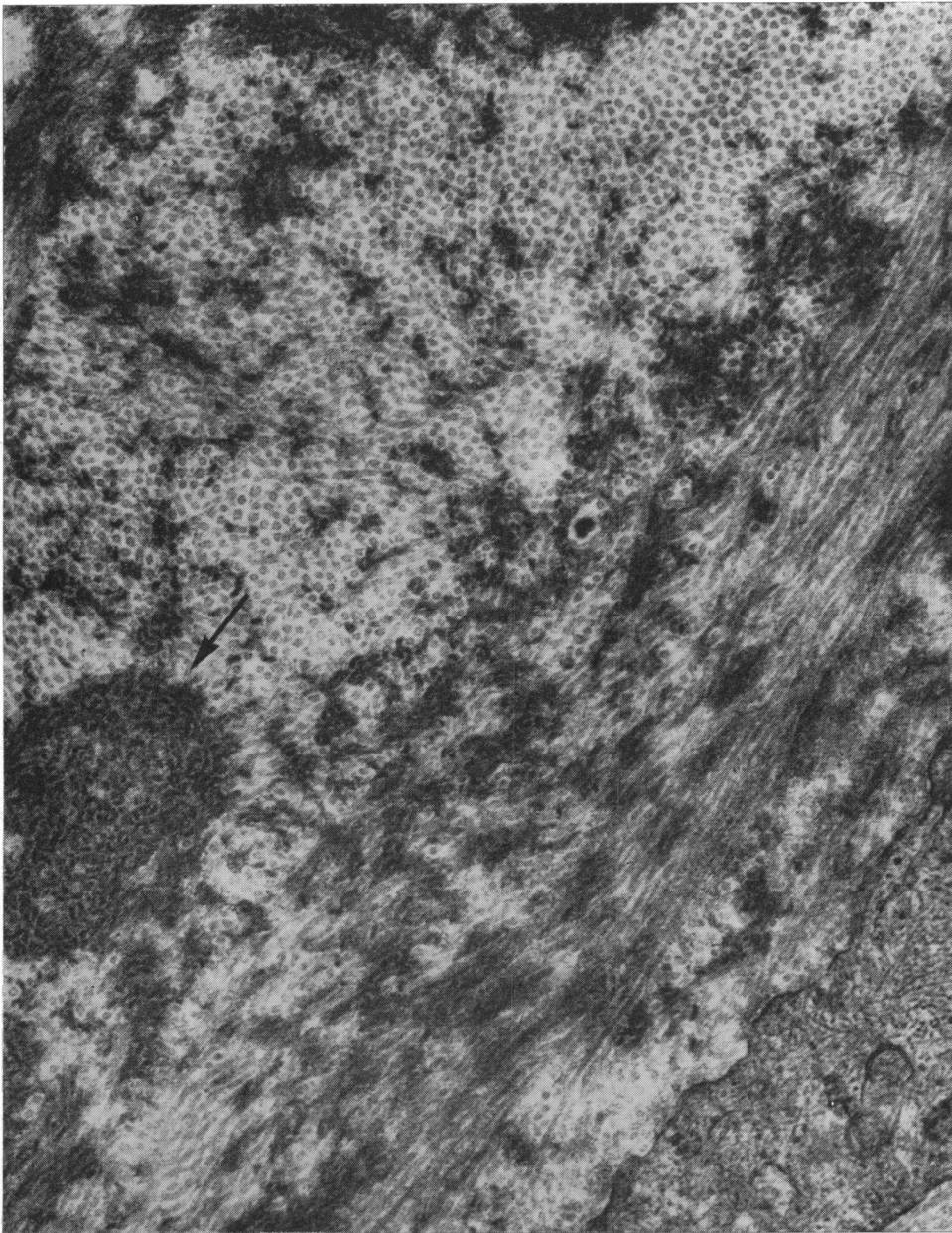


FIG. 21 (Case III₉).—Electron micrograph. Anterior collagen fibres show irregular and sharply demarcated zones of intense electron-density. In cross-section, dense fibres are seen intermingled with regular collagen fibres and aggregated in masses (arrow). Glutaraldehyde/O₃O₄/Araldite Epon/uranyl acetate/lead citrate. 44,500.

Genetic Aspects

In the family reported by Bücklers (1949) there were ten affected members, seven males and three females. The ratio of affected to unaffected among the progeny of affected people was 9 : 6 and all affected individuals had an affected parent. The mode of inheritance is clearly autosomal dominant with a high degree of penetrance. Verdi and Filippone (1958) reported a brother and sister, offspring of a consanguineous marriage, with a similar corneal dystrophy. Although they suggested that inheritance was probably recessive, a dominant mode of inheritance cannot be ruled out on this family history. Collier (1962) reported a family containing four affected individuals, two male and two female, in two generations; Paufigue and others (1964, 1966) reported a family containing twelve affected individuals, four male and eight female, in three generations; Grayson and Wilbrandt (1966) reported a family in which an affected female transmitted the condition to two sons, three other children being unaffected. These are also consistent with dominant inheritance.

In the family reported here the sex ratio of affected individuals is ten males to fifteen females, a statistically insignificant difference. The ratio of affected to unaffected among the progeny of affected people is 24 : 16, a difference that could easily have arisen by chance assuming a 1 : 1 expectation of an autosomal dominant trait. All affected individuals had an affected parent, and this, together with the ratio of affected to unaffected among the progeny of affected people, suggests complete penetrance of the gene.

Combining the present data with those of Bücklers (1949), Verdi and Filippone (1958), Collier (1962), Paufigue and others (1964, 1966), and Grayson and Wilbrandt (1966), the sex ratio of affected individuals is 26 males to 29 females. The ratio of affected to unaffected offspring of affected people is 46 : 30, a ratio that is in accordance with a dominant trait. The suggestion of Verdi and Filippone (1958) that autosomal recessive inheritance best explains their family does not apply to other families reported in the literature.

Reis-Bücklers' corneal dystrophy, therefore, is a condition inherited as an autosomal dominant with complete penetrance of the gene.

Pathology

Epithelium.—The epithelial changes in this condition are very similar to those to be found in chronic epithelial oedema from any cause. The disintegration of basal cells, which this electron microscopical study demonstrates conclusively, has been described in corneal oedema for many years (Brugger, 1886; Gilbert, 1908). More recently, in a study of experimental bullous keratopathy in cats, Cogan (1941) concluded that the amorphous debris in epithelial bullae was probably derived from ruptured epithelial cells which disgorged their contents beneath the epithelium—exactly as we have found in the present investigation. The epithelial detachment must have been due to this epitheliolysis of basal cells, for their hemidesmosomal attachments were thus rendered ineffective. The cellular debris contained, in addition to remnants of nuclei and organelles, numerous electron-dense granules, which were seen also intra- and intercellularly. Most of these were glycogen granules released from the ruptured cells, for not only were their ultrastructural appearances typical (Kugler, 1967), but their positive staining with PAS and Best's carmine, as seen by light microscopy, became negative after diastase digestion. The PAS-positive staining might easily be misinterpreted as thickening of the basement

membrane, but electron microscopy disproved this. Indeed, in these areas of epithelial detachment the basement membrane and associated hemidesmosomes were usually fragmented or absent, as noted also by Griffith and Fine (1967).

"Dark cells".—Most of the ruptured basal cells referred to above were extremely electron-dense, which corresponded in light microscopy with a more densely staining cytoplasm. It is an old observation that "dark cells" may be seen in the basal layers of the normal corneal epithelium (Virchow, 1910), and it has been thought that they were the more mature basal cells in the course of forward migration (Cogan, 1951). Binder (1951, 1952) held that the clear "matrix" basal cells divided laterally within the confined spaces of the basal layer, one or both of the new cells being compressed forward into the epithelium; according to him "compressibility" was characteristic of the young cell. Presumably compression results in condensation of the cytoplasm rendering the cell darker than its normal neighbour; similar views were previously put forward by Virchow (1910), Matsumoto (1918), and Matsumoto and Ishimaru (1922). Alternatively, the differing density of the basal cells may simply reflect differing stages in their physiological activity.

From his electron microscopical studies, however, Teng (1961) attributed to apparently the same "dark cells" a special activity in secreting the basement membrane and he called them "secretory cells". He noted that their contents were sometimes released into the intercellular spaces producing "transient secretory capillaries"; and he compared them with unicellular glands of the apocrine type. It may be significant, however, that he noted them more frequently in pathological conditions, namely, keratoconus and glaucoma, and very recently they have been described electron microscopically in the basal layers of a case of lattice dystrophy (Hogan and Alvarado, 1967a). It is our experience that these cells, which in paraffin sections appear shrunken and stain more deeply with haematoxylin than their fellows, are not infrequently seen in the normal corneal epithelium (Fig. 22), and are common in pathological conditions, particularly in association with corneal oedema and epithelial proliferation. This is not surprising if it is true that they are simply compressed cells, for it would be expected that any increase in tissue tension from swelling or undue cellular proliferation would result in an increase in their number and might even cause rupture of their cell membranes. The condensation of the cytoplasm in these cells would account for the increased density of osmiophilic particles and to the apparent increase of endoplasmic reticulum and Golgi vacuoles which Teng (1962) interpreted as evidence of secretory activity. Since Teng's material, derived from laboratory animals and human

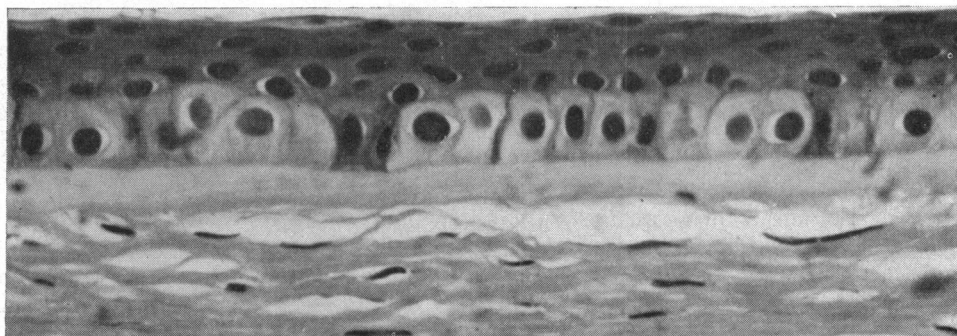


FIG. 22.—Normal human corneal epithelium, showing shrunken darkly-staining cells and swollen light-staining cells in the basal layer. Haematoxylin and eosin. $\times 550$.

eyes removed in exenterations for orbital neoplasms, cannot be assumed to be necessarily normal, it is possible that rupture of basal cells might account for the cytoplasmic material he observed in the intercellular spaces. Thus, with these alternative explanations, the evidence that "dark cells" perform any special secretory function appears to be inadequate at present, and we believe that "dark cells" and ruptured cells in the basal layers of our cases of Reis-Bücklers' dystrophy are most probably due to chronic epithelial oedema.

Bowman's membrane was absent in our first case and almost completely absent in the second, and its disappearance is obviously a feature of Reis-Bücklers' dystrophy. As is well known, however, the absorption or destruction of Bowman's membrane is a very common pathological change, presenting in many forms of corneal ulceration and chronic keratitis, and it does not follow that its absence in this condition, wherein recurrent erosions are a clinical feature, has any specific significance.

A similar histological picture may present in Fuchs's combined dystrophy, where the epithelium is irregular and becomes detached and where, in advanced cases, Bowman's membrane is replaced by proliferating stromal cells and cicatricial connective tissue. Comparable histological changes have also been described in congenital hereditary corneal dystrophy (Maumenee, 1960) and in atypical mucopolysaccharidosis (Gollance and D'Amico, 1967). These changes in the anterior cornea, so closely resembling those of Reis-Bücklers' dystrophy, are all secondary to chronic oedema and not, as far as is known, to any hereditary defects in Bowman's membrane or in the anterior stroma.

On the other hand, Griffith and Fine (1967), in their case of Reis-Bücklers' dystrophy, observed degenerative changes in Bowman's membrane consisting of disorganization of its normal fibrillar arrangement, and concluded that this probably represented the earliest change; a view supported by the clinical findings of Paufigue and Bonnet (1966) and of ourselves, that the initial opacities appear with election at the level of Bowman's membrane. In our ultra-thin sections Bowman's membrane was not present, and since we found changes closely similar to those of Griffith and Fine (1967) we are in some doubt whether the pathology they described was actually in Bowman's membrane or in the replacing tissue.

Other dystrophies wherein Bowman's membrane may be destroyed are lattice dystrophy, recently held to be an inherited variety of localized amyloidosis (Seitelberger and Nemetz, 1961; Klintworth, 1967), granular dystrophy, and macular dystrophy, but, quite apart from their distinct clinical appearances, they are all associated with definite deposits or well-defined masses in the stroma, which are not found in Reis-Bücklers' dystrophy, wherein the stromal changes are confined to the superficial lamellae (Paufigue and Bonnet, 1966; Griffith and Fine, 1967). Moreover, when Bowman's membrane is destroyed in these dystrophies, it is associated with the deposition of hyaline or granular material, quite unlike Reis-Bücklers' dystrophy wherein the replacing collagen, however abnormal and irregular, seemed in our cases to have maintained its fibrous character. Since Reis-Bücklers' dystrophy has been thought to be related to lattice dystrophy, it should be noted that the fibrous material replacing Bowman's membrane in our cases did not have the tinctorial properties of either the superficial lesions or stromal lesions of lattice dystrophy as described by Dark and Thomson (1960), Jones and Zimmerman (1961), and Klintworth (1967). Stains for amyloid in our cases were negative. The significance of these differences, however, is quite obscure for, as discussed in a later paragraph, the electron microscopical appearances of lattice dystrophy and Reis-Bücklers' dystrophy are very similar.

In any event the tinctorial properties of the superficial stroma in Reis-Bücklers' dystrophy do not seem to indicate any specific entity, for we have found very similar staining reactions in the anterior cicatricial changes of chronic herpetic keratitis, with similar electron microscopical appearances (Fig. 23, overleaf). Hogan (1967) has also reported such ultrastructural changes in herpetic keratitis.

Electron microscopically, the predominant features of this superficial replacing tissue are the presence of numerous keratocytes in varying stages of activity, with a few degenerate cells, and an abundance of randomly arranged regular collagen fibres (about 250 Å wide) associated with much finer fibrils (about 80 Å). Sections stained with uranyl acetate and lead citrate show what appear to be sharply demarcated and sometimes confluent electron-dense masses within the relatively electron-lucent regular collagen. Higher magnification, however, shows this to be due not only to a focal increase in the electron-density of regular collagen fibres, but also to the finer fibres which are predominantly electron-dense. These appearances are exactly similar to those described by Griffith and Fine (1967) in their electron microscopical study of Reis-Bücklers' dystrophy, and to those described in lattice dystrophy (McTigue and Fine, 1964; Klintworth, 1967; Hogan and Alvarado, 1967a). That these two diseases share the same ultrastructure was thought by Griffith and Fine (1967) to add some support to the suggestion of Bücklers (1949) that the condition he was describing might be a variant of lattice dystrophy.

The electron-dense fibres in lattice dystrophy were attributed by McTigue and Fine (1964) to "fibrillary degeneration" and they believed the delicate fibril to be a breakdown product of the larger collagen fibre, possibly due to loss of binding polysaccharide, a view held to be compatible with the characteristic loss of staining for mucopolysaccharide in this dystrophy. Hogan and Alvarado (1967a) also believed these appearances to be due to fibrillary degeneration, and compared them with those found in pterygia and pingueculae (Hogan and Alvarado, 1967b). Certainly there would appear to be no specific significance in the development of such fibrillary material for, as already pointed out, we have seen exactly comparable changes in electron micrographs of a corneal disc from an old herpetic keratitis, but whether these fibrils are necessarily a breakdown product is debatable.

In Reis-Bücklers' dystrophy, for instance, it would seem probable that the anterior stromal reaction is regenerative rather than degenerative. The presence of numerous keratocytes showing extensive development of rough-surfaced reticulum, denoting synthesis and secretion of protein (Palade, 1958)—and in the case of the fibroblast denoting collagen synthesis (Lowther, Green, and Chapman, 1961)—is presumptive evidence of regenerative activity. The coarse and fine fibrils of varying electron-density might, therefore, be interpreted as collagen precursors—probably corresponding to "reticulin" of light microscopy (Dunnington and Smelser, 1958; Melcher, 1966) in various stages of aggregation with associated lipid and mucopolysaccharide (the increased electron-density may be due to the fact that lead salts have a stronger affinity for mucopolysaccharides than for collagen—Clark and Curran, 1964). Thus the subepithelial changes of Reis-Bücklers' dystrophy could be due to cicatricial tissue replacing or absorbing Bowman's membrane, and it is possible that the chronic and recurrent breakdown and repair of the epithelium re-activates the stromal cells (Weimer, 1960).

There is, however, little information in the literature about the ultramicroscopical appearances of corneal scars. Variation of width of collagen fibrils in corneal scar tissue

was commented upon by Jakus (1962), but no reference was made to variation in electron-density. We have, therefore, made a preliminary study of corneal scar tissue in the rabbit. In a 6-day-old scar of a perforating wound we found very similar electron-dense fibrillar material interspersed between the regenerating collagen fibres (Fig. 24, opposite) and therefore suspect that this fibrillar material may appear either in the build-up or in the breakdown of collagen—processes which might, of course, co-exist. Further investigation will no doubt elucidate these points; meanwhile they should be considered when interpreting the significance of comparable electron microscopical appearances.

It is apparent that corneal conditions showing at some stage a similar ultrastructure may possess different tinctorial properties histologically (*e.g.* Reis-Bücklers' dystrophy and lattice dystrophy), and conditions with a similar histology at some stage, may differ clinically (*e.g.* Reis-Bücklers' dystrophy and congenital hereditary corneal dystrophy), which leads to some confusion in recognizing and classifying these diseases. Clearly, it is in the nature of the initial lesions that the difference probably lies, and many of the subsequent developments are general and non-specific.

Unfortunately, as in the case of Griffith and Fine (1967), this present study does not provide any conclusive answer to the question of the sequence of pathological events in Reis-Bücklers' dystrophy, and since the fibrillary changes appear non-specific in character, the mere fact that they are common to Reis-Bücklers' dystrophy and lattice dystrophy does not greatly influence the argument that they may be aetiologically related. From the pathology alone, all the changes found in Reis-Bücklers' dystrophy could derive from recurrent epithelial breakdown, with resulting activation of stromal cells and absorption of Bowman's membrane. There is, however, some clinical evidence which suggests that the primary defect may not lie in the epithelium. The opacities in the region of Bowman's membrane have been seen to appear very early in life and the attacks of epithelial erosion are self-limiting, usually ceasing by the end of the second decade. Further evidence is provided by a case of familial corneal dystrophy we have seen, in which the clinical appearances were identical with those of Reis-Bücklers' dystrophy, but there was no history of acute epithelial erosions. It is also worth noting that cases of recurrent epithelial erosion do not show the distinctive opacities seen in Reis-Bücklers' dystrophy. The examination of biopsy material from early cases is likely to prove more helpful, but at the present time the primary pathological change remains unidentified.

Summary

The clinical manifestations and genetic features of Reis-Bücklers' corneal dystrophy occurring in an English family are described. It is confirmed that the condition is inherited as an autosomal dominant.

The histological, tinctorial, and electron microscopical appearances of the corneal discs from two cases have been studied. In both cases the epithelium was irregular and partially detached with subepithelial fluid containing glycogen. The basement membrane where present was of normal thickness. Bowman's membrane was absent and replaced by irregular eosinophilic fibres confined to the anterior stroma. Staining reactions were inconstant and non-specific. Electron microscopy showed degenerative changes in the epithelium, particularly in the basal layers where there were clusters of extremely electron dense cells ("dark cells") some of which had ruptured giving rise to subepithelial granular

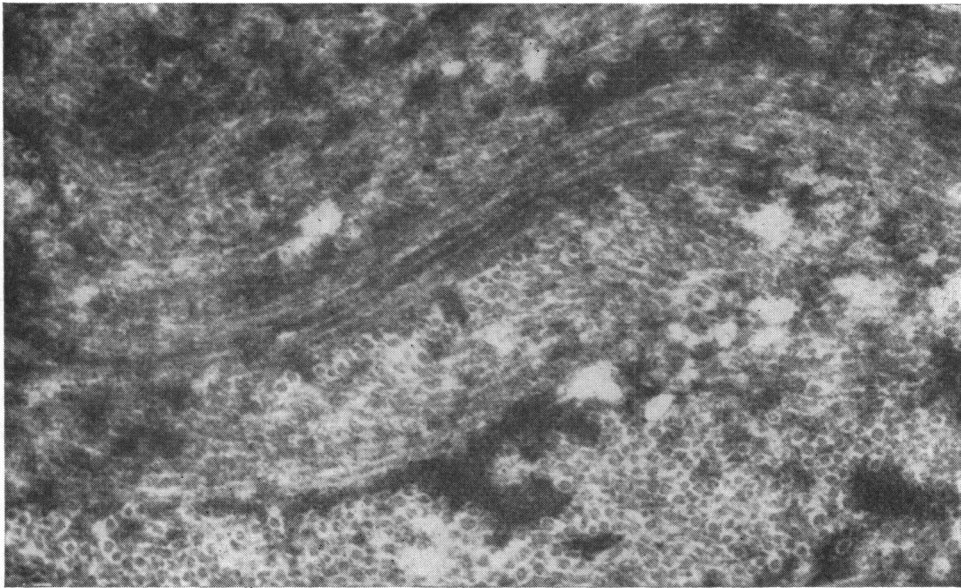


FIG. 23.—Electron micrograph of cornea from a case of old herpetic keratitis. Bundles of electron-dense fibrils are intermingled with regular electron-lucent collagen fibres. Compare with Figs 13 and 21. O_5O_4 /Araldite Epon/uranyl acetate/lead citrate. $\times 45,000$.

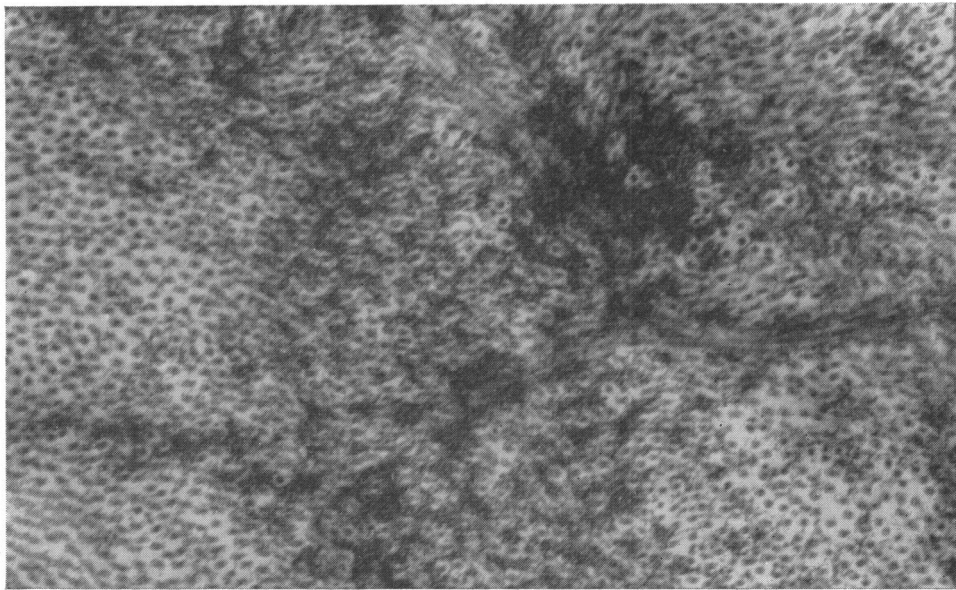


FIG. 24.—Electron micrograph of a 6-day-old scar from a perforating corneal wound (rabbit), showing bundles of fine electron-dense fibrils intermingled with regular collagen fibres. Compare with Figs 13, 21, and 23. O_5O_4 /Araldite/uranyl acetate/lead citrate. $\times 48,000$.

debris. The hemidesmosomes were thus ineffective and detachment occurred in these areas. Similar granular material was also present between the epithelial cells. The nature of the "dark cells" is discussed.

The anterior fibrous tissue replacing Bowman's membrane was found to consist of disorientated regular collagen fibres (200–250 Å) of varying electron-density interspersed with electron-dense fibrils of smaller calibre (about 80 Å) which were occasionally grouped in irregular masses. Numerous keratocytes in various stages of activity were found in this collagenous material. These appearances have previously been described in Reis-Bücklers' dystrophy and lattice dystrophy as "fibrillary degeneration", but since similar changes can be demonstrated in corneal scarring it would seem equally possible that they may represent a regenerative process.

These findings are evaluated in relation to other pathological conditions and it is concluded that, although the structural changes found in Reis-Bücklers' dystrophy could be due to recurrent epithelial breakdown, resulting in activation of stromal cells and absorption of Bowman's membrane, the same picture might equally well derive from a primary degeneration of Bowman's membrane, as seems more likely from clinical observation. Identification of the initial pathological change still awaits examination of material at an earlier stage of the disease.

It is a pleasure to acknowledge the help of Dr. M. Shakib, Dr. R. Tripathi, and Mr. D. Wood who at various times contributed to the electron microscopical study, and we are grateful to Mr. G. E. Knight and Mr. A. McNeil for technical assistance and Miss E. FitzGerald for secretarial help. We are indebted to Miss J. Trotman for the clinical paintings.

REFERENCES

- BINDER, R. (1951). *Wien. klin. Wschr.*, **63**, 701.
 ——— (1952). *Ibid.*, **64**, 978.
 BRUGGER, R. (1886). *Klin. Mbl. Augenheilk.*, **24**, 500.
 BÜCKLERS, M. (1949). *Ibid.*, **114**, 386.
 CLAG, A. E., and CURRAN, R. C. (1964). *Nature (Lond.)*, **202**, 912.
 COGAN, D. G. (1941). *Arch. Ophthal. (Chicago)*, **25**, 941.
 ——— (1951). *Trans. Amer. Acad. Ophthal. Otolaryng.*, **55**, 329.
 COLLIER, M. (1962). *Arch. Ophthal. (Paris)*, n.s. **22**, 131.
 DARK, A. J., and THOMSON, D. S. (1960). *Brit. J. Ophthal.*, **44**, 257.
 DUNNINGTON, J. H., and SMELSER, G. K. (1958). *A.M.A. Arch. Ophthal.*, **60**, 116.
 GILBERT, W. (1908). *v. Graefes Arch. Ophthal.*, **69**, 1.
 GOLLANCE, R. B., and D'AMICO, R. A. (1967). *Amer. J. Ophthal.*, **64**, 707.
 GRAYSON, M., and WILBRANDT, H. (1966). *Ibid.*, **61**, 345.
 GRIFFITH, D. G., and FINE, B. S. (1967). *Ibid.*, **63**, 1659.
 HOGAN, M. J. (1967). *Trans. ophthal. Soc. U.K.*, **87**, 113.
 ——— and ALVARADO, J. (1967a). *Amer. J. Ophthal.*, **64**, 656.
 ——— (1967b). *Arch. Ophthal. (Chicago)*, **78**, 174.
 JAKUS, M. A. (1962). *Invest. Ophthal.*, **1**, 202.
 JONES, S. T. (1962). In "Ophthalmic Pathology", 2nd ed., ed. M. J. Hogan and L. E. Zimmerman, p. 322. Saunders, Philadelphia.
 ——— and ZIMMERMAN, L. E. (1961). *Amer. J. Ophthal.*, **51**, 394.
 KLINTWORTH, G. K. (1967). *Amer. J. Path.*, **50**, 371.
 KUGLER, J. H. (1967). *J. roy. micr. Soc.*, **86**, 285.
 LOWTHER, D. A., GREEN, N. M., and CHAPMAN, J. A. (1961). *J. biophys. biochem. Cytol.*, **10**, 373.
 MATSUMOTO, S. (1918). *J. exp. Zool.*, **26**, 545.
 ——— and ISHIMARU, H. (1922). *Acta Sch. med. Kioto*, **5**, 167.
 MAUMENEE, A. E. (1960). *Amer. J. Ophthal.*, **50**, 1114.
 MCTIGUE, J. W., and FINE, B. S. (1964). *Invest. Ophthal.*, **3**, 355.
 MELCHER, A. H. (1966). *J. dent. Res.*, **45**, 426.
 PALADE, G. E. (1958). In "Microsomal Particles and Protein Synthesis" [First Symposium, Biophysical Society], ed. R. B. Roberts, p. 36. Pergamon Press, London.

- PAUFIQUE, L., and BONNET, M. (1966). *Ann. Oculist. (Paris)*, **199**, 14.
- , ———, BIGONNET, M., DIDIER-LAURENT, A., and LAURENT, C. (1964). *Bull. Soc. Ophthal. Fr.*, p. 210.
- REIS, W. (1917). *Dtsch. med. Wschr.*, **43**, 575.
- SEITELBERGER, F., and NEMETZ, U. R. (1961). *v. Graefes Arch. Ophthal.*, **164**, 102.
- STOCKER, F. W., and HOLT, L. B. (1955). *A.M.A. Arch. Ophthal.*, **53**, 536.
- TENG, C. C. (1961). *Amer. J. Ophthal.*, **51**, 278.
- (1962). *Ibid.*, **54**, 969.
- VANCEA, P., and LĂZĂRESCU, D. (1958). *Ophthalmologica (Basel)*, **136**, 361.
- VERDI, G. P., and FILIPPONE, A. (1958). *Boll. Oculist.*, **37**, 410.
- VIRCHOW, H. (1910). In "Graefe-Saemisch, Handbuch der gesamten Augenheilkunde", 2nd ed., vol. 1, pt 1, chap. 2. Engelmann, Leipzig.
- WEIMAR, V. (1960). In "The Transparency of the Cornea", C.I.O.M.S. Symposium, ed. S. Duke-Elder and E. S. Perkins, p. 111. Blackwell, Oxford.