

Early Effects of Iodine Deficiency on Radial Glial Cells of the Hippocampus of the Rat Fetus

A Model of Neurological Cretinism

Juan Ramon Martínez-Galán,* Pablo Pedraza,† Maria Santacana,* Francisco Escobar del Rey,‡
Gabriella Morreale de Escobar,‡ and Antonio Ruiz-Marcos*

*Unidad de Neuroanatomía del Instituto Cajal, and †Unidad de Endocrinología Molecular del Instituto de Investigaciones Biomédicas, Consejo Superior de Investigaciones Científicas and Facultad de Medicina de la Universidad Autónoma de Madrid, 28002 Madrid, Spain

Abstract

The most severe brain damage associated with thyroid dysfunction during development is observed in neurological cretins from areas with marked iodine deficiency. The damage is irreversible by birth and related to maternal hypothyroxinemia before mid gestation. However, direct evidence of this etiopathogenic mechanism is lacking. Rats were fed diets with a very low iodine content (LID), or LID supplemented with KI. Other rats were fed the breeding diet with a normal iodine content plus a goitrogen, methimazole (MMI). The concentrations of L-thyroxine (T4) and 3,5,3'-triiodo-L-thyronine (T3) were determined in the brain of 21-d-old fetuses. The proportion of radial glial cell fibers expressing nestin and glial fibrillary acidic protein was determined in the CA1 region of the hippocampus. T4 and T3 were decreased in the brain of the LID and MMI fetuses, as compared to their respective controls. The number of immature glial cell fibers, expressing nestin, was not affected, but the proportion of mature glial cell fibers, expressing glial fibrillary acidic protein, was significantly decreased by both LID and MMI treatment of the dams.

These results show impaired maturation of cells involved in neuronal migration in the hippocampus, a region known to be affected in cretinism, at a stage of development equivalent to mid gestation in humans. The impairment is related to fetal cerebral thyroid hormone deficiency during a period of development when maternal thyroxinemia is believed to play an important role. (*J. Clin. Invest.* 1997; 99:2701–2709.)

Key words: brain • thyroxine • triiodothyronine • glial-fibrillary-acidic-protein • nestin

Introduction

Alterations of thyroid function during human development are known to produce extensive damage to the central nervous system (CNS)¹ (for reviews see references 1–4), including se-

vere mental retardation. The most severe alterations are not those encountered in untreated congenital hypothyroidism, but in the neurological cretins born in areas of marked nutritional iodine deficiency (5–8). When newborns with congenital hypothyroidism are treated with L-thyroxine (T4) soon after birth, severe mental retardation is avoided (9). On the contrary, in the case of iodine deficiency, the major CNS damage is already irreversible by birth and can only be prevented by correction of the maternal iodine deficiency early in pregnancy (10, 11). Neurological abnormalities (6–8, 12, 13) include hearing and speech defects (often resulting in deaf-mutism), mental deficiency (intellectual deficits, visuomotor integration deficits, release of primitive reflexes, autism, and vacuity), and motor deficits (proximal and truncal rigidity, flexion dystonia, spasticity, muscle wasting, and thalamic posturing). It has been concluded from the clinical findings (7) that the underlying anatomic lesions are likely to implicate the cochlea, cerebral cortex, association cortex, frontal lobe, amygdala, hippocampus, right hemisphere cortex, basal ganglia (putamen and globus pallidus), corticospinal tracts (including the premotor cortex), lower motor neurons, and severe cortico-striatal motor lesions. The clinical presentation covers a wide spectrum of different combinations of the above findings. Except for the mental retardation, these abnormalities are rarely found in congenital hypothyroidism, even when left untreated after birth.

It has been difficult to explain the greater severity and irreversibility of the CNS lesions observed in neurological cretinism, as compared to those observed in congenital hypothyroidism. Typical neurological cretins are not clinically hypothyroid (14) and have a potentially normal thyroid gland, capable of synthesizing adequate amounts of thyroid hormone when sufficient iodine is supplied. In contrast, the congenitally hypothyroid newborn is often athyrotic, or has a permanent defect of thyroid hormone synthesis, and is clinically hypothyroid if left untreated. It was previously believed that maternal thyroid hormones do not cross the placenta and play no role in fetal development (15, 16). The fact that early postnatal treatment of the congenitally hypothyroid newborn prevents hypothyroidism and major brain damage was considered proof that the human brain is not sensitive to thyroid hormone until after birth (16). As a consequence of these ideas, it was initially proposed that it would be the deficiency of iodine itself (10), not of thyroid hormone, which causes the early irreversible CNS damage of the neurological cretin.

Since then it has been shown, however, that T4 is present in the human extra embryonic cavities during the first trimester (17), when both the yolk sac epithelium and choroid plexus synthesize transthyretin, which could facilitate entry of T4 into the embryo and brain. Type II 5'-iodothyronine deiodinase, which generates 3,5,3'-triiodo-L-thyronine (T3) from T4 locally, has been detected in first trimester fetal brains (18). T3, bound to its nuclear receptor, is found in human fetal brains

Address correspondence to Prof. Antonio Ruiz-Marcos, Instituto Cajal, Dr Arce 37, 28002 Madrid, Spain. Phone: 34-1-585-4709; FAX: 34-1-585-4754.

Received for publication 30 December 1996 and accepted in revised form 14 March 1997.

1. *Abbreviations used in this paper:* CNS, central nervous system; E-21, day 21 of gestation; F-BW, fetal body weight; GFAP, glial fibrillary acidic protein; LID, low iodine diet; MMI, methyl-mercapto-imidazole; T3, 3,5,3'-triiodo-L-thyronine; T4, L-thyroxine.

J. Clin. Invest.

© The American Society for Clinical Investigation, Inc.

0021-9738/97/06/2701/09 \$2.00

Volume 99, Number 11, June 1997, 2701–2709

before onset of fetal thyroid function (19, 20), and maternal transfer of T4 continues until birth, representing 20–50% of normal cord blood T4 (21). Experimental work in the rat has shown that maternal thyroid hormones reach the fetus throughout gestation, and that maternal thyroxine (T4), but not triiodothyronine (T3) protects the brain of a congenitally hypothyroid fetus from T3 deficiency until birth (22).

Such findings would explain the good results obtained with prompt neonatal T4 treatment: the mothers are usually normal and their contribution to fetal T4 has been sufficient to avoid exposure of the developing brain of her hypothyroid fetus to a deficiency of T3 up to birth. On the contrary, women suffering from severe iodine deficiency cannot produce enough T4 for initial fetal development. Their fetuses are also unable to synthesize enough T4 because of the lack of iodine. Thus, throughout pregnancy, the fetal brain does not receive enough T4, which is the only source of cerebral T3 during fetal development (23). This would explain the greater severity of the CNS damage caused by iodine deficiency. Thus, the important role of maternal thyroid function (24, 25) has been accepted, especially by investigators familiar with endemias where neurological cretins are born: maternal, followed by fetal, hypothyroxinemia, is now considered the major causative factor of their early CNS lesions (2, 7, 11–13, 26–29).

Most of the previous evidence leading to this conclusion was retrospective and might be merely circumstantial. Direct prospective evidence of this etiopathogenic mechanism would be convenient. It would be more convincing if it were shown that hypothyroxinemia caused by iodine deficiency during pregnancy actually resulted in alterations of brain morphology, or function, during a period of brain development corresponding to the first half of pregnancy in women. Obtaining such experimental evidence has been elusive for years (24, 25), possibly because important phases of human fetal brain development occur after birth in the rat, when compensatory mechanisms mitigate T3 deficiency during the postnatal brain T3 surge despite the low iodine intake (30–32). For this reason it appeared important to study the brain of iodine-deficient fetuses, which is markedly T3 deficient, whereas the brain of the suckling pup is not.

We have used two experimental models, one involving the use of iodine-deficient diets (LID), resulting in low circulating maternal T4, normal T3, and high thyroid stimulating hormone (TSH) (30–32), as described for iodine-deficient women giving birth to neurological cretins (25). This diet results in low concentrations of T4 and T3 in the fetal tissues, including the brain (30–32), as the amount of iodine reaching the maternal and fetal thyroids is insufficient for T4 synthesis. The other model involves treatment of female rats with a goitrogen, 1-methyl-mercapto-imidazole-2-thiol (MMI), added to the standard breeding diet with a normal iodine content. The latter treatment results in low maternal circulating T4 and T3, high TSH, and low concentrations of T4 and T3 in fetal tissues, including the brain (22), because the goitrogen is inhibiting the synthesis of hormone both by the maternal and fetal thyroids. Comparison of results from both experimental models would clarify whether any developmental abnormalities found in the fetal brain are caused by the lack of iodine itself, by the lack of thyroid hormone, or by possible nutritional deficiencies of the LID other than that of iodine.

We have focused our attention on the morphology of the hippocampus, which is clearly implicated in neurological cre-

tinism, and is one of the structures developing early in human pregnancy. We have focused specifically on radial glial cells of the CA1 region, which are amenable to careful quantification. Moreover, radial glial cells of the hippocampal formation are known to be sensitive to neonatally induced hypothyroidism early during the postnatal period (33), and are likely candidates for the detection of possible effects of thyroid hormone deficiency in the fetal rat.

As will be seen, both iodine deficiency and goitrogen treatment resulted in a decreased concentration of T3 and T4 in the brain, and a decrease in the proportion of glial radial cell fibers in the CA1 region of the hippocampus of 21-d-old fetuses, which were immunoreactive to glial fibrillary acidic protein (GFAP). This is, to our knowledge, the first description of prenatal alterations caused by severe iodine deficiency in the rat, at a period of development comparable to that occurring in humans during the first half of pregnancy.

Methods

Animals. Wistar rats were used. They were housed in temperature-controlled animal quarters with automatic light and darkness cycles of 14 and 10 h, respectively. Two experimental models were used.

The first model (A) involved three groups of female rats, which were fed a LID, prepared as previously described, but with important modifications.² One group received this diet (LID-1 group), another was given the same diet supplemented with 0.005% KClO₄ to decrease the availability to the thyroid of the very small amounts of iodine contained in the LID, further increasing the iodine deficiency of the animals (LID-2 group) and the third group received LID supplemented with KI to ensure a normal iodine intake (LID+1 group, 10 µg I/d). The latter would be the control group for the LID-1 and LID-2 animals. All three groups drank distilled water. The degree of iodine deficiency increased from the LID+1 to the LID-1, and to the LID-2 groups. The female rats were fed the LID-1 and LID-2 diets for 3 mo before mating, by which time their circulating T4 was very low (LID-1, 5.5±0.8 ng/ml; LID-2, 1.2±0.3 ng/ml as compared to 56.3±6.9 ng/ml in LID+1 controls).

The second model (B) involves female rats fed the normal breeding diet supplemented with 0.02% MMI in the drinking water (MMI

2. To prevent contamination with small amounts of T4 and T3, the LID we used previously (30–32) does not contain any component of animal origin. It is nutritionally inadequate even when supplemented with KI, as evidenced by poorer growth of the pups born from mothers that have been fed this diet for months, as compared to the growth of pups born from mothers on the standard breeding diet (34). To avoid this possible confounding factor in this study, each kilogram of the basic LID diet (6 kg corn flour, 2.5 kg wheat gluten, 1 kg brewer's yeast, 0.15 kg NaCl, and 0.15 kg CaCO₃) was fortified with 18 g of the macro- and 0.25 g of the micro-mineral mixtures, and 1 g of the vitamin mixture described by Bieri et al. (35), KI excluded, and with 10 g of L-lysine, 1.9 g of L-tryptophane, 2.2 g of L-methionine, 3.4 g of L-threonine, and 2 g of L-choline, which are all deficient in the wheat gluten used as major protein source. In addition, 10 ml of corn oil was added to each kg of diet to ensure an adequate supply of essential fatty acids. With this supplemented LID diet (LID-1) pups grew normally when also supplemented with KI (LID+1, 10 µg I/d). However, the iodine content inevitably increased, even when all salts added were of purissimum proanalysis quality. For this reason, minute amounts of KClO₄ (50 mg/kg of diet) were added (LID-2) to decrease availability of this small amount of iodine to the maternal and fetal thyroids. These small amounts do not affect thyroid function when the iodine supply is normal (36).

group), or the same diet alone, the latter being the corresponding control group (C group). They were given MMI for 10 d before mating, since by this time their circulating T4 was as low (4.5 ± 1.3 ng/ml in MMI animals, compared to 49.3 ± 5.9 ng/ml in C rats) as that of the animals on the LID-1, and T3 was undetectable.

The day of mating to normal males was assessed by vaginal smears and microscopic visualization of spermatozoa, and designated as day 0 of pregnancy. Hysterectomy was performed on day 21 of gestation (E-21 stage). Four fetuses were taken at random from three mothers of each group for immunohistochemistry, and four littermates from each mother were used to determine the concentrations of T4 and T3 in the brain.

Radioimmunoassays. The degree of thyroid hormone deficiency attained by the animals exposed to the different experimental conditions was assessed measuring the levels of T4 and T3 in the maternal serum and fetal brain by specific radioimmunoassays after extensive extraction and purification as detailed elsewhere (37). Samples were obtained from fetuses of the same litters as those used for the morphological study. For this purpose, these fetuses were perfused with 0.1 M phosphate-buffered 0.9% NaCl, pH 7.4 (PBS), and their brains were dissected out and rapidly frozen on dry ice and stored at -40°C until the day the extraction procedure was started.

Immunohistochemistry. Embryos at E-21 were perfused through the left ventricle with 4% paraformaldehyde in 0.1 M phosphate buffer, pH 7.4. The brains were carefully dissected out, postfixed in fresh fixative at 4°C for 4 h, and soaked overnight in 30% sucrose for cryoprotection. 50- μm -thick coronal sections of the hippocampus were cut using a freezing microtome. To identify radial glial fibers, two different primary antisera were used: (a) the monoclonal antisera against the intermediate filament nestin, known as RAT-401 (38), commercially available from the Developmental Studies Hybridoma Bank (University of Iowa, Iowa City, IA); and (b) polyclonal antisera against GFAP from DAKOPATTS (Copenhagen, Denmark). This antibody was raised in rabbits.

Two immunohistochemical techniques were used: (a) a double immunofluorescence technique using the two antisera for the same tissue sections; and (b) the peroxidase antiperoxidase (PAP) method of Sternberger et al. (39).

Double immunofluorescent technique. Free-floating sections were first incubated in a 3% solution of normal horse serum in PBS for 30 min at room temperature and then incubated in rabbit anti-GFAP, at 1:100 dilution for 24 h at room temperature. After several washes in PBS the sections were incubated with fluorescein (FITC)-conjugated donkey anti-rabbit IgG (Jackson ImmunoResearch Labs., Inc., West Grove, PA), at 1:100 dilution in PBS, for 90 min, in the dark at room temperature. All the following stages were carried out in the dark at room temperature. After several washes in PBS, the sections were incubated with full-strength RAT-401, overnight at room temperature. Sections were rinsed in PBS followed by incubation in rhodamine (TRITC)-conjugated donkey anti-mouse (Jackson ImmunoResearch Labs., Inc.), at 1:100 dilution for 90 min at room temperature. After being washed in PBS, the sections were mounted onto glass slides with distilled water. Pictures were taken on a fluorescent Nikon (Melville, NY) microscope equipped with rhodamine filter and fluorescein filter. Control sections were processed with the omission of primary antisera. No staining was found in these sections.

PAP technique. Free-floating sections were first incubated in PBS containing 3% hydrogen peroxide (H_2O_2) for 30 min at room temperature. After washing three times in PBS for 5 min, sections were incubated in normal horse serum (Vector Laboratories, Inc., Burlingame, CA) for 30 min at room temperature, followed by incubation in one of the primary antisera: RAT-401, full-strength, or anti-GFAP at 1:100 dilution in PBS containing 0.01% Triton X-100. The sections were left overnight in an orbital shaker at room temperature. After washing three times in PBS for 5 min each, incubation in the second antibody (anti-mouse [Biomakor, Rehovot, Israel] for RAT-401 at 1:100 dilution in PBS, or goat anti-rabbit [Sigma Chemical Co., St. Louis, MO] for anti-GFAP at 1:50 dilution in PBS) was carried

Table I. Mean (\pm SEM) Body Weight of E-21 Fetuses

Group	LID+I*	LID-1 [†]	LID-2 [‡]	C [§]	MMI
Weight (g)	4.84 ± 0.09	4.90 ± 0.62	4.58 ± 0.32	5.03 ± 0.12	$3.62 \pm 0.13^{\#}$

*Iodine-supplemented controls; [†]iodine-deficient diets; [‡]standard diet; [§]standard diet and a goitrogen. [#]The difference between the C and MMI rats is statistically significant. Q test, $P < 0.001$.

out for 60 min at room temperature. After several washes in PBS, sections were incubated in peroxidase antiperoxidase complex (mouse for RAT-401 at 1:800 dilution in PBS and rabbit for anti-GFAP at 1:200 in PBS, both from Sigma Chemical Co.) for 90 min at room temperature. After washing in PBS, the bound peroxidase was reacted with 0.05% 3,3'-diaminobenzidine (from Sigma Chemical Co.) as chromogen in PBS containing 0.03% H_2O_2 . After rinsing in PBS, the sections were mounted on gelatin-coated slides and allowed to air-dry, dehydrated, and coverslipped. In all experiments, control sections were processed without the primary antibody. No staining was found in these control preparations.

Quantification of radial glial processes. Six 50- μm -thick coronal sections of the hippocampus were obtained for each fetus and submitted to immunohistochemistry with the RAT-401 and GFAP antibodies.

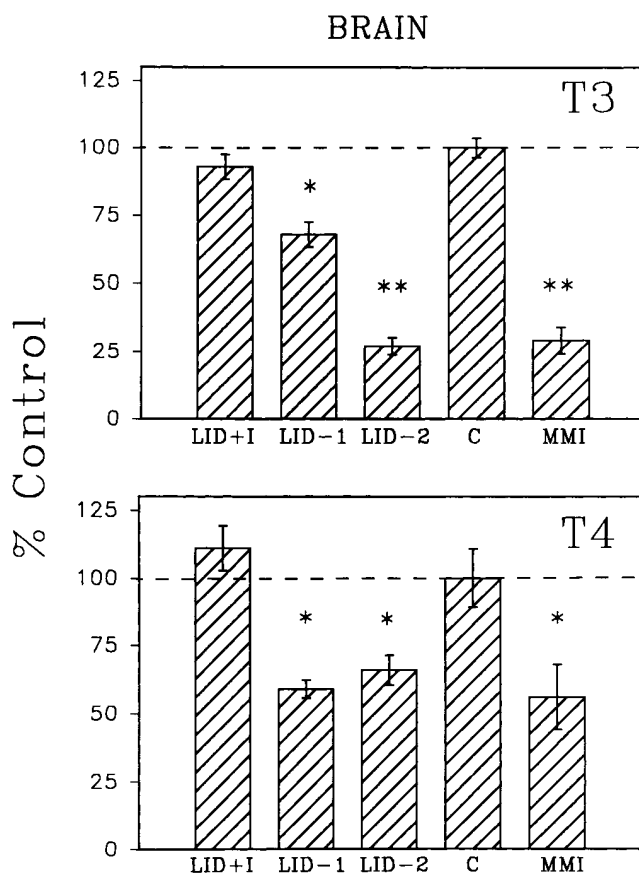


Figure 1. Mean values \pm SEM of the concentrations of T3 and T4 in the brain of E-21 fetuses are shown. The concentrations of T3 and T4 in the brain of fetuses from C dams were $1,242 \pm 46$ and $1,505 \pm 163$ ng/g, respectively. *The difference of the mean of treated animals with respect to controls is significant with $P < 0.05$. **These differences are significant with $P < 0.01$. For meaning of other abbreviations, see Table I.

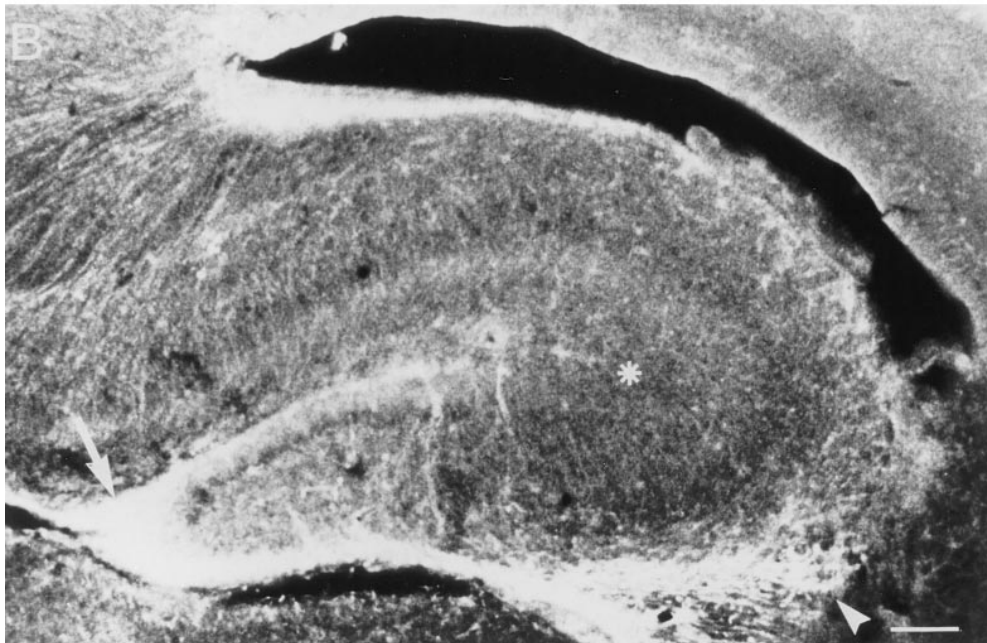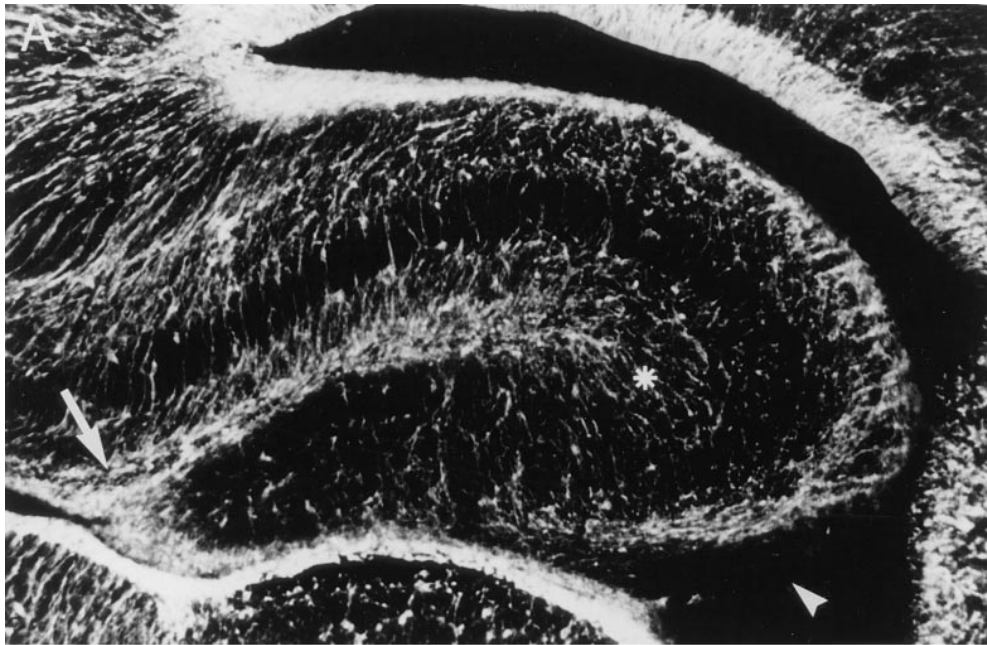


Figure 2. Low magnification microphotographs of double immunofluorescent labeling of 50- μm -thick sections of E-21 control hippocampal formation with RAT-401 (A) and GFAP (B). TRITC anti-mouse and FITC anti-rabbit were used, respectively, in order to identify the corresponding glial fibers. The asterisk shows some of the fibers immunoreactive mostly to RAT-401. The arrowhead marks fibers immunoreactive mostly to GFAP. The arrow points to fibers clearly immunoreactive to both. The horizontal bar represents 100 μm .

ies, as described above. These coronal sections were viewed at low magnification ($\times 63$) in order to exclude from the study those that appeared technically inadequate for later counting of glial fibers. At this low magnification it is not possible to assess fiber density, and this selection was considered adequate to avoid possible bias introduced by the observer. Actual fiber counting was performed on two to three sections per fetus.

The density of radial glia was determined by counting the number of intersections of immunostained fibers with a horizontally oriented 100- μm -wide bar (40). Initially this bar was placed on the dorsal, central, and ventral parts of the CA1 region, parallel to the supragranular glial band, but no statistically significant differences were found between the three different parts. For the statistical evaluation of the results, there were 24–30 values per experimental group.

Statistical analysis. The statistical significance among the mean values of body weight, levels of T3 and T4, and the number of immu-

noreactive processes to GFAP and RAT-401, corresponding to the different experimental conditions studied, was assessed using one-way analysis of variance, followed by the Q test for individual comparisons.

Results

Table I shows the body weight of the fetuses (F-BW) from the different groups of dams at E-21. As may be seen, the F-BWs of the LID-1 and LID-2 dams were not affected, as compared to either the LID+I or C fetuses, whereas those from the MMI dams were smaller.

Fig. 1 shows the concentrations of both T4 and T3 in the brain of the E-21 fetuses. As may be seen, the concentrations of both T4 and T3 were reduced in the brain of LID-1, LID-2, and

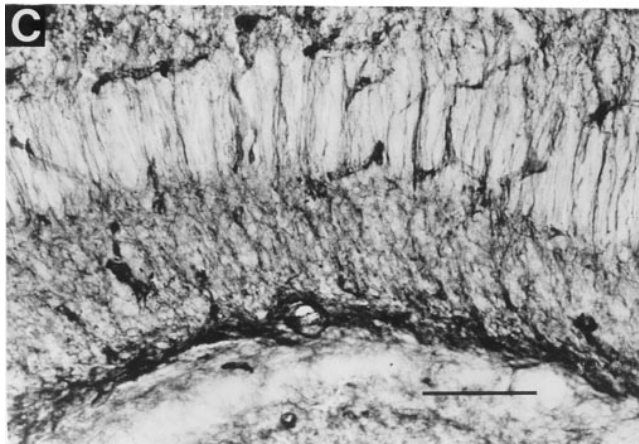
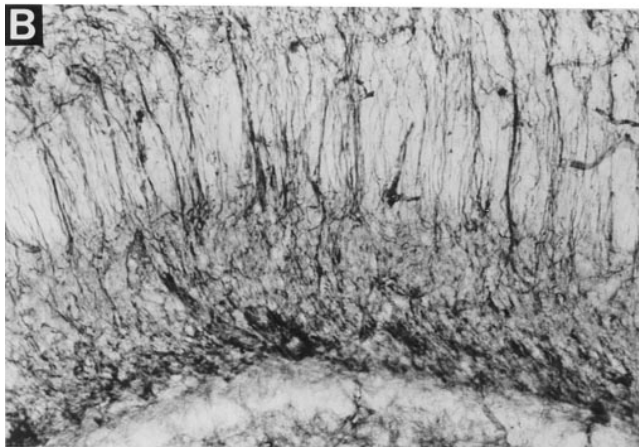
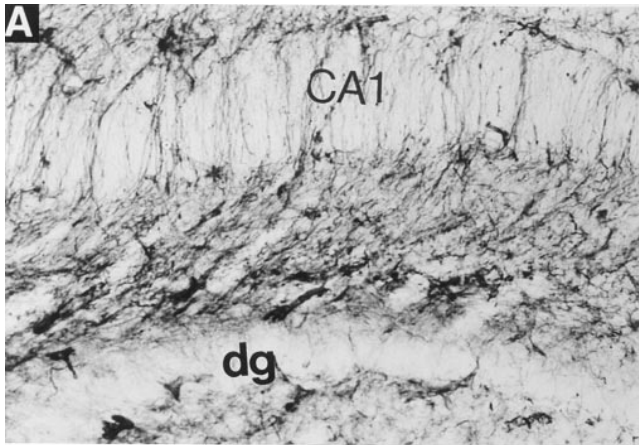


Figure 3. Microphotographs of 50- μ m-thick sections of the CA1 region of the hippocampus of normal (A), LID-1 (B), and MMI (C) fetuses, showing the radial glia immunoreactive to RAT-401. The horizontal bar represents 100 μ m.

MMI fetuses as compared to their respective LID+I and C controls. The concentration of T3 was less severely affected in fetuses from the LID-1 dams compared with those from the LID-2 dams, in agreement with the lower iodine intake of the latter group. The concentration of T3 in the fetal brain from LID-2 dams was comparable to that from dams treated with MMI.

Fig. 2 shows a panoramic view of the hippocampal formation of normal (C) E-21 rat fetuses in sections doubly labeled

with RAT-401 (Fig. 2 A) and with anti-GFAP (Fig. 2 B). There are regions of the hippocampal formation in which there are glial cells expressing mainly nestin (*asterisk*), or GFAP (*arrowhead*), or clearly expressing both nestin and GFAP simultaneously (*arrow*). Inspection of the double labeling in the CA1 region at a magnification ~ 10 times that used for Fig. 2, showed that many of the radial glial processes were clearly doubly immunoreactive to the RAT-401 and GFAP antisera. Some other fibers appeared as immunoreactive mostly to RAT-401 alone. In this area, we did not observe fibers reacting clearly only to GFAP.

Figs. 3 and 4 illustrate the presence of radial glial fibers immunolabeled with RAT-401 or anti-GFAP in the CA1 region

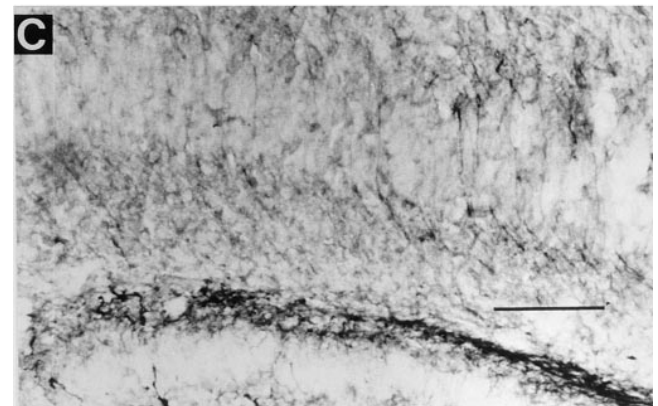
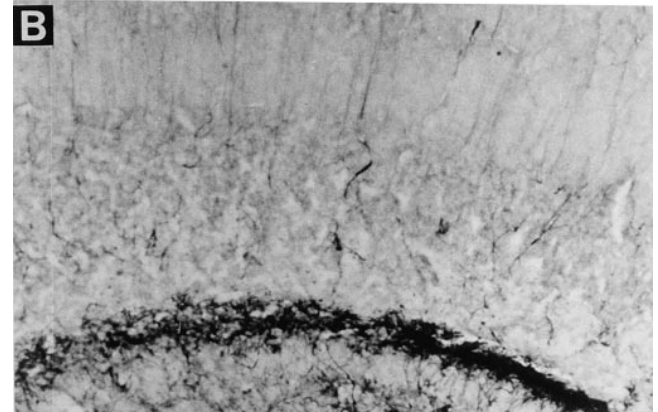
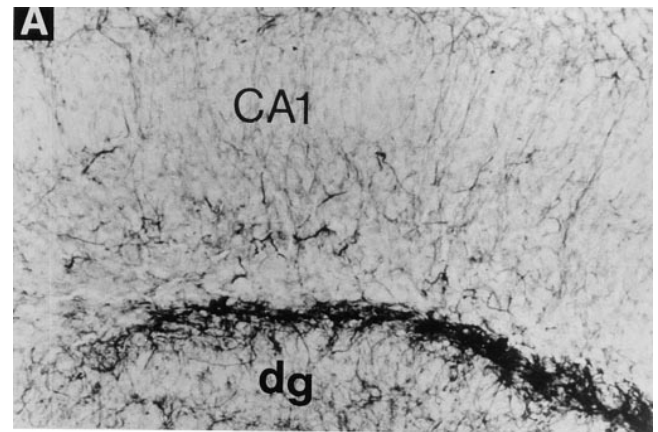


Figure 4. Comparable to Fig. 3, but showing radial glia immunoreactive to GFAP.

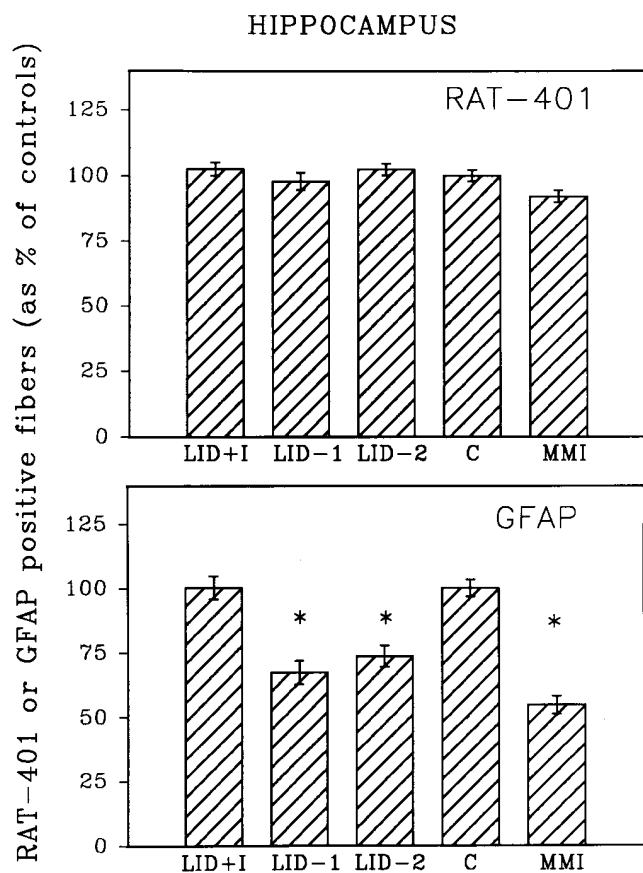


Figure 5. The number of intersections per 100 μm of radial glial fibers immunoreactive to RAT-401 or anti-GFAP, in the CA1 region of the hippocampus of E-21 fetuses, was measured for the different experimental groups. The results are expressed as a percentage of the mean values found in fetuses from C dams. These values were 19.01 ± 0.41 intersections per 100 μm for RAT-401 and 8.69 ± 0.29 intersections per 100 μm for anti-GFAP. *The difference of mean value is significant with respect to control with $P < 0.001$. For meaning of other abbreviations, see Table I.

of the hippocampus from C, LID-1, and MMI fetuses where counting of fiber density was performed.

Fig. 5 (top) shows the densities of radial glial fibers, as a percentage of control values, identified with RAT-401. As may be observed, the experimental conditions resulting in decreased cerebral T4 and T3 concentrations had no effect, as compared to C and LID+I controls. However, when the radial glial fibers were identified by GFAP, a highly significant effect of treatment was found, as illustrated in Fig. 5 (bottom). The experimental conditions which resulted in decreased cerebral thyroid hormone concentrations also resulted in a significant decrease of the density of the radial glia processes immunoreactive to GFAP.

Discussion

The experimental models: similarities and differences. With the fortified LID² used for this study, no differences were found in the BW of the fetuses, as compared to those of LID+I or C dams on the normal breeding diet. This indicates that the forti-

fied LID was nutritionally adequate and that any effects on the fetal brain would not be caused by a malnutrition other than that of a single component, namely iodine. This was confirmed by the normal postnatal growth of the pups born from other dams receiving the fortified LID diet (36).

On the contrary, the BW of fetuses from the MMI-treated dams was lower than that of C or LID+I treated animals. This decrease is likely a result of the marked degree of hypothyroidism of the MMI-treated mothers before conception and during gestation, and is similar to the decrease in BW of fetuses from rats thyroidectomized before mating (37, 41). The present MMI-treated dams had very low circulating T4, and undetectable T3 when mated, comparable to those of thyroidectomized dams (37). On the contrary, although circulating T4 in LID treated rats is equally low, T3 is normal during most of pregnancy (30–32), avoiding overt “clinical” hypothyroidism of the dams, as reported also for pregnant women from areas with severe iodine deficiency (14, 25).

Another difference between the animals on LID and on MMI is the iodine content of the diet, markedly deficient in the former, and normal in the MMI-treated animals, fed the standard breeding diet. Thus, the similarity of the changes found in the hippocampus of the fetuses from LID- and MMI-treated animals show that it is highly unlikely that the effects of LID are the result of a lack of the trace element iodine itself (10). On the contrary, our results clearly relate the observed changes to the deficiency of T4 and T3 in the brain, similar in the LID- and MMI-treated fetuses despite the difference in iodine availability.

Studies have been carried out previously by others to detect possible morphological changes in the progeny of dams with marked iodine deficiency. In adult progeny of rats fed a diet prepared with components from a severely iodine-deficient area of China, Chen et al. (42) show that the number of dendritic spines on the shaft of pyramidal neurons of the cerebral cortex was reduced as compared to that of progeny from rats fed the same diet, but supplemented with iodine. However, the parameter they measured is not only sensitive to hypothyroidism of neonatal onset (43), but also to adult onset hypothyroidism (44), and the alterations were not necessarily because of early brain damage. Permanent audiogenic seizure susceptibility was shown in adult progeny of severely iodine-deficient rats (45), but the timing of the initial damage was not defined. Iodine-deficient fetuses of ewes and newborn marmosets have been studied extensively, and the alterations in their brain morphology have been reported (46–48). Both these species are more mature at birth than humans: the fetal lambs and newborn marmosets were studied near term, at a period of CNS development which would be postnatal in humans. Early lesions corresponding to the first trimesters of pregnancy in women, and likely to be influenced mostly by the maternal hypothyroxinemia, were not reported.

In the present model we have confined our observations to the fetal stage of rat development for two main reasons. On one hand, the iodine available to the lactating pup from the LID mothers is increased somewhat as compared to that available to the fetus, and cerebral T3 becomes normal during the important phase of postnatal brain development (31, 32). This may well prevent the many CNS alterations (1–4) observed in thyroidectomized pups, or pups on goitrogens, treatments that result in marked cerebral T3 deficiency throughout this period of brain maturation. On the other hand, postnatal brain devel-

opment in the rat would correspond to events occurring during the second half of pregnancy in humans, whereas the fetus at term would correspond to the first half, when irreversible CNS damage occurs in cretinism (10, 11).

Early effects of iodine deficiency in the rat hippocampus. The hippocampus was chosen for this study because its development starts before mid gestation in humans, and is clearly implicated in neurological cretinism. Neurogenesis is completed in the hippocampal CA1 region of the rat fetus by E-20 (49). Comparison with data obtained in the Rhesus monkey has led to the proposal that in the human fetus this occurs around the 16–17th wk of pregnancy (50, 51), namely before mid gestation and before active secretion of thyroid hormones by the fetal gland (2, 52). For these reasons the CA1 region was a likely candidate for the detection of developmental abnormalities that might be present during fetal life in the rat. Postmitotic neurons do not express either RAT-401 or GFAP, which are specific for glial cells. Quantification of radial glial cell fibers is, moreover, greatly facilitated in the CA1 region by the fact that the somata of pyramidal cells of the hippocampus located there separate the radial glial processes from each other.

The radial glia express mainly nestin during their immature stage of differentiation, and GFAP with maturation. Experiments both in vivo (53–55) and in vitro (56) have shown that morphological transformation of radial glial cells of the murine cortex into astrocytes is accompanied by a loss of immunoreactivity to RC1, RC2, RAT-401, and vimentin, and an increase in the expression of GFAP. We describe here that at E-21 there are two types of radial glia in the rat hippocampal formation, namely those only expressing nestin clearly and those expressing clearly both nestin and GFAP. We have not observed cells expressing clearly only GFAP in the CA1 region, although they were observed in the fimbria, indicating that at E-21 glial cells in different regions of the hippocampal formation are at different stages of maturation.

The total number of glial cell fibers of the CA1 layer expressing nestin was unaffected by the decreased concentrations of thyroid hormones in the fetal brain, irrespective of the experimental model used, namely dams fed LID or MMI. In contrast, the proportion of glial cell fibers expressing GFAP was affected significantly, and to a similar degree, both by LID-1 and LID-2, or by MMI treatment of the dams. These results show that the deficiency of thyroid hormones in the fetal brain delays maturation of the glial cells of the CA1 region, which may act as a scaffold for the migration of the postmitotic neurons of the hippocampus.

Our results are in conceptual agreement with those obtained postnatally in rat pups from dams receiving another goitrogen, propyl-thiouracil (PTU); Ramie and Rabie (33) did not observe any difference in the number of processes in the hippocampal formation that expressed vimentin in the hypothyroid as compared to the control pups, whereas they did observe a decrease in the expression of GFAP in glial processes from 0 to 15 d of postnatal age, with a further decrease in the number of astrocytes in the hilus at 35 d of postnatal age. In rat pups that were made hyperthyroid postnatally, the inverse occurred, namely an increase in the density of GFAP immunoreactive astrocytes and a premature disappearance of the vimentin reactive glia (57). Such results also indicate that a deficiency of thyroid hormone delays the development of the hippocampus, whereas an excess accelerates the process.

Although not shown here, it is possible that the delay in maturation of the radial glial cells of the hippocampus described here is accompanied by an alteration of their function, such as an abnormal timing and/or a final outcome of the migration process of neurons from the ventricular to the CA1 region, a point that is being studied currently. With respect to this, it is interesting that McCall et al. (58) have created recently GFAP-null mice using gene targeting in embryonic stem cells. They found astrocytes in the CNS of the mice, but with a severely reduced number of intermediate filaments. These alterations were accompanied by a change in neuronal physiology, namely in long-term potentiation in the CA1 region of the hippocampus, suggesting that GFAP is important for astrocyte–neuronal interactions and that astrocyte processes may play a role in modulating synaptic efficacy in the murine CNS.

Conclusion. For years it has been generally assumed that the rat brain only becomes sensitive to thyroid hormones during a postnatal developmental period, and not during fetal life (16), despite increasing evidence that thyroid hormone receptors are expressed in different regions of the fetal brain, and occupied by T3 (14, 59–62). Moreover, some prenatal effects have been described in the brain of fetuses from dams on goitrogens: Smith (63) found that the number of β -adrenergic receptors decreased to 60% of control values in the brain of E-21 fetuses from PTU-treated mothers. The decrease was avoided by treating the mothers with T4. More recently, Vega-Nuñez et al. (64) have reported that on E-16 there is a 50% reduction in the levels of 16S mRNA (a mitochondrial gene) in the brain of fetuses from MMI-treated rats. This study shows another prenatal effect of goitrogen treatment on the maturation of the CA1 region of the hippocampus. This is, to our knowledge, the first report of a prenatal effect on the CNS of iodine deficiency alone and, specifically, an effect in the hippocampus which in humans is developing before mid gestation.

Thus, these results are the first experimental evidence that iodine deficiency alone results in early developmental defects in the brain. The decreased maturation of the radial glial cells of the CA1 region of the hippocampus is related to the deficiency of thyroid hormones in the fetal brain, mainly caused by the maternal hypothyroxinemia, and not to a deficiency of the trace element itself. Although these results do not show a causal link between reduced GFAP in the CA1 region of the fetal hippocampus and some of the clinical manifestations of neurological cretinism caused by iodine deficiency, they open the possibility for further studies related to this problem in a rat experimental model.

Acknowledgments

We are grateful to Ms. S. Duran and Ms. M.J. Presas (both of the Unidad de Endocrinología Molecular) for their technical assistance in the hormonal determinations and to Mrs. M^a Ester Fernandez de Molina (of the Unidad de Neuroanatomía) for her help with the typing of the manuscript.

This investigation has been supported by grants to Dr. A. Ruiz-Marcos from the “Fondo para Investigaciones Sanitarias de la Seguridad Social” (grant 93/0160) and from the “Comisión Interministerial de Ciencia y Tecnología” (grant PM95-0011) and a grant to Dr. G. Morreale de Escobar from “Fondo para Investigaciones Sanitarias de la Seguridad Social” (grant 92/0888).

References

1. Morreale de Escobar, G., A. Ruiz-Marcos, and F. Escobar del Rey. 1983. Thyroid hormones and the developing brain. *In* Congenital Hypothyroidism. J.H. Dussault and P. Walker, editors. Marcel Dekker, Inc., New York. 85–126.
2. Morreale de Escobar, G., M.J. Obregón, R.M. Calvo, and F. Escobar del Rey. 1993. The effects of iodine deficiency on thyroid hormone metabolism and brain in fetal rats: the role of the maternal transfer-thyroxine. *Am. J. Clin. Nutr.* 57:280S–285S.
3. Dussault, J.R., and J. Ruel. 1987. Thyroid hormones and brain development. *Annu. Rev. Physiol.* 49:321–334.
4. Bernal, J., and J. Nunez. 1995. Thyroid hormones and brain development. *Eur. J. Endocrinol.* 133:390–398.
5. Hetzel, B.S. 1983. Iodine deficiency disorders and their eradication. *Lancet.* 2:1126–1129.
6. DeLong, G.R. 1989. Observations on the neurology of endemic cretinism. *In* Iodine and the Brain. G.R. DeLong, J. Robbins, and P.G. Condliffe, editors. Plenum Publishing Corp., New York. 231–238.
7. DeLong, G.R. 1993. The effects of nutrition on human brain development. *Am. J. Clin. Nutr.* 57:290S–295S.
8. DeLong, G.R., M. Tai, C. Xue-wei, J. Xin-Min, D. Zhi-hong, M.A. Rake-man, Z. Ming-li, and R. Heinz. 1994. The neuromotor deficit in endemic cretinism. *In* The Damaged Brain of Iodine Deficiency. J.B. Stanbury, editor. Cognizant Communication Corp., Elmsford, NY. 9–14.
9. Illig, R., R.H. Largo, Q. Qin, T. Torresani, P. Rochiccioli, and A. Larson. 1987. Mental development in congenital hypothyroidism after neonatal screening. *Arch. Dis. Child.* 62:1050–1055.
10. Pharoah, P.O.D., I.H. Buttfield, and B.S. Hetzel. 1971. Neurological damage to the fetus resulting from severe iodine deficiency during pregnancy. *Lancet.* 1:308–310.
11. Xue-Yi, C., J. Xin-Min, D. Zhi-Jong, M.A. Rakeman, Z. Ming-Li, K. O'Donnell, M. Tai, K. Amette, N. DeLong, and G.R. DeLong. 1994. Timing of vulnerability of the brain to iodine deficiency in endemic cretinism. *N. Engl. J. Med.* 331:1739–1744.
12. Halpern, J.P., S.C. Boyages, G. Maberly, J.K. Collins, C.L. Eastman, and J.G.L. Morris. 1991. The neurology of endemic cretinism: a study of two endemias. *Brain.* 114:825–841.
13. Boyages, S.C. 1994. The damaged brain of iodine deficiency: evidence for a continuum of effect on the population at risk. *In* The Damaged Brain of Iodine Deficiency. J.B. Stanbury, editor. Cognizant Communication Corp., Elmsford, NY. 251–258.
14. Pharoah, P.O.D., N.F. Lawton, S.M. Ellis, E.S. Williams, and R.P. Ekins. 1973. The role of triiodothyronine in the maintenance of euthyroidism in endemic goitre. *Clin. Endocrinol.* 2:193–199.
15. Fisher, D.A., and A.K. Klein. 1981. Thyroid development and disorders of thyroid function in newborn. *N. Engl. J. Med.* 304:702–712.
16. Fisher, D.A., and D.A. Polk. 1989. Maturation of thyroid hormone actions. *In* Research in Congenital Hypothyroidism. F. Delange, D.A. Fisher, and D. Glinoo, editors. Plenum Publishing Corp., New York. 61–78.
17. Contempré, B., E. Jauniaux, R. Calvo, D. Jurkovic, S. Campbell, and G. Morreale de Escobar. 1993. Detection of thyroid hormone in human embryonic cavities during the first trimester of pregnancy. *J. Clin. Endocrinol. Metab.* 77:1719–1722.
18. Karmarkar, M.G., D. Prabakaran, and M.M. Godbole. 1993. 5'-Mono-deiodinase activity in developing human cerebral cortex. *Am. J. Clin. Nutr.* 57:291S–294S.
19. Bernal, J., and F. Pekonen. 1984. Ontogenesis of the nuclear 3,5,3'-triiodothyronine receptor in the human fetal brain. *Endocrinology.* 114:677–679.
20. Ferreira, B., J. Bernal, C.G. Goodyer, and C.L. Branchard. 1988. Estimation of nuclear thyroid hormone receptor saturation in human fetal brain and lung during early gestation. *J. Clin. Endocrinol. Metab.* 67:853–856.
21. Vulsma, T., M.H. Gons, and J. Vijlder. 1989. Maternal-fetal transfer of thyroxine in congenital hypothyroidism due to a total organification defect or thyroid agenesis. *N. Engl. J. Med.* 321:13–16.
22. Calvo, R.M., M.J. Obregón, C. Ruiz de Oña, F. Escobar del Rey, and G. Morreale de Escobar. 1990. Congenital hypothyroidism, as studied in rats. Crucial role of maternal thyroxine but not of 3,5,3'-triiodothyronine in the protection of the fetal brain. *J. Clin. Invest.* 86:889–899.
23. Ruiz de Oña, C., M.J. Obregón, F. Escobar del Rey, and G. Morreale de Escobar. 1988. Development changes in rat brain 5'-deiodinase and thyroid hormones during the fetal period: the effects of fetal hypothyroidism and maternal thyroid hormones. *Pediatr. Res.* 24:588–594.
24. Choufoer, M., M. van Rhijn, and A. Querido. 1965. Endemic goiter in Western New Guinea. II. Clinical picture, incidence and pathogenesis of endemic cretinism. *J. Clin. Endocrinol. Metab.* 25:385–402.
25. Hetzel, B.S., and N.J. Potter. 1983. Iodine deficiency and the role of thyroid hormones in brain development. *In* Neurobiology of the Trace Elements. I.E. Dreosti and R.M. Smith, editors. Humana Press Inc., Totawa, NJ. 83–133.
26. Pharoah, P.O.D., S.M. Ellis, R.P. Ekins, and E.S. Williams. 1976. Maternal thyroid function, iodine deficiency and fetal development. *Clin. Endocrinol.* 5:159–166.
27. Morreale de Escobar, G., M.J. Obregón, R. Calvo, and F. Escobar del Rey. 1994. Hormone nurturing of the developing brain: the rat model. *In* The Damaged Brain in Iodine Deficiency. J.B. Stanbury, editor. Cognizant Communication Corp., Elmsford, NY. 103–122.
28. Hetzel, B.S. 1994. Historical development of concepts of brain-thyroid relationships. *In* The Damaged Brain of Iodine Deficiency. J.B. Stanbury, editor. Cognizant Communication Corp., Elmsford, NY. 1–8.
29. Boyages, S.C., and J.P. Halpern. 1992. Endemic cretinism: toward a unifying hypothesis. *Thyroid.* 3:59–69.
30. Escobar del Rey, F., R.M. Pastor, J. Mallol, and G. Morreale de Escobar. 1986. Effects of maternal iodine deficiency on the L-thyroxine and 3,5,3'-triiodo-L-thyroxine contents of rat embryonic tissues before and after onset of fetal thyroid function. *Endocrinology.* 118:1259–1265.
31. Escobar del Rey, F., J. Mallol, R.M. Pastor, and G. Morreale de Escobar. 1987. Effects of maternal iodine deficiency on thyroid hormone economy of lactating dams and pups: maintenance of normal cerebral 3,5,3'-triiodo-L-thyroxine concentrations in pups during major phases of brain development. *Endocrinology.* 121:803–811.
32. Obregón, M.J., C. Ruiz de Oña, R.M. Calvo, F. Escobar del Rey, and G. Morreale de Escobar. 1991. Outer ring iodothyronine deiodinases and thyroid hormone economy: responses to iodine deficiency in the rat fetus and neonate. *Endocrinology.* 129:2663–2673.
33. Ramie, A., and A. Rabie. 1988. Effect of thyroid deficiency on the development of glia in the hippocampal formation of the rat: an immunocytochemical study. *Glia.* 1:337–345.
34. Morreale de Escobar, G., C. Ruiz de Oña, M.J. Obregón, and F. Escobar del Rey. 1989. Models of fetal iodine deficiency. *In* Iodine and The Brain. G.R. DeLong, J. Robbins, and P.G. Condliffe, editors. Plenum Publishing Corp., New York. 187–201.
35. Bieri, J.G., G.S. Stoewsand, G.M. Briggs, R.W. Philips, J.C. Woodward, and J.J. Knappa. 1977. Report of the American Institute of Nutrition ad hoc committee on standards for nutritional studies. *J. Nutr.* 7:1340–1351.
36. Morreale de Escobar, G., P.E. Pedraza, F. Escobar del Rey, and M.J. Obregón. 1996. Thyroidal and extrathyroidal adaptation to graded degrees of iodine deficiency: An experimental model for the study of neurological iodine deficiency disorders (IDD). *In* Thyroid and Trace Elements. L.E. Braverman, J. Köhrl, O. Eber, and W. Langsteiger, editors. Blackwell Wissenschafts-Verlag, Ges. m.b.H., Vienna. 113–126.
37. Morreale de Escobar, G., R.M. Pastor, M.J. Obregón, and F. Escobar del Rey. 1985. Effects of maternal hypothyroidism on the weight and thyroid hormone content of rat embryonic tissues. *Endocrinology.* 117:1890–1901.
38. Hockfield, S., and R.D.G. McKay. 1985. Identification of major cell classes in the developing mammalian nervous system. *J. Neurosci.* 5:3310–3328.
39. Sternberger, L.A., P.H. Hardy, J.J. Cuculis, and H.G. Meyer. 1970. The unlabeled antibody-enzyme method of immunohistochemistry. Preparation and properties of soluble antigen-antibody complex (horseradish peroxidase-anti-horseradish peroxidase) and its use in the identification of spirochetes. *J. Histochem. Cytochem.* 18:315–333.
40. Miller, M.W., and S. Robertson. 1993. Prenatal exposure to ethanol alters the postnatal development and transformation of radial glia to astrocytes in the cortex. *J. Comp. Neurol.* 337:253–266.
41. Bonet, B., and E. Herrera. 1988. Different responses to maternal hypothyroidism during the first and second half of gestation in the rat. *Endocrinology.* 122:450–455.
42. Chen, Z.P., X.X. Chen, L. Dong, X. Hu, W.D. Zhao, D. Wang, and T. Ma. 1986. The iodine deficient rat. *In* Iodine Deficiency Diseases and Congenital Hypothyroidism. G. Medeiros-Neto, R.M.B. Maciel, and A. Halpern, editors. Ache Press, Sao Paulo. 46–51.
43. Ruiz-Marcos, A., F. Sánchez Toscano, F. Escobar del Rey, and G. Morreale de Escobar. 1979. Severe hypothyroidism and the maturation of the rat cerebral cortex. *Brain Res.* 162:315–329.
44. Ruiz-Marcos, A., F. Sánchez Toscano, F. Escobar del Rey, and G. Morreale de Escobar. 1980. Reversible morphological alterations of cortical neurons in juvenile and adult-onset hypothyroidism in the rat. *Brain Res.* 185:91–102.
45. van Middlesworth, L. 1977. Audiogenic seizures in rats after severe prenatal and perinatal iodine depletion. *Endocrinology.* 100:242–245.
46. Potter, B.J., M.T. Mano, G.B. Belling, G.H. McIntosh, C. Hua, B.G. Cragg, J. Marshall, M.L. Wellby, and B.S. Hetzel. 1982. Retarded fetal brain development resulting from severe dietary iodine deficiency in sheep. *Neuropathol. Appl. Neurobiol.* 8:303–313.
47. Mano, M.T., B.J. Potter, G.B. Belling, J. Chavadej, and B.S. Hetzel. 1987. Fetal brain development in response to iodine deficiency in a primate model (Callythrix Jacchus Jacchus). *J. Neurol. Sci.* 79:287–300.
48. Hetzel, B.S. 1994. Hormone nurturing of the developing brain: sheep and marmoset models. *In* The Damaged Brain of Iodine Deficiency. J.B. Stanbury, editor. Cognizant Communication Corp. Elmsford, NY. 123–130.
49. Altman, J., and S. Bayer. 1990. Prolonged sojourn of developing pyramidal cells in the intermediate zone of the hippocampus and their settling in the stratum pyramidale. *J. Comp. Neurol.* 301:343–364.
50. Rakic, P., and R.S. Nowakowski. 1981. The time of origin of neurons in the hippocampal region of the rhesus monkey. *J. Comp. Neurol.* 196:99–128.
51. Janas, M.S., R.S. Nowakowski, and K. Mollgard. 1991. Glial cell differ-

- entiation in neuron-free and neuron-rich regions. II. Early appearance of S-100 protein positive astrocytes in human fetal hippocampus. *Anat. Embryol.* 184: 559–569.
52. Morreale de Escobar, G., and F. Escobar del Rey. 1990. Thyroid physiology in utero and neonatally. In *Iodine Prophylaxis Following Nuclear Accidents*. E. Rubery and E. Smales, editors. Pergamon Press Ltd., Oxford. 3–32.
53. Caviness, V.S., Jr., J. Misson, T. Takahashi, and J. Crandall. 1989. Astroglial transformations in the developing murine cerebral wall. *Soc. Neurosci. Abstr.* 15:328a.
54. Stichel, C.C., C.M. Müller, and K. Zilles. 1991. Distribution of glial fibrillary acidic protein and vimentin immunoreactivity during rat visual cortex development. *J. Neurocytol.* 20:97–108.
55. Cameron, R.S., and P. Rakic. 1991. Glial cell lineage in the cerebral cortex: a review and synthesis. *Glia.* 4:124–137.
56. Culican, S.M., N.L. Baumrind, M. Yamamoto, and A.L. Pearlman. 1990. Cortical radial glia: identification in tissue culture and evidence for their transformation to astrocytes. *J. Neurosci.* 10:648–692.
57. Gould, E., M. Frankfurt, A. Westlind-Danielsson, and B.S. McEwen. 1990. Developing forebrain astrocytes are sensitive to thyroid hormone. *Glia.* 3: 283–292.
58. McCall, M.A., R.G. Gregg, M. Behringer, C.L. Delaney, E.J. Galbreath, C.L. Zhang, R.A. Pierce, S.Y. Chiu, and A. Messing. 1996. Targeted deletion in astrocyte intermediate filament (*Gfap*) alters neuronal physiology. *Proc. Natl. Acad. Sci. USA.* 96:6361–6366.
59. Pérez-Castillo, A., J. Bernal, B. Ferreiro, and T. Pans. 1985. The early ontogenesis of thyroid hormone receptor in the rat fetus. *Endocrinology.* 117: 2457–2461.
60. Mellström, B., J.R. Naranjo, A. Santos, A.M. González, and J. Bernal. 1991. Independent expression of the α and β c-erbA genes in developing rat brain. *Mol. Endocrinol.* 5:1339–1350.
61. Bradley, D.J., H.C. Towle, and W.S. Young. 1992. Spatial and temporal expression of α - and β -thyroid hormone receptor mRNAs, including the β_2 -subtype, in the developing mammalian nervous system. *J. Neurosci.* 12:2288–2302.
62. Bradley, D.J., H.C. Towle, and W.S. Young. 1994. α and β thyroid hormone receptor (TR) gene expression during auditory neurogenesis: evidence for TR isoform-specific transcriptional regulation in vivo. *Proc. Natl. Acad. Sci. USA.* 91:439–443.
63. Smith, R.M. 1981. Thyroid hormones and brain development. In *Fetal Brain Disorders, Recent Approaches to the Problem of Mental Deficiency*. B.S. Hetzel and R.M. Smith, editors. Elsevier Science B.V., Amsterdam, The Netherlands. 149–185.
64. Vega-Núñez, E., A. Menéndez-Hurtado, R. Garesse, A. Santos, and A. Pérez-Castillo. 1995. Thyroid hormone regulated brain mitochondrial genes revealed by differential cDNA cloning. *J. Clin. Invest.* 96:893–899.