

High Prevalence of Thymic Tissue in Adults with Human Immunodeficiency Virus-1 Infection

Joseph M. McCune,* Rick Loftus,* Diane K. Schmidt,* Pamela Carroll,* Devon Webster,* Lisa B. Swor-Yim,* Isaac R. Francis,† Barry H. Gross,‡ and Robert M. Grant*

*The Gladstone Institute of Virology and Immunology, University of California, San Francisco, San Francisco, California 94141-9100; and †Department of Radiology, University of Michigan, Ann Arbor, Michigan 48109

Abstract

The thymus in adults infected with the HIV-1 is generally thought to be inactive, both because of age-related involution and viral destruction. We have revisited the question of thymic function in adults, using chest-computed tomography (CT) to measure thymic tissue in HIV-1-seropositive ($n = 99$) or HIV-1-seronegative ($n = 32$) subjects, and correlating these results with the level of circulating CD4⁺ and CD8⁺ T cells that are phenotypically described as naive thymic emigrants. Abundant thymic tissue was detectable in many (47/99) HIV-1-seropositive adults, aged 20–59. Independent of age, radiographic demonstration of thymic tissue was significantly associated with both a higher CD4⁺ T cell count ($P = 0.02$) and a higher percentage and absolute number of circulating naive (CD45RA⁺CD62L⁺) CD4⁺ T cells ($P < 0.04$). The prevalence of an abundant thymus was especially high in younger HIV-1-seropositive adults (≤ 39 yr) with CD4 counts in the range 300–500 cells/ μ l and in older subjects (> 40 yr) regardless of CD4 count ($P = 0.03$). These studies suggest that the thymus is functional in some but not all adults with HIV-1 disease. (*J. Clin. Invest.* 1998; 101:2301–2308.) Key words: HIV disease • thymus • naive T cell • immune reconstitution • computed tomography

Introduction

The thymus is important for the generation of naive CD4⁺ and CD8⁺ T cells with a diverse T cell receptor repertoire. Although it is active in utero and in early life, intrathymic T cell production diminishes progressively with age. Numerous studies by autopsy (1–8), biopsy (9), and computed tomography

(CT)¹ (10–12) indicate that the volume of true thymic tissue (excluding perivascular space, adipose and fibrous tissue) diminishes progressively throughout life. These observations are consistent with clinical studies showing that, postmyeloablation, circulating naive CD4⁺ and CD8⁺ T cells are only found after relatively long periods of time (4–6 mo) and then usually in children and young adults (13–16). Viewed in conjunction with a more extensive literature of thymic function in rodents (17–23), these data underscore the commonly-held belief (17, 24, 25) that the thymus is not present or not functional in adults.

Even if functioning thymic tissue persisted in adults, it might be quickly eliminated by infection with HIV-1. Viral infection is clearly associated with thymic pathology in HIV-1-infected humans (26–36), and SCID-hu mice (37–40), simian immunodeficiency virus-infected nonhuman primates (41–43), and feline immunodeficiency virus-infected cats (44, 45). Destruction of thymocytes occurs after infection of CD3⁺CD4⁺CD8⁺ intrathymic T progenitor cells, CD3⁺CD4⁺CD8⁺ cortical thymocytes, and/or CD3⁺CD4⁺CD8⁺ or CD3⁺CD4⁺CD8⁺ medullary thymocytes (37–40). HIV-1-infected children with rapid disease progression have been found to have less thymic mass (as measured radiographically) (46) and function (as determined by the level of circulating CD4⁺ and CD8⁺ cells) (47). Finally, the chronic stress associated with HIV-1 disease and its attendant opportunistic infections could predictably lead, in and of itself, to thymic involution.

Given the current availability of highly active antiretroviral therapy, we considered it of interest to revisit the question of thymic function in the setting of adults with HIV-1 disease. In those with a functioning thymus, it might be possible to regenerate a T cell compartment with a diverse T cell receptor repertoire; in those without such thymic function, restoration of the T cell repertoire might require alternative approaches. We used computed tomography to visualize the amount of thymic parenchymal tissue in 99 HIV-1-seropositive and 32 HIV-1-seronegative adults. To ascertain whether thymic tissue visualized by CT scanning was functional, we graded and correlated the presence and amount of thymic tissue with the level of circulating naive (CD45RA⁺CD62L⁺) and memory/effector CD4⁺ and CD8⁺ T cells as measured by multiparameter flow cytometry.

Methods

Subjects. A convenience sample of subjects with documented HIV-1 infection was recruited from clinics and community organizations in

Portions of this work were presented at the 2nd Joint Conference of NIAID's SPIRAT/NCDDG-HIV, 22–26 June 1997 in Vienna, VA and at the 24th AIDS Clinical Trials Groups meeting, 7–10 December 1997 in Arlington, VA.

Address correspondence to J.M. McCune, The Gladstone Institute of Virology and Immunology, University of California, San Francisco, P.O. Box 419100, San Francisco, CA 94141-9100. Phone: 415-695-3828; FAX: 415-826-8449; E-mail: Mike_McCune.givi@quickmail.ucsf.edu

Received for publication 16 January 1998 and accepted in revised form 23 March 1998.

J. Clin. Invest.

© The American Society for Clinical Investigation, Inc.
0021-9738/98/06/2301/08 \$2.00

Volume 101, Number 11, June 1998, 2301–2308

<http://www.jci.org>

1. Abbreviation used in this paper: CT, computed tomography.

Table I. Composition of Study Cohort

Age	HIV status	CD4	n	Thymus (%)	Years since seroconversion		
					0-5	6-10	11+
20-29	-	≥ 500	9	100			
	+	< 500	16	81	7	6	1
	+	≥ 500	2	100	0	1	0
30-39	-	≥ 500	13	54			
	+	< 500	27	48	7	10	8
	+	≥ 500	10	50	6	4	0
40+	-	≥ 500	10	0			
	+	< 500	34	26	3	11	13
	+	≥ 500	10	50	3	3	4
Total	-	All	32	50			
	+	All	99	47	26	35	26

Of those HIV-1-seropositive subjects in the 40+ group, 39 were in the range of 40-49 yr old and five were in the range of 50-59 yr old. The years after seroconversion were self reported by 87 subjects and likely represent an underestimate. The CD4+ T cell counts were obtained within 0 to 5 (mean = 1) months of the CT scan.

the San Francisco Bay Area between August 1995 and June 1997. Efforts were made to balance entry of subjects across three age strata (20-29, 30-39, 40-49 yr) and two strata of CD4 counts (< 500, ≥ 500 cells/μl). HIV-1-uninfected controls were frequency matched by age strata. Prospective subjects were excluded if they had an acute illness and/or a prior medical condition known to have effects on the thymus (e.g., myasthenia gravis, hyperthyroidism, lymphoma, or cachexia).

The protocol was approved by the UCSF Committee on Human Research.

Chest tomography. After written informed consent was obtained, noncontrast chest CTs were performed on a CT scanner (9800; General Electric Co., Milwaukee, WI), with contiguous 5-mm sections obtained at end expiration from the sternal notch to the xiphoid. A thymic index was scored (by B.H. Gross and I.R. Francis) on a grading scale of 0-5: 0 - no soft tissue, with the thymus entirely replaced by fat; 1 - minimal soft tissue, barely recognizable; 2 - minimal soft tissue, more obvious; 3 - moderate soft tissue; 4 - moderate soft tissue of greater extent, almost mass like; and 5 - mass-like appearance, of concern for hyperplasia or thymoma. Representative images from HIV-1-seropositive adults are shown in Fig. 1. Most (> 95%) of the scores fell in the range of 1-4. Before data analysis, thymic scores of 3 or greater were designated to represent abundant thymic tissue. The radiologists were blinded to CD4 count and to HIV-1 serostatus. When all films were reviewed in a blinded manner for a second time and 31 randomly selected films were reviewed for a third time, 98% of the scores were within one grade of each other; the changes did not affect any of the conclusions below.

Flow cytometry. Naive or memory/effector CD4+ and CD8+ T cells were discriminated as described by Roederer et al. (48). Briefly, peripheral blood mononuclear cells were selected by scatter gates, divided into CD4+ or CD8+ T cell subpopulations, and then subdivided into naive (CD45RA+CD62L+) populations (see Fig. 3). All samples were processed for staining within 6 h of venipuncture, using the following antibody combinations: (a) mouse (ms) IgG1-FITC/msIgG1-phycoerythrin (PE)/CD4-CyChrome; (b) ms IgG1-FITC/ms IgG1-PE/CD8-CyChrome; (c) CD45RA-FITC/CD62L-PE/CD4-CyChrome; (d) CD45RA-FITC/CD62L-PE/CD8-CyChrome; (e) CD8-FITC (isotype control); (f) CD8-PE (isotype control); (g) CD8-CyChrome (isotype control); and (h) auto control (unstained). Monoclonal antibodies were obtained from PharMingen Corp. (San Diego, CA) as premixed two color stain combinations (FITC and PE conjugates)

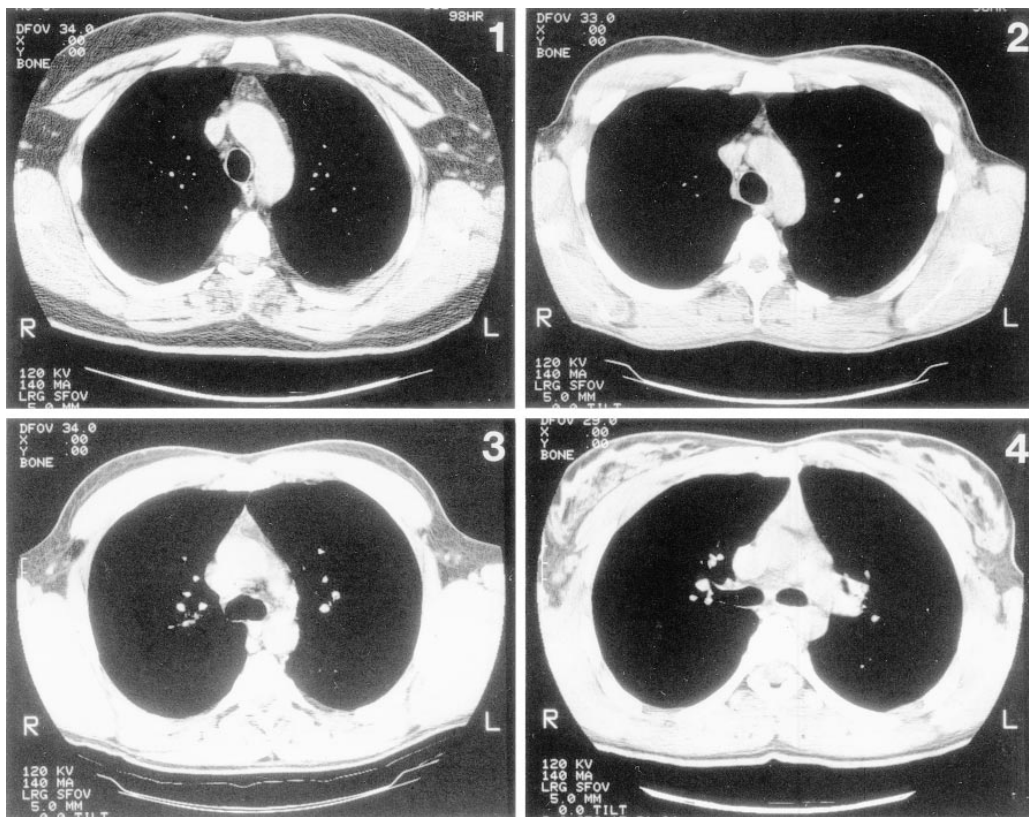

Figure 1. Visualization of the thymus in HIV-1-seropositive adults by computed tomography. Representative CT scans are shown corresponding to thymic index scores of 1, 2, 3, or 4. The thymus is the triangular-shaped mass at the top center of each frame, most obvious in frames 3 and 4.

and single-color reagents (CyChrome conjugates). Flow cytometric analysis was performed on a dual laser (argon 310 nm, argon 488 nm) FACStar Plus (Becton Dickinson Immunocytometry Systems, San Jose, CA). For each stain, data from 50,000 cells were collected and analyzed on CellQuest software. Absolute numbers of CD4⁺ or CD8⁺ T cell subpopulations were calculated by multiplying their fractional representation by the absolute counts obtained at the SFGH Clinical Laboratories. The coefficient of variation in the number of naive CD4⁺ and CD8⁺ T cells averaged 16% (range 4 to 35%) among eight subjects retested two or three times over intervals as long as 244 d (median = 70.5 d).

Results

Thymic tissue in HIV-1-seropositive adults. Our cross-sectional study stratified subjects into groups between the ages of 20–59; those that were HIV-1 seropositive were further subdivided into groups with CD4 counts that were either greater than or less than 500 cells/ μ l (Table I). The median age of the 99 HIV-1-seropositive subjects and the 32 HIV-1-seronegative subjects was 39 and 32 yr, respectively.

Younger subjects demonstrated larger amounts of thymic tissue by noncontrast chest CT (Fig. 1) than those who were older, whether they were HIV-1 seropositive (Fig. 2 A) or HIV-1 seronegative (Fig. 2 B) ($n = 99$, Spearman $r = -0.39$, $P = 0.0001$ for HIV-1 seropositives; $n = 32$, $r = -0.73$, $P =$

0.0001 for HIV-1 seronegatives). There was also a statistically significant association between decreasing amounts of thymic tissue and longer durations of infection with HIV-1 (Fig. 2 C) ($n = 87$, $r = -0.31$, $P = 0.003$). Subjects with a longer duration of infection were older ($n = 87$, $r = 0.45$, $P = 0.0001$) and tended to have lower CD4 counts ($n = 87$, $r = -0.09$, $P = 0.38$). On multivariate logistic regression analysis (Table II), the relationship between thymic index and duration of infection was observed to be confounded by age: subjects who had been infected longer were likely to have a lower thymus index simply because they were also older. However, in the HIV-1-seropositive subjects, bivariate analysis showed that higher thymic index was associated with higher CD4 count (Fig. 2 D) ($n = 99$, $r = 0.21$, $P = 0.04$), an association which persisted after controlling for age and duration of infection in multivariate logistic analysis (Table II) and stratified analysis (see Fig. 5).

Correlation of circulating naive T cells with thymic tissue. To determine whether the composition of the CD4⁺ T cell population was consistent with thymic function, circulating T cell subpopulations from 47 HIV-1-seropositive and 32 HIV-1-seronegative subjects were analyzed by multiparameter flow cytometry. Previous studies demonstrated that naive CD4⁺ and CD8⁺ T cells (i.e., thymic emigrants that have not yet undergone antigen-driven expansion) are phenotypically distinguishable from memory/effector T cells by their coexpression

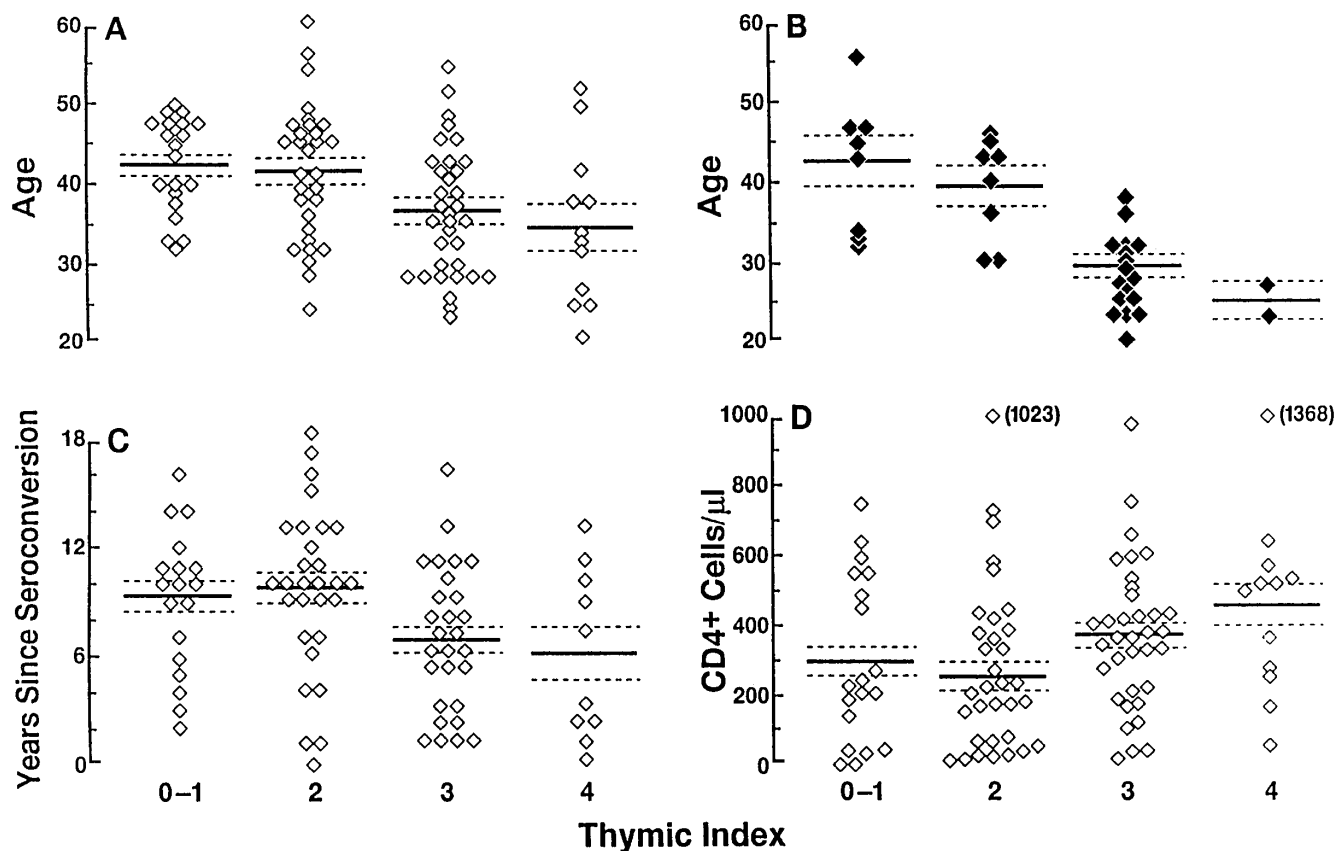


Figure 2. Thymic index relative to age, serostatus, years since seroconversion, and CD4 count. The thymic index for 99 HIV-1-seropositive (A) and 32 HIV-1-seronegative (B) subjects is shown relative to age. For the HIV-1-seropositive subjects, the thymic index is also correlated with years since seroconversion (C) and the absolute number of CD4⁺ T cell/ μ l (D). Solid bars represent means for each group; dotted lines represent the standard error of the mean. All associations are statistically significant and the association between thymic index and the CD4 count is independent of age (see text and Table II).

Table II. Multivariate Logistic Regression Analysis of Predictors of Thymic Index < 3

	Bivariate analysis		Multivariate analysis	
	Odds ratio	Significance	Odds ratio	Significance
Increasing age	1.70	$P = 0.0003$	1.64	$P = 0.006$
Increasing years of infection	1.62	$P = 0.0003$	1.25	$P = 0.23$
Decreasing CD4 count	1.33	$P = 0.02$	1.37	$P = 0.02$

Seropositive subjects ($n = 87$) with valid data for all predictors were analyzed. Thymic index was grouped before any analysis into two categories ($< 3, \geq 3$), representing nonabundant and abundant thymic tissue. The range of each predictor variable was grouped into six equal intervals to standardize the variance before analysis. Ages were grouped into 5-yr intervals increasing from ages 20 to 24, years of infection were grouped into 3-yr intervals increasing from years 0 to 2, and CD4 counts were grouped into intervals of 100 cells/ μ l decreasing from cells counts > 500 cells/ μ l. Odds ratios represent the odds of having thymic index < 3 for any interval of the predictor variable relative to the previous interval. Analysis of each interval as an independent variable indicated consistent dose-response relationships. Allowance for the unexpected increased prevalence of thymic tissue among young subjects with mildly decreased CD4⁺ counts (see Fig. 5) significantly improved the fit of the logistic model ($P = 0.03$) but did not substantially change the overall association between CD4 count and thymic mass. Consideration of other statistical interactions did not significantly improve model fit and did not substantially change model estimates.

of the surface markers CD45RA and CD62L (49, 50). Roederer and colleagues (48, 51) revealed a fall in the absolute number of naive (CD45RA⁺CD62L⁺) CD4⁺ and CD8⁺ T cells as a function of HIV-1 disease progression. Using similar techniques and phenotypic definitions here, CD4⁺ and CD8⁺ cells were categorized as naive T cells if they also expressed CD45RA and CD62L; those that were CD45RA⁺CD62L⁻, CD45RA⁻CD62L⁺, or CD45RA⁻CD62L⁻ were grouped together as memory/effector T cells (Fig. 3).

The HIV-1-uninfected controls, when compared with the HIV-1-infected subjects, were found to have higher CD4⁺ absolute numbers ($P = 0.0001$), lower CD8⁺ absolute numbers ($P = 0.0001$), and higher absolute numbers and percentages of naive CD4⁺ and CD8⁺ cells ($P < 0.004$). The thymic index in the uninfected group was significantly associated with the absolute number (Fig. 4, A and B) and percentage (Fig. 4, C and D) of naive CD4⁺ and CD8⁺ T cells ($r = 0.36-0.38, P < 0.05$ for each association). Amongst the HIV-1-seropositive adults, there was a significant correlation between the absolute CD4⁺ T cell count and the percentage of circulating naive CD4⁺ T cells ($n = 37, r = 0.41, P = 0.004$), confirming previously published observations (48). There was also a significant correlation between the thymic index and both the absolute number ($n = 37, r = 0.37, P = 0.02$) (Fig. 4 A) and the percentage ($n = 47, r = 0.35, P = 0.02$) (Fig. 4 C) of circulating naive CD4⁺ T cells. These associations persisted after controlling for age (Cochran-Mantel-Haenszel χ^2 analysis; $P < 0.04$). There was no significant association between thymic index and the absolute number (Fig. 4 B) or percentage (Fig. 4 D) of CD8⁺ naive T cells.

Enhanced abundance of thymus in some HIV-1-seropositive adults. Closer inspection of the data revealed two circum-

stances in which HIV-1 disease is associated with more and not less thymic tissue. First, abundant thymic tissue is particularly prevalent in younger seropositive subjects (≤ 39 yr) with a CD4 count in the range of 300–500 CD4⁺ T cells/ μ l. Over 93% of younger subjects in this CD4 range had abundant thymic tissue, a prevalence which was higher than that found in either the > 500 or the 100–300 CD4⁺ T cell strata (Fischer's exact test; $P = 0.06$ and 0.03 , respectively) (Fig. 5 B). Secondly, thymic tissue persisted in older subjects (> 39 yr) who were HIV-1 seropositive but not in those who were HIV-1 seronegative. Thus, abundant thymic tissue was not found in older seronegative subjects (0/10) but was found in 50% (5/10) of seropositive subjects of comparable age and CD4 count, representing a significantly higher prevalence in the HIV-1-infected group (Fischer's exact test; $P = 0.03$) (Table I, Fig. 5 C). Of note, abundant thymic tissue in these older (> 39 yr) HIV-1-infected subjects was associated with signs of thymic function, e.g., a higher absolute number and percentage of naive CD4⁺ T cells ($n = 25, r = 0.36, P = 0.07; n = 23, r = 0.41, P = 0.05$, respectively).

Discussion

The above data indicate that CT appearance of the thymus is highly correlated with circulating naive T cell subpopulations in both HIV-1-seropositive and HIV-1-seronegative adults. Abundant thymic tissue (with a score of 3 or greater) is present in many (47/99) HIV-1-seropositive adults. Among HIV-1-seropositive subjects under age 40, thymic tissue may be responsive to declining CD4⁺ T cell counts, which could explain the persistence of thymic tissue observed in older HIV-1-infected subjects. Alternatively, the high prevalence of thymic tissue in people over 39 yr of age may be due to increased survival among adults with thymus. In either case, and by inference, the thymus may be functional in some but not all individuals with HIV-1 disease.

This inference must be considered with two caveats in mind. First, the images visualized by CT may not represent true thymic tissue but a pathologic accumulation instead, e.g., of inflammatory or malignant cells. Direct biopsy studies of thymic tissue from HIV-1-seropositive adults will be necessary to resolve this issue. Secondly, it has not been proven that all CD45RA⁺CD62L⁺ human T cells emanate directly from the thymus; some, for instance, may be memory cells that have reverted in phenotype (23). Although the CD45RA⁺CD62L⁺ phenotypic definition of a naive T cell is more accurate than the use of the CD45RA⁺ phenotype alone (48, 49, 51), future studies will be necessary to confirm that this population has additional attributes of recent thymic emigrants, e.g., a diverse T cell receptor repertoire and the presence of T cell receptor rearrangement deletion circles (52, 53). Notwithstanding these caveats, it is striking that there is such a high correlation between the presence of abundant thymus and the circulating levels of provisionally assigned naive CD4⁺ T cells, suggesting that the thymus is contributing to this pool of cells in adults.

The possibility that functioning thymic tissue may be present in some HIV-1-seropositive adults is not completely unanticipated by the prior literature. Thymic involution certainly occurs in most adults, but the course is variable and even subjects as old as 107 yr have been found to have histologically normal thymic tissue (as defined by demarcated cortical and medullary regions and by the presence of immature cells posi-

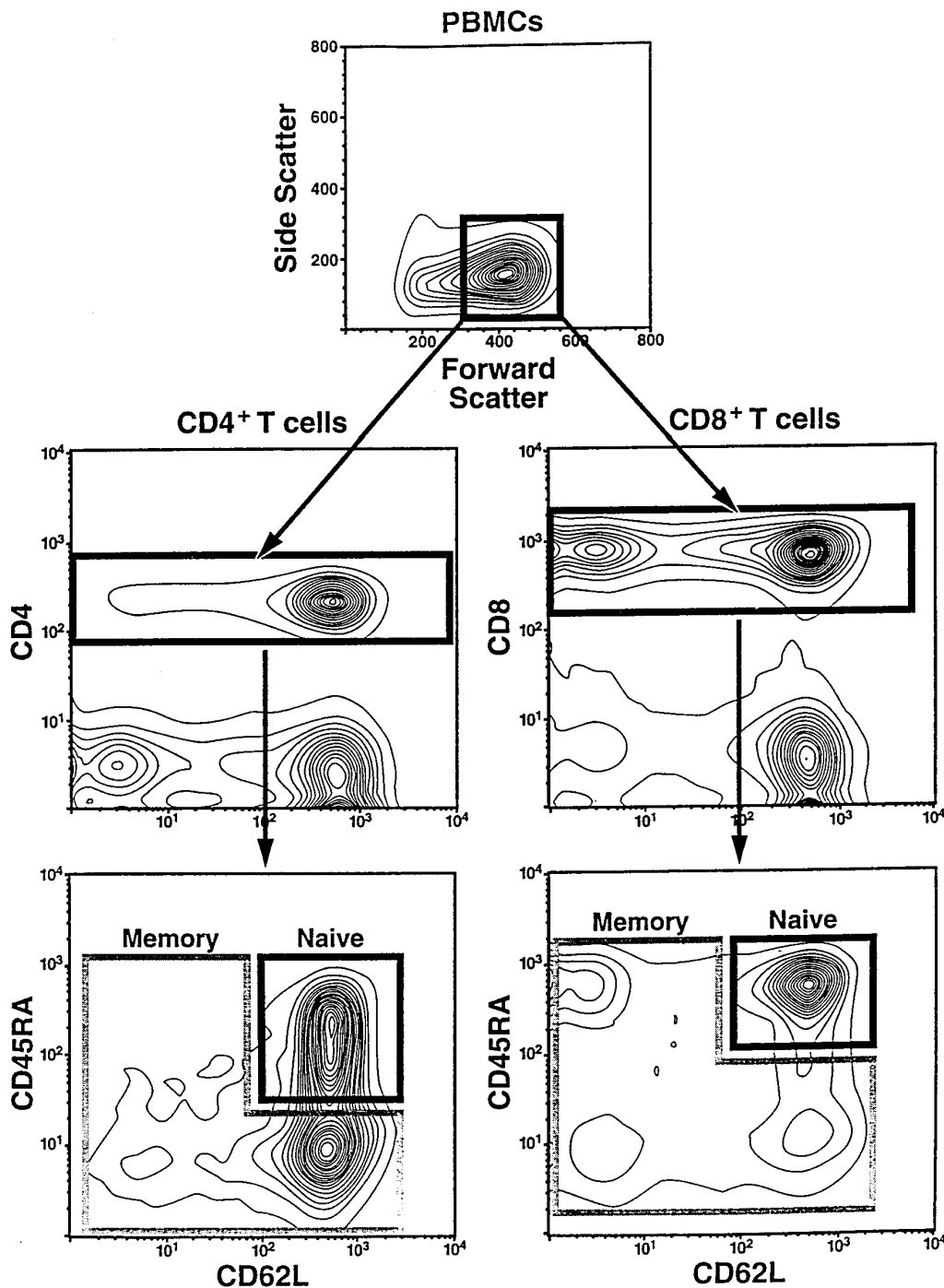


Figure 3. Detection of naive and memory/effector CD4⁺ and CD8⁺ T cell subpopulations by flow cytometry. PBMCs were selected by scatter gates (top), divided into CD4⁺ or CD8⁺ T cell subpopulations (middle, dark bars), and then subdivided into naive (CD45RA⁺CD62L⁺) populations (bottom, boxes with dark lines labeled naive); the remaining cells (boxes with gray lines labeled memory) represent various memory/effector populations.

tive for terminal deoxytransferase) (2, 54–58). In adult mice, thymocyte turnover is slower than it is in young mice, but nonetheless measurable: 10⁵ cells/d in the adult (6-mo-old) mouse as opposed to > 10⁶ cells/d in the young mouse (20–23). Finally, phenotypic analyses of naive T cells in HIV-1-seropositive adults as well as estimates of their turnover are consistent with, but not heretofore linked directly with, the presence of thymic function at older ages (48, 59–61).

The high frequency of thymic tissue found in HIV-1-seropositive adults raises the possibility that thymic function may actually be enhanced in some who are HIV-1 infected. This

possibility is underscored by the observation that most infected individuals with a CD4 count in the range of 300–500 cells/μl have a high thymic index (scores of 3–4). In the same manner that thymic rebound has been observed in adults after myeloablation (62–67) and after correction of Cushing's disease (68, 69), the peripheral T cell depletion induced by HIV-1 may drive renewed thymocyte maturation in an otherwise dormant thymic remnant. Thymic rebound may contribute to host compensation during the early phase of HIV-1 infection, characterized by maintenance of total T cell counts (70). If so, peripheral total T cell depletion may occur when thymopoiesis is

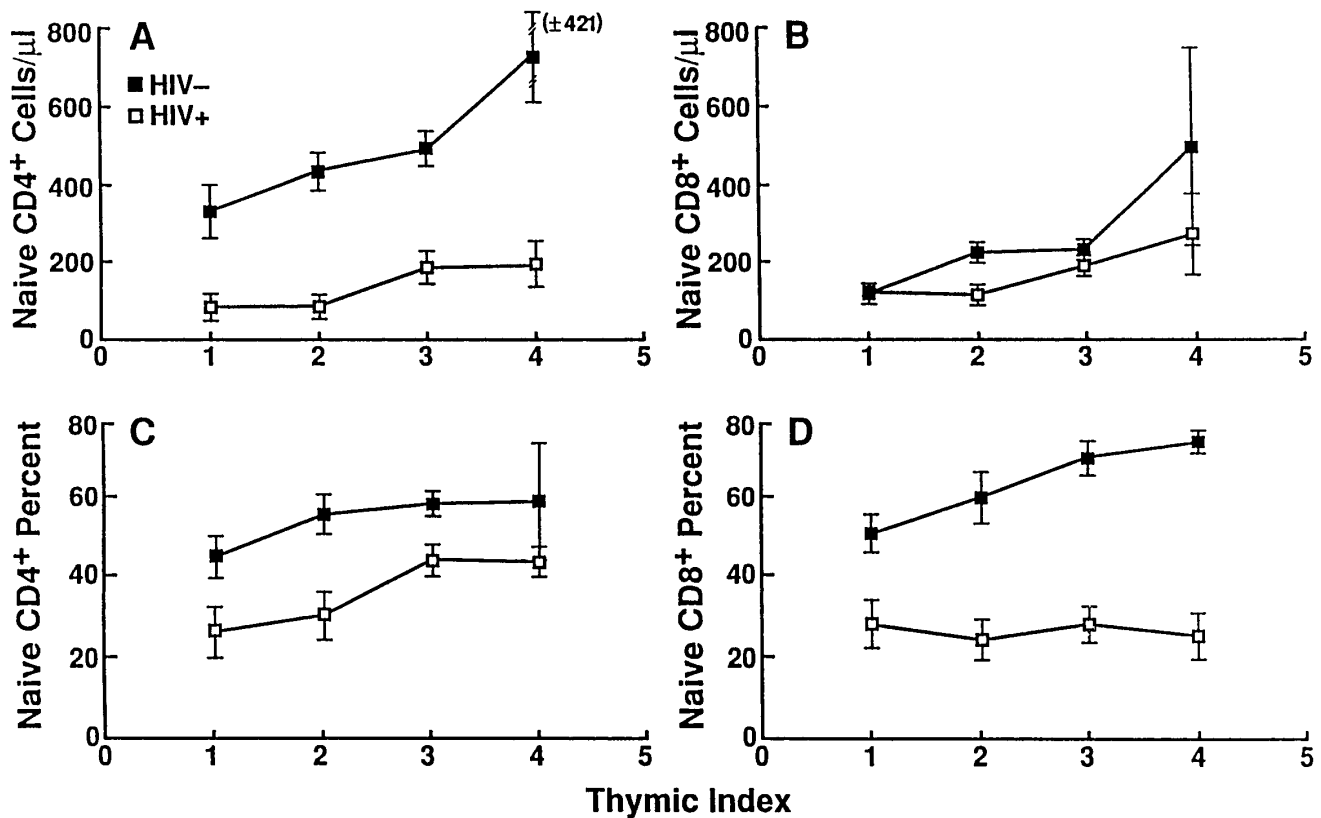


Figure 4. Naive T cells, thymic index, and HIV-1 serostatus. The thymic index for HIV-1-seropositive and HIV-1-seronegative subjects is shown relative to the absolute number and percent of circulating naive CD4⁺ (A and C, respectively) and CD8⁺ (B and D, respectively) T cells. For HIV-1-uninfected subjects, data from 37 and 47 subjects were available for analysis of absolute numbers and percent cells, respectively. For HIV-1-infected subjects, data from 32 subjects were available for analysis of absolute number and percent cells. These values were calculated as described in the Fig. 3 legend. Means and SEMs are shown.

finally disrupted (e.g., after direct infection and destruction of the organ by HIV-1). Reciprocally, immune reconstitution in late stage disease may be possible if disruption of thymopoiesis is reversible. These implications bear potential importance to the understanding of HIV-1 disease and to the design of clinical trials of highly active antiretroviral therapy and vaccines in HIV-1-infected patients. It will accordingly be critical to es-

tablish definitive evidence of thymic function in future studies of HIV-1-infected adults.

Acknowledgments

We thank the individuals who participated in this study, as well as ACT UP Golden Gate, Project Inform, and other members of the

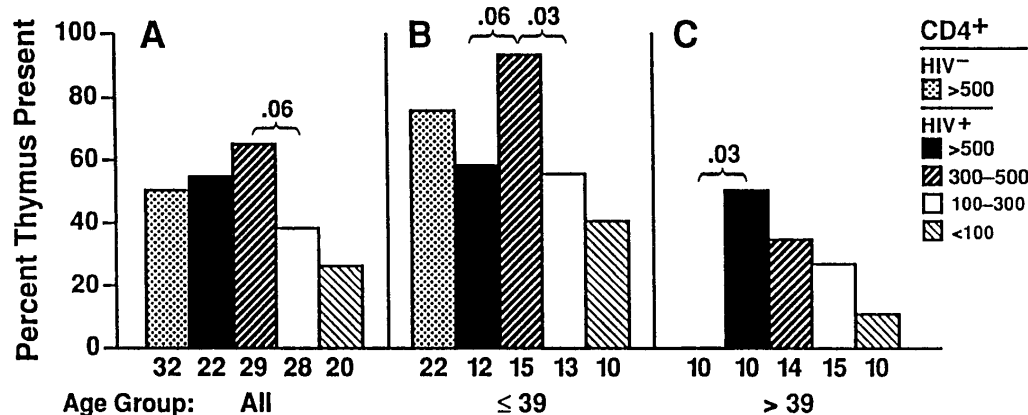


Figure 5. The presence of abundant thymic tissue and peripheral absolute CD4 cell counts. The percentage of HIV-1-seropositive and HIV-1-seronegative subjects with abundant thymic tissue (score of 3-4) is shown relative to absolute CD4 count, for all subjects (A), for those ≤ 39 yr (B), and for those > 39 yr (C). The number of subjects in each strata is shown at the base of each bar. The association between thymic abundance

and CD4 count persisted after controlling for age (Cochran-Mantel-Haenszel χ^2 analysis; $P = 0.01$). P values are indicated for comparisons between adjacent groups based on Fischer's Exact Tests and are not corrected for multiple comparisons.

San Francisco AIDS community for support; Mario Roederer for expert assistance in analysis of T cell subpopulations by flow cytometry; the San Francisco General Hospital Department of Radiology for assistance with the CT scans; Morgan Jenkins, Krishna Komanduri, Mario Roederer, and Karen Kaye Smith-McCune for careful reading of the manuscript; and James Gruden for early contributions to this project.

This work was supported by grants (to J.M. McCune) from the UCSF Center for AIDS Research, the UCSF AIDS Clinical Research Center, National Institutes of Health grant RO1-AI40312, and the J. David Gladstone Institutes. R.M. Grant is a UCSF Molecular Medicine Fellow. J.M. McCune is an Elizabeth Glaser Scientist supported by the Elizabeth Glaser Pediatric AIDS Foundation.

References

1. Bratton, A.B., and M.B. Cantab. 1925. The normal weight of the human thymus. *J. Pathol. Bacteriol.* 28:609-620.
2. Hammar, J.A. 1921. The new views as to the morphology of the thymus gland and their bearing on the problem of the function of the thymus. *Endocrinology.* 5:543-573, 731-760.
3. Boyd, E. 1927. Growth of the thymus. Its relation to status thymico-lymphaticus and thymic symptoms. *Am. J. Dis. Child.* 33:867-879.
4. Boyd, E. 1932. The weight of the thymus gland in health and in disease. *Am. J. Dis. Child.* 43:1162-1214.
5. Greenwood, M., and H.M. Woods. 1927. "Status thymico-lymphaticus" considered in the light of recent work on the thymus. *J. Hyg.* 26:305-326.
6. Steinmann, G.G. 1986. Changes in the human thymus during aging. In *The Human Thymus. Histopathology and Pathology.* Vol. 75, H.K. Muller-Hermelink, editor. Springer-Verlag, New York. 43-88.
7. Haagensen, D.C., N. Lane, and R. Lattes. 1972. Neoplastic proliferation of the epithelium of the mammary lobules of adenosis, lobular neoplasia, and small cell carcinoma. *Surg. Clin. North. Am.* 52:497-524.
8. Kendall, M.D., H.R.M. Johnson, and J. Singh. 1980. The weight of the human thymus gland at necropsy. *J. Anat.* 131:485-499.
9. Simpson, J.G., E.S. Gray, and J.S. Beck. 1975. Age involution in the normal human adult thymus. *Clin. Exp. Immunol.* 19:261-265.
10. Baron, R.L., J.K. Lee, S.S. Sagel, and R.R. Peterson. 1982. Computed tomography of the normal thymus. *Radiology.* 142:121-125.
11. Moore, A.V., M. Korobkin, W. Olanow, D.K. Heaston, P.C. Ram, N.R. Dunnick, and P.M. Silverman. 1983. Age-related changes in the thymus gland: CT-pathologic correlation. *AJR.* 141:241-246.
12. Francis, I.R., G.M. Glazer, F.L. Bookstein, and B.H. Gross. 1985. The thymus: reexamination of age-related changes in size and shape. *AJR.* 145:249-254.
13. Mackall, C.L., T.A. Fleisher, M.R. Brown, L. Wexler, M.A. Horowitz, I.T. Magrath, A.T. Shad, S.A. Steinberg, C.C. Chen, M.A. Andrich, et al. 1995. Age, thymopoiesis and CD4+ T lymphocyte regeneration after intensive chemotherapy. *N. Engl. J. Med.* 332:143.
14. Storek, J., R.P. Witherspoon, and R. Storb. 1995. T cell reconstitution after bone marrow transplantation into adult patients does not resemble T cell development in early life. *Bone Marrow Transplant.* 16:413-425.
15. Weinberg, K., G. Annett, A. Kashyap, C. Lenarsky, S.J. Forman, and R. Parkman. 1995. The effect of thymic function on immunocompetence following bone marrow transplantation. *Bio Blood Marrow Transplant.* 1:18.
16. Mackall, C.L., T.A. Fleisher, M.R. Brown, M.P. Andrich, C.C. Chen, I.M. Feuerstein, I.T. Magrath, L.H. Wexler, D.S. Dimitrov, and R.E. Gress. 1997. Distinctions between CD8+ and CD4+ T-cell regenerative pathways result in prolonged T-cell subset imbalance after intensive chemotherapy. *Blood.* 89:3700-3707.
17. Mackall, C.L., F.T. Hakim, and R.E. Gress. 1997. T-cell regeneration: all repertoires are not created equal. *Immunol. Today.* 18:245-251.
18. Hirokawa, K., K. Sato, and T. Makinodan. 1982. Influence of age of thymic grafts on the differentiation of T cells in nude mice. *Clin. Immunol. Immunopathol.* 24:251-262.
19. Hirokawa, K., S. Kubo, M. Utsuyama, C. Kurashima, and T. Sado. 1986. Age-related change in the potential of bone marrow cells to repopulate the thymus and splenic T cells in mice. *Cell. Immunol.* 100:443-451.
20. Scollay, R., and K. Shortman. 1985. Cell traffic in the adult thymus: cell entry and exit, cell birth and death. In *Recognition and Regulation in Cell-mediated Immunity.* J.D. Watson and J. Marbrook, editors. Marcel Dekker, New York. 3-30.
21. Shortman, K., M. Egerton, G.J. Spangrude, and R. Scollay. 1990. The generation and fate of thymocytes. *Semin. Immunol.* 2:3-12.
22. Scollay, R.G., E.C. Butcher, and I.L. Weissman. 1980. Thymus cell migration. Quantitative aspects of cellular traffic from the thymus to the periphery in mice. *Eur. J. Immunol.* 10:210-218.
23. Tough, D.F., and J. Sprent. 1995. Life span of naive and memory T cells. *Stem Cells.* 13:242-249.
24. George, A.J.T., and M.A. Ritter. 1996. Thymic involution with ageing: obsolescence or good housekeeping? *Immunol. Today.* 17:267-272.
25. Weinberg, K., and R. Parkman. 1995. Age, the thymus, and T lymphocytes. *N. Engl. J. Med.* 332:182-183.
26. Joshi, V.V., and J.M. Oleske. 1985. Pathologic appraisal of the thymus gland in acquired immunodeficiency syndrome in children. A study of four cases and a review of the literature. *Arch. Pathol. Lab. Med.* 109:142-146.
27. Joshi, V.V., J.M. Oleske, S. Saad, C. Gadol, E. Connor, R. Bobila, and A.B. Minnefor. 1986. Thymus biopsy in children with acquired immunodeficiency syndrome. *Arch. Pathol. Lab. Med.* 110:837-842.
28. Joshi, V.V., J.M. Oleske, and E.M. Connor. 1990. Morphologic findings in children with acquired immune deficiency syndrome: pathogenesis and clinical implications. *Pediatr. Pathol.* 10:155-165.
29. Burke, A.P., D. Anderson, W. Benson, R. Turnicky, P. Mannan, Y.H. Liang, J. Smialek, and R. Virmani. 1995. Localization of human immunodeficiency virus 1 RNA in thymic tissues from asymptomatic drug addicts. *Arch. Pathol. Lab. Med.* 119:36-41.
30. Prevot, S., J. Audouin, J. Andre-Bougaran, R. Griffais, A. Le Tourneau, J.G. Fournier, and J. Diebold. 1992. Thymic pseudotumorous enlargement due to follicular hyperplasia in a human immunodeficiency virus seropositive patient. Immunohistochemical and molecular biological study of viral infected cells. *Am. J. Clin. Pathol.* 97:420-425.
31. Davis, A.E.J. 1984. The histopathological changes in the thymus gland in the acquired immune deficiency syndrome. *Ann. NY Acad. Sci.* 437:493-502.
32. Grody, W.W., S. Fligel, and F. Naeim. 1985. Thymus involution in the acquired immunodeficiency syndrome. *Am. J. Clin. Pathol.* 84:85-95.
33. Linder, J. 1987. The thymus gland in secondary immunodeficiency. *Arch. Pathol. Lab. Med.* 111:1118-1122.
34. Savino, W., M. Dardenne, C. Marche, D. Trophilm, J.-M. Dupuy, D. Pekovic, N. Lapointe, and J.F. Bach. 1986. Thymic epithelium in AIDS. An immunohistologic study. *Am. J. Pathol.* 122:302-307.
35. Schuurman, H.J., W.J.A. Krone, R. Broekhuizen, J. van Baarlen, P. van Veen, A.L. Golstein, J. Huber, and J. Goudsmit. 1989. The thymus in acquired immune deficiency syndrome: comparison with other types of immunodeficiency disease and presence of components of human immunodeficiency virus type 1. *Am. J. Pathol.* 134:1329-1338.
36. Seemayer, T.A., A.C. Laroche, P. Russo, R. Malebranche, E. Arnoux, J.M. Geurin, G. Pierre, J.M. Dupuy, J.G. Gartner, W.S. Lapp, et al. 1984. Precocious thymic involution manifest by epithelial injury in the acquired immune deficiency syndrome. *Hum. Pathol.* 15:469-474.
37. Stanley, S.K., J.M. McCune, H. Kaneshima, J.S. Justement, M. Sullivan, E. Boone, M. Baselar, J. Adelsberger, M. Bonyhadi, J. Orenstein, et al. 1993. Human immunodeficiency virus infection of the human thymus and disruption of the thymic microenvironment in the SCID-hu mouse. *J. Exp. Med.* 178:1151-1163.
38. Su, L., H. Kaneshima, M. Bonyhadi, S. Salimi, D. Kraft, L. Rabin, and J.M. McCune. 1995. HIV-1 induced thymocyte depletion is associated with indirect cytopathicity and infection of progenitor cells in vivo. *Immunity.* 2:25-36.
39. Aldrovandi, G.M., G. Feuer, L. Gao, B. Jamieson, M. Kristeva, I.S.Y. Chen, and J.A. Zack. 1993. The SCID-hu mouse as a model for HIV infection. *Nature.* 363:732-736.
40. Bonyhadi, M.L., L. Rabin, S. Salimi, D.A. Brown, J. Kosek, J.M. McCune, and H. Kaneshima. 1993. HIV induces thymus depletion in vivo. *Nature.* 363:728-732.
41. Baskin, G.B., M. Murphey-Corb, L.N. Martin, B. Davison-Fairburn, F.S. Hu, and D. Kuebler. 1991. Thymus in simian immunodeficiency virus-infected rhesus monkeys. *Lab. Invest.* 65:400-407.
42. Joag, S.V., Z. Li, L. Foresman, E.B. Stephens, L.J. Zhao, I. Adany, D.M. Pinson, H.M. McClure, and O. Narayan. 1996. Chimeric simian/human immunodeficiency virus that causes progressive loss of CD4+ T cells and AIDS in pig-tailed macaques. *J. Virol.* 70:3189-3197.
43. Li, S.-L., E.E. Kaaya, C. Ordonez, E. Ekman, H. Feichtinger, P. Putkonen, D. Bottiger, G. Biberfeld, and P. Biberfeld. 1995. Thymic immunopathology and progression of SIVsm infection in cynomolgus monkeys. *J. AIDS.* 9:1-10.
44. Beebe, A.M., N. Dua, T.G. Faith, P.F. Moore, N.C. Pedersen, and S. Dandekar. 1994. Primary stage of feline immunodeficiency virus infection: viral dissemination and cellular targets. *J. Virol.* 68:3080-3091.
45. Dua, N., G. Reubel, P.F. Moore, J. Higgins, and N.C. Pedersen. 1994. An experimental study of primary feline immunodeficiency virus infection in cats and a historical comparison to acute simian and human immunodeficiency virus disease. *Vet. Immunol. Immunopathol.* 43:337-355.
46. Meyers, A., N. Pepe, W. Cranley, and K. McCarten. 1992. Decreased thymus size on chest radiography: a sign of pediatric human immunodeficiency virus infection? *Pediatrics.* 90:99-102.
47. Kourits, A.P., C. Ibegbu, A.J. Nahmias, F.K. Lee, W.S. Clark, M.K. Sawyer, and S. Nesheim. 1996. Early progression of disease in HIV-infected infants with thymus dysfunction. *N. Engl. J. Med.* 335:1431-1436.
48. Roederer, M., J.G. Dubs, M.T. Anderson, P.A. Raju, L.A. Herzenberg, and L.A. Herzenberg. 1995. CD8 naive T cell counts decrease progressively in HIV-infected adults. *J. Clin. Invest.* 95:2061-2066.
49. Picker, L.J., J.R. Treer, D.B. Ferguson, P.A. Collins, D. Buck, and L.W.

- Terstappen. 1993. Control of lymphocyte recirculation in man. I. Differential regulation of the peripheral lymph node homing receptor L-selectin on T cells during the virgin to memory cell transition. *J. Immunol.* 150:1105–1121.
50. Sanders, M.E., M.W. Makgoba, and S. Shaw. 1988. Human naive and memory T cells. *Immunol. Today.* 9:195–199.
51. Rabin, R.L., M. Roederer, Y. Maldonado, A. Petru, L.A. Herzenberg, and L.A. Herzenberg. 1995. Altered representation of naive and memory CD8 T cell subsets in HIV-infected children. *J. Clin. Invest.* 95:2054–2060.
52. Kong, F., C.H. Chen, and M.D. Cooper. 1998. Thymic function can be accurately monitored by the level of recent T cell emigrants in the circulation. *Immunity.* 8:97–104.
53. Pickel, J.M., W.T. McCormack, C.H. Chen, M.D. Cooper, and C.B. Thompson. 1993. Differential regulation of V(D)J recombination during development of avian B and T cells. *Int. Immunol.* 5:919–927.
54. Muller-Hermelink, H.K., G.G. Steinmann, and H. Stein. 1982. Structural and functional alterations of the ageing human thymus. *Adv. Exp. Med. Biol.* 149:303–312.
55. Muller-Hermelink, H.K., and G.G. Steinmann. 1984. Age-related alterations of intrathymic microenvironment. In *Lymphoid Cell Functions in Ageing*. Vol. 3, A. L. de Weck, editor. Eurage, 75–82.
56. Steinmann, G.G., and H.K. Muller-Hermelink. 1984. Immunohistological demonstration of terminal transferase (TdT) in the age-involved human thymus. *Immunobiology.* 126:45–52.
57. Steinmann, G.G., and H.K. Muller-Hermelink. 1984. Lymphocyte differentiation and its microenvironment in human thymus during aging. *Monogr. Dev. Biol.* 17:142–155.
58. Steinmann, G.G., G. Klaus, S. Gillis, and H.K. Muller-Hermelink. 1984. Thymic and splenic IL2-production and response during ageing and correlations with immunohistologic studies. In *Lymphoid Cell Functions in Ageing*. Vol. 3, A.L. de Weck, editor. Eurage, 161–168.
59. Wolthers, K.C., G. Bea, A. Wisman, S.A. Otto, A.M. de Roda Husman, N. Schaft, K. de Wolf, J. Goudsmit, R.A. Coutinho, A.G. van der Zee, et al. 1996. T cell telomere length in HIV-1 infection: no evidence for increased CD4+ T cell turnover. *Science.* 274:1543–1547.
60. Palmer, L.D., N.-P. Weng, B.L. Levine, C.H. June, H.C. Lane, and R.J. Hodes. 1997. Telomere length, telomerase activity, and replicative potential in HIV infection: analysis of CD4+ and CD8+ T cells from HIV-discordant monozygotic twins. *J. Exp. Med.* 185:1381–1386.
61. Hellerstein, M.K., and J.M. McCune. 1997. T cell turnover in HIV-1 disease. *Immunity.* 7:583–589.
62. Choyke, P.L., R.Z. Zeman, J.E. Gootenberg, J.N. Greenberg, F. Hoffer, and J.A. Frank. 1987. Thymic atrophy and regrowth in response to chemotherapy: CT evaluation. *AJR.* 149:269–272.
63. Carmosino, L., A. Dibenedetto, and S. Feffer. 1985. Thymic hyperplasia following successful chemotherapy. *Cancer.* 56:1526–1528.
64. Kissin, C.M., J.E. Husband, D. Nicholas, and W. Eversman. 1987. Benign thymic enlargement in adults after chemotherapy: CT demonstration. *Radiology.* 163:67–70.
65. Small, E.J., A.P. Venook, and L.E. Damon. 1993. Gallium-avid thymic hyperplasia in an adult after chemotherapy for Hodgkin disease. *Cancer.* 72: 905–908.
66. Simmonds, P., M. Silberstein, and J. McKendrick. 1993. Thymic hyperplasia in adults following chemotherapy for malignancy. *Aust. N. Z. J. Med.* 23: 264–267.
67. Tait, D.M., P. Goldstraw, and J.E. Husband. 1986. Thymic rebound in an adult following chemotherapy for testicular cancer. *Eur. J. Surg. Oncol.* 12: 385–387.
68. Tabarin, A., B. Catargi, P. Chanson, S. Hieronimus, J.B. Corcuff, F. Laurent, M. Harter, J. Drouillard, and P. Roger. 1995. Pseudo-tumours of the thymus after correction of hypercortisolism in patients with ectopic ACTH syndrome: a report of five cases. *Clin. Endocrinol.* 42:207–213.
69. Doppman, J.L., E.H. Oldfield, G.P. Chrousos, L. Nieman, R. Udelsman, G.B. Cutler, and D.L. Loriaux. 1986. Rebound thymic hyperplasia after treatment of Cushing's syndrome. *AJR.* 147:1145–1147.
70. Margolick, J.B., A. Munoz, A.D. Donnenberg, L.P. Park, N. Galai, J.V. Giorgi, M.R. O'Gorman, and J. Ferbas. 1995. Failure of T-cell homeostasis preceding AIDS in HIV-1 infection. *Nat. Med.* 1:674–680.