

RETINAL PATHOLOGY AFTER CENTRAL RETINAL VEIN OCCLUSION*

BY

J. REIMER WOLTER†

Ann Arbor, Mich., U.S.A.

OCCLUSION of the central retinal vein causes incomplete haemorrhagic infarction of the inner layers of the retina. Haemorrhagic infarction describes a situation in which the venous backflow of an area of tissue is interrupted. As a result the flow of blood has to stop; ischaemia and resulting increase of vascular permeability lead to retinal oedema and extensive haemorrhages. The central retinal artery remains open and goes on pushing more blood into the retina. In the inner retina the ischaemia soon results in degeneration of the neurons of the inner retinal layers. The glia and the mesodermal retinal structures, however, survive and form a scar. This incompleteness of the haemorrhagic infarction of the inner retina in central vein occlusion has its explanation in the double blood supply of the retina. The inner retinal layers are normally supplied by the retinal blood system, while the chorio-capillaris supplies the outer retinal layers. After central vein occlusion the supply from the chorio-capillaris is obviously sufficient for a survival of the glia and the mesodermal structures of the inner retina until the retinal circulation is re-established by venous collaterals and recanalization of the thrombus. The high metabolic needs of the neurons of the inner retina, however, cannot be supplied from the chorio-capillaris and these cells suffer irreversible damage which causes blindness. Secondary (haemorrhagic) glaucoma is a very common complication of central vein occlusion, and occurs about 2 to 5 months after the occlusion.

The above description of the retinal changes which follow venous occlusion may be sufficient to explain this pathological process to a student. The ophthalmologist, however, should add all the available details which can be gained by every possible approach of research. It is the purpose of this study to demonstrate the early and late pathology of the second neuron of the visual pathway which is the direct cause of the blindness which finally results from central vein occlusion. Along with the pathology of the retinal part of the second neuron—the ganglion cells and the nerve fibres—the neuroglia and the retinal blood vessels will be considered.

Two typical cases of occlusion of the central retinal vein—one early and one late—are used as examples for this demonstration. Half of each involved

* Received for publication November 4, 1960.

† From the Department of Ophthalmic Surgery of the University of Michigan Med. Center. Supported by Grant No. B-2873 of the U.S. Department of Health, Education, and Welfare.

eye was studied with the conventional histological techniques. The retina of the other half of each eye was isolated, sectioned flat on the freezing microtome, and stained with the silver carbonate technique of del Rio Hortega (Scharenberg and Zeman, 1952). All the illustrations to this paper are unretouched photomicrographs.

Cases and Histological Observations

Case 1, a 73-year-old white male, was seen in April, 1954, by Dr. R. C. Pochert of Owosso, Michigan. The patient gave a history of painless loss of vision in his right eye about 2 months before. About one week before, however, he had started to have pain in this eye. At the time of the first examination he showed a red eye exhibiting a steamy cornea and a shallow anterior chamber. The eye was stony hard and there were numerous new-formed blood vessels on the iris surface. Extensive haemorrhages were seen on the retina. A short trial of conservative treatment of the glaucoma in the right eye was unsuccessful. Enucleation because of pain and blindness was done on April 28, 1954, about 2 months after the sudden loss of vision. The diagnosis was absolute glaucoma secondary to thrombosis of the central retinal vein.

Macroscopic Examination.—This eye is of normal size. The anterior chamber is shallow. The lens is clear. The vitreous shows posterior liquefaction. Many haemorrhages are seen all through the retina.

Microscopic Examination.—There are bullous epithelial changes of the cornea. The chamber angle is narrow and in some areas occlusion of the chamber angle has occurred by fibrovascular tissue extending over it. A new layer of fibroblasts and thin-walled new-formed blood vessels is seen on the anterior iris surface. Diffuse lymphocytic infiltration is seen in the iris and ciliary body and the ciliary body is atrophic. The retina shows peripheral cystic degeneration. Extensive haemorrhages are seen through all layers of the retina, especially in the posterior pole. The routine techniques show the retina otherwise to be about normal. There is only a slight decrease of the ganglion cells, and the nerve-fibre layer has about its normal thickness. The optic disc and optic nerve are about normal, but thrombosis and early recanalization are observed in the central retinal vein. The diagnosis is that of secondary (haemorrhagic) glaucoma following occlusion of the central retinal vein.

Pathology.—This eye exhibiting relatively early retinal pathology following occlusion of the central vein was used as an example for the demonstration of the retinal changes in special stained flat sections. Extensive deep and flame-shaped haemorrhages are found with these techniques all through the retina. In the nerve-fibre layer and in Henle's fibre layer the erythrocytes are arranged in a radiating pattern in the interspaces of the nerve fibres and of Henle's fibres (Figs 1 and 2, opposite). The outer layers of the retina are rather well preserved and show no distinct pathology except for the extensions of some of the haemorrhages into these layers. Most of the pathology is found in the nerve-fibre layer and in the ganglion-cell layer.

In some areas the nerve fibres running through the extensive haemorrhages still appear to be normal. Most areas show a definite decrease of the number of nerve fibres, which is most advanced in the areas of haemorrhage (Fig. 3, opposite).

Many nerve fibres all through the nerve-fibre layer are seen in all phases of destruction. All through the nerve-fibre layer interruption of single nerve fibres is seen, and bizarre swellings of Cajal have developed on the remaining nerve-fibre stumps which are still

FIG. 1.—Low-power view of flat section through the retina close to the optic disc in Case 1. The dark-stained erythrocytes are seen to be arranged in the pattern of flame-shaped haemorrhage. Hortega method, photomicrograph. $\times 133$.

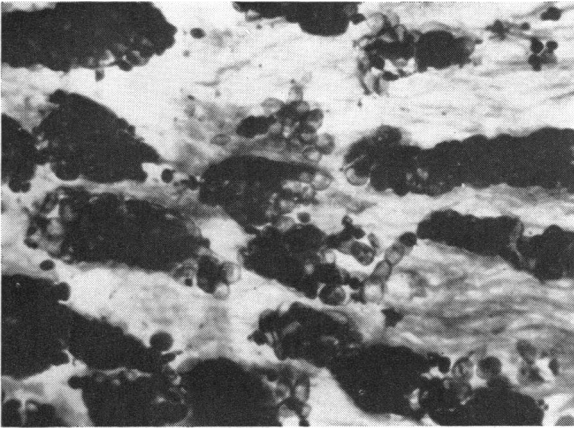
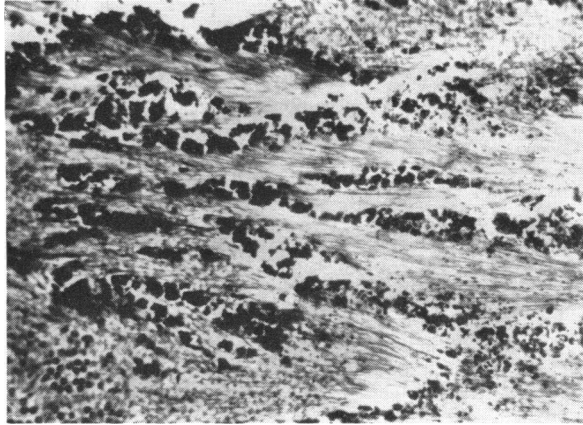


FIG. 2.—High-power view of the central area of Fig. 1. Accumulations of erythrocytes of the flame-shaped haemorrhages are seen between the nerve fibres. Hortega method, photomicrograph. $\times 500$.

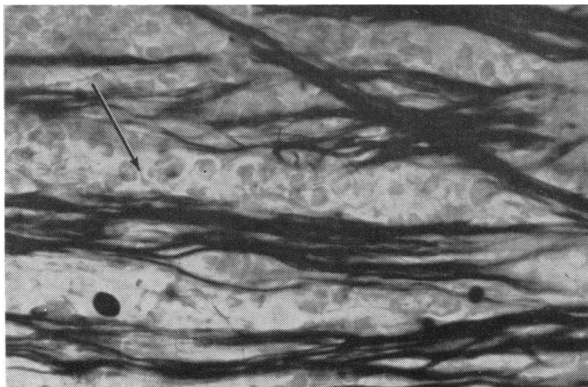


FIG. 3.—High-power view of continuous nerve fibres within an area of retinal haemorrhage (arrow) in a retinal flat section of Case 1. Hortega method, photomicrograph. $\times 500$.

connected to the neuronal cell bodies of the ganglion-cell layer (Fig. 4). The great majority of these terminal swellings of Cajal—well known as components of the cotton wool spots of the retina—is found to point with their ends towards the optic disc. Thus, in the histological picture seen in Fig. 4, the optic disc would be on the left side while the corresponding ganglion cells of the nerve-fibre stumps would be on the right side of the picture. It is of great interest that in many sections some small interrupted nerve fibres are seen to point in exactly the opposite direction. These delicate interrupted nerve fibres point away from the optic disc (Fig. 5).

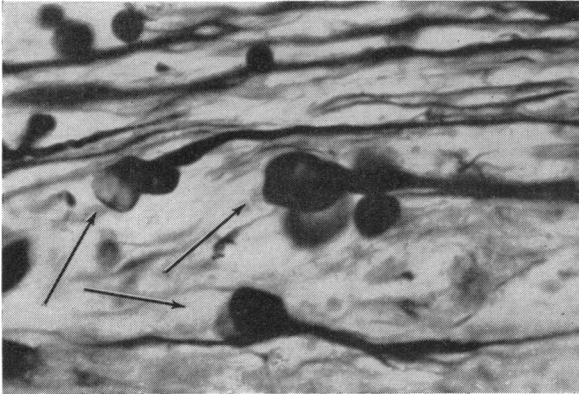
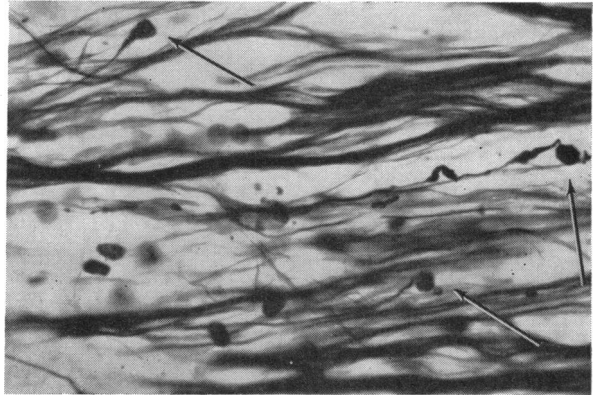


FIG. 4.—High-power view of three nerve-fibre stumps with terminal swellings of Cajal at their distal ends (arrows) seen in retinal flat section through the nerve-fibre layer of Case 1. The optic disc would be on the left side of this picture. Hortega method, photomicrograph. $\times 500$.

FIG. 5.—Flat section through nerve-fibre layer of Case 1, showing three interrupted nerve fibres with Cajal terminal swellings (arrows) pointing away from the optic disc. Hortega method, photomicrograph. $\times 500$.



An understanding of the development and significance of the terminal swellings of Cajal at the distal end of interrupted nerve fibres is important for the explanation of these two different types of nerve-fibre stumps pointing in opposite directions. Whenever nerve fibres become interrupted by any type of pathology the part distal to the site of interruption will soon disappear since it is no longer connected to the cell body. The proximal part, however, will remain for some time; its distal end soon develops, as a reaction to the interruption and next to its site, a so-called terminal swelling of Cajal, also known as growth bulb. The stumps with this growth bulb remain for some time. In the retina they may be seen densely accumulated in the so-called cotton-wool spots (compare Wolter, 1959a). Finally, in the retina, retrograde degeneration will result in complete loss of the remaining nerve-fibre stumps and corresponding ganglion cells.

Our present case shows many nerve-fibre stumps with Cajal bodies pointing towards the optic disc. A few interrupted nerve fibres of smaller size with Cajal bodies are seen to point in the opposite direction—away from the disc. This fact indicates that the majority of the interrupted nerve fibres in this case are centripetal in character and run

to the lateral geniculate body of the brain. The smaller nerve stumps, however, which point away from the disc, must be the stumps of centrifugal nerve fibres which originate in the brain and end in the retina (compare Wolter, 1956a, b, 1960). Both types of nerve fibres are interrupted by the ischaemic process as a result of the haemorrhagic infarction following venous occlusion in the present case. The interruption of the centripetal fibres means interruption of the second neuron of the visual pathway. The function of the interrupted centrifugal fibres remains as yet unknown.

In this case of central vein occlusion, which was examined about 2 months after the vascular accident, most of the pathology is found in the nerve-fibre layer. The interruption and destruction of these nerve fibres results, of course, in blindness; it will also result in retrograde degeneration of the ganglion cells of the ganglion-cell layer later in the course of the disease. The ganglion-cell layer of this first case shows different early phases of swelling and degeneration of the ganglion cells. This accompanies early hyperactivity and proliferation of the astroglia of this layer. Our knowledge of the normal structure and pathology of the human retinal ganglion cells is still extremely limited and no attempt is made in this study to describe and classify all the changes seen in the ganglion cells of this first case. Fig. 6 shows an area of a flat section through the ganglion-cell layer with several ganglion cells. Wide spaces between the ganglion cells are filled with glia. This indicates a loss of some of the ganglion cells, and this loss is found throughout the ganglion-cell layer.

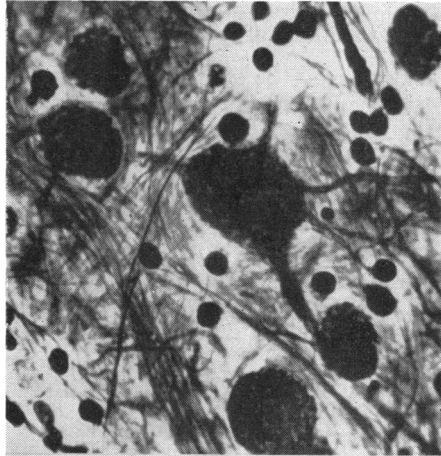


FIG. 6.—High-power view of flat section through ganglion-cell layer of Case 1. Large spaces are seen between the ganglion cells and the astroglia is hyperplastic. Hortege method, photomicrograph. $\times 500$.

In summarizing it can be stated that the pathology of the retina 2 months after venous occlusion as seen with silver stain in this case is found to be composed of extensive haemorrhages, interruption and degeneration of both the centrifugal and centripetal nerve fibres of the nerve-fibre layer, different stages of early degeneration of the ganglion cells of the ganglion-cell layer, and hyperactivity and early proliferation of the astroglia of both inner retinal layers. The outer retinal layers appear to be normal except for extensions of some of the haemorrhages.

Case 2, a 76-year-old white male, was first examined by Dr. T. R. McWilliams of Ann Arbor, Michigan. This patient had primary open-angle glaucoma diagnosed in 1955 which was well controlled on Pilocarpine eye drops. In 1957 a painless loss of vision occurred in the patient's left eye. This was explained by central vein occlusion which had developed in addition to the primary glaucoma. Early in 1959 the patient had severe pain and redness of the left eye, and the intra-ocular pressure was then found to be 60 mm. Hg. Enucleation was carried out on January 15, 1959.

Macroscopic Examination.—The eye ball measures $25 \times 24 \times 24$ mm. The anterior chamber is of about normal depths. The lens is in the normal position. Extensive posterior synechiae are found all around. The posterior vitreous is liquefied and the anterior vitreous resembles a dense ring-shaped formation which is firmly attached to the peripheral retina. There is deep glaucomatous cupping of the disc, and haemorrhages of different sizes and shapes are seen in the retina.

Microscopic Examination.—The routine stains show large defects in the corneal epithelium. The remaining epithelium shows bullous keratopathy. The filtration angle is completely closed by continuous anterior peripheral synechiae. Proliferated fibrovascular tissue containing many thin-walled blood vessels is found on the anterior surface of the iris and in the false angle. The central retina shows complete loss of the nerve-fibre and ganglion-cell layers. In some areas cystic degeneration of the retina is seen. The outer layers of the retina with the rods and cones appear rather well preserved. There are deep and superficial retinal haemorrhages and there are areas with new-formed thin-walled blood vessels within and on the inner surface of the retina. The optic disc shows deep glaucomatous cupping and there is advanced optic nerve atrophy. The central retinal vein and some of the larger venous branches are seen to be occluded and partially recanalized. The diagnosis is that of secondary (haemorrhagic) glaucoma with bullous keratopathy, angle closure, rubeosis iridis, and degeneration of the retina and optic nerve. It is possible to differentiate histologically the changes of long-standing primary glaucoma from those of secondary glaucoma following occlusion of the central retinal vein.

Pathology.—The silver carbonate stains reveal important additional facts about the retinal pathology, the typical late changes seen in many cases of old venous occlusion with or without secondary glaucoma. The outer layers of the retina are almost normal. Fig. 7 gives the low-power view of a flat section through the foveola with the cross-sectioned cones in the centre and parts of the outer nuclear layer and Henle's fibre layer around it. Fig. 8 shows a high-power view of the cross-section through the cones which appear virtually normal, though a few have degenerated and left cyst-like spaces.

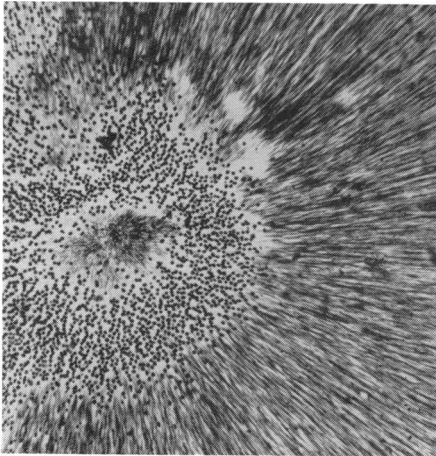


FIG. 7.—Low-power view of flat section through the foveola of Case 2. The cross-sectioned cones are seen in the centre, and parts of the outer nuclear layer and Henle's fibre layer are seen around it. Hortega method, photomicrograph. $\times 133$.

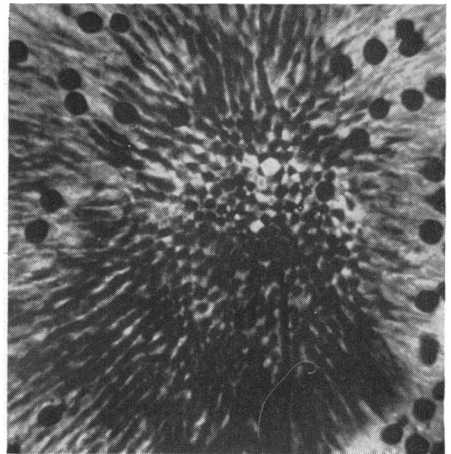


FIG. 8.—High-power view of the central area in Fig. 7, showing the cross-sectioned cones of the foveola. Most of the cones appear normal, but some have undergone cystic degeneration. Hortega method, photomicrograph. $\times 500$.

Fig. 9 shows a transitional section of the intermediate retina demonstrating the rods and cones in their normal arrangement and shape. The observation of the almost normal histology of the outer retina in this case of old absolute glaucoma is interesting. However, the rather well-preserved neurons of the outer retina in this case are of no use since the inner neurons are completely degenerated.

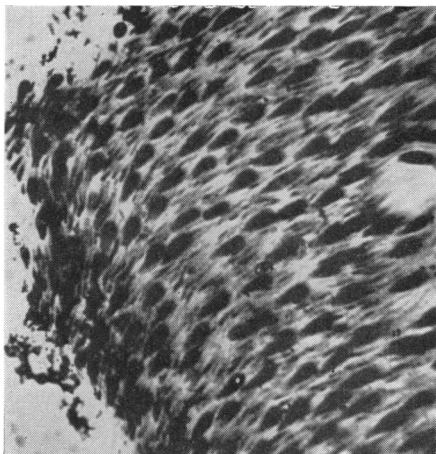


FIG. 9.—Normal appearance of rods and cones of the intermediate retina of Case 2 as seen in the transitional section. Hortega method, photomicrograph. $\times 500$.

Fig. 10 shows an area of a flat section through the inner retina. This area corresponding to the ganglion-cell layer shows a dense scar of proliferated astroglia and cross-sections of the inner processes of Müller's fibres, but no ganglion cells have survived. In other areas of the inner retina extensive cystic degeneration has occurred at the site of old haemorrhages.

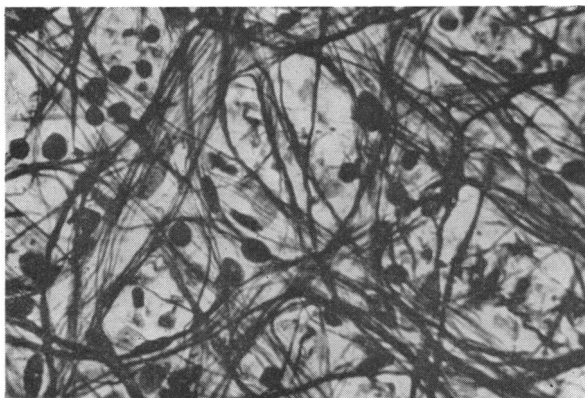


FIG. 10.—Flat section through inner retina of Case 2. The ganglion cells and nerve fibres are replaced by hypertrophic astroglia. Hortega method, photomicrograph. $\times 500$.

Extensive vascular pathology is found within this scar-like inner part of the retina. Fig. 11 (overleaf) shows one of the occluded larger venous branches with an irregular wall and with mesodermal cells proliferating within the lumen. Scar-like glia—of the type seen in the nerve fibre layer (compare Wolter, 1959b)—is seen around the blood vessels. Extensive neovascularization is also seen all through the inner retina.

Fig. 12 (overleaf) shows a new-formed, thin-walled blood vessel of the inner retina of this case at high power. Its wall is composed of endothelial cells and it has very little adventitia and no muscle layer. It is surrounded by the processes of proliferated retinal astroglia of the scar-like inner retina. Large areas of accumulations of tortuous microaneurysms in all different stages of development and secondary degeneration are another interesting observation in the inner retina of this case.

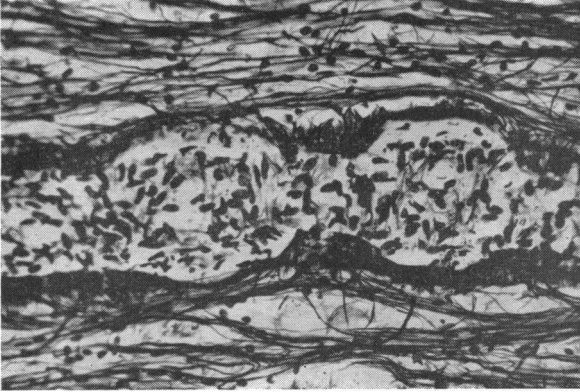


FIG. 11.—Occluded venous branch in Case 2. Hypertrophic lemmocytes are seen around the blood vessel. Hortegea method, photomicrograph. $\times 133$.

FIG. 12.—High-power view of new-formed, thin-walled blood vessel of the inner retina of Case 2. This is seen to be composed of endothelial cells. A hypertrophic astroglia has close relations to the wall. Hortegea method, photomicrograph. $\times 500$.

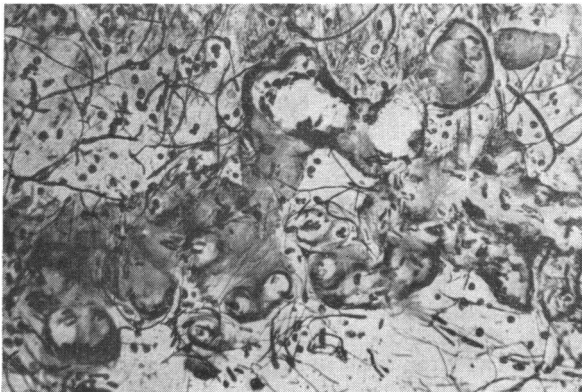
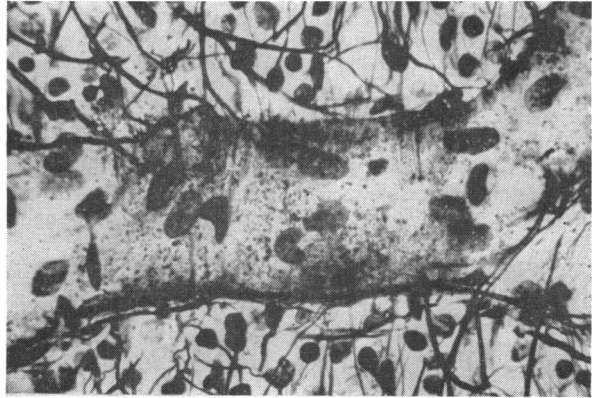

Fig. 13 shows a large conglomeration of capillary micro-aneurysms in a flat section. Some of the micro-aneurysms seen in this case are composed of endothelium only.

FIG. 13.—Area of tortuous new-formed blood vessels and micro-aneurysms in the inner retina of Case 2, seen in a transitional retinal section. Hortegea method, photomicrograph. $\times 133$.

Others, however, show extensive thickening of their walls by fibrosis and deposition of a hyaline-like substance (Fig. 14, opposite).

The appearance of the micro-aneurysms in this case is somewhat different to those seen in diabetic retinopathy. Fig. 15 (opposite) shows a part of the vascular conglomerations in this case with very advanced hyaline deposition at high power. The difference

FIG. 14.—High-power view of a complicated micro-aneurysm in the inner retina of Case 2. Proliferated endothelial cells are seen in its centre, and its wall shows hyaline thickening. Hortega method, photomicrograph. $\times 500$.

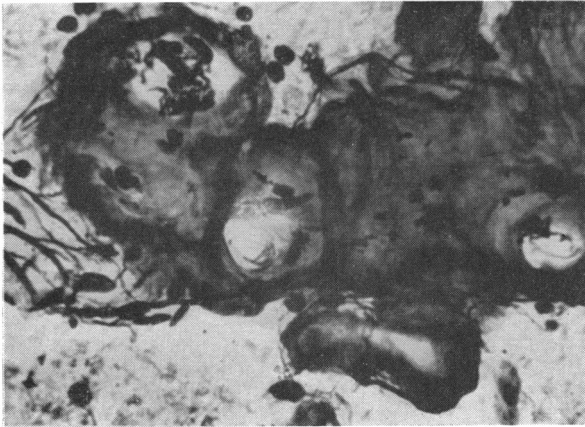
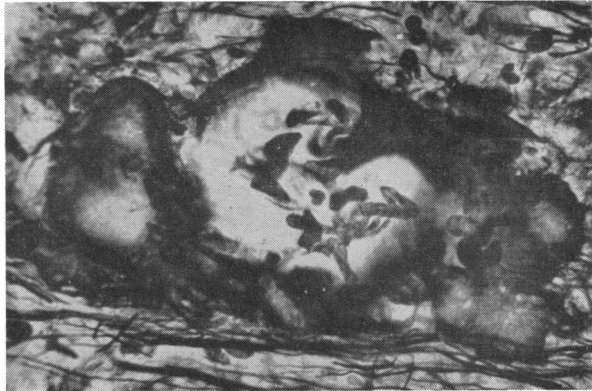
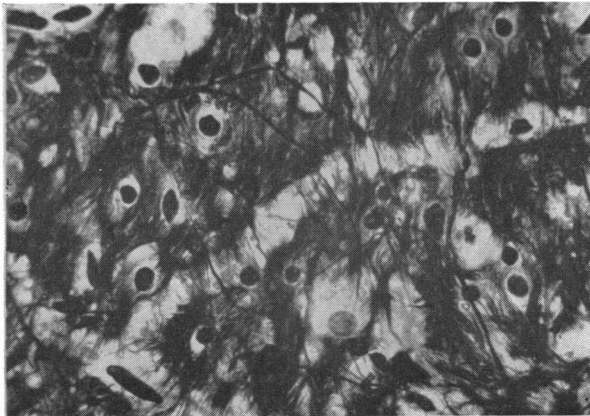FIG. 15.—High-power view of another vascular new formation of the inner retina of Case 2. The walls of this complicated formation show fibrous thickening and hyalinization. Hortega method, photomicrograph. $\times 500$.

between these micro-aneurysms and those seen in diabetes is that the micro-aneurysms in this case are mostly dilations of tortuous capillaries as a whole. Local bulging of the capillary wall as commonly seen in diabetes is rather uncommon in cases of old venous occlusion. Another interesting finding in this late case of venous occlusion is a new layer of glia on the inside of the inner limiting membrane of the retina—mainly in the area of the posterior pole (compare Wolter, 1956b, 1959b). Fig. 16 represents a flat section through

FIG. 16.—Flat section through the new-formed layer of proliferated glia on the inner surface of the retina seen in Case 2 at the posterior pole. Hortega method, photomicrograph. $\times 500$.



this layer of proliferating astroglia with the glia cells and their long processes. It has been pointed out before that such a layer of proliferating glia on the inner retinal surface is seen in many diseased eyes as a nonspecific change.

A beautiful demonstration of the blood vessels of the retina after venous occlusion is possible with the trypsin digestion technique of Kuwabara and Cogan (1960). Figs 17 and 18 represent an area of the retinal blood vessels of an eye with absolute haemorrhagic glaucoma after venous occlusion in a 53-year-old female. Many fusiform micro-aneurysms are seen and there is a definite loss of retinal capillaries.

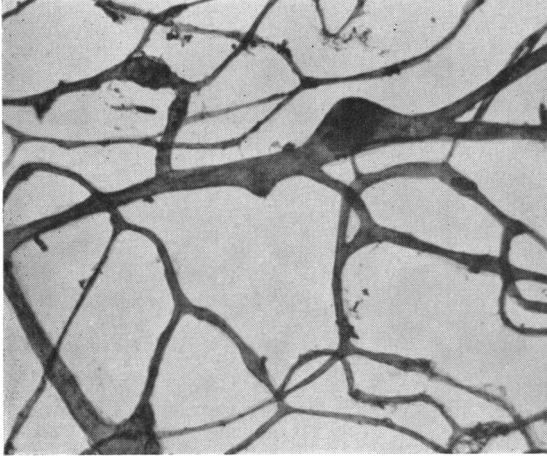


FIG. 17.—Typical micro-aneurysms of old venous occlusion, seen in the retina of a 53-year-old female with absolute secondary haemorrhagic glaucoma. Trypsin digestion, silver impregnation, photomicrograph.

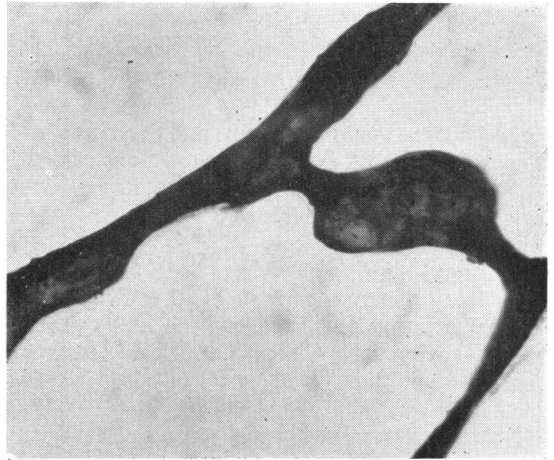


FIG. 18.—High-power view of fusiform micro-aneurysm of same retina as in Fig. 17. Trypsin digestion, silver impregnation, photomicrograph.

Discussion

This paper adds to the understanding of the retinal damage following central retinal vein occlusion. It is well known that the vision is not suddenly and completely lost after central vein occlusion. This is in contrast

to central artery occlusion, when sudden and total blindness results—unless there is some cilioretinal blood supply. In central vein occlusion most of the earlier damage is seen in the nerve-fibre layer; 2 months after the occlusion many fibres of this layer are already totally missing and others are interrupted. The damage of the nerve-fibre layer is not that of sudden necrosis, but of an irreversible slowly progressive nerve-fibre destruction that allows for reactive changes at the distal ends of the interrupted neurites. Such reactive changes are never seen in arterial occlusion, where sudden destruction of the nerve fibres and ganglion cells as a whole results in fragmentation and dissolution of the neurites without any reactive changes. The damage to the ganglion cells is not very severe 2 months after central vein occlusion; many ganglion cells are already missing and others are swollen and degenerated, but there are still many ganglion cells of normal appearance exhibiting cellular nuclei. The fact that many reactive terminal swellings of Cajal are seen in the nerve-fibre layer with their distal ends pointing towards the optic disc is further evidence that these cells are still active and able to react. It is not yet possible to state whether all the degenerative changes of the ganglion cells are due to ischaemia, or whether a part of the damage is retrograde degeneration following interruption of the corresponding nerve fibres. The fact that most of the swellings of Cajal point towards the disc while some point away from it offers further evidence for the existence of centrifugal (antidrome) nerve fibres in the human retina. (Compare Wolter, 1956.)

In a late stage of central vein occlusion the second visual neuron is totally lost, though the glia of the inner retina survives and forms a dense scar. The outer retinal layers are about normal even in old absolute glaucoma following central vein occlusion. This interesting fact is of no importance to the clinician, since the survival of the first visual neuron is of no practical use when its connecting second and third neurons are destroyed.

The finding after venous occlusion of relatively large patches of densely accumulated capillary aneurysms with interconnecting vascular channels within areas of intraretinal neovascularization and also of isolated micro-aneurysms is very interesting. Capillary micro-aneurysms and similar formations frequently occur after venous occlusions (Becker and Post, 1951). The shape and arrangement of the micro-aneurysms differs somewhat from those seen in diabetic retinopathy, but secondary thickening of the capillary wall by fibrosis and deposition of a hyaline-like substance occurs in these formations just as it does in those due to diabetes. The close relation to neovascularization of the following venous occlusion supports the view of Ashton (1951) and Michaelson (1954), that micro-aneurysms represent abortive attempts at neovascularization. The appearance of a new layer of proliferating glia on the retina of the posterior pole in old cases of occlusion of the central retinal vein is common and non-specific.

Summary

Two cases of relatively early and late central retinal vein occlusion are used as examples in a discussion of the retinal pathology following venous occlusion. In the early stages most of the neuronal damage is seen in the nerve-fibre layer, and the ganglion-cell layer is also involved. In the late stages the whole third visual neuron is missing. The outer retina shows little pathological change even in old cases with absolute haemorrhagic glaucoma. Isolated patch-like micro-aneurysms are found as late changes and seem closely related to the process of neovascularization.

REFERENCES

- ASHTON, N. (1951). *Proc. roy. Soc. Med.*, **44**, 747.
 BECKER, B., and POST, L. T. (1951). *Amer. J. Ophthalm.*, **34**, 677.
 KUWABARA, T., and COGAN, D. G. (1960). *A.M.A. Arch. Ophthalm.*, **64**, 904.
 MICHAELSON, I. C. (1954). "Retinal Circulation in Man and Animals". Thomas, Springfield, Ill.
 WOLTER, J. R. (1956). *v. Graefes Arch. Ophthalm.*, **158**, 235.
 ——— (1957). *Ibid.*, **158**, 524.
 ——— (1959a). *Amer. J. Ophthalm.*, **48**, 473.
 ——— (1959b). *Ibid.*, **48**, No. 5, pt. 2, p. 370.
 ——— (1960). *A.M.A. Arch. Ophthalm.*, **64**, 697.
 SCHARENBERG, K., and ZEMAN, W. (1952). *Arch. Psychiat. Nervenkrank.*, **188**, 430.