

PRIMARY TUMOUR OF THE OPTIC NERVE*
(Glioblastoma Multiforme)

BY

JOHAN SÆBØ

NORWAY

*Ophthalmological Clinic of the University
Hospital, Oslo (Professor Birger Malling)*

PRIMARY tumours of the optic nerve are rare. Nordmann states that Hidan estimates their frequency at 1:25,000 patients, Bennett at 1:35,000 and Lundberg at 1:68,000. Duke-Elder (1940) refers to information from Moorfields (Collins and Marshall, 1900) from which it appears that only two such cases were found among 388,000 patients, and that approximately 350 had been reported in the entire literature. Nordmann further states that Morax (1926) found only three cases of tumours of the optic nerve among 61 neoplasms of the orbit. In 1930 Mathewson pointed out that 80 per cent. of optic nerve tumours were gliomatous, and originated from the nerve itself, while the rest originated from the nerve-sheaths.

The first complete description of such a tumour was given by v. Graefe (1864), but much work has been done since that time in order to clarify the clinical picture of this condition, especially as regards the pathological findings and the terminology. The following quotations from Duke-Elder, however, suggest that considerable confusion still exists: "The nature of the neoplasms, however, remained controversial and in the earlier literature an amazing confusion of terminology is encountered: glioma, gliosarcoma, fibroma, fibrosarcoma, myxoma, myxosarcoma, sarcoma, neuroma, endothelioma, fibromatosis, and so on. They were variously considered mesoblastic or epiblastic, benign or malignant, a hypertrophy or a neoplasm, the pathological diagnosis being changed from time to time and different views being expressed as to their significance and prognosis." It therefore seems justifiable to report a case of optic nerve tumour and to discuss the problems of exact diagnosis.

Case Report. E.G., a 43 year-old woman, was admitted to the Eye Clinic with the diagnosis of orbital tumour. During the preceding four months the patient had noted a marked decrease in vision of the left eye, and simultaneous protrusion of the eye-ball. There was no history of pain or diplopia other than headache, and she stated that she had been perfectly well and able to do full-time work.

Physical examination, August 22, 1941. The patient appeared to be in good general condition. Local examination revealed the left eye protruding more than the right. Exophthalmometer readings were 21 mm. in the left eye and 18 mm.

* Received for publication, March 16, 1949.

in the right. The left eye could not be pressed into normal position. The mobility of the eyes seemed to be normal. No tumour could be palpated in the orbit. There was no evidence of metastasis to regional lymph nodes, nor any pulsation or *bruit*. The left eye was normal as to the cornea, anterior chamber and iris. The pupil reacted indirectly to light. Ophthalmoscopy demonstrated a mushroom-like disc, protruding approximately 9 dioptres. The retinal vessels were enlarged and tortuous, and there were several retinal hemorrhages.

The right eye was normal. Visual acuity: R. 5/5; L. amaurotic. Visual fields: Normal. Intra-ocular pressure: R. 24; L. 14 mm. Hg. Laboratory tests: Urinalysis negative. Serology (Wassermann) negative. Roentgenogram demonstrated a normal skull, left orbit and optic foramen. A week later another roentgenogram revealed a slight widening of the left optic foramen. On September 10, 1941 the patient was dismissed without treatment, but she was ordered to return at regular intervals. Approximately five months later the patient was admitted to the clinic for an examination as the left eye had become red and painful. *Physical examination January 23, 1942*: The protrusion of the left eye was unaltered, but the mobility was somewhat reduced.

L. eye: There was ciliary congestion with the beginning of a *caput medusae*. The cornea was clear. The iris was hyperaemic and showed small haemorrhages. Ophthalmoscopically there were no significant changes from August 22, 1941. R. eye: Normal findings. Vision 5/5. Visual field normal. The intra-ocular pressure now was 24 R., and 33 mm. Hg. L. Roentgenogram was taken on January 1, 1942, with the report that since August 8, 1941, a definite widening of the left optic foramen had appeared, and that the outlines of the foramen were blurred.

Summary of examination:

- (1) Proptosis of the left eye straight forward and irreducible.
- (2) Complete failure of vision had developed simultaneously with the protrusion.
- (3) Papilloedema with haemorrhages.
- (4) No history of diplopia. Mobility was at first normal, but decreased slightly.
- (5) Pain in the eye occurred in association with increased ocular tension.
- (6) Widening of the optic foramen over a period of approximately five months.

The patient had been in good health, and there was no evidence of any other diseases.

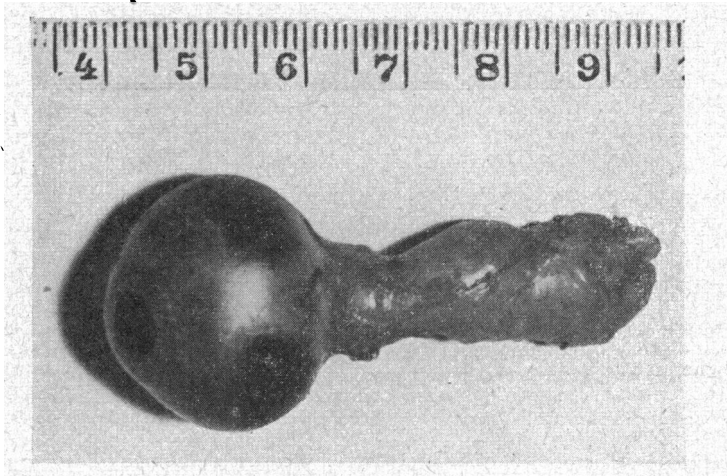


FIG. 1.

The enucleated eye with fasciculus opticus, which has circular constrictions and spool-like swellings.

These findings indicated a tumour of the left optic nerve.

As the eye was afflicted with increased intra-ocular pressure, blindness and pain, we decided to excise it together with the suspected tumour. During the operation one could feel enlargement of the optic nerve with scissors, and by drawing the eyeball forward as much as possible, one had the impression of cutting the nerve behind the tumour. A subsequent pathological examination demonstrated that removal of the tumour had been incomplete. The patient was told this, and

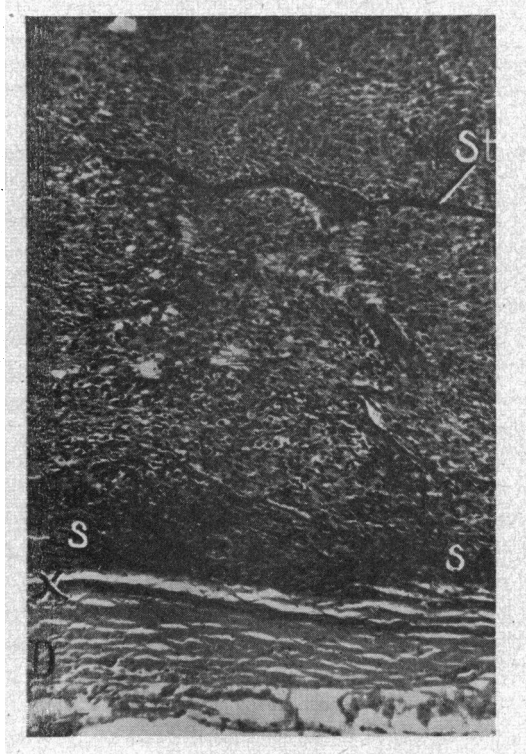


FIG. 2.

Expansively growing tumour limited to fasciculus opticus, which is surrounded by leptomeninges (x) and dura (D). Septa (St) with abundance of connective-tissue and blood-vessels give the tumour tissue a lobular appearance with some dense areas of small cells (s-s). Paraffin preparation. Hematoxylin-eosin staining. Magnified $\times 73$.

that an intra-cranial operation would be necessary. She opposed this proposal, and was then dismissed from the clinic one month after the operation, during which time she received X-ray treatment. She was also advised to continue with X-ray therapy in her home town.

The patient subsequently returned twice for control during the first six months. She had felt well, and, was working at her farm. The other eye was normal, and there were no signs of intra-cranial complications. She now failed to return for her appointment, and her physician reported that the patient died one year after the operation, with increasing cerebral symptoms. No autopsy was performed.

After operation the enucleated eye and the tumour were sent to the Pathological Laboratory of the University Clinic. Dr. Jan Cammesmeyer made the following report: Fasciculus opticus is approximately 3.5 cm. long, and its thickness varies from 0.8-1.3 cm. (See Fig. 1.)

The considerably enlarged fasciculus opticus shows a few circular constrictions. The rostral part is circularly constricted, and in a longitudinal section the tumour seems to be separate from the bulbous. The tumour is of a yellowish-white colour, mainly round, and is entirely surrounded by a capsule. It is of hard elastic consistency. The wall of the eyeball is not infiltrated.

Microscopic examination showed that the dura mater surrounding the fasciculus was not infiltrated by tumour cells. Lymphocytes and fibroblasts fill the inter-fibrillar spaces of the leptomeninges. The intrameningeal fissures are obliterated by expansion of the tumour. The original structure of the fasciculus opticus is

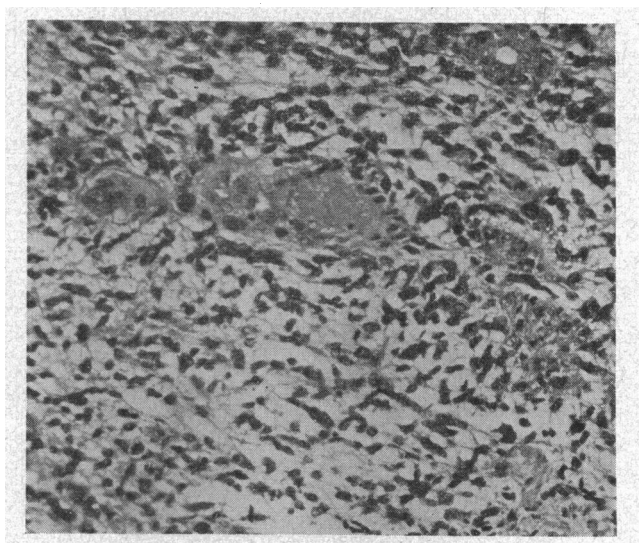


FIG. 3.

Polymorphous tumour tissue without definite polarization of the cells. Paraffin preparation. Hematoxylin-eosin staining. Magnified $\times 180$.

completely replaced by a neoplastic tissue rich in polymorphic cells. Irregular lobules of tissue are limited by occasional vascularized broad fibrous septa which split up the fasciculus as far as the lamina cribosa.

The number of cells varies considerably in the different parts of the tumour. In the central portion of the longitudinal section through the fasciculus, and in some places near the surface there are areas with densely packed, relatively small cells with round, hypochromatic nuclei (Fig. 2).

Other lobules are not quite so rich in cells, and here the individual cell outlines are more clearly demonstrated (Fig. 3).

There is considerable variation in the shape and size of the individual cells as well as in their nuclei (Fig. 4). Various numbers of cytoplasmic processes arise from the different cells, and in some places fuse with the adventitia of the vessels. Besides the unipolar, bipolar and tripolar cells which resemble immature glial cells, spongioblasts and astroblasts respectively, one sees multipolar cells with a better developed cytoplasmic pericaryon which resemble mature astroglia. The

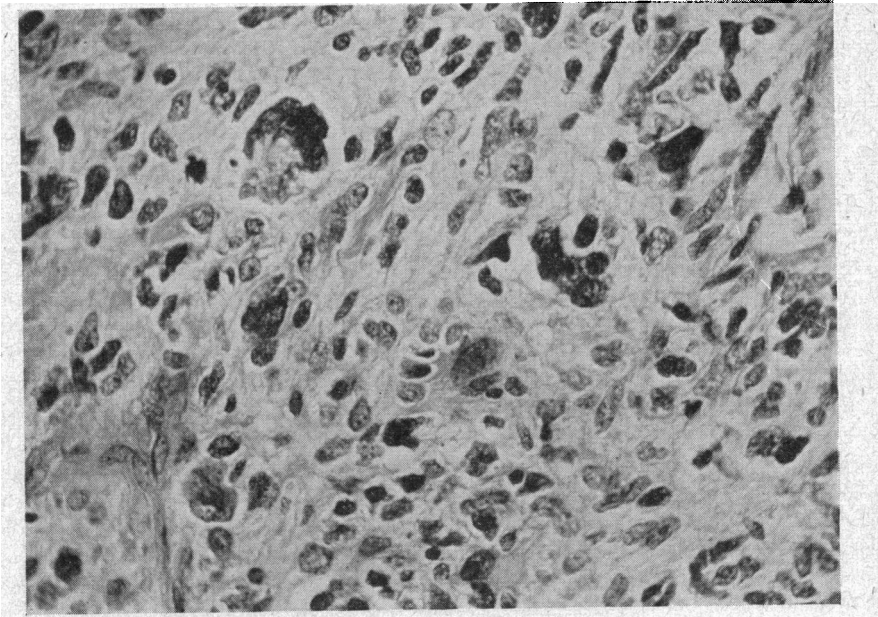


FIG. 4.

Slide demonstrating the variation in size, shape and staining reaction of cells and their nuclei. Note also the tumour's giant-cells. Paraffin preparation. Stained with hematoxylin-eosin. Magnified $\times 400$.

cells show no definite orientation, giving off their processes in all directions, although these are often closely related to the perivascular membranes. Some of the nuclei are very large. Mitoses are frequent, and occasionally incomplete. Multi-nucleated forms are also present.

In one area of the cross-section of the cerebral portion of the nerve the tumour tissue is looser and infiltrated with a number of glial fibres. Palisade formations of pyknotic nuclei surround small, oblong, circular and triangular areas of necrosis. Besides these distinctly degenerated areas one can see throughout the whole tumour tissue small areas of various size in which the cells are not degenerated but show definite pyknotic nuclei.

There are mild reactive changes in the vessels in some places, with increase in the number of endothelial nuclei.

No nerve fibres were found in the paraffin sections examined, nor were there any melanin-pigmented cells.

Conclusion : In the pathological examination of the thickened fasciculus opticus an expansively growing and polymorphic tumour is found, with numerous primitive cell-forms of gliomatous types, continuing to the edge of the resection. Diagnosis : Glioblastoma multiforme.

Discussion : As no symptoms or signs were found indicating

that the tumour might be a metatasis from other organs, it was presumed to be primary. As mentioned above, uncertainty exists as to the classification of the optic nerve tumours. Hence it has been particularly difficult to decide upon the origin of the various neoplasms, e.g., whether they were intraneural (ectodermal) or whether they originated from the inner nerve-sheaths (mesodermal). Rønne (1931) holds that this confusion originates from the fact that in a great number of cases the nerve and its inner sheath are both affected.

Hudson (1912) divided these tumours into three types: I, Gliomatous; II, Endothelioid and III, Fibromatoid, of which the first originated from the nerve itself, and the last two from the sheaths.

Duke-Elder (1940) gives the following classification: I, Essential (Ectodermal) tumours of the nerve—Gliomata; II, Meningiomata, mesodermal tumours of the sheaths. (a) Endotheliomata and (b) Fibromata; III, Neuro-ectodermal tumours. (a) neurinomata and (b) malignant melanomata.

Although doubt may exist as to the exact pathological diagnosis in the present case, it most likely belongs to group I, gliomata. The microscopic picture is, however, characterized by considerable polymorphism, and therefore the diagnosis glioblastoma multiforme is made. It also appears that the leptomeninges were infiltrated by lymphocytes and fibroblasts, while the dural sheath was free. Likewise the eyeball itself was not infiltrated, but the tumour spread backward to the brain. In contrast to gliomata, the endotheliomata usually show a marked tendency to infiltrate the dural sheath and hence grow into the orbit. There are, however, some peculiarities in the clinical course of this case. In the literature it is stressed that the gliomata are of such slow development that they may even be considered benign. In the present case the progress of the tumour was rapid, and death occurred approximately two years after the onset of symptoms. In harmony with this view is the widening of the optic foramen on repeated roentgen examinations during five months.

The disease appeared in the present case at a relatively late age, 43 years. Other authors have shown that gliomata of the optic nerve usually start at an earlier age. Hence, Hudson (1912) found that 75 per cent. of the cases occurred in the first decade, and in 88 per cent. before the age of 20. The same author mentions also that endotheliomatous tumours, in contrast to the gliomatous, usually appear later, with an average of 35 years.

The other signs were as expected in this type of optic nerve tumour. Exophthalmos was present in a moderate degree. The

proptosis was straight forward, which is typical of optic nerve tumours and an important sign in the differential diagnosis from other orbital growths. Failure of vision, which in the present case occurred simultaneously with the proptosis, progressed rapidly to blindness. This is a usual feature in these tumours, and Braunschweig (1895) demonstrated that 33 of 44 cases with optic nerve tumours were amaurotic. Reduction of vision in such cases may also be due to secondary changes, e.g., papilloedema and haemorrhages. As the affected eye was blind at the first examination, no defect in the visual field was found. At an earlier stage such may be found, and by spread of the disease to the chiasma, such a defect may even be found in the other eye.

Diplopia is rare in this condition, and this accords with the fact that mobility of the eye may long remain unimpaired. By the time mobility is retarded, the eye may be amaurotic, and hence this symptom is precluded. In the present case there was no history of diplopia.

Most gliomatous tumours of the optic nerve originate in the intraorbital part of the nerve. The rule is that they tend to grow neither into the dural sheath nor into the eyeball. On the other hand they frequently tend to grow backwards through the optic foramen and towards the brain. This tendency leads to widening of the optic foramen, an important sign, which was noted in this case.

Prognosis and Treatment: In spite of the fact that gliomatous tumours of the optic nerve usually develop slowly, the danger of intra-cranial extension exists. Likewise the exophthalmos may become so pronounced as to induce necrosis of the cornea and panophthalmitis.

As these tumours do not as a rule metastasize, radical excision carries a good prognosis. Early diagnosis and adequate removal are important. As these tumours seldom infiltrate the eyeball itself, they may be removed without excising the eye. The usual techniques are those of Lagrange, Knapp and Kroenlein. As all these methods greatly damage the vessels and nerves, subsequent excision of the eye is frequently indicated.

If widening of the optic foramen, suggesting intra-cranial extension of the tumour, is found, or if it is evident that the tumour has been incompletely removed, an intra-cranial operation is advisable (Dandy, 1922; Martin and Cushing, 1923). Before this second operation is done, however, the wound of the first should be healed. This precaution is advised in order to prevent infection and loss of cerebro-spinal fluid. For the same reason secondary enucleation after a cerebral operation must be postponed.

Both Rönne and Duke-Elder are more optimistic in their statements concerning similar cases. Thus Rönne says: "Auf Grund der relativ grossen Benignität der Sehnerventumoren kann das Operationsresultat befriedigend sein, selbst, wo eine völlige Entfernung des Gewebes am Foramen opticum nicht gelingt."

SUMMARY

The case of a 43-year-old woman with a "glioblastoma multiforme" of the optic nerve is given.

The usual symptoms and signs of such a tumour were present. A widening of the optic foramen was found on repeated roentgenograms. The tumour was excised together with the bulbus. Unfortunately pathological examination revealed that the operation was incomplete. The patient refused to have a secondary intra-cranial operation. In spite of post-operative X-ray therapy she died one year later from intra-cranial complications.

The pathological picture was characterized by polymorphism, and the diagnosis was "glioblastoma multiforme." The tumour was considered to be primary.

Unusual features in this case were the appearance of the tumour at a relatively late age, its rapid course and its polymorphism.

REFERENCES

- BRAUNSCHWEIG, P. (1893).—Die primären Geschwülste des Sehnerven. *Arch. f. Ophthalm.*, **39**, 1.
- COLLINS, E. T. and MARSHALL, C. D. (1900).—Diseases of the Optic Nerve. Two Cases of Primary Neoplasm of the Optic. *Trans. Ophthalm. Soc. U.K.*, **20**, 156.
- DANDY, W. E. (1922).—Prechiasmal intracranial Tumours of the Optic nerve. *Amer. J. of Ophthalm.*, **5**, 169.
- DUKE-ELDER, S. (1940).—Tumours of the Optic Nerve and its Sheaths. Text-Book of Ophthalmology., **3**, 3076.
- EILLER, P. (1930).—Der Sehnerv, Nervus opticus. *Kurzes Handbuch der Ophthalm.*, **1**, 135.
- GRAEFE, V. (1864).—Geschwülste des Sehnerven. *Arch. f. Ophthalm.*, **10**, 193.
- HUDSON, A. C. (1912).—Primary Tumours of the Optic Nerve. *Roy. Lond. Ophthalm. Hosp. Rpts.*, **18**, 317.
- MARTIN, P. and CUSHING, H. (1923).—Primary Gliomas of the Chiasm and Optic Nerves in their intracranial Portion. *Arch. of Ophthalm.*, **53**, 209.
- MATHEWSON, G. A. (1930).—Primary Tumours of the Optic Nerve. *Amer. J. of Ophthalm.*, **13**, 880.
- NORDMANN, H. (1939).—Les tumeurs du nerf optique. *Traité d'ophtalmologie.*, 751.
- RÖNNE, H. (1931).—Die Geschwülste des Sehnerven, Papille und Opticus bis zum Chiasma. *Kurzes Handbuch der Ophthalm.*, **V**, 751.