

THE BRITISH JOURNAL
OF
OPHTHALMOLOGY

DECEMBER, 1932

COMMUNICATIONS

ANTERIOR DIALYSIS OF THE RETINA:
DISINSERTION OR AVULSION AT
THE ORA SERRATA

BY

J. RINGLAND ANDERSON

MELBOURNE

PART II

Spontaneous Dialysis

Leber stated that he found spontaneous anterior avulsions quite frequently. Nordenson (1887) in his book discusses fully the retinal ruptures in the Göttingen clinic. Amongst 45 cases in which a tear was found, in seven there was a large rent in front of the equator. Deutschmann (1899) claimed that spontaneous dialysis was a common occurrence and more frequently seen than a tear in the retina itself, "die Risse in der Kontinuität." "The more attention one pays to this lesion the more frequently one finds it and is astonished at the great number of cases in which it is observed." Deutschmann found avulsions regularly at the lower retinal border, never above, while tears elsewhere were usually in the upper half. Leber endorsed these findings.

An anterior retinal dialysis may be accidentally found during the routine examination of the periphery of an eye which has produced no symptoms of disorder. Particularly is this apt to

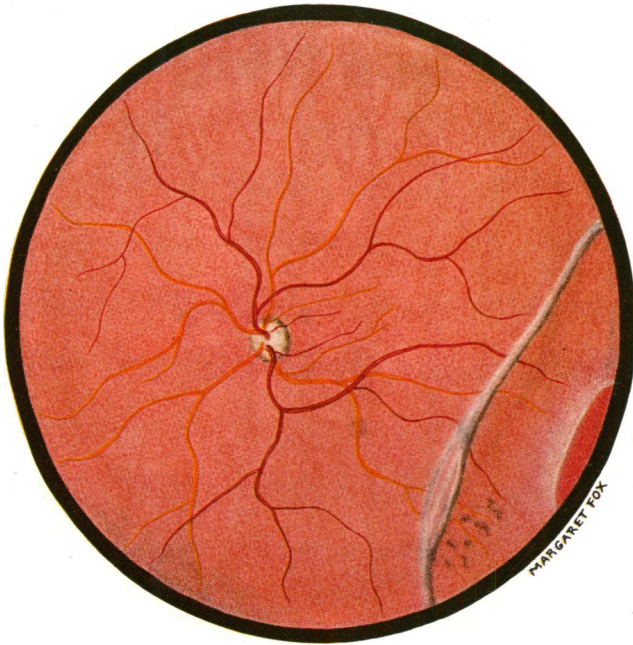
be so if the fellow eye is or has been affected by a dialysis. The following history illustrates this point:—

J. B. was aged 29 years when he first noticed a film over the right eye and a defect in the superior nasal field. Lamp posts appeared distorted and certain objects appeared magnified. His field loss increased but his oculists advised against operation. When he was 14 years old his nose had been broken in one of many fights. He played football till he was 21 years of age. He consulted me five years later. An almost complete detachment was found with a typical large dialysis in the inferior temporal quadrant. He noticed that small illuminated spots moved across his right field from time to time. This symptom is relatively common amongst patients with detachments. Examination of the left eye, which appeared normal to the patient, revealed a most unusual lesion. An irregular band, grey in colour and somewhat translucent, was found in the inferior temporal quadrant. It ran from 3 to 7 o'clock. It was in focus with +6.0 D. lens and the retina on each side of it with -3.0 D. lens. At first it was considered to be the edge of a dialysis, but it was found that the fine peripheral retinal vessels ran deep to it. It disappeared in the vicinity of the ora serrata at its extremities and did not reach the retina posteriorly. Its most central portion was 4 D. D. from the the ora serrata. Diffuse pigmentation was present in the retina close to its lower extremity. Peripheral to it was a typical small dialysis which extended from 4 to 6 o'clock. At no point was the margin of this dialysis more than 1 D. D. from the visible limits of the fundus. Neither of these lesions produced a defect in the field to a 1 mm. white test object. The nature of the former is unexplained.

The latency and the bilateral occurrence of retinal dialyses are features which will probably grow in importance with further clinical examination.

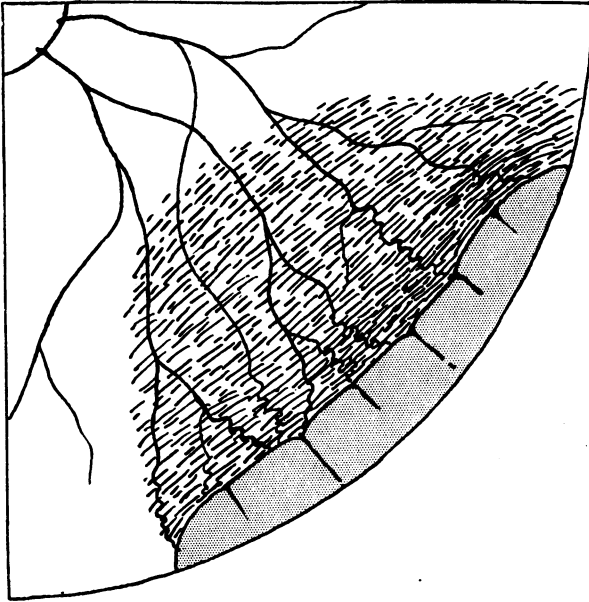
For a long time oculists have been familiar with choroidal warts and with scattered areas of fine pigment and small foci of retino-choroidal atrophy in the periphery of fundi, particularly in middle and old age. Gonin's and Vogt's researches have re-awakened interest in the periphery of the retina. This has produced amongst other things a realisation of the frequency of anterior retinal dialysis—another point realised by the careful investigators of fifty years ago, but apt to be forgotten in the days of complex apparatus, and quick work.

Leber stated that he had seen eight cases of spontaneous anterior dialysis and six associated with trauma. Gonin described and illustrated retinal "désinsertions" in the French Encyclopaedia of Ophthalmology (1906), and in 1920. He summarized the characteristics of the condition in 1930 (*a*) The prolonged disappearance of this condition from the literature makes retinal dialysis the Rip van Winkle of ophthalmology.



Fundus of Mr. J. B., showing a small latent dialysis and detachment, and a most unusual band of semi-opaque tissue in the anterior part of the vitreous. A small melanoma of the choroid is present below the macula. The other eye presented a complete detachment and an extensive dialysis.

It has been seen that an anterior dialysis when secondary to cyclitis is usually due to traction from in front and medially. The appearance of a spontaneous dialysis, especially when arcade-like,



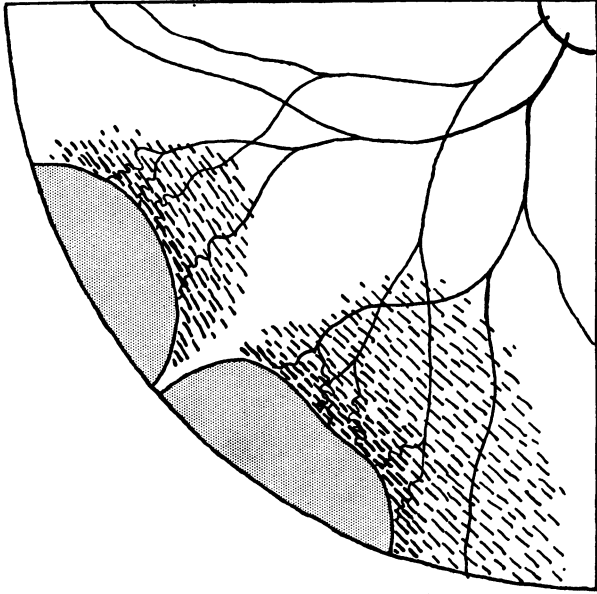
Arcade-like or festooned anterior retinal dialysis.

gives the impression of traction from behind. In the absence of a visible mechanism that could produce posterior traction, one concludes that some cause such as cystoid degeneration, traumatic cyclitis, direct trauma or a broad and firm vitreous base, separates the retina from the pars ciliaris retinae and so produces dialysis, and that the retinal vessels then draw the retina backwards.

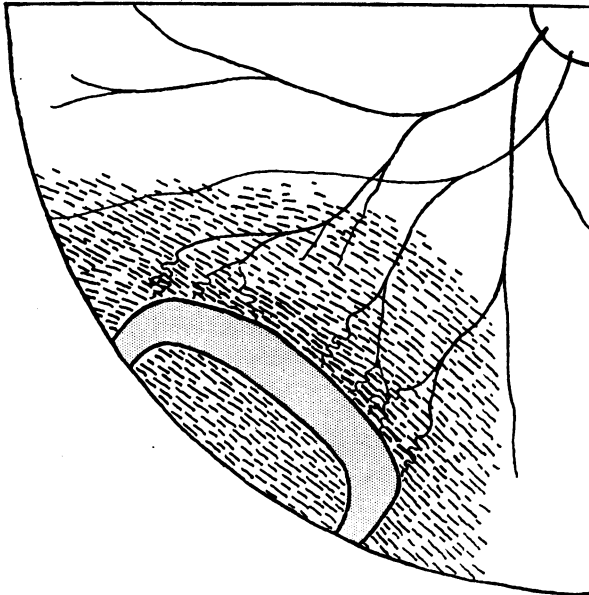
Signs and Symptoms

Dialyses when small may be missed and therefore they have appeared infrequently in the literature. "Un petit repli rétinien parallèle à l'ora serrata m'a plus d'une fois trahi la présence d'une minime désinsertion." (Gonin.) When a dialysis is due to trauma it may be hidden by haemorrhage. Dubois (1929) considered that a rupture at the ora following trauma could heal rapidly and completely, provided that the vitreous was normal. In a series of 49 cases of retinal detachment reported by Jeandelize and Baudot (1931), 37 were found to have tears and of these 4 were dialyses.

Only perimetry with a small test object is of value because the field is usually full to one of 5°. Lagrange (1931) assumed that in a certain patient no dialysis was present because the field though



Two adjacent anterior retinal dialyses, each with separate detachment.



Anterior retinal dialysis with peripheral tongue—
"à lambeau." Gonin.

restricted to a dull white stimulus was full to a 1.5 mm. luminous object. It is doubtful if one is justified in such an assumption unless the angle subtended by the object is minute. Reference to certain of the fields published with this paper will demonstrate the value of perimetry with minute objects.

Anterior dialyses of the retina may vary greatly in size. Arruga (1929) reported and illustrated a double "désinsertion" in one eye and an unusual form which showed a tongue and was crescentic in shape, "désinsertion à lambeau." Gonin has found that dialyses tend to be situated symmetrically when bilateral. Amongst his 25 cases, six were bilateral. In Shapland's series of 37 patients, three had bilateral dialyses and in one eye there were two dialyses each with its own separate detachment.

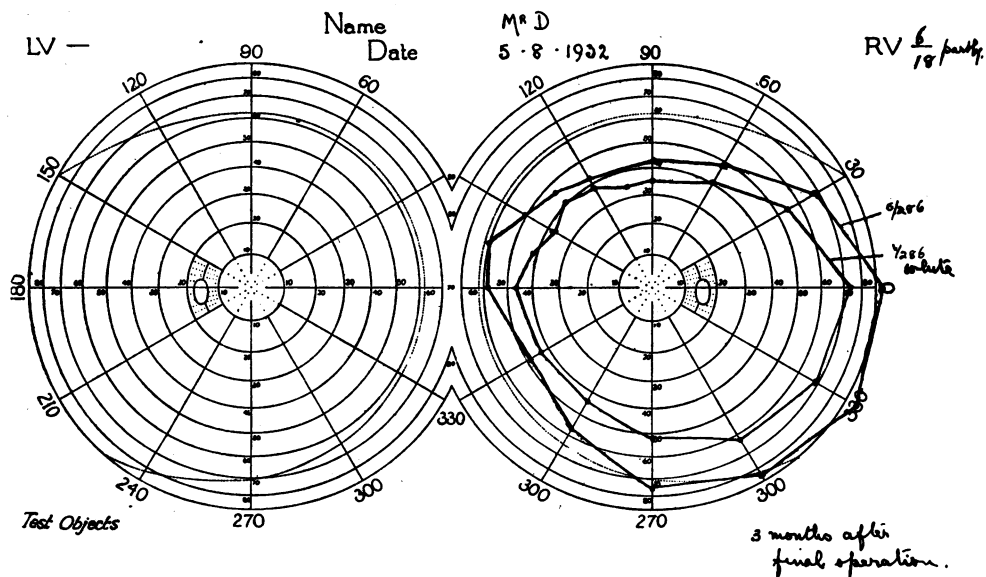
Juler (1931) reported a male patient, aged 27 years, with a dialysis of the right eye of eighteen month's duration, and a symmetrically situated dialysis in the left eye of 6 month's duration. A single puncture of each eye at 6 o'clock, 9 mm. from the limbus, led to re-attachment. Seven months later the vision was R. = 6/24, L. = 6/5 and the retinae were firmly fixed. Parsons (1917) reported a female patient, aged 17 years, with a bilateral detachment. In one eye the temporal half and in the other the inferior half was affected. He suggested an advanced stage of cystic degeneration as a probable cause.

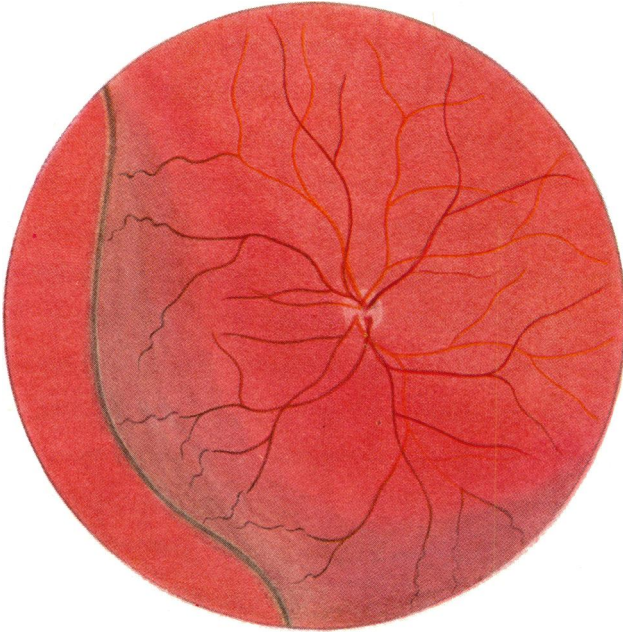
As a rule the patient complains of blurred vision which commenced in one corner of the visual field. Usually the superior nasal quadrant is the first area to be affected. Most patients have observed floating dark spots before the eye for some time prior to the appearance of the mist. The vitreous towards the "désinsertion" usually shows minute opacities. At times larger dark masses run in a radial direction across the tear.

Even though the dialysis is large the central part of the detachment is very shallow and it very gradually becomes more elevated towards the tear. Sometimes it is difficult to delimit the detached area. If however a clear choroidal pattern is present, the line of its disappearance will show the limits of the detachment. Particularly in those cases in which the tear is below is there this tendency to a very gradual slope. More often when the tear originates towards the horizontal meridian is there a tendency to an earlier interference with the macula and the formation of abrupt folds and white retinal reflexes. The absence of these folds and the shallow nature of the detachment in the type which commences below have caused a difficulty in diagnosis. In such cases in the past a careful search of the periphery might have revealed a tear and the provisional diagnosis of central retinal oedema or tuberculous or even choroidal tumour upset. Close to its edge the detached retina appears grayish in colour, and it mounts steeply

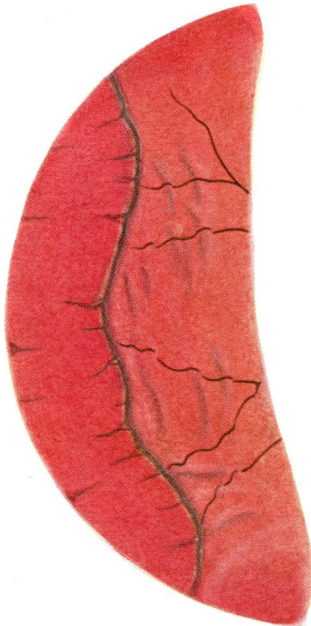
by a series of small folds made clear by the marked tortuosity of the overlying vessels. The edge of the retina varies in appearance according to the mode of illumination. While clearly focused in a convergent beam it is white, in less intense light or if seen by reflected light it may appear dark. The edge often appears slightly rolled over towards the vitreous and therefore looks broad. At times fine tags—of varying length—run forwards from it. One finds in some cases, especially towards the extremities of the tear, the ends of other tags which run from in front towards the posterior edge. When tags are complete the direction of the retinal edge may be altered so that an arcade-like appearance is produced. These tags, when wide and flat, may appear of the same colour as the retina, as a rule, however, they are dark and black. If these tags are complete the appearance suggests that more than one dialysis is present. Deutschmann referred to incomplete and arcade-shaped dialysis as well as to retinal shreds suspended in the periphery. Gonin (1906) also recorded instances of an arcade-like appearance. The anterior end of the retina appeared to be drawn posteriorly in places like a curtain. Such an appearance was found in the following case and is illustrated in Plate 2.

Mr. D. The patient, an emmetrope, aged 23 years, for at least three months had noticed a blur over the nasal field of the right eye. He was kindly referred to me by Dr. Hogg, of Tasmania. He had received conservative treatment for a period of six weeks. He appeared to be in perfect health and had had no illnesses. Ten years previously he had been struck above this eye.





Mr. L. Representation of retinal detachment and extensive anterior retinal dialysis. Re-attachment followed one operation. Plan of operation. Fields of same (see p. 718).



Mr. D. Anterior retinal arcade-like dialysis. Stereophotographs of retinal detachment (see Plate).

Coloured Drawings by Miss Margaret Fox, Melbourne.

by a stick thrown as a spear but he attributed no visual loss to this or any other injury. He had not observed any spots before his eyes. He had a very extensive detachment of the temporal and lower retina of the right eye. It was divided by deep clefts and along the abruptly sloping margins the retina showed broad white bands. An anterior dialysis extended from 7:30 to 10:15 o'clock. The margin of this rent was irregular and many tags, some of which appeared red and transparent, ran from it towards the periphery. Ends of other tags appeared, as if they came from the anterior margin of the dialysis, and ran posteriorly. His vision was reduced to counting fingers at several feet and only his temporal field of vision remained. At operation two cautery punctures were made and the retina became completely re-attached. Two weeks later however, a small detachment was found towards 11 o'clock. This disappeared when the eye was tied up and it was found that small patches of pigment were present where the retina had re-attached above and below. Later the lower retina detached and though no new rent was visible punctures were made just above and below the original limits of the dialysis. The retina appeared to go back into position but two weeks later it was detached again and it was interesting to observe that the original white retinal folds had returned. A third operation was done at which the surface of the sclera just behind the ora serrata from 9 to 11 o'clock was touched with the cautery and punctured at two points. Immediately after the operation the detachment in this vicinity was much flatter but still present. In the extreme periphery one was able to obtain a very clear view of the ends of the ciliary processes but the anterior margin of the dialysis could not be seen. If this operation had failed to re-attach the upper retina a similar method would have been adopted in dealing with the lower area of detachment. However, the retina completely re-attached and three months later the vision was 6/18 partly and the fields as shown.

I have not been able to see the anterior margin of a dialysis. In none of my cases could any sign of choroidal disorders be seen, though the pattern of the exposed choroid could be clearly focused in the younger patients.

The separated retina may be so displaced that it may obscure the disc and reveal its external surface to the observer. Baquis (1896), Scheffels (1891), Constantin (1904), Ballantyne, Juler and Goulden (1931) observed this. When this occurs the retinal vessels are not distinctly seen.

Monocular Diplopia

Such an extensive dialysis of the retina may lead to a very interesting form of monocular diplopia. It appears to be very uncommon. Leber refers to two cases and I have found no other

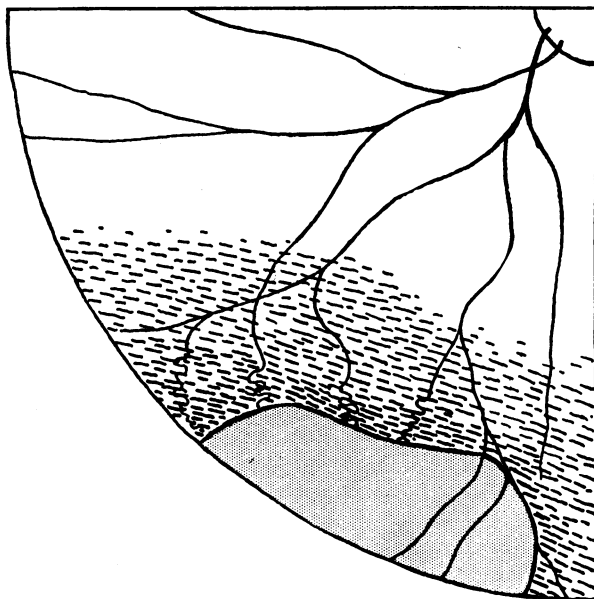
cases in the literature. The detached retina becomes folded over the intact retina and the layer of rods and cones of the former is exposed. The image due to stimulation of this layer is projected as if it was still lying on the choroid and therefore it is inverted. In Baquis' patient (1896) objects on the right were projected to the left and a wheel turning in one direction would appear to rotate in the opposite. In Costentin's patient (1904) the upper retina was superimposed on the lower and a false image was seen below the true one especially when the test object was 30° above the horizontal plane. If the object was moved vertically the false image moved in the opposite direction. The lower the object, the less this became until at last the images coincided. The diplopia lasted for several days, disappearing when the detachment became total. At first in Baquis' patient only the retina which was uncovered by the displaced portion appeared to function. Six months later however, the displaced portion became capable of indistinct vision. When the test object was in a certain position both it and the underlying portion were stimulated. The resulting diplopia could be elicited for three months when a cataract rendered the vision too defective. It is worthy of note that the retina retained partial vision for so long when separated from the pigmented epithelium. Leber (1916g).

SECONDARY DIALYSIS

There appears to be a type of dialysis which may follow either cauterisation or the contraction of a non-operative retino-choroidal focus. Rubbrecht reported that he found a dialysis in a highly myopic man soon after cauterisation of an isolated retinal tear. Schoenberg, after an ignipuncture of the inferior half of the globe, found a dialysis in the superior temporal quadrant in a man, aged 33 years. He also reported a girl, aged 12 years, with rapidly progressive myopia who developed in the superior temporal quadrant a dialysis which extended whilst under observation. It was a degenerate eye that collapsed and developed a deep cloud in the vitreous after a single puncture. Gonin reported a woman, aged 35 years, with an inferior temporal dialysis who had had a macular choroiditis a year before. He also reported a non-myopic young man, who, after four punctures made to create a barrier for a dialysis, developed retinal folds, one of which extended from the inferior nasal sector to the superior temporal periphery. In the latter area a large detachment appeared, and a new tear developed close to and parallel with the ora serrata. Gonin classes it as an example of a serious type of secondary tear that is produced by extreme retinal tension and counter-traction of the vitreous. Gonin also reported a highly myopic girl, aged 12 years, who developed a dialysis in the inferior half of one eye 3 years after two punctures

had been made to close a small tear in the inferior temporal periphery. Shapland, amongst 11 cases of relapse after treatment for detachment, found one with a large secondary dialysis at a point remote from the original hole. A further series of four punctures failed to close it.

The characteristics of the incidence of anterior dialysis do not apply to this group. In this small series three are female and the



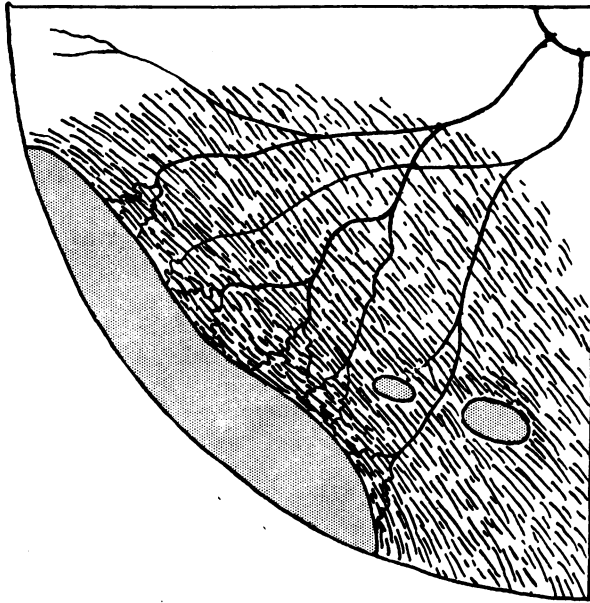
Secondary anterior retinal dialysis crossed by two fine vessels.

superior half of the globe is affected in three. I have only observed this condition twice; each patient was highly myopic and the margin of the dialysis in one was torn and irregular. In both, the dialysis was found diametrically opposite the original puncture.

The following is a brief history of one of these patients:—

This patient was kindly referred to me by Dr. F. Newman of Melbourne. She was a myope, aged 60 years. Six years earlier the right retina had become detached and after 18 months' time the vision was perception of light and opaque media hid the fundus from view. Three weeks before I saw her, objects in the left inferior temporal quadrant were found to be blurred. Central vision with correction -2.5 D. sph., -1.0 D. cyl. = $6/9$. An extensive detachment was found of the nasal and inferior areas of the retina. After two days the temporal area became involved. The lens showed

extensive peripheral opacities and the vitreous contained a few coarse opacities and many fine ones. A zone of very fine black vitreous dots was found in the anterior portion of the vitreous. The clearness of the posterior vitreous suggested that it was replaced by fluid. Two small oval holes were found in the superior nasal quadrant, lying on a very sloped surface. They were situated at 10·45 o'clock and were 2·75 D. D. from the ora serrata. The larger



Anterior retinal dialysis and two oval holes in associated retinal detachment.

hole was 1/4 D. D. in length. The detachment was least marked in the vicinity of the tears and most marked below where it was globular. A band of pigment lay close to the larger hole. At operation after the usual preparation, a stud was passed into the scleral wound and it was found to lie close to the larger hole. Cauterisation was done at this site. There was a very marked reaction, even the lids becoming oedematous. One month later the retina was found to be in position except in the temporal periphery. Many searches for another hole were made in the superior temporal quadrant, but the lens opacities greatly obstructed one's view. After two months the patient was allowed out of bed and once the erect posture was assumed, fluid collected below. At last in this area one found an extensive secondary dialysis. It extended from 6·30 to the neighbourhood of 5 o'clock but its temporal limit was obscured by lens

opacities. The margin of the dialysis was in focus with +6.0 D. and it appeared to be 2.0 D. D. from the "ora serrata." As it lay close to the insertion of the inferior rectus muscle the tendon was divided and a cauterisation 5 mm. in width was made 9 mm. from the limbus. The lower retina returned to its normal position. However, the temporal retina remained detached and it was decided to cauterise part of the surface of the globe in the superior temporal quadrant and to make two punctures. This was done but unfortunately the lower temporal retina did not re-attach.

In reviewing this patient's history one considers that the delay between the operations was too long. If the retina does not re-attach during the first two or three weeks after operating, nothing is gained by keeping the patient in bed, for as soon as the patient gets up the fluid will descend again. It is wiser to allow the patient up and search for the remaining hole. This patient described the frequent appearance of numerous bright objects which appeared in one part of the visual field and always moved along the same course. This suggested some form of retinal irritation in the superior temporal quadrant but no adequate cause could be found.

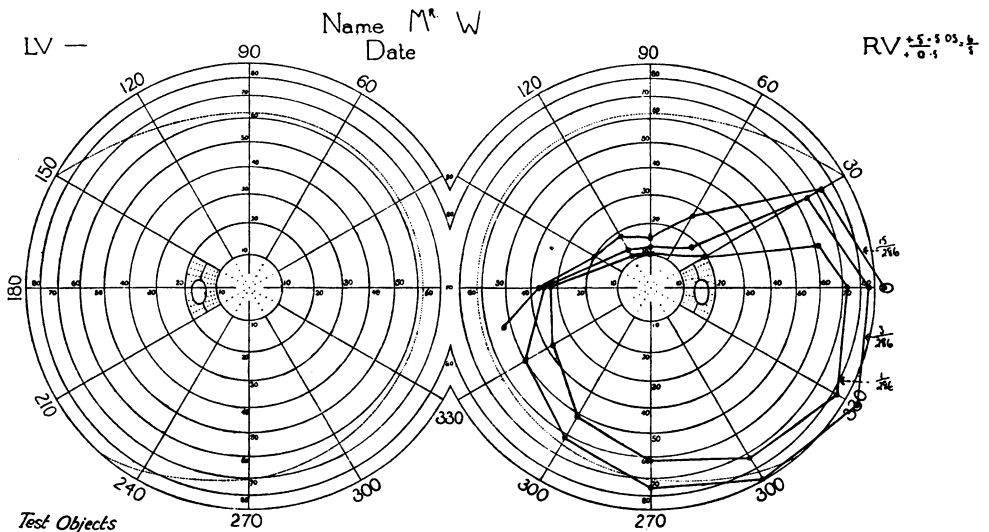
Prognosis

Amsler (1931) when referring to retinal "désinsertions" wrote "In my four cases I have had quite bad results so that probably in similar detachments appearing below or temporally in youthful non-myopic patients I shall not use the cautery, even though I know of favourable results obtained by Professor Gonin."

Gonin stated that "désinsertions" showed a marked tendency to spread and that they were particularly unfavourable for operative cure. He considered that the opening could not be closed like a simple tear by cautery puncture. He endeavours to make a barrier of adhesions posterior to the retinal edge. If the margin was 11 mm. from the limbus he would cauterise 1 or 2 mm. further back, to avoid the fragile retinal edge. As the new attachment is not at the ora serrata the retina may not become accurately re-attached and small folds may result. If the macula is not re-applied perfectly metamorphopsia and even impaired vision may result. Gonin (1932) found that secondary tears were particularly apt to occur along the cauterisation scars. This is due to the firm attachment of the vitreous to the retina. This attachment also explains the tendency for detachments to appear at other sites after such an operation, especially if the dialysis is of long duration. Gonin (1931b) describes a generalised retraction of the vitreous as another difficulty which is apt to be associated with a dialysis. Its presence is suggested by a diffuse opacity and a particular and rigid disposition of the retinal folds. He reports such an occurrence. In a patient

with a detachment which had recurred twice after operations for a large dialysis I was struck with the accuracy with which the main white retinal folds resumed their former position. Gonin (1931a) writes that amongst his series of 118 cured retinal detachments, 153 tears were closed by 197 cautery punctures. 11 "désinsertions" are included and as 27 punctures were required for these the number of interventions necessary for this form of tear is relatively high. He has only twice operated more than four times on one eye. In each of these a dialysis was present in a young man and each had six operations. There appears to be a definite tendency for detachments due to an inferior dialysis to become stationary. They spontaneously develop a pigmented band of retino-choroidal adhesions. I share with Gonin the experience of refusing operation in such a case without regret. Detachments due to temporal dialyses however tend to advance more quickly. Gonin found the latter type to be more common in older patients. This incidence naturally influences the prognosis. The slow development of an anterior retinal dialysis is illustrated by the following history:—

W. W. was a railway employee who, when aged 32 years, noticed "something strange" about the right eye. A few weeks later he detected a "film" in the superior nasal field. This was variable in extent and degree but it gradually increased. I examined him 18 months later and found an extensive detachment in the inferior temporal quadrant. Peripherally a large dialysis was found which extended from 5 to 8 o'clock. Numerous pigment areas were



Mr. W. Fields taken at least two years after development of anterior retinal dialysis to show the occasional slow progress.

present in an intermediate zone between the detached and the normal zones. These areas resembled those found after spontaneous re-attachment. The areas became more profuse towards the edge of the detachment. The vision was 6/5 after the correction of 5.5 D. of hypermetropia and 0.5 D. of astigmatism. The field of vision was as illustrated. This case demonstrates the little interference with central vision that may result from an anterior dialysis and the non-progressive nature of certain of these cases even though the occupation of the patient is strenuous. The patient was a boiler-maker.

Similar problems were raised by a patient reported by Haitz (1931). A one-eyed man, aged 49 years, developed a retinal detachment with anterior dialysis after a fall on his back. At the time he noticed a flash of light and two months later vision began to fail. During the following three years little change was noticed in the detachment and 5/36 vision was retained. No operation had been attempted.

Arruga wrote in 1929 regarding retinal dialyses, "lorsque elles sont très grandes, elles sont impossible à guérir." Coppez (1931) also reports that large separations at the ora serrata are unfavourable for operation.

Schoenberg (1931) considers that "the presence of a very large tear, principally at the ora serrata (retinal dialysis) is a contra-indication to operation." This is probably a partial explanation of his statement that the number of inoperable cases of retinal detachment is large in proportion to the operable and the "doubtful" groups. The experience at Moorfields Hospital has been more satisfactory. Amongst 40 cases regarded as probable cures in Shapland's series 18 had an anterior dialysis (1931). It must be noted however that patients were considered to be cured if when they left hospital they had a full field and the retina re-attached. Of 15 cases operated on by Gonin four were reported as cures and three as partial cures with arrest of the detachment. Of seven cases under my care three are cured, one other appeared to re-attach but a vitreous haemorrhage occurred which is gradually being absorbed, one other is a probable cure though a small area of retina is not quite flat, and the remaining two appeared to be stationary and no operation was advised.

The dialyses in the successful cases had been present for at least one, three, six and twenty months respectively before re-attachment.

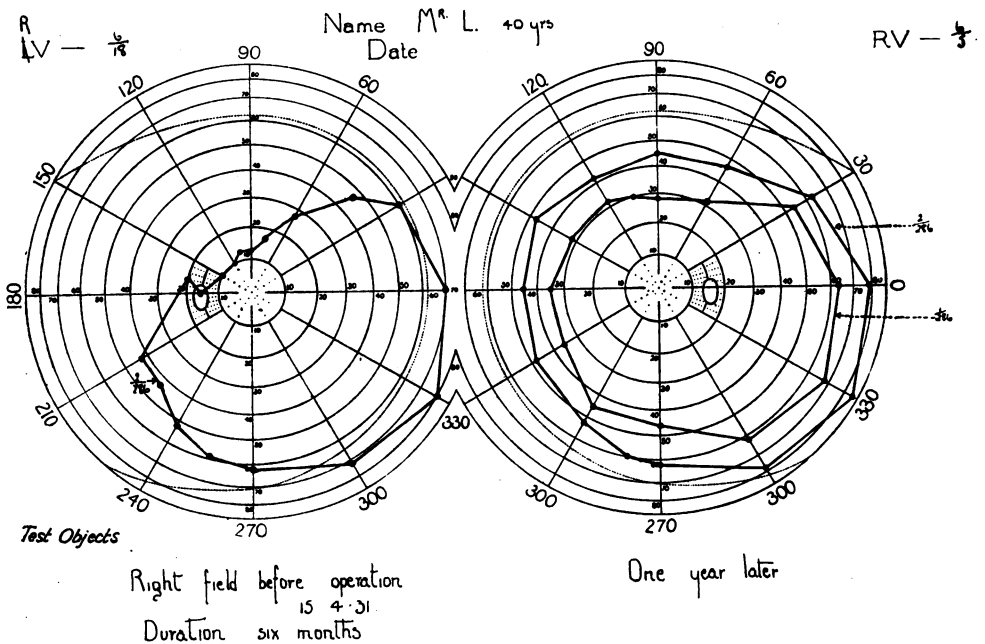
Axenfeld (1930) believed that if a detachment is limited to the periphery and signs of limitation such as marginal pigmentation and other changes are present, it is wisest not to operate. Amongst other patients he observed a doctor who practised for many years with bilateral peripheral retinal detachments. As a rule an

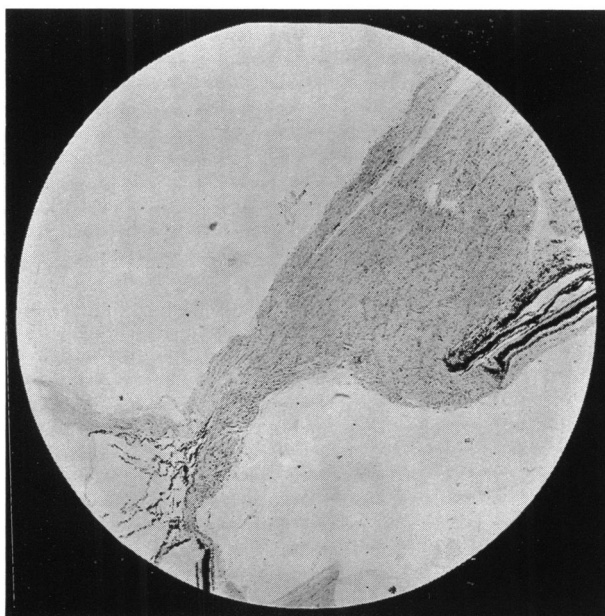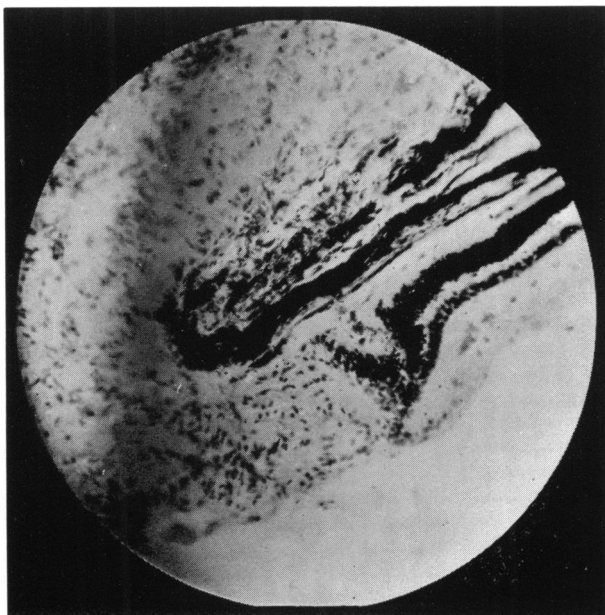
early operation is the only hope but one must not slavishly follow such a plan. Peculiar problems arise in each case and consideration of them must determine one's treatment.

Though these opinions, expressed by the most experienced operators and even Gonin himself, do not justify optimism, yet the histories of the two following patients is sufficient to show that the previous hopeless outlook is now far removed.

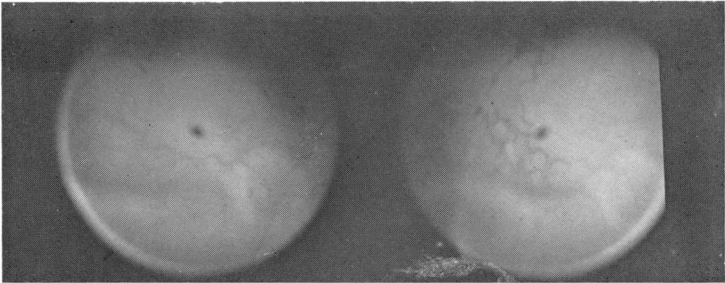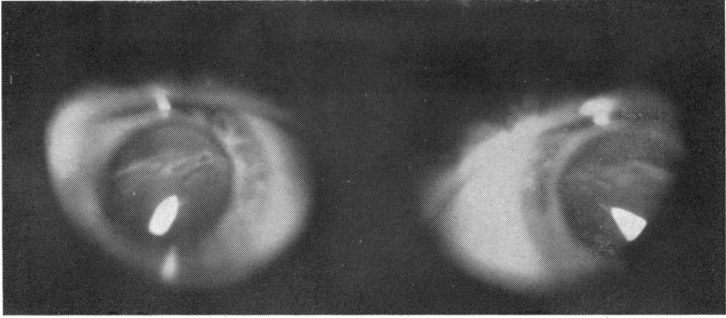
Clinical Reports

1. K. L., aged 41 years, a clerk with slight hypermetropia. Health good except for constipation. Some carious teeth were removed. There was no history of injury. For 5 years he had observed spots floating before the right eye. Six months before he consulted me, he noticed a black line before this eye which would increase after heavy work. Two months later he observed a blur in the superior nasal portion of the right field. This field gradually contracted and eventually the whole field appeared blurry. An appearance like glowing embers appeared in the superior nasal quadrant of the right field. On examination the eye was quiet and of slightly reduced tension. The retina of the right eye was almost completely detached, though very slightly so centrally, and in the superior nasal quadrant. The vitreous

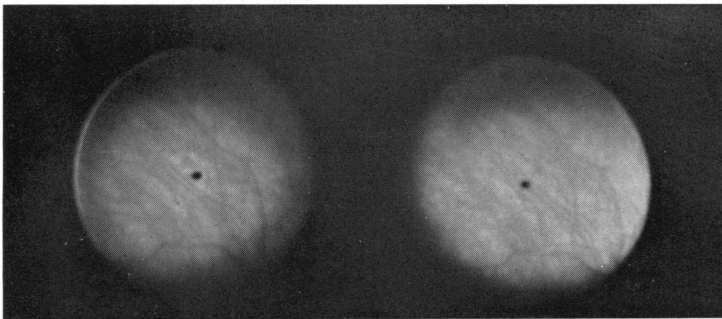
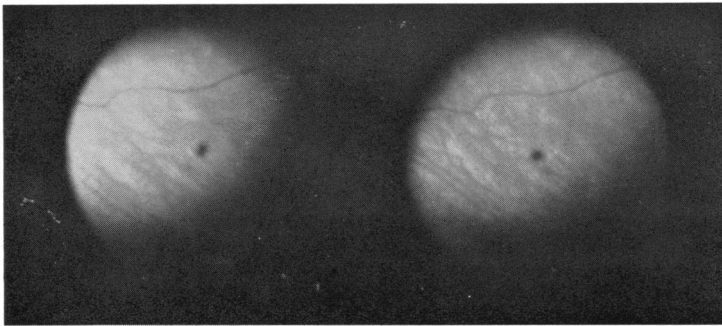
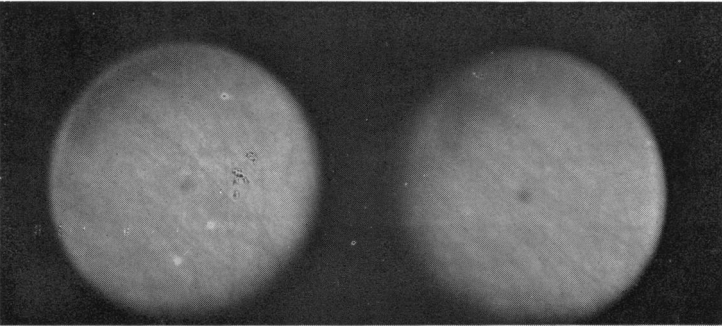
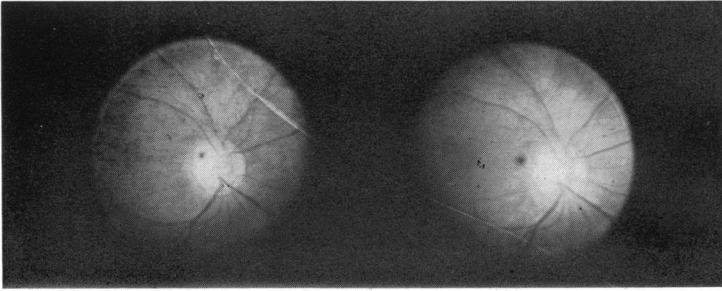




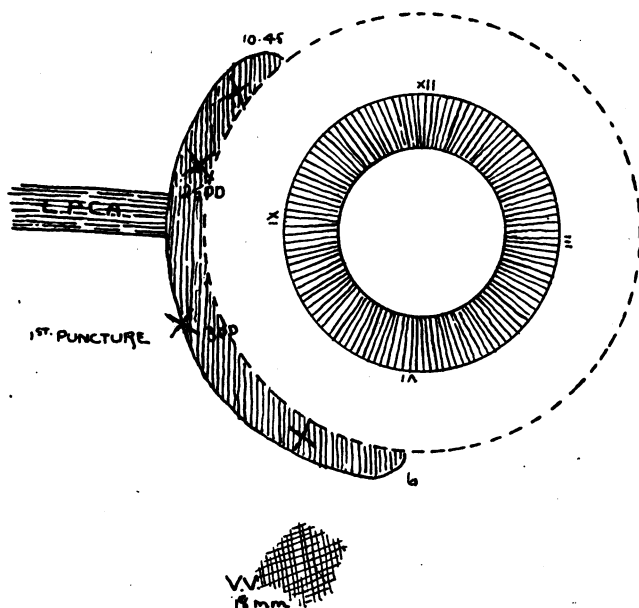
Microphotographs of scar from galvano-cautery puncture of rabbit's eye three months previously. Notice that area of retinal damage is greater than that of choroidal. High and low magnification.



Mr. D. Stereophotographs showing (1) Retinal detachment as seen through pupil. Eye rotated slightly upwards. (2) Retinal detachment close to disc. Eye rotated slightly downwards.



Mr. G. W. Stereophotographs of re-attached retina four months after ignipuncture of large anterior retinal dialysis.



Mr. L. Operation plan showing position of dialysis, long post. ciliary vessels, vena vorticiosa and sites of four punctures.

showed fine opacities in the lower and temporal areas but considering the extensive detachment it was relatively clear. A dialysis extended from 6 o'clock to 11. The retinal edge was uneven, white and slightly rolled over. It separated the uniformly coloured choroid which could be clearly focused from the undulating retinal surface which was a paler red and gray. Neither in this patient nor in any that I have seen could the anterior margin of the dialysis be seen. Undue pressure on the sclera was considered unjustifiable as a means of revealing this edge. The vision was 6/18 partly and the field to a 2 mm. white object was as illustrated.

At the time the only operative experience known to the author was that of Rubbrecht who had found a dialysis after cauterising a small retinal aperture. It was decided to puncture the globe with a red-hot galvano-cautery loop at four separate sites. After the usual preparation and the hypodermic administration of omnopon (gr. 2/3) and scopolamine (gr. 1/150) and under cocaine and novocaine anaesthesia, the conjunctiva was turned back in two flaps which met over the external rectus tendon. The first puncture was made below the lower edge of the external rectus tendon and opposite the posterior retinal margin, that was 8 mm. + 4.5 mm. from the limbus. A considerable degree of semi-fluid vitreous escaped. The three other punctures were made immediately behind the ora serrata for it was considered that after the escape of fluid

the retina would have moved forwards and after all one's plan was to get the retinal margin adherent along the original line of the ora serrata. These punctures were at 7, 9.30 and 10.30 o'clock respectively. The two flaps were sutured in position and both eyes were bandaged. The operation was performed on April 22, 1931. The patient was kept in bed for three weeks. Gradually he was allowed to use his other eye. He was encouraged not to rotate quickly his eyes or his head. He was gradually raised in bed and then allowed up. As in all other cases he was nursed with the affected part of his eye towards his pillow. This is a most important point, though at times difficult, in the nursing of all patients with retinal detachment. A year later his vision was 6/5 and the fields of vision full.

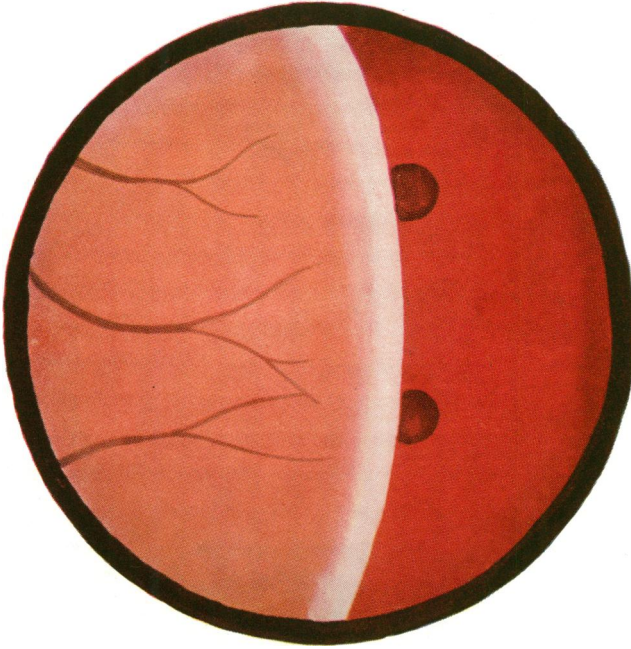
It is claimed that the special placing of the first and the more anterior situation of the three other punctures led to this satisfactory result.

Gonin (1930c) has found tears up to 18 mm. in length or diameter. This one must have been almost 20 mm. Verhoeff (1931) gives a preliminary report of a tear 15 mm. long which was still under treatment at the time of the report.

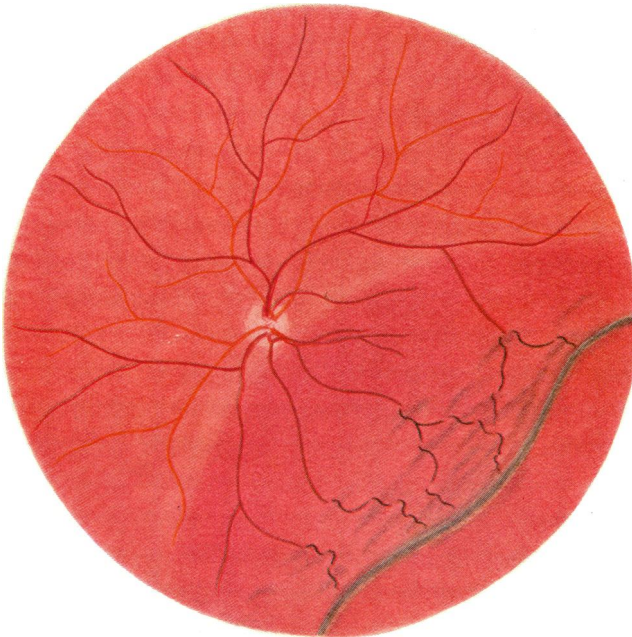It is of interest to compare this history with that of a patient whom Gonin reported in September, 1931. He was a doctor, aged 25 years, who several years previously had apparently lost the sight of the left eye as the result of detachment. Progressive metamorphopsia appeared in the right eye, and vision in September, 1928, was 0.1. The whole of the temporal and inferior parts of the retina were detached and a series of folds stretched from periphery to macula; the latter was raised and oval. An anterior dialysis extended from 6.30 to 10.30 o'clock (*i.e.* 120°). The vitreous was cloudy, especially in the inferior region, and a large number of white pip-like bodies were present which were considered to be nodules of fibrin, probably due to a haemorrhage. It was considered impossible directly to close the aperture. A puncture was made as far back as possible at the level of the macula. The resulting scar produced several radiating folds, and vision improved to 0.2. Five other punctures were made. They were interrupted by acute glaucoma and an iridectomy of the other eye and acute otitis. Gradually the edges of the dialysis became fixed to the choroid. After three and a half months the vision was 0.6, and with the exception of a small zone in the inferior periphery the reapplication was complete. Six months later vision was 0.9 and the field was full. Two years later the condition was unchanged.

From my limited experience it appears wise to attempt to close the tear directly at one sitting, and not to puncture posteriorly and at several operations.

Another patient with an extensive anterior dialysis was G. W.,



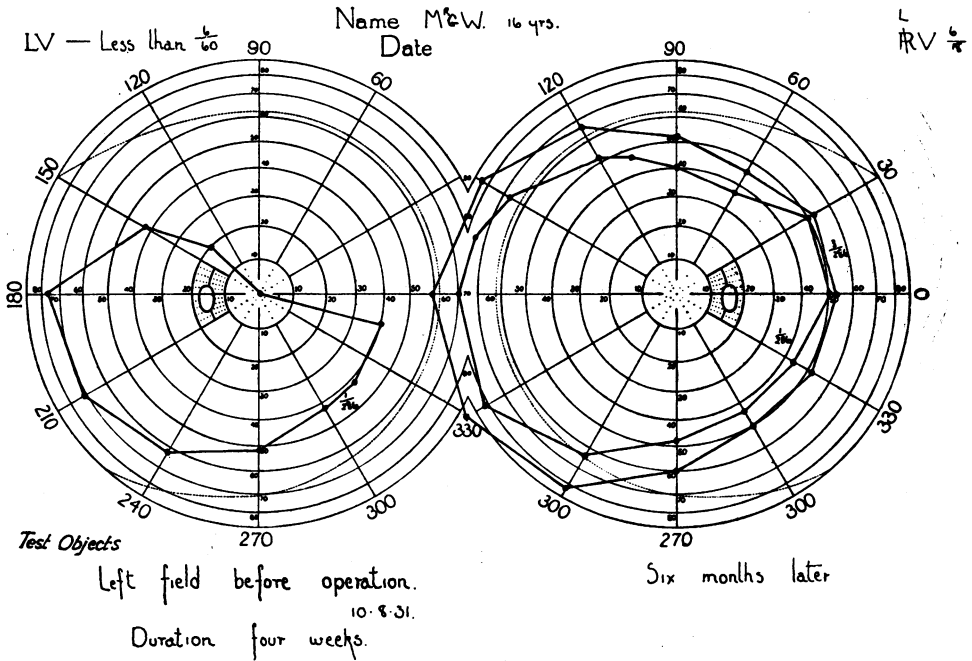
Mr. G. W. Two cautery punctures opposite margin of anterior retinal dialysis at time of operation. The retina had not been touched by cautery.



Mr. G. W. Representation of retinal detachment and extensive anterior retinal dialysis. Fields of same (see p. 721). Stereophotographs of optic disc and periphery of retina after re-attachment (see Plate).

Coloured Drawings by Miss Margaret Fox, Melbourne.

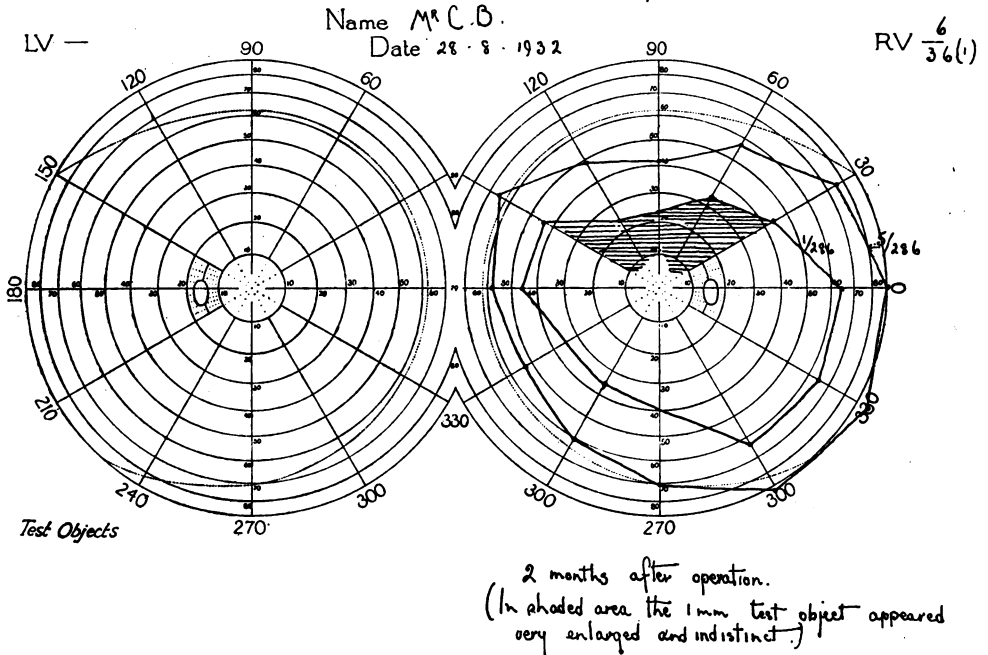
aged 16 years. Three weeks before his visit to me, he had noticed a blur in the superior nasal quadrant of the left eye. He had for some months observed numerous moving spots before this eye. Seven years earlier he had been knocked down and his head injured but no visual disturbances followed this. He had definite hyperopia. On examination an anterior dialysis was found which extended from 3 to 6 o'clock. There was normally a clearly defined choroidal pattern and the absence of this enabled one to recognise the limits of the detachment. Its limits otherwise would have been



difficult to find owing to the shallow nature of the detachment centrally. The two usual guides were absent *viz* a darkening of the colour of the blood vessels and a pallor of the retina where detached. Two cautery punctures were made at one operation. Ophthalmoscopy immediately after the operation showed that though the punctures were opposite the margin of the dialysis, the cautery had not actually touched the retina. This may explain the fact that the retina was not accurately re-applied centrally. Though the field of vision was practically full, central vision at first was only 6/36. Six months later the retina appeared to be in perfect position, and central vision was 6/18. During the interval the patient had a severe gastric disorder with frequent vomiting.

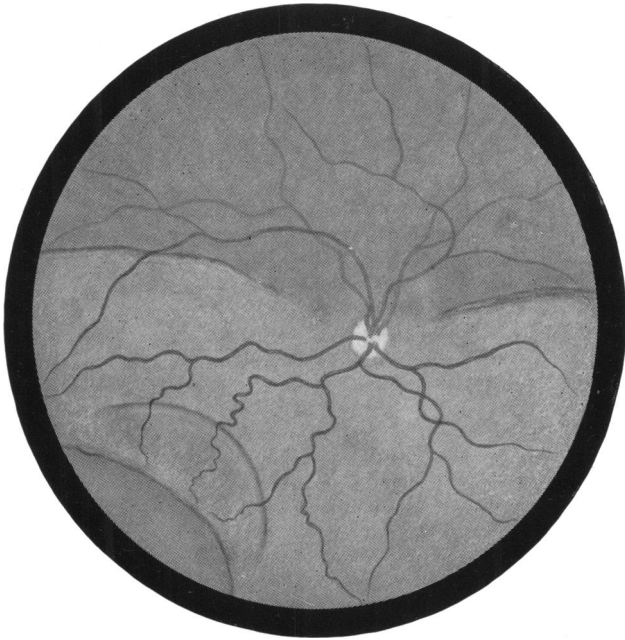This and his return to swimming and diving have not affected his vision.

A third patient was Mr. C. B. who was kindly referred to me by Dr. William Box of Melbourne. Each eye was highly hypermetropic and astigmatic and apparently both were amblyopic, his vision being only 6/36. The right field had been defective for 1 year and 8 months. A retinal dialysis was found and an



extensive detachment. Above the dialysis a crescentic retinal fold was observed. Three cauterly punctures were made at one sitting and two months later the retina appeared to be in position except for a small area near the nasal end of the dialysis. The fields are as shown.

It is interesting to recall Meller's advice against more than one puncture at a sitting. For, in my opinion, success in the preceding cases was partly due to multiple punctures at one sitting. Gonin states that the prognosis of anterior dialysis is made worse by the necessity for several operations. Arruga (1929) stated that cauterisation must not be made in the aperture itself, but on the retina which borders the dialysis. Gonin is inclined to puncture a little further back still because he has found the margin fragile. My



Fundus of Mr. C. B. showing anterior retinal dialysis and unusual crescentic retinal fold or prominence.

limited experience has produced the opinions that it is wise to make all the punctures at one operation and to make the first puncture opposite or a little posterior to the margin and subsequent punctures over the margin or a little in front of it according to the likelihood of the margin moving forwards. The possibility of the retina sliding forwards may be lessened by the presence of definite white retinal folds. Gonin usually punctures 12 or 13 mm. from the limbus. This is further back than appears necessary unless the margin of the retina appears very fragile. Juler punctured 9 mm. from the limbus in two cases with success.

Vogt (1932) reported an elderly male patient (-1.0 D. S. myopia) whose right eye was struck by a pear falling from a tree. At first only conjunctival ecchymosis was observed but 10 months later a decrease of vision was noticed. On examination central vision was 5/6 and the field limited upwards. A dialysis was found from 5 to 9 o'clock in the right eye. Three months later the vision was only 0.1. Therefore three small ignipunctures with the small Sourdille needle were made over the free margin of the wound from 5 to 7 o'clock. Four weeks later two punctures were made between 6 and 8 o'clock. Ten days later he found that vision was 1/6 and that the margin of the wound was adherent except between 7 and 9 o'clock. Two weeks later vision was 6/9, but after a few days a relapse occurred. Most of the re-attached area became detached and vision decreased to 0.1. A fresh series of punctures was made between 7 and 9 o'clock. Ten days later, for the first time the aperture appeared closed and the retina completely re-attached. Nine months later this state was unchanged and vision 0.7. This history is characteristic in that there was a considerable interval between injury and onset of visual loss, and that the initial loss was in the superior nasal quadrant.

The only occurrence of vitreous haemorrhage in my series of retinal detachments was in Richard K., aged 54 years. He was a sailor who had during a period of at least 2 months, detected a gradual failure of the left eye. The right eye could count fingers at two feet and had evidently been convergent since an injury received when very young. It appeared to be amblyopic. The left eye could just read 6/60. He had several very carious teeth and definite pyorrhoea. These conditions received the necessary treatment. His blood pressure after treatment was 112 diastolic and 170 systolic and there was marked thickening of his vessels. The superior nasal third of the left retina appeared to be in normal position. The remainder was detached. The separation was slight centrally and gradually became greater towards an extensive anterior dialysis, which extended from 3.15 to 7.15 o'clock. The white slightly rolled over edge of the retina was 2 D.D. from the ora serrata. The retinal vessels near the tear were extremely tortuous

and here and there dark masses of various sizes appeared on the retina close to the vessels. The vitreous was very degenerate, and scattered profusely through it were small dust-like opacities and a few coarse masses.

Two cautery punctures were made and at the early examinations the patient expressed satisfaction at the improvement of vision. Towards the end of the second week however, this improvement had gone and on ophthalmoscopy little red reflex was obtainable. Gradually the haemorrhage absorbed and was still improving 1 year 6 months later when the vision was 6/60.

Conclusions

1. Anterior dialysis is a special form of breach of retinal continuity. It probably occurs immediately behind the ora serrata. It produces retinal detachment, in the same manner as any other retinal aperture does, by the passage through it of fluid from the vitreous.

2. It occurs most frequently amongst relatively young patients, particularly males. The greater exposure to injury of these patients may partly explain this finding. The great majority of these patients are non-myopic. The preponderance may not be greater than that of non-myopic over myopic eyes. Other forms of retinal detachment are definitely associated with the degeneration of middle age and myopia, and appear regardless of sex.

3. The lower retinal area and particularly the inferior temporal quadrant appears to be predisposed to dialysis. This is in marked contrast with the form of retinal aperture due to degeneration which is most frequently found in the superior temporal quadrant. A retinal detachment in a non-myopic young man if non-traumatic is nearly always due to a dialysis and lies in the inferior temporal quadrant. A detachment of later life, particularly amongst myopes, appears first as a rule in the upper temporal, less frequently in the upper nasal, quadrant.

4. The actual cause of anterior dialysis, apart from obvious cyclitis and severe trauma, is obscure. Structural features, and particularly the attachment of the vitreous base and the "stretched" nature of the inferior temporal ciliary zone, appear to play a part in the mechanism that may produce dialysis. One has only to watch the development of a tear round a retino-vitreous adhesion or to see the alteration in shape and position of a hole in a posterior hyaloid membrane after cauterisation to realize the effect that vitreous traction may have on the retina. Such traction is particularly potent near the ora serrata owing to the firm attachment of the vitreous base. Once the pars ciliaris retinae and the ora serrata

are torn from the retina by the adherent base of the vitreous, the retina lies loosely, and almost un-attached, on the choroid until the collection of fluid beneath it causes its detachment. Such a separation may be aided by the presence of cystoid degeneration which appears most early in this apparently predisposed zone.

5. As a rule retinal dialyses tend to progress, particularly when situated temporally. However, retino-choroidal adhesions may form which may arrest the spread of the tear and its associated detachment. Inferior dialyses may be stationary for a long time.

6. The application of the principles of Gonin's treatment of the more common forms of detachment gives us a reasonable chance of cure. It may be found that, instead of making multiple punctures, a linear or wide surface cauterisation or application of endothermy, with an occasional puncture of the choroid by cautery or trephine will lead to the most satisfactory results. A modification of Guist's operation may prove of value. (Arruga 1932. Guist 1932. Safar 1932. Larsson 1932. Gonin 1932.)

7. Though the cases in this report are too few to justify decided opinions, yet, they show that strict adherence to Gonin's principles can produce operative cures.

REFERENCES

- 1869 Lawson, G.—Cystic disease of the retina in an eye lost from injury 15 years previously. *Pathol. Soc. Trans.*, Vol. XIX, p. 362. Quoted by Leber. *Graefe-Saemisch-Hess Handbuch*, 1916.
- 1871 Bäurlein.—*Blätter f. Heilwissensch.*, Vol. II, p. 9. Ref. Nagel's *Jahresb.*, p. 460.
- 1875 Pagenstecher and Genth's Atlas (1875).—*Atlas der pathol. Anat. des Augapfels*, Wiesbaden, Taf. 28, Fig. 6.
- 1876 Pagenstecher.—*Arch. f. Ophthal.*, Vol. XXII, Part 2, p. 272.
- 1877 Fuchs.—*Klin. Monatsbl. f. Augenheilk.*, Vol. XV, p. 422.
- 1880 Eales.—*Birmingham Med. Review*, Vol. IX, p. 262. Abstract.
- 1881 Kuhnt.—*Ber. ueber die XII Vers. der Ophthal. Ges.*, p. 36. Abstract.
- 1882 Eales.—*Ophthal. Review*, Vol. I, p. 41.
- 1887 Berger.—*Arch. of Ophthal.*, Vol. XVI, p. 26.
- 1887 Nordenson, E.—Die Netzhautablösung: Untersuchungen ueber deren path. *Anatomie und Path.*, Vol. IV, Wiesbaden. Mit 27 Taf.
- 1890 Collins, Treacher.—The Pathology of Intra-ocular cysts. *Ophthal. Hosp. Repts.*, Vol. XIII, p. 65.
- 1891 Scheffels, Otto S.—Traumatic Dialysis and secondary "aufrollung" of the Retina. *Arch. of Ophthal.*, Vol. XX, p. 403.
- 1892 Collins, Treacher.—Detachment of Ciliary Body. *Trans. Ophthal. Soc. U.K.*
- 1892 Dahrenstadt.—A rare case of retinal detachment. *Zentralbl. f. p. Augenheilk.* Abstract *Graefe-Saemisch-Hess Handbuch*, 2nd Edit., Vol. VII, p. 739.
- 1896 Baquis.—*An. di Ottal.*, Vol. XXV, p. 241. Abstract *Graefe-Saemisch-Hess Handbuch*, 2nd Edit., Vol. VII, p. 739.
- 1899 Deutschmann, R.—*Deutschmann's Beiträge*, Vol. XL, pp. 1 to 226 and 659. Reference *Graefe-Saemisch-Hess Handbuch*.
- 1899 Velhagen.—A very rare form of detachment and iridocyclitis. *Arch. f. Ophthal.*, Vol. XLIX, p. 599.

- 1901 Römer, P.—A case of total tearing of the retina from the ora serrata. *Klin. Monatsbl. f. Augenheilk.*, Vol. XXXIX, p. 306.
- 1901 Wintersteiner.—Microscopical demonstration of Retinal Dialysis. *Ber. ueber die XXIX Vers. d. Ophth. Ges.*, p. 260; *Klin Monatsbl. f. Augenheilk.*, Vol. XXXIX, p. 698.
- 1901 Vossius.—Deutschmann's The question of separation of the Retina at the ora serrata. *Beitr.*, Heft XLVII, p. 112. Abstract *Graefae-Saemisch-Hess Handbuch*, 2nd Edit., Vol. VII, p. 763.
- 1901 Buchanan, L.—"Cyclitis: a study of inflammatory exudates into the vitreous, etc." *Trans. Ophthal. Soc. U.K.*, Vol. XXI, p. 208.
- 1903 ——— "Traumatic separation of the ciliary body due to rupture of the pectinate ligament." *Trans. Ophthal. Soc. U.K.*, Vol. XXIII, p. 283.
- 1905 Cramer.—Traumatic retinal detachment. *Zeitschr. f. Augenheilk.*, Vol. XIII, p. 31. Abstract.
- 1904 Constantin.—Congr. Internat. d'Ophthal., Lucerne. B. 181. Abstract.
- 1905 Paul.—*Klin. Monatsbl. f. Augenheilk.*, Vol. XLIII, pp. 1, 185.
- 1906 Gonin, J.—*Encycl. franç. d'Ophtal.* (Plate 9, Fig. 13), Vol. VI, p. 1002.
- 1908 Wolftrum.—*Archiv f. Ophthal.*, Vol. LXIX, p. 145.
- 1908 (a) Parsons, Sir J. H.—Pathology of the Eye, p. 342; (b) Vol. IV, Part 2, p. 1149.
- 1912 Collins, Treacher, and Mayou, S.—Pathology and Bacteriology (Fig. 178).
- 1912 Zeeman.—*Archiv f. Ophthal.*, Taf. 9 and 10, Vol. LXXX, Part 2, p. 259.
- 1912 (a) Salzmann, M.—The Anatomy and Histology of the Human Eyeball. Chicago, p. 84; (b) The Anatomy and Histology of the Human Eyeball. Chicago, p. 209.
- 1916 (a) Leber.—*Graefae-Saemisch-Hess Handbuch*, 2nd Edit., Vol. VII, p. 777 (Figs. 97, 150, 151, 212), (b) p. 718, (c) p. 719, (d) p. 736, (e) p. 665, 667, 737, (f) p. 740, (g) 673.
- 1917 Lawson, A.—Case of detachment of the retina at the ora serrata. *Trans. Ophthal. Soc. U.K.*, Vol. XXXVII, p. 231.
- 1917 Collins, Treacher.—*Trans. Ophthal. Soc. U.K.*, Vol. XXXVII, p. 236.
- 1917 Butler, H.—*Trans. Ophthal. Soc. U.K.*, Vol. XXXVII, p. 236.
- 1917 Parsons, Sir J. H.—Detachment of the retina at the ora serrata. *Trans. Ophthal. Soc. U.K.*, Vol. XXXVII, p. 236.
- 1920 Gonin, J.—*Bull. et Mém. Soc. franç. d'Ophtal.*, Vol. XXXIII.
- 1920 Fuchs, E.—Surface proliferation of the ciliary epithelium and observations about ectopia of the lens. *Klin. Monatsbl. f. Augenheilk.*, Vol. LXIV, p. 1.
- 1928 Poos, G. H.—*Amer. Jl. of Ophthal.*, Vol. X, p. 299.
- 1928 (a) Mann, Ida.—The Development of the Human Eye. Cambridge; (b) The regional differentiation of the vertebrate retina. *Amer. Jl. of Ophthal.*, Vol. XI, p. 515.
- 1929 Arruga, H.—Treatment of Detachment of the Retina. XIII^o Concil. Ophthal., Amsterdam, p. 655.
- 1929 Martin, W. O.—Anterior and Posterior Dialysis of the Retina. *Amer. Jl. of Ophthal.* (August), Vol. XII, p. 652.
- 1929 Dubois, H.—*Ann. d'Ocul.* (February), Vol. CLXVI, p. 81.
- 1930 (a) Gonin, J.—*Bull. et Mém. Soc. franç. d'Ophtal.*, Vol. XLIII, p. 324; (b) Detachment of the Retina and its treatment. *Trans. Ophthal. Soc. U.K.*, Vol. L, p. 535; (c) Remarks on 240 cases of Retinal Detachment, etc., *Ann. d'Ocul.*, Vol. CLXVII, p. 361.
- 1930 Löhlein, W.—*Ber. ueber der deutsch. Ophthal. Gesell.*, Heidelberg, Vol. XLVIII, p. 68.
- 1930 Samuels, B.—*Arch. of Ophthal.*, Vol. IV, p. 838.
- 1930 Gonin, J.—*Bull. et Mém. Soc. franç. d'Ophtal.*, Vol. XLIII.
- 1931 Knapp, P.—*Klin. Monatsbl. f. Augenheilk.*, Vol. LXXXVII, p. 399.
- 1931 Ballantyne, A. J.—Case of detachment and reflection of the retina. *Trans. Ophthal. Soc. U.K.*, Vol. LI, p. 113.
- 1931 Müller, H.—*Zeitschr. f. Augenheilk.*, Vol. LXXIII, p. 163.
- 1931 Haitz.—*Klin. Monatsbl. f. Augenheilk.*, Vol. LXXXVI, p. 106.
- 1931 Lagrange, E.—*Arch. de Oftal. Hisp.-Amer.*, Vol. XXXI, p. 129. Abstract *Amer. Jl. of Ophthal.*, Vol. XIII, p. 1295.

- 1931 Shapland, C.—An analysis of 100 cases of Retinal Detachment treated by Caутery Puncture. *Trans. Ophthalm. Soc. U.K.*, Vol. LI, p. 152.
- 1931^a Gonin, J.—The obliterating thermo-puncture of tears in Retinal Detachment. *Ann. d'Ocul.* (September), Vol. CLXVIII, p. 705.
- 1931^b Gonin, J.—Results of obliterating caутery puncture, etc. Case XXIX. *Ann. d'Ocul.* (September), Vol. CLXVIII, p. 719.
- 1931 Ballantyne, Juler, and Goulden.—A case of Detachment and reflection of the retina. *Trans. Ophthalm. Soc. U.K.*, Vol. LI, pp. 113, 115.
- 1931 Verhoeff, F. H.—*Amer. J. of Ophthalm.*, Vol. XIV, 1049.
- 1931 Jeandelize, P., and Baudot, R.—*Bull. et Mém. Soc. franç. d'Ophthal.*, Vol. XLIV, p. 488.
- 1931 Amsler, M.—Gonin's operation. *Klin. Monatsbl. f. Augenheilk.*, Vol. LXXXVI, p. 1.
- 1931 Schoenberg, M. J.—Experiences with the Gonin Operation. *Arch. of Ophthalm.*, p. 675.
- 1931 Coppez, L.—Treatment of Retinal Detachment. *Le Scalpel*, p. 925 (July).
- 1931 Juler, F. A.—Detachment of the Retina. *Trans. Ophthalm. Soc. U.K.*, Vol. LI, p. 164.
- 1932 Gonin, J.—Ignipuncture or Chemical Cauterisation, etc. *Arch. d'Ophthal.* (May), Vol. XLIX, p. 292.
- 1932 Vogt, A.—*Klin. Monatsbl. f. Augenheilk.*, Vol. LXXXVIII, p. 246.
- 1932 Velhagen, K.—The formation of tears in secondary detachments and the question of detachments amongst young emmetropes. *Klin. Monatsbl. f. Augenheilk.*, Vol. LXXXVIII, p. 317.
- Stellwag.—*Ophthalmologie*, Vol. I, Section 713; Vol. II, Section 552. (Quoted by Scheffels.)
- 1932 Guist, G.—Chemical Treatment of Detachment. *Deutsch. Ophthalm. Gesell.*, Leipzig, May.
- 1932 Safar.—Treatment of Detachment by Multiple Diathermy. *Deutsch. Ophthalm. Gesell.*, Leipzig, May.
- 1932 Arruga, H.—Seventeenth Assembly of Spanish-American Ophthalmological Society. Congress of French Ophthalmological Society (July).
- 1932 Larsson, S.—Electro-diathermy in Detachment of the Retina. Vol. VII, p. 661.

JOHN ZACHARIAH LAURENCE— A BELATED TRIBUTE

BY

ARNOLD SORSBY

LONDON

THE passing of John Zachariah Laurence in his 42nd year in 1870, was barely noticed by his contemporaries. In the ophthalmic journals of that period there is no mention of his decease, and contemporary English medical periodicals, save for a short and rather patronising paragraph in the *Medical Times and Gazette*, are likewise silent. Nevertheless his memory has persisted. When Hirschberg came to deal with British Ophthalmology in the second half of the nineteenth century, he found Laurence a noteworthy figure, a learned and inventive man, and one who had aspired to great things; it was a matter for regret that nothing concerning his life was to be obtained from the usual sources of reference.