

THE BRITISH JOURNAL

OF

OPHTHALMOLOGY

FEBRUARY, 1945

COMMUNICATIONS

PENICILLIN AND THE CONTROL OF DEEP INTRA-OCULAR INFECTION*

BY

Lieut.-Col. B. W. RYCROFT, R.A.M.C.

ADVISER IN OPHTHALMOLOGY, ALLIED
FORCE HEADQUARTERS, C.M.F.

DEEP infections of the eye due to penetrating wounds present to military ophthalmologists a major problem, the solution of which would go far in limiting the total blindness which so often results.

For many months this problem has engaged the attention of all ophthalmologists in the British North African and Central Mediterranean Forces; the results of their efforts to date (September, 1944) are contained in this account.

Types of ocular wounds

Wounds of the eyes tell the story of a battle and whether an army is advancing, entrenched, or in retreat. When an army advances mines are the greatest menace, but when it is stationary, machine-gun bullets, mortars and grenades account for many wounds: in retreat, wounds by shellfire are prominent.

Mine wounds have been a marked feature of the recent warfare in Italy. The nature of the country and the Winter of 1943-4 enabled the Germans to graft a strong defensive system along a line of natural barriers, and no mean part of this system was the

* Received for publication, December 6, 1944.

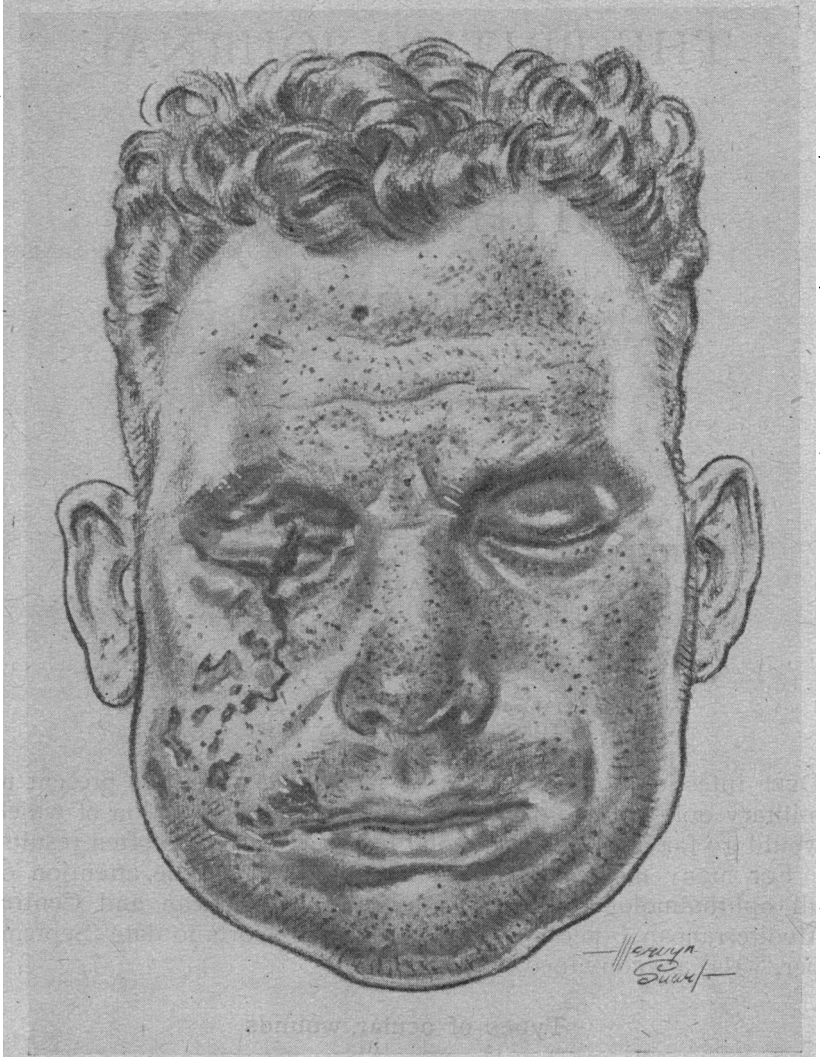


DIAGRAM 1.

CASE 2C.—The result of injuries from a Schu mine. There is extensive peppering of the skin of the face and neck by minute grit particles which give a typical bluish discoloration. The lids of the right eye are extensively lacerated and the globe was disintegrated.

The blast oedema of the left lids is well seen: this persisted for three weeks after the wound was received.

Foreign bodies were found at all depths in the left cornea; at least twenty stone particles were removed, but many remained. There was penetration of the cornea, iris and lens, with purulent keratitis, hypopyon, iritis, traumatic cataract, and secondary glaucoma. Vision on discharge to United Kingdom was "hand movements (gross)." Other injuries were trivial.

This N.C.O. went to the rescue of an officer in an uncleared minefield. The illustration was made a fortnight after being wounded.

development of elaborate mine warfare. These wounds are characterised by multiple small foreign bodies of the face, hands, and chest wall, together with gross infection by mud, gravel, and clothing: one or both feet are also frequently blown away.

In the eyes, the significance of these wounds is that they are caused by tiny stone foreign bodies which penetrate the cornea to all depths, traverse the anterior chamber, and by penetrating the iris and lens reach the anterior vitreous; they result in purulent keratitis, hypopyon, iritis, cataract, and endophthalmitis, with infection all the way.

These foreign bodies vary according to the nature of the mine which produces them. From Teller and "S" mines they are generally of steel, but the igniters of any mine may be composed of aluminium (DZ 35A) or brass (DZ 35B or ZZ 35); the containers may be of wood (Schu mine 42), concrete (Stock) or bakelite, relying for their devastating anti-personnel effect on blast. When blast is severe, the minute grit foreign bodies driven into the eye cause the utmost physiological damage, whereas elsewhere, as for example in the skin of the face, they are of little consequence.

The latest anti-personnel Schu mine contains practically no metal, and is consequently extremely difficult to detect in daylight and almost impossible at night.

From the ophthalmic standpoint, this mine is the greatest menace, relying as it does mainly on blast and producing a multitude of wounds with non-magnetisable foreign bodies, such as stone, and with almost inevitable infection.

When enemy resistance halts an army, there is more danger of wounds from trained machine-guns. Machine-gun bullet "spatter" generally results in a nickel or stone intra-ocular foreign body with problems of removal rather than of infection.

Shells, mortars and grenades give rise to a variety of lesions varying from the tiny chips of intra-ocular steel which are easily removed, to large pieces which disintegrate the globe, open the skull, and cause death by haemorrhage or meningitis.

It is generally agreed that in this campaign, mortar wounds have been the most serious of all.

Pathology

The problem under consideration is that of the deep infections of the eye which these varied missiles may cause. These may be classified as follows:—

Cornea. (a) Single ragged penetrating wound. (b) Retained multiple foreign bodies at all depths causing diffuse purulent infiltration.

Anterior Chamber. (a) Retained single or multiple foreign

bodies which may be infected or non-infected. (b) Hypopyon (anterior). (c) Hyphaema.

Iris. (a) Infected holes. (b) Retained foreign bodies causing iritis.

Lens. (a) Infection of lens matter under or outside the lens capsule. (b) Retained infected foreign bodies within the lens.

Vitreous. (a) Retained infected foreign bodies, usually within the anterior segment. (b) Posterior hypopyon (quiet endophthalmitis). (c) Panophthalmitis (abscess of the vitreous).

Wounds of the eye often suggest the type of missile which caused them. The ragged single dirty penetrating wound of the cornea with prolapse of iris or lens capsule, traumatic cataract and retention of a foreign body in the vitreous frequently characterises a small shell or mortar fragment, whilst the tiny almost invisible limbal wound, the small iris hole, the retention of vision and normal tension occurs from the "hammer and chisel" foreign body of a tank workshop.

Tiny circular deep and penetrating wounds of the cornea which extend across the interpalpebral portions with gross dirt contamination bespeak a mine. Foreign bodies lie at any depth up to the anterior vitreous and at all depths generally show infection with calamitous effects on vision.

In the anterior chamber, hypopyon is frequent and may be the result of any infected corneal wound, but when also associated with deep purulent infiltration of the cornea the risk of permanent blindness is great from subsequent organisation and fibrosis. Hypopyon in the anterior chamber should be designated "anterior hypopyon" to distinguish it from a similar sterile exudation behind the iris, which it is proposed should be named "posterior hypopyon."

Infection of the iris is brought about in a similar manner; holes are torn, vessels distend, the pattern dies away, the colour changes with blood or exudate and posterior synechiae soon form. Sometimes infection can be seen to spread from a tiny foreign body caught up in the stroma.

Lens infection has not been found to be common. Pouting lens flocculi in the anterior chamber change from grey to yellow and then absorb, but it has not been possible to say definitely whether true infection was present or not. On the other hand, tracks with or without foreign bodies are very common, passing in all directions through the cortex.

Vitreous infection presents an interesting picture which could only be painted in wartime. It is most frequently seen in the anterior segment from stone or grit: ferrous foreign bodies are not allowed these days to remain long enough to set up deep reactions, and non-ferrous metals are often free from reaction.

Infection of the vitreous is seen as two types:—

(a) In the eye which appears relatively quiet. There is little conjunctival oedema or loss of corneal lustre and the anterior chamber is clear. Behind the lens, however, is seen a yellow exudate spreading with finger-like processes across the vitreous chamber: it is seen to increase day by day. There is little pain, but a gradual diminution in the perception of light follows. Until the condition is well advanced tension remains normal, but in the later stages it falls commensurate with the degree of shrinkage of the globe.

The general appearance of such an eye does not suggest an acute inflammatory process within, but rather the gradual accumulation of exudation which indeed there is. The exudate appears to have all the characteristics of a hypopyon in that it is sterile, forms gradually and is not accompanied by severe local reaction.

(b) That which shows as an acute crisis of inflammation with severe pain, lid and conjunctival oedema, haziness of the cornea and media, and a dirty yellow reflex behind the lens. Tension is high, perception of light is soon lost, and the end is frequently perforation.

The latter type has been much less common than the former in this Force since extensive mine warfare began.

The bacteriology of these lesions will be noted when individual cases are described.

The prevention of deep intra-ocular infections in war

Since the causes of deep intra-ocular infection are known, namely the production of penetrating wounds by foreign bodies and contamination by organisms, some thought must be given to attempts at prevention.

War cannot be waged without casualties, but a small proportion of eye wounds would appear to be preventable.

(a) Time and again men have been blinded by mines which were known to be about and when obvious risks had to be taken. Such circumstances arise when an area has to be cleared or a comrade rescued from a minefield. The preventable portion is about 40 per cent. of all mine casualties.

For these occasions a Perspex anti-mine vizor has been devised in this theatre. This vizor is made of $\frac{1}{8}$ in. Perspex and weighs two and a quarter ounces: it is fixed to the head with tapes and allows a full field of vision thereby differing from former types which tended to be blown off by blast or restricted peripheral vision. The vizor is primarily intended to be a protection for sappers and assault pioneers when clearing an area of Schu mines, these being notoriously difficult to detect. It will not stop bullets or large grenade fragments.




DIAGRAM 2.

Perspex Anti-Mine Vizor.—This vizor is constructed from $\frac{1}{8}$ in. Perspex as used in aircraft turrets. It is padded by strips of standard orthopaedic felt and secured to the head by tapes or elastic. Air holes are drilled at all borders and in the temporal areas.

It weighs about $2\frac{1}{4}$ ozs, and will stop small fragments at close range, especially stone particles. The vizor is primarily designed to protect the eyes of those dealing with known and unknown Schu mines; for example, it would have saved Case 2.C.

On trial, personnel of the Eighth Army report the advantages that the morale is increased, and there is a definite place for such protection in modern warfare.

Disadvantages noted are that occasionally there are optical defects due to unequal contraction of the material on cooling; that the material scratches and that glint may give away positions to the enemy. These difficulties are being overcome by improved methods of manufacture and a new type which eliminates distortion and directs reflected rays downwards.

Up to the present the vizor has been tried with the Eighth Army and issues are to be made. It remains to be seen how effective it will prove to be, but at any rate those concerned in actual field trials have approved it and requested issues as a rational attempt at prevention of blindness.

(b) Casualties of all types nowadays come under early skilled examination at Advance Dressing Stations (A.D.S.). Thanks to the co-operation of Brigadier Stammers, Consulting Surgeon, Eighth Army, it has been possible to direct the attention of general surgeons to the care of eye wounds at a very early stage and so to institute simple measures calculated to reduce infection.

Forward surgeons have all been asked to carry out the following recommendations and already the results show considerable promise.

Suggestions to surgeons in the forward areas in the early care of ophthalmic cases

(1) The skin of the lids should be carefully cleaned and gross debris removed.

(2) Loose foreign bodies should be removed from the conjunctival sacs.

Irrigation of the eye is contra-indicated except under anaesthesia as it may cause squeezing and further extrusion of ocular contents after a penetrating wound.

(3) Cut the lashes with vaselined scissors in every case of lid or eye injury and burns.

(4) Atropine is used in every wounded eye.

(5) Tie up the eye with a pad and bandage if there is a penetrating wound.

(6) If the cornea looks like being exposed, stitch the lid to the cheek with a simple temporary anchor stitch: if there is no lid, cover with vaseline gauze.

(7) Only complete disorganisation of the eye is an indication for removal in forward areas.

(8) Every corps has a mobile ophthalmic unit attached to a Forward C.C.S., a skilled ophthalmic surgeon is available there and the repair and renewal of spectacles can also be undertaken on the spot.

(c) Mobile ophthalmic units are the next link in this prophylactic chain. These units are staffed by skilled surgeons of experience who command full equipment; they function within a few miles of the line and are attached to a "bottle neck" C.C.S.

Ophthalmic cases reach them within an hour or two of injury so that one potent factor in the cause of infection, namely, time lag after wounding, is much reduced.

The duty of these forward ophthalmologists is to clean up the eye, to attempt the removal of the intra-ocular foreign body through the wound of entry, to excise prolapses, apply penicillin, and seal the wounds securely by conjunctival flaps. In other words eyes are made "travel safe" and early ingress of infection prevented. Sixty per cent. of intra-ocular foreign bodies are removed at the mobile units.

Should the foreign body not yield to hand or giant magnet attraction, the toilet of the wound proceeds in a similar manner and the case is then evacuated by air to a Base ophthalmic wing.

The value of these mobile units cannot be too strongly stressed not only because of the expert surgery which they offer at such an early stage, but because of the facilities for the immediate supply and repair of spectacles with the consequent saving of manpower in forward areas or isolated landings.

To summarise, as a result of experience of three campaigns the measures to be recommended for the prevention of ocular infection are as follows:—

- (1) The provision of anti-mine vizors for selected troops.
- (2) Early attention to ophthalmic cases by forward general surgeons.
- (3) Early magnet applications and removal of intra-ocular foreign bodies from entry wounds, excision of prolapses and closure of wounds by skilled ophthalmic surgeons.
- (4) Insufflation of pulv. Ca. Penicillin into every case of penetrating wound of the eye.
- (5) Air evacuation to a Base ophthalmic wing. When cases reach this stage the chances of preventing the infection have diminished: treatment of the established condition supervenes.

The treatment of deep intra-ocular infections

On arrival at a Base ophthalmic wing, the following special measures are taken in addition to the ordinary routine of treatment, namely:—

- (1) Complete radiographic investigation and localisation by equatorial or limbal rings followed by the removal of intra-ocular foreign bodies by formal surgery.

- (2) Sulphonamide therapy.
- (3) Non-specific protein therapy.
- (4) Penicillin therapy.
- (5) Surgical treatment.

(1) *Intra-ocular foreign bodies*.—It is difficult to say how often a ferrous intra-ocular body is associated, or would be associated, with deep infection since so many are removed in the early stages and repeated cultures of such foreign bodies after removal are

sterile. Certainly the combination of retained ferrous intra-ocular foreign body and acute sepsis is not particularly frequent in this campaign.

More so is the case with aluminium and alloys which are so frequently clearly seen in the vitreous chamber free of irritation and infection. But with stone the story is different and infection of the eye is the rule.

The working principle for removal of metal intra-ocular foreign bodies is that at a Base ophthalmic wing a surgical attempt after localisation is always undertaken and direct magnet approach carried out. The negative subjective response to a "magnet test" is of no value since time and again ferrous foreign bodies have been seen in the vitreous to leap to the magnet and yet the patient complained of no discomfort. The details of these operations have been so well described by Stallard and Skeoch that there is little more to add.

In the case of superficial stone foreign bodies the rule is to remove those from the cornea which it is possible to dislodge readily and afterwards to carbolicise the wounds: this procedure has to be frequently repeated as the case progresses.

(2) *Sulphonamide therapy*.—All cases with intra-ocular foreign bodies are given a course of sulphonamide therapy as a routine. There is not the least doubt that this is of benefit for the ocular infection as well as for infection of other coincident wounds, which are generally present. The usual course commences with an initial dose of 3 grms. (6 tablets) followed by 2 grms. (4 tablets) four hourly day and night for three days making a total course of 37 grms. Sulphathiazole is the drug of choice except where there is reason to believe the skull has been opened in which case sulphadiazine, on account of excretion into the cerebro-spinal fluid, is preferred. The usual precautions as to alkaline fluid intake, urine control, white cell blood counts are observed.

Infective lesions which respond quickly are those of vascular areas such as the uveal tract, whereas in corneal wounds the effect is not so marked. Nor has any marked benefit been seen from it in closed endophthalmitis.

In mine wounds with gross sepsis of the face and lids it is of particular value.

(3) *Non-specific protein therapy*.—Many substances have been recommended to produce artificial pyrexia in the treatment of ocular infection, but for ease of technique, availability, and certainty of result there is little to beat the intravenous injection of T.A.B. vaccine. The relationship of the pyrexia produced to the dose employed is reasonably constant and an initial dose of 50-75 millions may be expected to produce a fever of 101-102 deg. F.

After three days, a second dose of 75-100 millions may be employed and more than two doses are rarely required. Heavier doses will produce higher temperatures, but they have the disadvantage of also producing herpetic lesions which are non-specific and may occur in any high pyrexia. Herpes labialis is of little consequence; herpes of the cornea, as noted in one Italian P.O.W., after a high dose is the only serious complication which has been seen.

It may be categorically stated that as a result of the general reaction from T.A.B. protein shock, almost any hypopyon will disappear, and it is for this condition and sub-acute iritis that the method is of such value in military practice. In corneal infections alone the results, though definitely beneficial, are not so startling; in closed endophthalmitis they are encouraging, but of transient benefit only.

Protein shock is never given coincidentally with a course of sulphonamides, as the sweating which results from the former may cause dangerous concentrations of the latter in the urine, especially in hot climates. The method of choice is first to assess the value of a sulphonamide course and then to boost the treatment by intravenous T.A.B. injections if necessary.

(4) *Penicillin therapy*.—Great interest has centred round the value of this drug in ocular conditions; it has been used by most ophthalmologists in this Theatre on hundreds of cases for over seven months. Reports from them have been forwarded to Headquarters, and their conclusions are briefly as follows:—

(i) That penicillin is of great value for superficial infections of the conjunctiva and sockets (Majors C. Cockburn, W. D. Hamilton, and Captain C. Brown).

(ii) That the drug effectively prevents infection of the conjunctiva when used early after operation, such as was commonly seen around stitches in conjunctival flaps, etc. The "fourth day" bead of pus at the base of conjunctival sutures has now practically vanished (Majors B. Gluck and E. C. Zorab).

(iii) That routine application by forward ophthalmologists results in the arrival of cleaner eyes at the base; this feature is particularly noticeable when Sicilian and Tunisian battle casualties are compared with those of the C.M.F. (Majors H. H. Skeoch, R. McIvor Paton, and Lindsay Burns).

(iv) That penicillin has no great value in the treatment of corneal ulceration, unless secondary to conjunctivitis (Captain C. Brown).

Other investigators, namely, Cashell, Crawford and King, and Milner, obtained similar results. Therefore, for superficial infections of the eye, the value of penicillin must now be considered

well proven: but for deep infections the remedy had yet to be tried.

The rapid advance of the Allied Armies to Naples did not involve them to any great extent in mine warfare, and a high degree of eye infection from this cause did not therefore occur, but at Cassino the terrain and the tactics of the enemy defence abruptly changed.

"All roads lead to Rome, but unfortunately all the roads are mined" said General Alexander—they certainly were, and the hills too! The month of May, 1944, brought the attack on Cassino, and as the mine warfare intensified, so did the frequency of the deep ocular sepsis. It seemed profitable to investigate the value of penicillin in the treatment of this deep sepsis in view of what might be expected in other theatres of war.

Military ophthalmologists were asking for answers to these queries:—

- (1) What is the most effective form in which to use penicillin?
 - (2) What are ophthalmic incompatibilities?
 - (3) What effect has the drug on established intra-ocular sepsis?
- These queries required speedy answers.

Methods of application

1. *Drops*.—Sodium Penicillin (1,000 units to 1 c.c. distilled water) is useful for conjunctival lesions when frequently used. The disadvantages are the need of frequent preparation and careful cold storage.

2. *Ointment*.—The most suitable base which retains penicillin is lanette wax as the following simple experiments show. The table shows the potency of penicillin in vaseline, lanoline, and lanette wax kept in room temperature over a period of several days.

Clinical trials already suggest a profitable field in the treatment of sebaceous chronic blepharitis, bugbear of all military outpatient departments.

3. *Powder*.—The value of this form of application lies in the persistence of the drug action, a point of moment when wounded men are to be evacuated and continuity of treatment interrupted. Mixed with sulphathiazole or sulfanilamide (2,000 units per gramme of powder), it is the method of choice for military ophthalmologists in forward areas since it keeps well, is portable and is easily applied.

Here it is insufflated as a routine in all cases of penetrating wounds of the eye. Occasionally the powder is irritable and appears to aggravate an infection. This is due more to the sulphathiazole rather than to the penicillin, and a change should accordingly be made to drops.

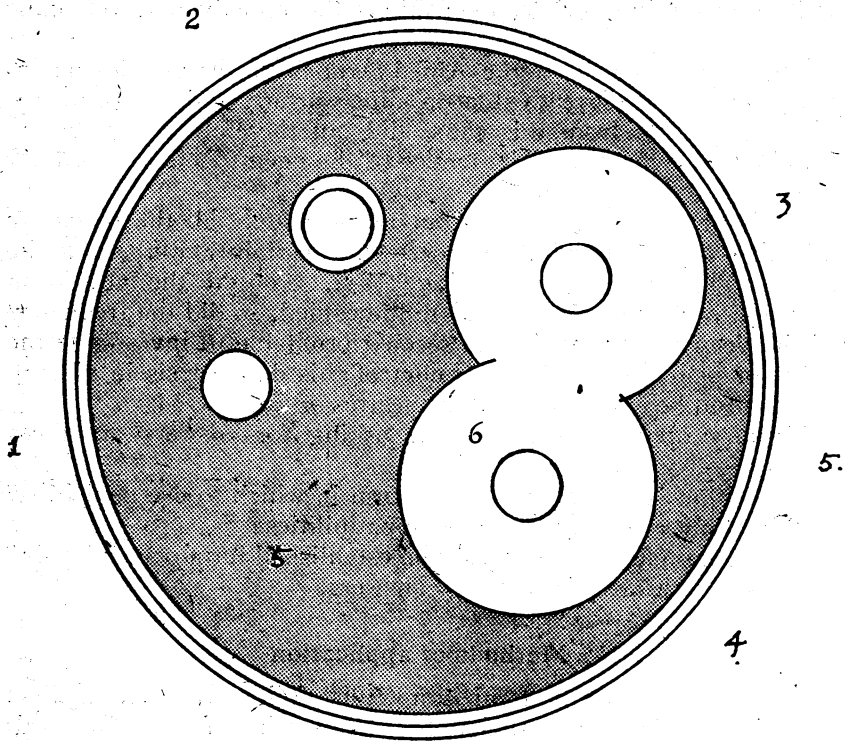


DIAGRAM 3.

1. Vaseline with penicillin. 2. Adipis lanæ with penicillin. 3. Lanette wax with penicillin. 4. Penicillin 10 units per c.c. (control).

5. Shading = *S. aureus* haem. 6. Area of bacterial inhibition.

This diagram shows the bacterial inhibition which remained at the end of 12 days during which the plate was kept at room temperature. The test is crude and qualitative, and it is not possible to ensure that the vehicle is equally distributed in each hole, but it does show that lanette wax retains the penicillin longer than the other vehicles.

Hole No. 1.—500 units penicillin per gramme vaseline. Hole No. 2.—500 units penicillin per gramme lanoline. Hole No. 3.—500 units penicillin per gramme lanette wax. Hole No. 4.—10 units penicillin as control in water.

| | June 29 | June 30 | July 3 | July 11 |
|--|---------|-------------|--------------|---------------|
| Base | | After 1 day | After 4 days | After 12 days |
| 10 units penicillin in distilled water | | 14 mm. | 12 mm. | 12 mm. |
| Lanoline and 500 units penicillin per gramme | | 5 mm. | Nil-1 mm. | Nil-1 mm. |
| Vaseline and 500 units penicillin per gramme | | 9 mm. | 1 mm. | Nil. |
| Lanette wax and 500 units penicillin per gramme | | 13 mm. | 12 mm. | 12 mm. |

1. The numbers refer to the increase in diameter in millimetres of the circles of bacterial inhibition.

2. It will be noted that after 12 days the activity of penicillin in lanette wax was still present, whereas in lanoline and vaseline it had almost died away.

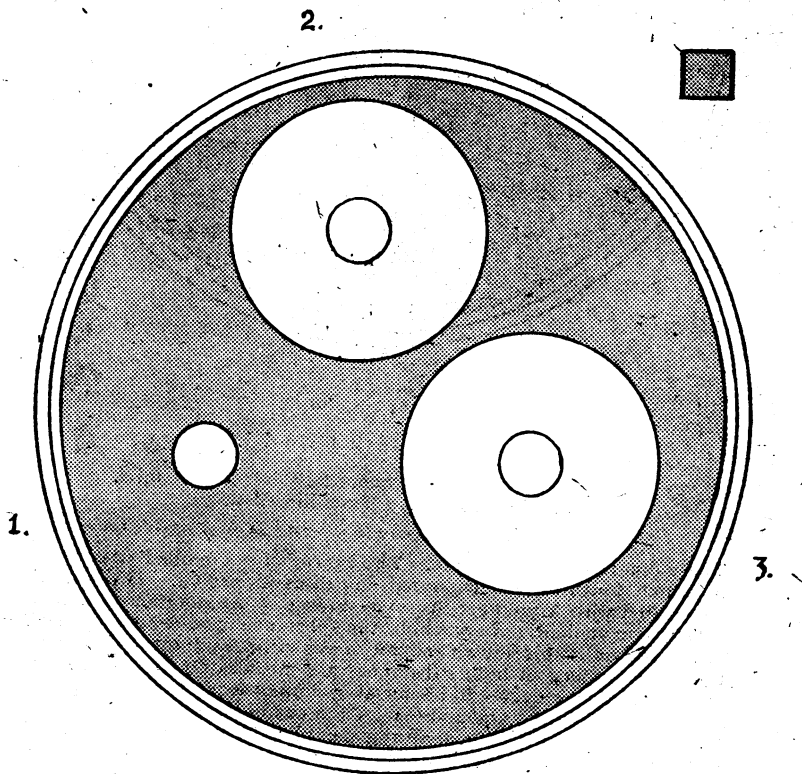
Incompatibilities

The local ocular incompatibilities were checked by using a Petri dish preparation as described later.

Fifty units of penicillin in distilled water were placed in one hole : this gave a uniform inhibition of growth of 36 mm. diameter.

In the second hole only the substance to be tested was placed : *e.g.*, proflavine 1/4,000 produced a circle of 3 mm. increase inhibition, liq. hydrarg perchlor. 1/5,000 produced a 4 mm. increase circle, whilst pure carbolic acid extended to 10 mm. increase.

The third hole contained penicillin together with the substance for which it was desired to ascertain compatibility.



B.

DIAGRAM 4.

1. Atropine alone. 2. Penicillin 50 units. Atropine + penicillin, 50 units.

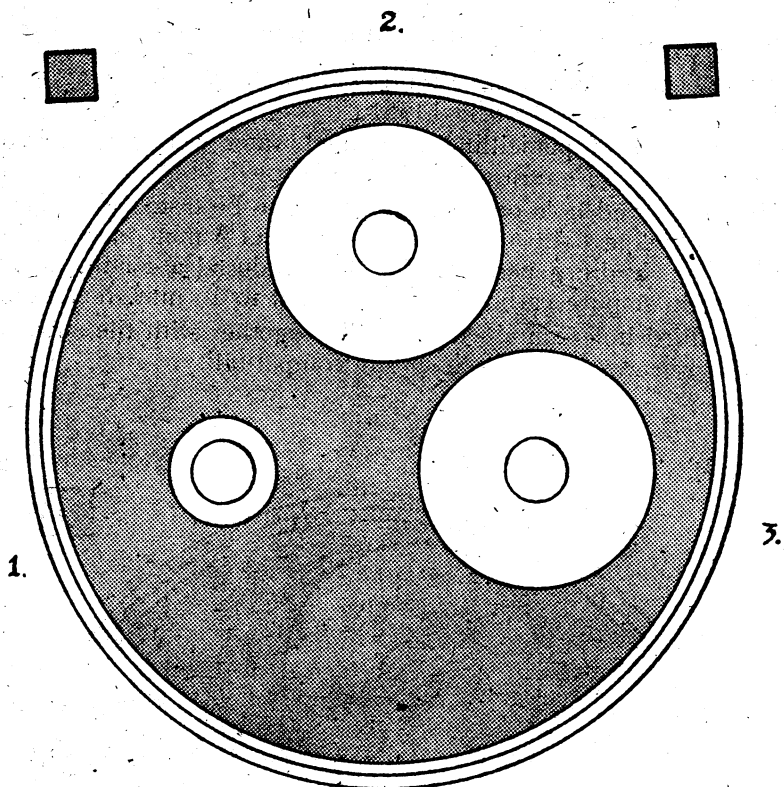


DIAGRAM 4a.

1. Hydrarg. perchlor. alone.
2. Penicillin 50 units.
3. Hydrarg. per. + penicillin, 50 units.

Shade shows bacterial growth ; white shows inhibition.

These diagrams are full scale. The Petri dishes are filled with media in which holes have been bored and discs extracted. The plate is inoculated with a young culture of *S. aureus* haemolyticus which is sensitive to penicillin. In one hole, the substance to be tested is placed, in the second hole a known amount of penicillin, and in the third hole the same amount of both substances are mixed. Qualitative results are judged by the degree of bacterial inhibition around the hole.

Diagram 4 illustrates atropine—penicillin combination.

Diagram 4a illustrates liq. hydrarg. perchlor. 1:5000 combination.

In both instances, the penicillin acts to an equal degree when pure or mixed with the drug in question.

The following table briefly summarises the results and shows that by these qualitative crude tests, penicillin is not inhibited by any of the ocular remedies mentioned in common use.

The figures refer to the size of the circle of bacterial inhibition.

| Substance | Bacterial inhibition of substance alone | Bacterial inhibition of substance with 50 units penicillin |
|------------------------------------|---|--|
| Gtt. adrenalin hydrochlor. 1/1000 | Nil | 36 mm. diameter |
| Gtt. atropine sulph. 1 per cent. | Nil | 36 mm. diameter |
| Gtt. cocaine hydr. 4 per cent. ... | Nil | 36 mm. diameter |
| Gtt. Novutox 2 per cent. ... | Nil | 36 mm. diameter |
| Gtt. albucid 30 per cent. ... | Nil | 36 mm. diameter |
| Gtt. proflavine 1/4000 ... | 3 mm. diameter increase | 36 mm. diameter |
| Gtt. pure acid carbolic ... | 10 mm. diameter increase | 36 mm. diameter |
| Gtt. argyrol 20 per cent. ... | Nil | 36 mm. diameter |
| Liq. hydrarg. perchlor. 1/5000... | 4 mm. diameter increase | 36 mm. diameter |
| Penicillin 50 units ... | 36 mm. diameter increase | — |

4. INJECTIONS. (a) *Intramuscular*.—1,500 units of Sod. Penicillin are dissolved in 2 c.c. sterile water and administered every three hours. It is not a popular method and it is heartily disliked by patients. It will be shown later that it has proved of little benefit in ophthalmic cases, but orbital infections may benefit.

(b) *Anterior chamber*.—The extreme solubility and low toxicity of pure penicillin enables a high concentration to be set up in the anterior chamber. Here, 1,000 units per minim have been used for injections into the anterior and vitreous chambers without ill effects.

For the treatment of established intra-ocular infection two methods of choice therefore present, namely parenteral intramuscular injection and direct injection into the chambers of the eye.

1. *Intramuscular injections*.—Before the value of this route to ocular infection could be assessed, it was necessary to establish that penicillin did actually enter the media of the eye when injected into muscles. It has been observed that it does not enter the pleural cavity, the synovial cavity or cerebro-spinal spaces when given by this route, but information as to behaviour to the normal or abnormal eye was lacking. Experiments to try and obtain this information were conducted in the following manner.

In the case of normal eyes, large injections of penicillin were given intramuscularly to moribund patients and their eyes were examined as speedily as possible post-mortem. For traumatised eyes, it was easier to shorten the time lag between injection and collection, as it was possible to examine the media at a given time after injection. Hence the time opportunity for the assay of normal eyes arrived less quickly than it did for abnormal eyes.

Two methods of penicillin assay were employed :—

(a) *Plate Test*.—A Petri dish containing blood agar had five circles of 8 mm. diameter removed by a cork borer, leaving shallow holes. Thereafter it was sterilised and inoculated with a young culture of penicillin-sensitive Oxford *S. aureus*.

Into one hole was placed 50 units of penicillin in distilled water which produced a circle of bacterial inhibition 12-14 mm. wide: one hole was left blank as a control. Into the others were placed the fluids in which it was desirable to detect the presence of penicillin: this was shown by inhibition of staphylococcal growth around the hole. Although this test is crude and not sensitive for small amounts it was a useful clinical and qualitative indication.

(b) *Dilution test.*—The material to be tested was put up in various dilutions with normal saline, for example, aqueous and vitreous fluids neat, and with $\frac{1}{2}$, $\frac{1}{4}$, $\frac{1}{8}$, and $1/16$ dilutions.

One-fifteenth c.c. of each was placed in a small test tube to which $1/50$ th c.c. glucose was added for bacterial growth.

Each tube was then subcultured to exclude contaminants. To each tube was then added $1/50$ th *S. aureus* haemolyticus suspension which had been previously proved to be penicillin sensitive. This amount was approximately equivalent to 5 millions staphylococci.

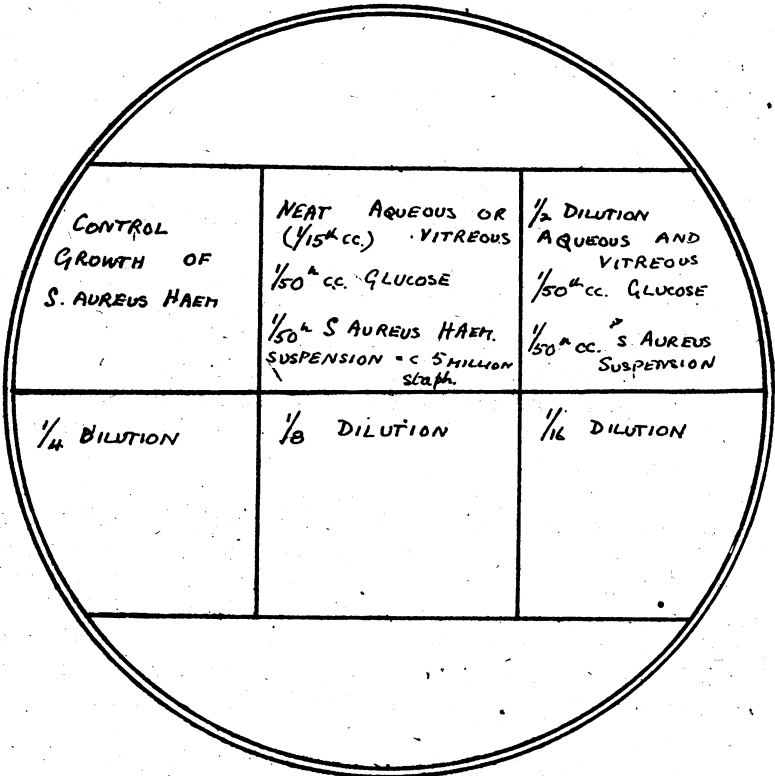


DIAGRAM 5.

Penicillin dilution test.

NORMAL EYES. Media Collected Post-Mortem Dilution Test.

| No. | Name | Nat. | History | Penicillin | Collection | Assay Result | Remarks |
|-----|-------------|------|---|---|---|--------------------------------------|---|
| 1 | Cpl. S. ... | P. | Wounded May 24. Large shell fragment passed through left orbit into the left temporo-sphenoidal lobe. Died May 28, 23.40 hours | I.M. course 4 million units May 25-27. 1500 units 22.00 hours, May 27 | Right eye 09.00 hours, May 29 (a) 9½ hours after death (b) 35 hours after last dose | A. No inhibition V. No inhibition | This case is not satisfactory owing to lapse of time between the last dose and collection |
| 2 | Pte. D. ... | B. | Wounded May 23. Penetrating head wound through right temporal fossa. Penetrating wounds of chest and abdomen. Died 03.00 hours, May 24 | Nil | Left eye 09.45 hours, May 24 (a) 6½ hours after death (b) not applicable | A. No inhibition V. No inhibition | This was a control case to examine whether any natural inhibiting substances were present in the ocular media |
| 3 | Fus. Mc.G. | B. | Wounded May 16. Penetrating wound of head by shell fragment which lacerated left temporal lobe. Basal meningitis. Died 17.25 hrs., May 29 | I.M. course terminating with last dose at 16.30 hours, May 29 | Right eye 11.30 hours, May 30 (a) 18 hours after death (b) 19 hours after last dose | A. No inhibition V. No inhibition | Also rather a late case |
| 4 | Tpr. B. ... | B. | Wounded May 28. Mortar fragments caused penetrating wounds of left occiput, chest and buttock. Died 03.00 hours, May 29 | I.M. course May 28-29. Last dose 02.00 hours, May 29 | Right eye 09.00 hours, May 29 (a) 6 hours after death (b) 7 hours after last dose | A. No inhibition V. No inhibition | — |
| 5 | Gdsn. G. | B. | Wounded May 26. Penetrating shell wound of head and face with extensive laceration of the brain. Died 04.00 hours, May 28 | Nil | Left eye 10.00 hours, May 28 (a) 6 hours after death (b) not applicable | A. No inhibition V. No inhibition | Control case |

NORMAL EYES. Media Collected Post Mortem Dilution Test—continued.

| No. | Name | Nat. | History | Penicillin | Collection | Assay | Remarks |
|-----|-------------|------|---|---|---|--------------------------------------|---|
| 6 | Spr. B. ... | B. | Extensive burns (primus) of face, trunk and arms, May 16. Died 19.00 hours, May 29 | Two courses (I.M.) (a) May 18-21, 350,090 units (b) May 26-29, 390,000 units Last dose 18.00 hours, May 29 | Right eye 22.00 hours, May 29 (a) 3 hours after death (b) 4 hours after last dose | A. No inhibition V. No inhibition | Short interval between dose, collection and assay |
| 7 | Spr. M. S. | Ind. | Wounded May 29. Penetrating wounds of head, chest and abdomen by mortar fragments. Died 22.00 hours, May 29 | I.M. dose 30,000 units at 18.00 hours | Right eye 24.00 hours, May 29 (a) 2 hours after death (b) 6 hours after last dose | A. No inhibition V. No inhibition | — |

ABNORMAL EYES. (Traumatised).

| No. | Name | Nat. | History | Penicillin | Collection | Assay | Remarks |
|-----|---------|------|--|---|--|--|---------|
| 1a | Gnr. W. | B. | Wounded May 13. Mortar fragment entered left orbit and passed into the skull through the roof. It lacerated the left temporo-sphenoidal lobe, crossed the middle fossa and ended up in the right temporo-sphenoidal lobe. Died May 20, 22.00 hours | I.M. Penicillin May 15-20. Last dose 20.00 hours, May 20 | Right eye: avulsion of the optic nerve with intra-ocular haemorrhage. 09.00 hours, May 21. (a) 11 hours after death (b) 13 hours after last dose | A. No bacteriostasis V. No inhibition | — |

ABNORMAL EYES. (Traumatised)—continued.

| No. | Name | Nat. | History | Penicillin | Collection | Assay | Remarks |
|-----|-------------|------|--|--|--|--|--|
| 2a | Pte. C. ... | B. | Wounded May 19. Shell fragment shattered the mandible and left maxilla. Died from gas gangrene. 20.00 hours, May 20 | One dose 30,000 units 18.00 hours, May 20 | Left eye contusion of globe. Vitreous haemorrhage 21.00 hours, May 20 (a) One hour after death (b) 3 hours after last dose | A. Slight bacteriostasis V. Slight bacteriostasis | This was an early case and the only one in the series which showed slight bacterial inhibition |
| 3a | Pte. G. ... | B. | Wounded May 30. Mortar fragments spattered face and entered the left eye. The left eye had a penetrating wound with large prolapse of iris. On June 20 there was endophthalmitis and low tension with considerable irritation. Enucleation June 28: section showed almost total retinal detachment with extensive infiltration of the vitreous | June 28, I.M. (a) 15,000 units, 07.00 hours (b) 15,000 units, 09.00 hours (c) Enucleation 09.30 hours | (a) Not applicable (b) Half-hour after last dose | A. No inhibition V. No inhibition | — |
| 4a | Spr. L. ... | B. | Wounded May 31. Extensive mine wounds of face, eyes and hands: penetrating wounds of the right eye with prolapse of iris; multiple intra-ocular foreign bodies. June 20, extensive inflammation of vitreous: endophthalmitis. No P.L. Enucleation June 28 | June 28, I.M. (a) 15,000 units, 06.30 hours (b) 15,000 units, 07.30 hours (c) Enucleation 09.30 hours | (a) Not applicable (b) 2 hours after last dose | A. No inhibition V. No inhibition | — |

ABNORMAL EYES. (Traumatised) — continued.

| No. | Name | Nat. | History | Penicillin | Collection | Assay | Remarks |
|-----|--------------|------|---|--|---|--|---------|
| 5a | Spr. J. ... | P. | Wounded May 13. Multiple shell wounds of face and chest. Penetrating wound of left eye with retained intra-ocular foreign body. This was removed by magnet extraction but on June 16 the eye was shrinking, soft and irritable. Enucleation June 28 | June 28, I.M. (a) 15,000 units, 08.00 hours (b) 15,000 units, 09.30 hours (c) Enucleation 10.00 hours | (a) Not applicable (b) Half-hour after last dose | A. No inhibition V. No inhibition | — |
| 6a | Pte. P. | B. | Wounded May 30. Multiple shell wounds of face, chest, arms and legs. T and I penetrating wound of right eye. Enucleation June 7 | June 7, I.M. (a) 15,000 units, 12.00 hours (b) 15,000 units, 14.00 hours (c) Enucleation 15.00 hours | (a) Not applicable (b) One hour after last dose | A. No inhibition V. No inhibition | — |
| 7a | Pte. S. K. | I. | Wounded July 28. Multiple mortar wounds of face, eyes and hands. Penetrating wound of right eye with iris prolapse. Excision and conjunctival-flap. Aug. 18 hypopyon iritis. Aug. 26 endophthalmitis, painful eye; no P.L. Aug. 27 I.M. penicillin and enucleation. | (a) August 27, 09.50 hours; 15,000 units I.M. (b) 10.20 hours, 15,000 units (c) Enucleation 11.30 hours | (a) Not applicable (b) One hour after last dose | A. No inhibition V. Sterile 48 hours aerobic culture | — |
| 8a | Pte. F. ... | B. | Wounded Aug. 3. Box mine caused penetrating wounds of left eye, hands and face. Aug. 3 excision of iris, prolapse and conjunctival flap. Aug. 7 endophthalmitis. Aug. 27 enucleation | Nil. Enucleation 12.30 hours | 13.30 hours | Forty-eight hour culture sterile. Assay nil. Control at same time as 7a. | — |

Next, the tubes were incubated for 6 hours and then subcultured to fresh plates which had been divided into squares. One square had a control culture of *S. aureus* growing whereas in others the dilution of the substance in question containing the known number of organisms: (Diagram No. 5).

The inhibitions at any dilution could thus be noted.

The results are classified as follows:—

- (1) In normal eyes.
- (2) In wounded eyes, *i.e.*, scleral rupture, haemophthalmos.

In both types of eyes, the aqueous was withdrawn by a fine hypodermic needle: the vitreous was obtained by a scleral incision and the insertion of a small sterile test tube into the wound.

Normal eyes were obtained from patients who had died of wounds with no ocular involvement: abnormal eyes had lesions such as avulsion of the optic nerve, haemorrhagic glaucoma (haemophthalmos) phthisis, bulbi, etc.

Analysis of results

(1) Five normal eyes were removed as speedily as possible after death from patients who had received intramuscular penicillin, the aqueous and vitreous humours were subjected to penicillin assay immediately. There were two control eyes.

(2) Seven eyes with abnormality of trauma or infection were examined for penicillin immediately after enucleation. There was one control eye.

(3) Both groups had received intramuscular penicillin before death or before enucleation at the times stated.

In Group 1 of normal eyes, the average time of assay was carried out $6\frac{1}{2}$ hours after death, and 14 hours after administration of the last dose (9 hours if Case No. 1 is excluded). These intervals must be regarded as too long; speed of collection was necessarily limited by practical considerations. No inhibition of bacterial growth by the ocular media from any of these cases was detected by the tests used. In order to exclude the presence of a natural inhibitory substance in the ocular media two control cases which had received no penicillin were tested; these also gave negative results and no bacterial inhibition.

In Group 2 which was composed of damaged eyes, the rate of collection was better as the ocular media could be examined much closer to the time after the last dose of penicillin had been given. The average time of examination after this dose was therefore much shorter even to half an hour in two cases.

Conclusion

From these experiments and controls it appeared that when penicillin was injected intramuscularly it did not readily pass into

the humours of the eyes nor in such quantities that it was detectable by the tests described. It can of course be argued that the tests employed such dilutions that they were not sufficiently sensitive and that the time interval after collection was too long. On the other hand, however, if the penicillin was present in such minute amounts the prospects of controlling such gross infections as occurred within the eye, when penicillin was administered therapeutically by this route, did not appear to be very bright. Such later was found to be the case.

In view of the disappointing results of general penicillin therapy, it remained to investigate the local effect of the direct injection of penicillin into the aqueous and vitreous humours of infected eyes.

Technique of aspiration and Penicillin replacement.—These injections were all carried out under pentothal anaesthesia using sodium penicillin solution (1,000 units per minim of distilled water). The aqueous or vitreous fluid withdrawn was subjected to 48 hours aerobic culture in every case and was always found to be sterile. No general effects were noted as a result of these injections: local effects in one case were an increase of pain accompanied by conjunctival oedema. It is possible that tension alterations might cause pain if more than two minims of fluid are withdrawn and replaced, or if the manoeuvre is not executed very slowly.

Aqueous humour.—No antiseptics were used in the conjunctival sacs for twenty-four hours prior to aspiration. After a small incision had been made into the cornea with the point of a broad needle, a fine hypodermic needle (23 S.W.G. 1 in. long) mounted on a 2 c.c. all glass syringe was inserted obliquely into the anterior chamber. Usually the intra-ocular pressure forced the plunger up and two minims of turbid aqueous were withdrawn. The syringe was quickly changed leaving the needle in position and a second syringe attached by means of which two minims of penicillin solution (2,000 units) were injected very slowly into the anterior chamber. The needle was then quickly withdrawn and the anterior chamber retained: the brown penicillin solution could be seen mixing with the turbid aqueous. The aqueous fluid in the first syringe was despatched immediately for culture.

Vitreous humour.—In order to avoid conjunctival contamination a small conjunctival flap was reflected between the external and inferior recti muscles. After the sclera had been partially incised, a hypodermic needle was passed into the vitreous chamber pointing upwards, backwards, and inwards for a distance of about a quarter of an inch, depending on the site of the exudate, and at a point approximately ten millimetres from the limbus. Generally light suction was necessary to extract fluid: in one case it was

impossible. Replacement by penicillin solution of the same strength as described was done by change of syringes and the procedure completed by replacement of the conjunctival flap.

Cases

In the present series of cases described, the need for injection of penicillin into the anterior chamber has not arisen so frequently as it has in the case of the vitreous chamber since the anterior chamber is more readily cleared of exudate by a combination of sulpha therapy and protein shock.

In Case 1c the hypopyon actually reformed and increased after being partially aspirated and replaced by penicillin solution: there was no improvement. Improvement was marked after sulphonamide therapy: no protein shock was given.

The outstanding feature of Case 2c was the purulent infiltration in the deep stroma of the cornea which originated from stone particles. In spite of a susceptible organism, penicillin as powder in the conjunctival sac and as solution in the anterior chamber failed to control the infection which went on to general involvement of almost the entire cornea. Protein shock initiated an improvement which Saemisch sections completed. Sulphonamide therapy had no striking effect.

Case 3c showed the beneficial effect of shock therapy by typhoid vaccine on the hypopyon: this is by no means uncommon. It looked as if the hypopyon disappeared from the anterior chamber only to appear in the posterior chamber at the far end of the penetrating wound. Here again culture of the vitreous was sterile and no form of therapy controlled the deep infection.

Case 4c was an example showing the intravitreal use of penicillin combined with the removal of an intra-ocular body eight days after wounding. The eye settled quickly probably due far more to the removal of the foreign body and the natural resistance of a Ghurkha than to the penicillin therapy.

Case 5c was a case of severe infection almost amounting to panophthalmitis. A large dose of penicillin was injected into the turbid yellow vitreous with no improvement. Two days later when the eye was removed and the vitreous subjected to penicillin assay a high concentration of penicillin still remained.

Case 6c showed gross involvement of the vitreous chamber but maintained a steady downward progress to painless shrinkage of both eyes. The vitreous culture was sterile, and all along the inflammatory reaction of the eyes was not marked.

Case 7c is parallel to Case 4c. After removal of the foreign body the eye settled, but the intravitreal injection of penicillin had no influence on the spread of the exudate afterwards.

These two cases also probably benefited to some extent by the drainage through a posterior sclerotomy incision.

| No. | Name | Nat. | History | Penicillin | Cultures | Assay | Comment |
|-----|--------------|------|--|---|---|--|---|
| 1c | Pte. M. | B. | <p>Wounded June 22 when a house in which he was hiding was struck by a shell. A splinter entered the right eye; no other serious injuries. Pen. central corneal wound.</p> <p>June 22. Giant magnet extraction of 1.0 F.B. by post. route—no penicillin applied.</p> <p>June 24. Hypopyon; yellow lens flocculi; yellow retro-lenticular reflex.</p> <p>June 25. Course of I.M. penicillin half-million units completed.</p> <p>June 26. No appreciable improvement. 3 mm. hypopyon and yellow lens flocculi remain. Aqueous aspirations: 2 minims. 30,000 units Sod. Pen. in 2 min. dist. water injected. A.C. not lost.</p> <p>June 27. Further increase in hypopyon, no undue reaction; no pain and no improvement.</p> <p>June 28. Full course of sulphathiazole.</p> <p>July 1. Oedema less. Much better.</p> <p>August 9. Eye white post caps. synechiae. Opaque lens. P.L. accurate. V. C.F.</p> <p>August 16. Lens discission.</p> <p>August 20. No undue post-operative reaction.</p> <p>September 27. Eye white and quiet.</p> | <p>(a) June 25. Course of 15,000 units 3 hourly I.M. H.B.s atropine, etc. Total course 500,000 units. No clinical improvement.</p> <p>(b) June 26. Aqueous injection of 30,000 units. No clinical improvement. In this early case a high penicillin concentration was obtained in the A.C. but there was no undue reaction.</p> | <p>June 26. Aqueous humour—negative (aerobic) 48 hours.</p> | <p>June 26. Aq., no inhibition during I.M. course.</p> | <p>(a) No improvement after I.M. and A.C. penicillin.</p> <p>(b) T.A.B. shock deliberately withheld.</p> <p>(c) Improvement after sulphathiazole course</p> |
| 2c | Sgt. B. | B. | <p>Wounded June 27 by Schu mine. Severe lacerations of lids; penetrating wounds of both eyes; multiple stone foreign bodies and gross infection of the left eye. Blast oedema of lids made examination at this stage impossible.</p> | | | | |

| No. | Name | Nat. | History | Penicillin | Cultures | Assay | Comment |
|-----|------------------------|------|--|---|---|-----------------------|--|
| 2c | Sgt. B. ... (cont.) | B. | <p>June 29. The fused eye had been previously removed. The left eye showed a cornea peppered to all depths with stone particles around which purulent exudate was forming. Culture <i>S. aureus</i>, haemolyticus. X-ray: no radio opaque intra-ocular foreign bodies in either eye. Full course sulphathiazole; local application of penicillin powder and atropine half per cent. every three hours.</p> <p>July 10. Corneal infection completely uncontrolled. Steady extension of deep purulent corneal infiltration; hypopyon formed and dimly seen. Local penicillin powder does not appear to be effective.</p> <p>July 13. Aspiration replacement of 2000 units Sod. Penicillin in anterior chamber. Aqueous culture.</p> <p>July 20. No improvement: diffuse yellow infiltration of entire cornea, almost total hypopyon; paracentesis.</p> <p>July 21. Seventy-five million T.A.B. intravenous injection. T. 102. Paracentesis re-opened.</p> <p>July 28. Oedema of lids and conjunctiva less but corneal condition no better.</p> <p>August 8. Saemisch section and evacuation of turbid aqueous.</p> <p>August 17. Saemisch section repeated.</p> <p>August 19. 100 million T.A.B. vaccine intravenously. T. 101.</p> <p>August 21. The local inflammation in the eye showed signs of improvement following the second Saemisch section.</p> | <p>(a) Local Pulv. penicillin 3 hourly into conjunctival sac.</p> <p>(b) Aspiration replacement of 2,000 units sod. penicillin in anterior chamber.</p> | <p>Aqueous 48 hour aerobic—sterile.</p> | <p>Not applicable</p> | <p>No undue pain</p> <p>First signs of general improvement.</p> <p>Corneal condition subsiding.</p> <p>Saemisch section initiated the improvement.</p> <p>(a) Gross conjunctival and corneal infection by <i>S. Aureus</i> haemolyticus not controlled by penicillin</p> |

| No. | Name | Nat. | History | Penicillin | Cultures | Assay | Comment |
|-----|------------------------|------|---|--|--|-------|--|
| 2c | Sgt. B. ... (cont.) | B. | <p>September 11. The cornea was healed and showed deep scarring in the lower half; the upper and outer quadrant was clear. Linear scars of the Saemisch sections were not unduly dense. The anterior chamber was reformed: anterior synechiae were present but not easily seen. Iris and lens details not discernible. Projection brisk and accurate. Vision: P.L., to gross hand movements. Tension: definitely plus. Case evacuated to U.K.</p> | | | | <p>(b) Improvement due to T.A.B. therapy and Saemisch sections. (c) In spite of heavy corneal infection, the aqueous culture was sterile</p> |
| 3c | Cpt. S. ... | I. | <p>August 8. Walked into barbed wire at night and received a penetrating wound of the right eye. August 10. Infected penetrating wound of cornea: 2 mm. hypopyon; iritis; local lens changes. V. H. M. Full course of sulphathiazole. August 12. Hypopyon increasing. 50 million T.A.B. shock. T. 101.8° F. August 16. Eye improving: hypopyon less, lens cloudy; retro-tentacular yellow exudate appearing in vitreous behind site of penetration. 75 million T.A.B. shock. T. 101° F. August 18. No hypopyon; yellow vitreous reflex increasing; exudate now clearly seen. Very poor projection. August 27. I.M. course of penicillin 500,000 units. August 31. No sign of improvement. Vitreous exudation now very extensive and projection very poor. September 10. Intravitreous penicillin injection. Vitreous aspiration and culture. September 11. Severe ocular pain: increase in conjunctival oedema.</p> | <p>August 27. I.M. course of penicillin. 15,000 units 3 hourly. September 10. Intra-vitreous injection 2,000 units sod. penicillin.</p> | <p>48 hour aerobic vitreous culture negative</p> | | <p>(a) The hypopyon in the anterior chamber dispersed as a</p> |

| No. | Name | Nat. | History | Penicillin | Cultures | Assay | Comment |
|-----|------------------------|------|---|--|---|-------|--|
| 3c | Cpt. S. ... (cont.) | I. | <p>September 26. Local inflammation has subsided; cornea bright; A.C. clear, post. synechia; local lens opacity; general canary-yellow vitreous reflex; V. P.L. T. soft.</p> <p>October 5. Enucleation. Implantation of Perspex ball in Tenon's capsule.</p> | | | | <p>result of shock therapy.</p> <p>(b) General I.M. penicillin caused no improvement.</p> <p>(c) Vitreous culture sterile.</p> |
| 4c | Spr. N. ... | I. | <p>August 29. Wounded by the accidental explosion of a Mills grenade. Penetrating wound of the left eye, neck and right thigh.</p> <p>August 31. Penetrating scleral wound of left eye. Explored and covered by conjunctival flap at Indian C.C.S.</p> <p>September 5. Acute iritis; local lens changes; yellow vitreous reflex. V. no P.L. X-ray: radio opaque intra-ocular foreign body.</p> <p>September 6. Vitreous aspiration for culture. Infero lateral posterior sclerotomy. Haab extraction of steel foreign body; escape of turbid fluid. 2000 units of penicillin were injected through the scleral incision and appeared to be retained.</p> <p>September 23. Normal convalescence; the eye settled and became white but the yellow vitreous reflex persisted. Tension normal to soft, and vision no P.L.</p> | <p>September 6. Intra-vitreous injection 2,000 units penicillin.</p> | <p>48 hours culture— aerobic.</p> <p>(a) Vitreous—sterile.</p> <p>(b) foreign body—sterile.</p> | | <p>The eye settled after removal of the foreign body and injection of penicillin. Such a result, however, is common after such operations without penicillin.</p> <p>The vitreous exudation was not noticeably affected.</p> |

| No. | Name | Nat. | History | Penicillin. | Culture | Assay | Comment |
|-----|-------------|-------|--|---|--|---|---|
| 5c | Pte. M. ... | Maori | <p>August 2. Wounded by shell fragment. Penetrating corneal wound of right eye; large prolapse of iris and traumatic cataract. Conjunctival vizor flap <i>in situ</i>. Large intra-ocular foreign body removed at Mobile unit.</p> <p>August 8. Retraction of flap; acute iritis; lens cloudy; gross infection of vitreous.</p> <p>August 9. Intra vitreous penicillin injection.</p> <p>August 11. Condition worse. Severe pain and no perception of light. Enucleation. Vitreous assay.</p> | <p>August 9. Intra vitreous injection of 5,000 units sod. penicillin.</p> | <p>Aerobic 48 hours—vitreous culture negative.</p> | <p>Assay of vitreous showed high concentration of penicillin.</p> | <p>(a) Severe infection of vitreous. (b) Penicillin was found in vitreous after injection. (c) No benefit from intra-vitreous injection. (d) Vitreous culture sterile.</p> |
| 6c | Gdsn. W. | B. | <p>July 28. Wounded by Schu mine. Pepper wounds of face; penetrating wounds of both eyes. No other serious injury. The sclera of the right eye had been ruptured, sutured and covered by vizor flap. The left eye had a corneal wound with iris prolapse. Excision of prolapse; removal of stone foreign bodies in iris; vizor flap.</p> <p>August 9. Both eyes settling; stitches out; flaps retracting. Full course of sulphamide. There was canary-yellow reflex of the vitreous in both eyes. R. V. P.L., L. V. no P.L.</p> <p>August 17. No improvement in yellow reflex although eyes were whitening. R. eye: vitreous aspiration and injection of penicillin.</p> | <p>Right eye. 2,000 units intra vitreous injection.</p> | <p>48 hour aerobic vitreous culture sterile.</p> | | <p>(a) No improvement from sulphamide or penicillin therapy. (b) Both eyes improved a little after shock therapy. (c) Although</p> |

| No. | Name | Nat. | History | Penicillin | Culture | Assay | Comment |
|-----|---------------------|------|--|---|--|-------|--|
| 6c | Gdsn. W. (cont.) | B. | <p>August 20. No undue effects and no improvement as a result of the intra-vitreous injection. 75 million T.A.B. shock. T. 102.8° F.</p> <p>September 13. Both eyes quiet and white. Extensive infiltration by yellow exudate in both vitreous chambers. Tension soft in both eyes. Total blindness.</p> <p>September 5. Wounded by splinter when shell struck his tank turret. Limbal penetrating wound of left eye.</p> <p>September 7. Excision of prolapse; vizor flap at Mobile unit.</p> <p>September 16. Acute iritis; clear lens, canary-yellow vitreous exudate. X-ray: single radio opaque intra-ocular foreign body. Posterior sclerotomy and Haab removal. 2000 units of penicillin injected into vitreous through scleral incision.</p> <p>October 8. Left eye quiet and white. Diffuse yellow reflex behind the lens infiltrating the vitreous. This appears to have increased since the operation. Tension, soft. Vision, faint P.L.</p> <p>October 21. Left eye painful and irritable, globe shrinking rapidly. Vision, no P.L. Enucleation and implantation of Perspex globe.</p> | <p>Intra vitreous injection of 2,000 units of penicillin.</p> | <p>(a) Vitreous—sterile. (b) Foreign body—sterile.</p> | | <p>both eyes appeared alike there was no appreciable difference as a result of intra-vitreous penicillin injection of one eye.</p> <p>No improvement as a result of intra - vitreous penicillin injection.</p> |
| 7c | Sgt. T. ... | B. | | | | | |

(5) *Surgical treatment.*—It is not intended here to add refinements of surgical technique to those descriptions already published by experienced military ophthalmologists, but rather to draw attention to an old operation which can play an important part particularly in corneal lesions resulting from Schu mines.

If the diffuse purulent infiltration throughout the substantia propria of the cornea is allowed to persist the eventual physiological impairment of vision from deep scar tissue will certainly be great. Drastic measures aiming to bring about speedy resolution are indicated.

The removal of one or two stone foreign bodies and the application of pure carbolic acid has no influence on the deeper infiltration. Nor is it possible to curette because the infiltration has spread in every direction amongst the interstices of the corneal tissue. Also, the actual cautery would leave far too dense a scar if it had to be applied to eliminate such an infection.

Corneal section after the manner of Saemisch has proved of value in these desperate cases. The section should be made once or twice through the area of deepest infiltration and the length of section should be adequate in order to evacuate the sticky hypopyon which so frequently co-exists.

No fears need be entertained as to the final density of the scar or the risk of broad anterior synechiae.

Time and again this operation has proved of value when paracentesis, without opening the actual area of infiltration, has not been satisfactory.

Summary

(1) An account of clinical experiments and methods of treatment to control deep intra-ocular infection in battle casualties is rendered. This work has been carried out under conditions of active service.

(2) To control deep intra-ocular infection in warfare the following measures are recommended:—

(a) The adoption of the Anti-Mine vizor particularly for selected troops likely to encounter Schu mines. This has been proved to be practicable.

(b) Simple cleansing measures of eye wounds by general surgeons at F.S.U. level.

(c) The employment of expert ophthalmic surgeons and adequate equipment as far forward as possible thus reducing time lag after wounding, and ensuring the early extraction of intra-ocular foreign bodies with sealing of the penetrating wound.

(d) Routine insufflation of penicillin powder at an early stage into all wounds of the eye: sterilisation of the conjunctiva by penicillin must be considered as established fact.

(e) Air evacuation to Base ophthalmic wings.

(f) Sulphonamide therapy and protein shock.

(g) Saemisch section in selected cases.

(3) It appears from these clinical experiments, but it cannot be considered to be proven that (a) penicillin does not enter the ocular media when given by intramuscular injection.

(b) That such therapeutic injections do not influence the course of deep infections of the eye.

(c) That the eye will tolerate and retain large concentrations of penicillin when injected into the media but that such concentrations do not control deep infection thereof.

(d) The value of penicillin in the control of deep intra-ocular infection must therefore be in prevention rather than in cure: hence it should be used as a local application as soon as possible after the eye is wounded.

(4) It is suggested that since the exudates of the anterior chamber and of the vitreous chamber are consistently sterile as well as the intra-ocular foreign bodies, they should be designated "anterior" hypopyon and "posterior" hypopyon respectively since they have an identical pathology.

In conclusion this work must be taken to express many of the thoughts, verbal and written, of the team of ophthalmologists of this Force who have been too busily occupied recently to publish them. As a member of that team I am privileged to carry out that duty for them, in the hope that they may be of some value to our colleagues in other Theatres. The Army pathologists, as ever, have been most helpful, particularly Majors Facey and Cunningham. Brigadier Sir Stewart Duke-Elder has seen to it that we always had the "tools" and there has been no lack of equipment with which to do the job. Pte. Mervyn Suart, ophthalmic artist at a Base ophthalmic wing has kindly provided the drawings.

BIBLIOGRAPHY

1. CRAWFORD, T. and KING, E. F.—The value of penicillin in the treatment of superficial infections of the eyes and head. *Brit. Jl. Ophthal.*, Vol. XXVIII, p. 373, 1944.
2. STALLARD, H. B.—*Brit. Jl. Ophthal.*, Vol. XXVIII, p. 261, 1944.
3. SKEOCH, H. J.—Pending publication.
4. MILNER.—*Brit. Med. Jl.*, August 5, 1944.