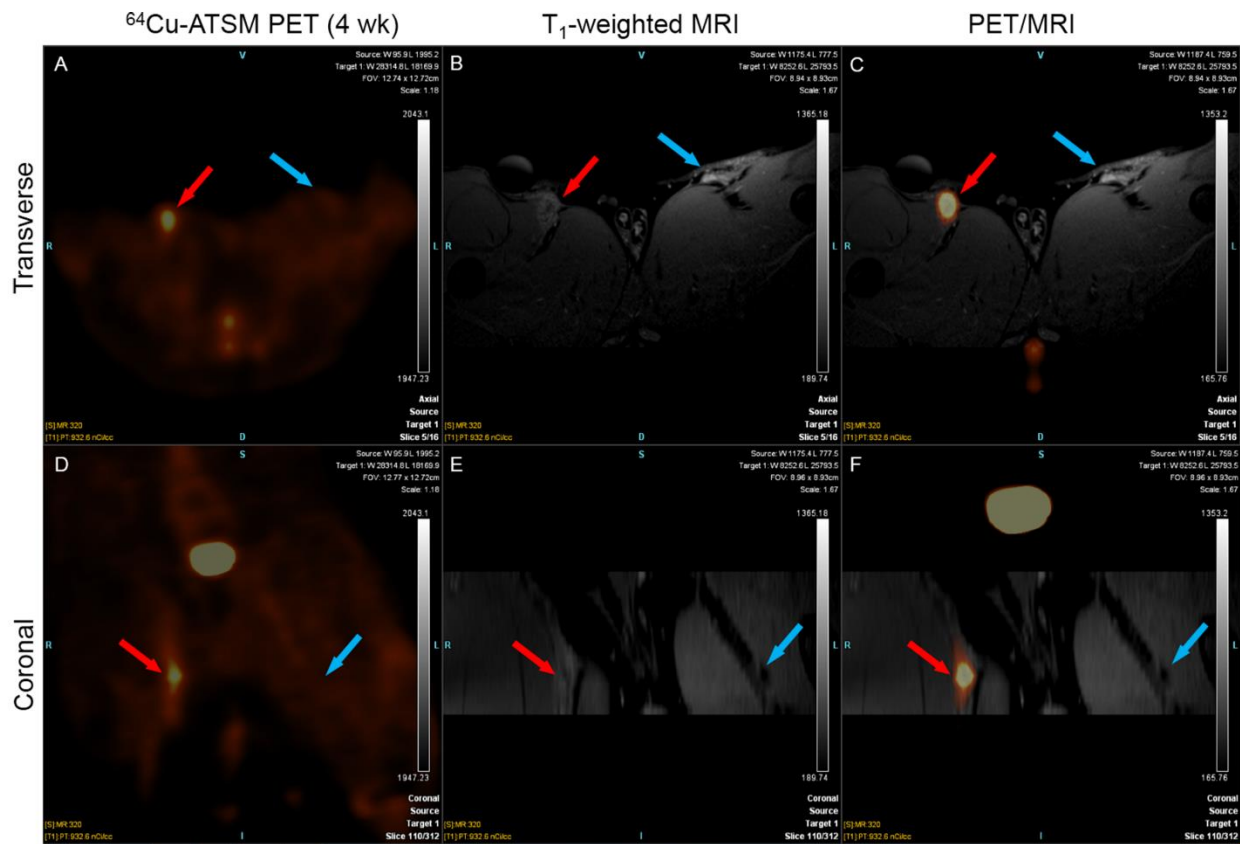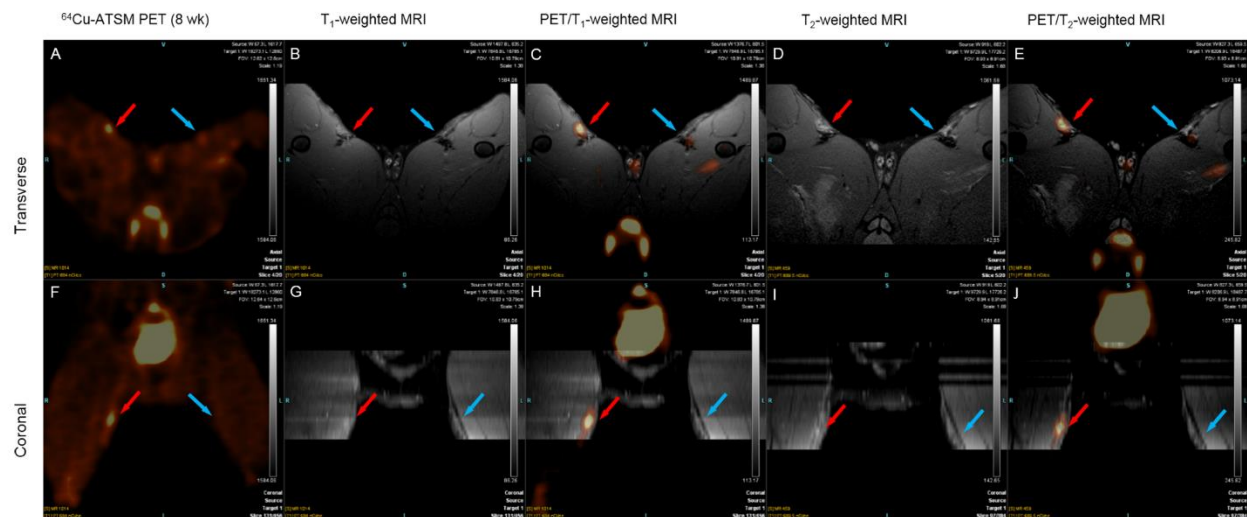
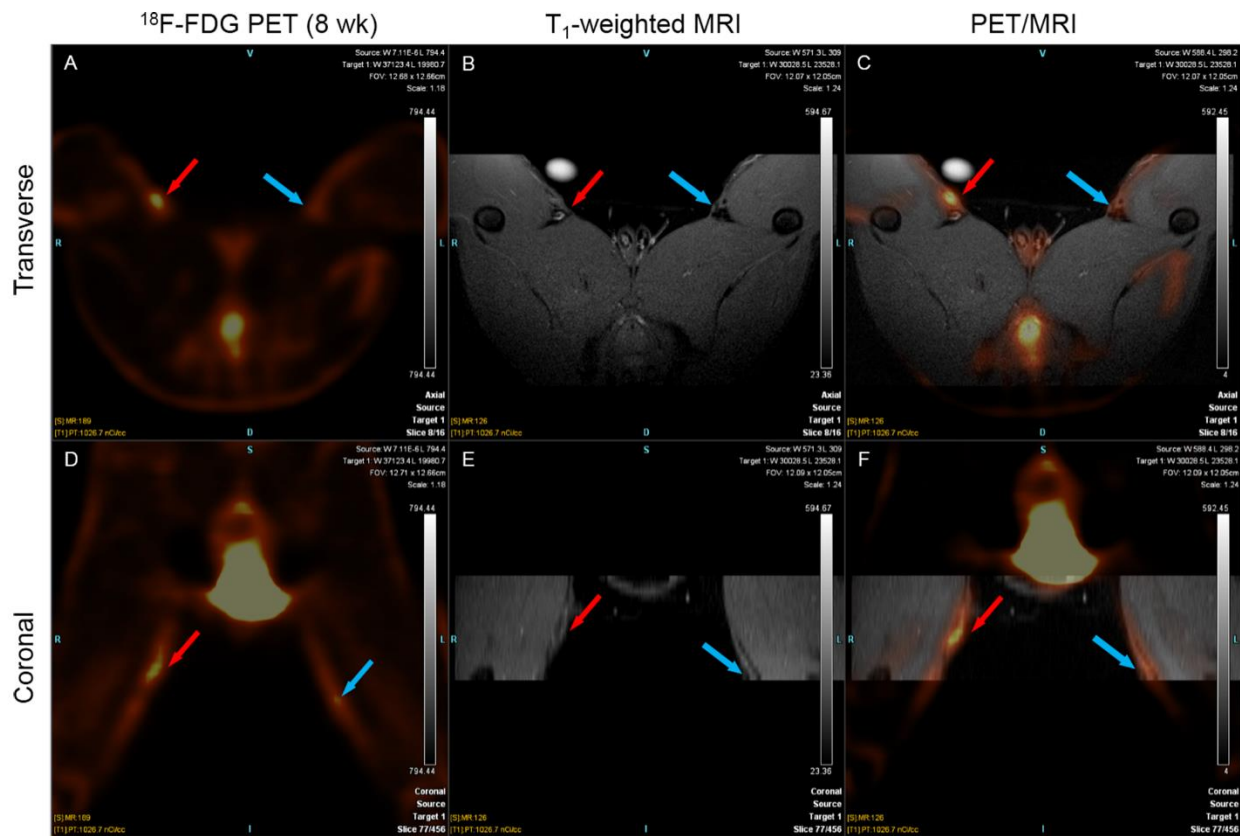


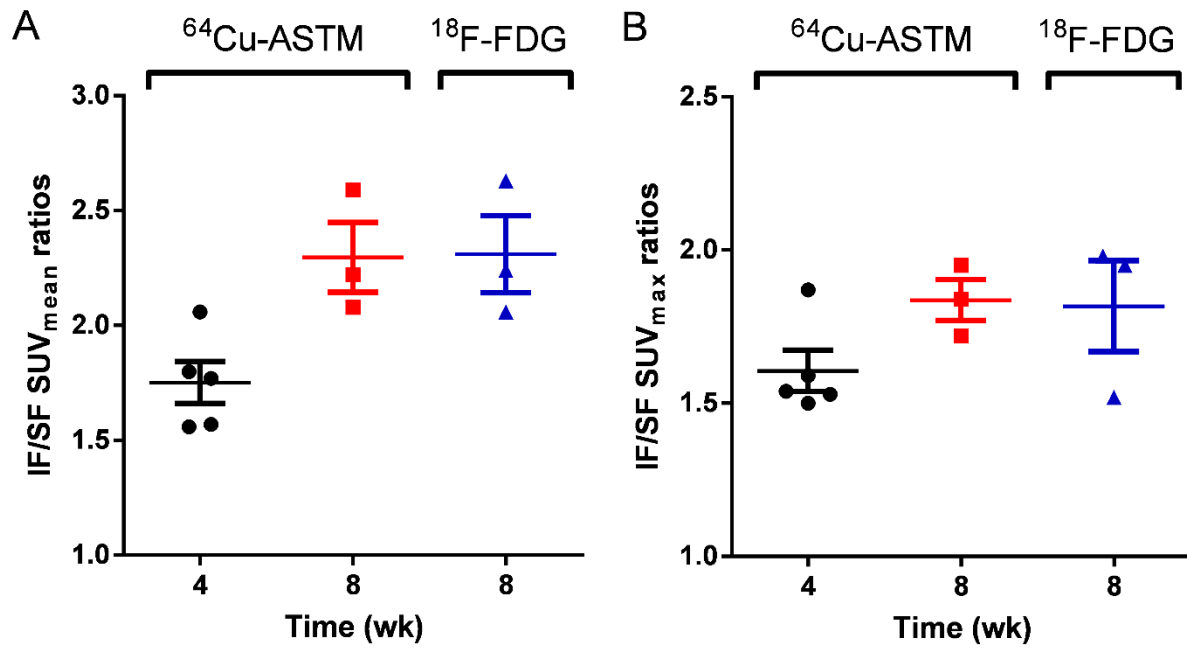
Supplemental Figure 1. ⁶⁴Cu-ATSM PET/MR images of a representative rabbit shown in Figure 2 4 wk post injury. The transverse (top) and coronal (bottom) view of the PET images (A, D), T₁-weighted MR images (B, E) and fused PET/MR images (C, F) indicated a significantly elevated uptake of ⁶⁴Cu-ATSM in the IF as compared to the SF. Red arrows point to injured femoral artery; blue arrows point to sham-operated femoral artery.



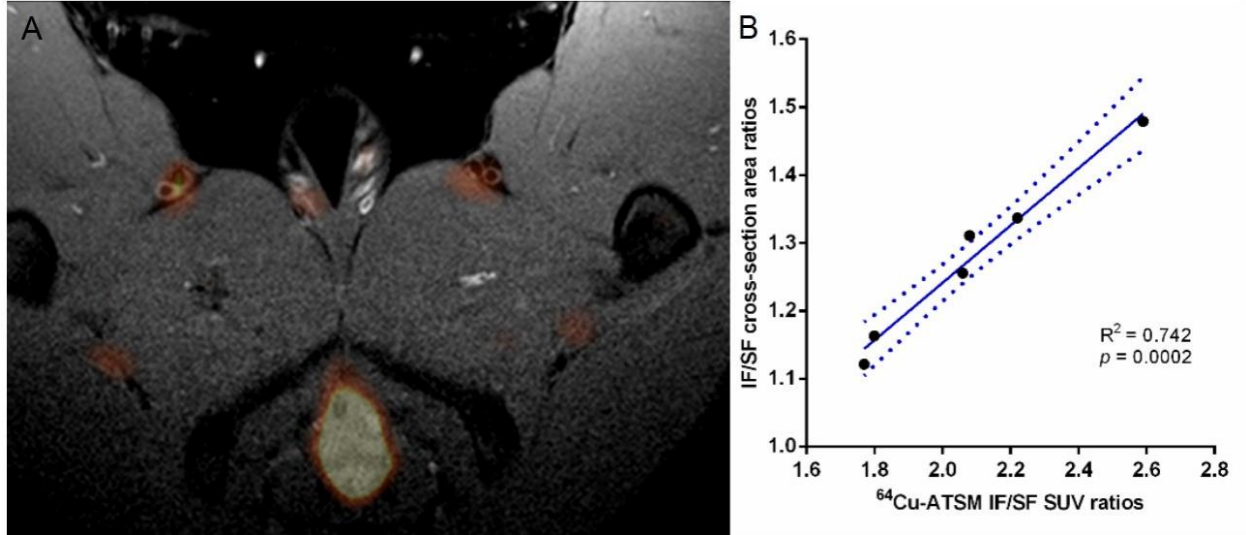
Supplemental Figure 2. ^{64}Cu -ATSM PET/MR images of the same representative rabbit shown in Figure 2 8 wk post injury. Significant uptake of ^{64}Cu -ATSM was also found in the IF as compared to the SF as shown in transverse (top) and coronal (bottom) views of the PET images alone (A, F), fused either with T₁-weighted MR images (MR: B, G; fused PET/MR: C, H) or T₂-weighted MR images (MR: D, I; fused PET/MR: E, J). Red arrows point to injured femoral artery; blue arrows point to sham-operated femoral artery.



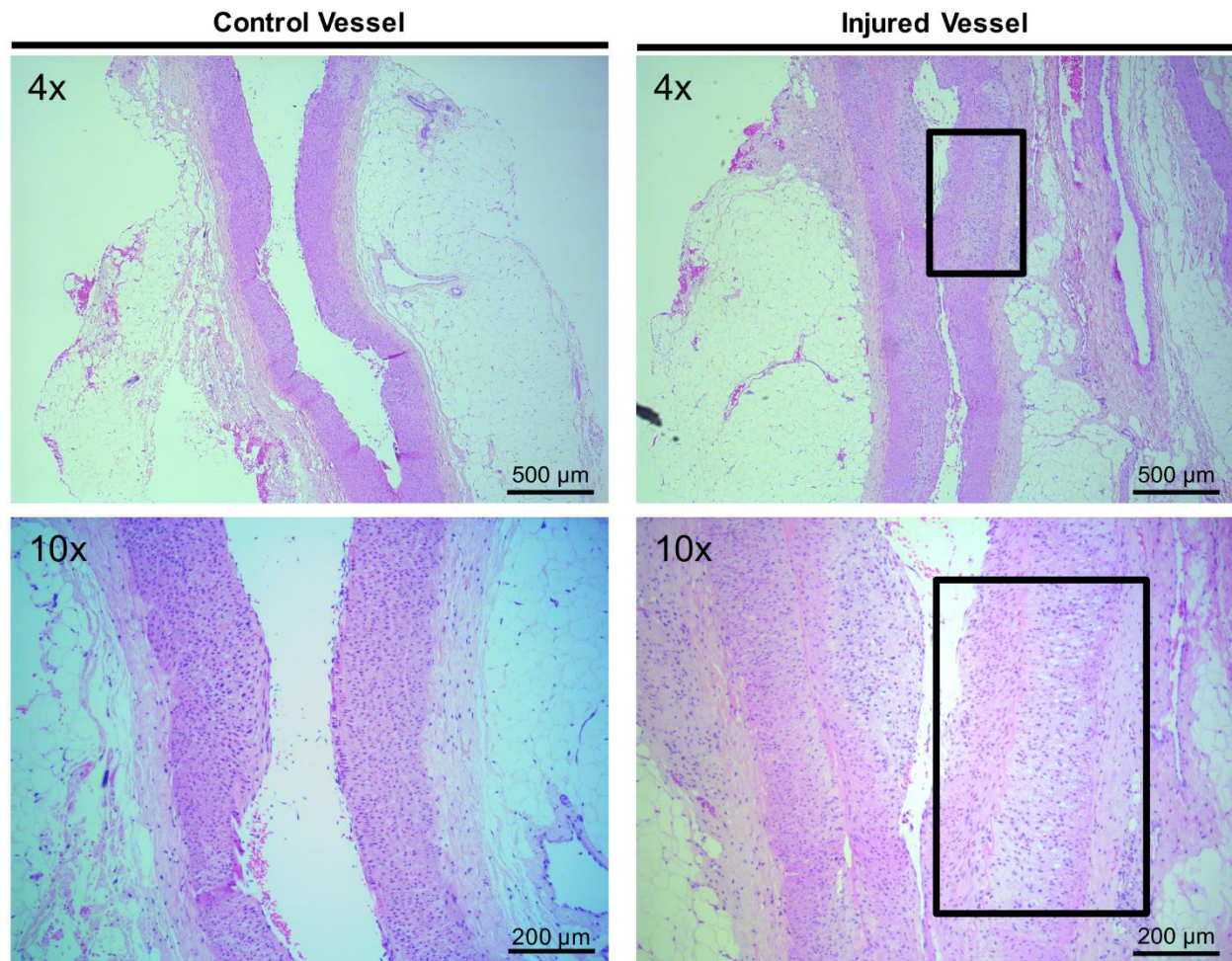
Supplemental Figure 3. ^{18}F -FDG PET/MR images of the same representative rabbit shown in Figure 2 8 weeks post injury. The transverse (top) and coronal (bottom) view of the pure PET images (left, A, D), pure MR images (middle, B, E) and fused PET/MR images (right, C, F) showed a higher uptake of ^{18}F -FDG in the IF as compared to the SF. Red arrow points to injured femoral artery; blue arrow points to sham-operated femoral artery.



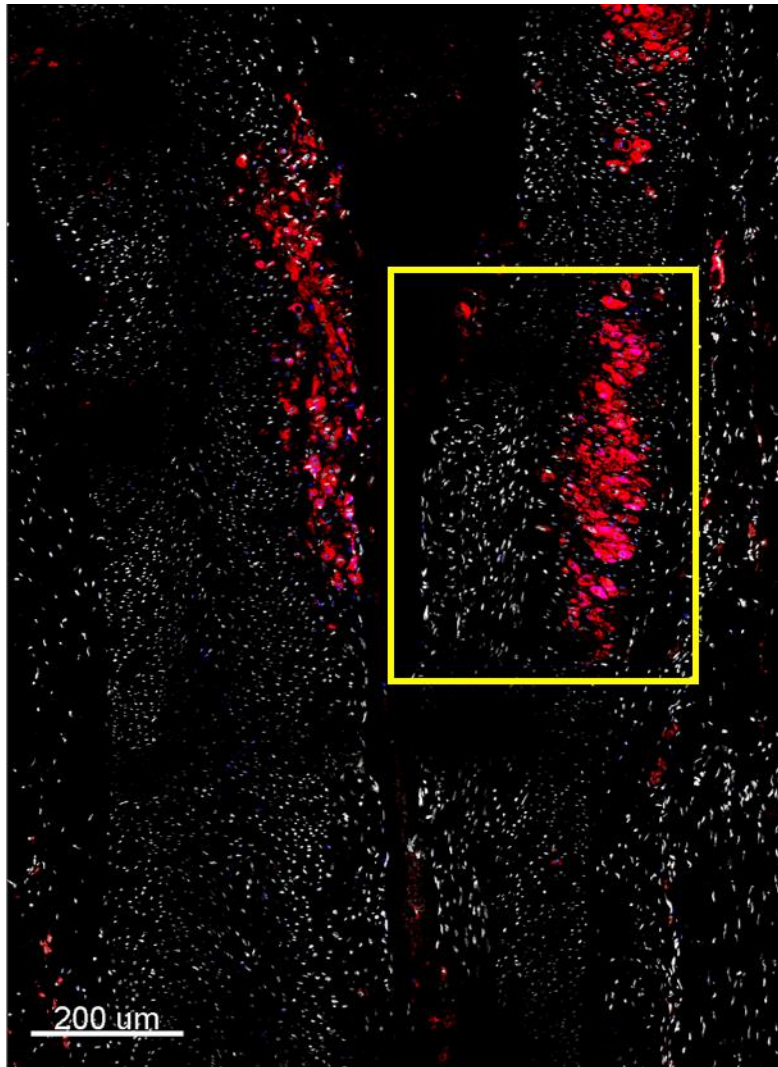
Supplemental Figure 4. IF/SF SUV_{mean} (A) and SUV_{max} (B) of the rabbits in both ⁶⁴Cu-ATSM and ¹⁸F-FDG images increased over time after injury.



Supplemental Figure 5. (A) Fused PET/MR image suggests a thickened arterial wall and elevated uptake ^{64}Cu -ASTM in the IF as compared to the SF. (B) Linear regression analysis shows that ^{64}Cu -ATSM PET IF/SF SUV_{mean} ratios are positively correlated to IF/SF cross-section area ratios measured in T₁-weighted MRI images.

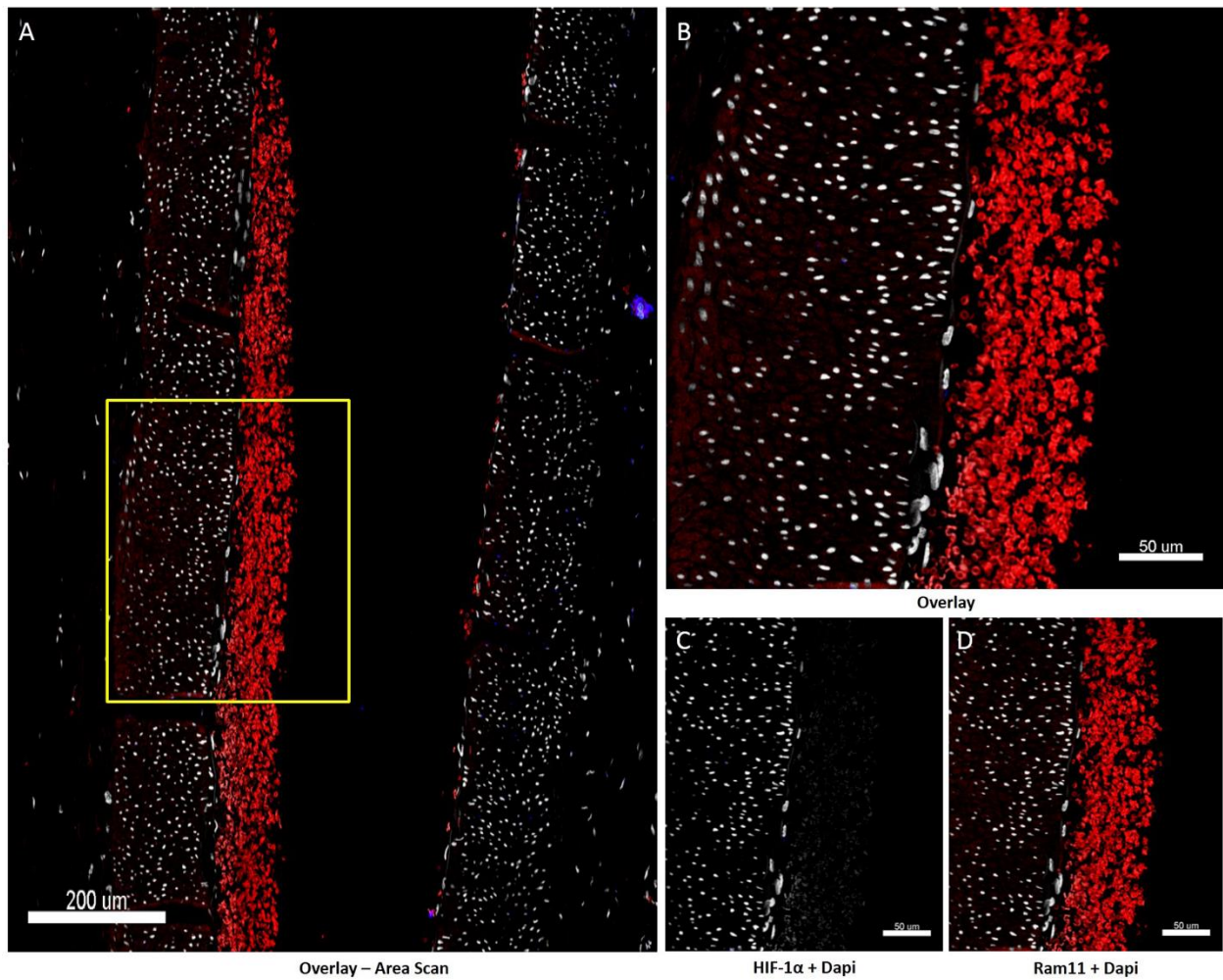


Supplemental Figure 6. Hematoxylin and eosin (H&E) stain of the sham-operated (control) femoral artery (left) and injured femoral artery (right) in 4X (top) and 10X (bottom) magnification shows that feeding cholesterol-enriched diet and air desiccation produced a focal thickened neointima in the area of previous air desiccation that was comprised of foam cells, and vascular smooth muscle cells. The duration of cholesterol diet was too short to see lesions induced in peripheral arteries other than the one with air desiccation.



HIF-1 α & Ram-11 overlay – area scan

Supplemental Figure 7. Area scan containing the injured femoral artery depicted in Figure 4 shows the presence of both deep and superficial macrophages in RAM-11 staining which are co-localized to HIF-1 α staining. However, only deep macrophage-rich area is pimonidazole positive, as displayed in Figure 4(C). The color code is as follows: DAPI, white; RAM-11, red; HIF-1 α , blue.



Supplemental Figure 8. Immunofluorescence images of the sham-operated femoral artery showing that neither Ram-11 nor HIF-1 α were positively stained in this region. Red observed is red blood cells (non-nucleated). Images of pimonidazole staining from the adjacent section (no positive results) were not included in this figure.