

Cases of dystrophia myotonica have been reported from all parts of the world, their numbers now running into hundreds, but this disease is not mentioned in many standard text-books, and it is certainly not so well known in this country as it should be. I have seen twenty cases in London since 1919, and as the disease is always familial and as cataract occurs in some members of almost every affected stock, it is almost certain that the number of cases scattered throughout the country is a considerable one. My object will be attained if the foregoing bald narration of some of the facts leads to their more frequent detection.

REFERENCES.

1. Batten and Gibb.—*Brain*, Vol. XXXIX, p. 1, 1916.
2. Curschmann, H.—*Zeitschr. f. Nervenheilk.* Vol. XLV, p. 161, 1912.
3. Fleischer, B.—*Arch. f. Ophthal.*, Vol. XCVI, p. 91, 1918.
4. Adie and Greenfield.—*Brain*, Vol. XLVI, p. 73, 1923.
5. Uhthoff.—(Quoted by Fleischer).
6. Bartels, R.—*Klin. Monatsbl. f. Augenheilk.*, Vol. XLIV, p. 374, 1906.
7. Greenfield, J. G.—*Rev. of Neur. and Psych.*, Vol. IX, p. 169, 1911.
8. Kennedy and Oberndorf.—*Jl. Amer. Med. Assoc.*, Vol. LVII, p. 1117, 1911.
9. Ormond, A. W.—*Trans. Ophthal. Soc. U.K.*, Vol. XXXI, p. 214, 1911.
10. Kennedy, F.—*Jl. Amer. Med. Assoc.*, Vol. LXI, p. 1959, 1913.
11. Bramwell and Addis.—*Edin. Med. Jl.*, Vol. XI, p. 21, 1913.
12. Hoffman, J.—*Arch. f. Ophthal.*, Vol. LXXXI, p. 512, 1912.
13. Tetzner.—*Neur. Centralbl.*, Vol. XXXI, p. 89, 1912.
14. Fearnside, E. G.—*Rev. of Neur. and Psych.*, Vol. XIII, 1915.
15. Mann.—*Deut. Med. Woch.*, Vol. XXVIII, p. 1386, 1913.
16. Löhlein, W.—*Klin. Monatsbl. f. Augenheilk.*, Vol. LII, p. 453, 1914.
17. Hauptmann, A.—*Zeitschr. f. Nervenheilk.* Vol. LV, p. 53, 1916.
18. Rohrer.—*Ibid.*, Vol. LV, p. 242, 1916.
19. Rülff.—*Arch. f. Psych.*, Vol. LXIV., p. 225, 1921.

REPORT TO THE LANG CLINICAL RESEARCH COMMITTEE, ROYAL LONDON OPHTHALMIC HOSPITAL*

A BILATERAL CHRONIC AFFECTION OF THE ENDOTHELIAL
FACE OF THE CORNEA OF ELDERLY PERSONS WITH
AN ACCOUNT OF THE TECHNICAL AND CLINICAL
PRINCIPLES OF ITS SLIT-LAMP OBSERVATION

BY

BASIL GRAVES

THE affection I am going to describe begins at or very near the central part of the deep face of the cornea, whence it spreads insidiously in a centrifugal direction. In respect of this distribution the condition is a bilaterally symmetrical one; but nearly always

* Submitted to the Lang Clinical Research Committee, August 10, 1924.

it is slightly more pronounced in one eye than in the other. The observations on which I base this report cover a period of two and a half years; I have minutely recorded and followed twenty-two cases, and I have on various occasions come upon others which I have noted less attentively. In no case has the period of time yet been sufficient to enable me to watch, in any one case, the transition from the early ("young") to the late ("old") manifestations of the affection. As far as I can infer this may require many years. On this account, and as also the appearances differ in different cases, it may be asked why I believe that the recorded cases in general represent one affection.

The inference is, I think, justifiable because in those rather rare cases which I have classed as being older cases, although the central region of the endothelium may appear very different, the periphery of the affected area usually shows, under special methods of illumination, very characteristic appearances like those seen confined to the centre in the less pronounced cases. I therefore think it justifiable tentatively to regard all the cases as representing one affection which, starting near the centre of the cornea, takes years to spread peripheralwards. The early states give rise to no symptoms—vision is not impaired—and at the beginning detection is not easy; slit-lamp methods afford the only means of detecting the condition. I think it likely that the early stage is by no means uncommon, and that either people do not live long enough for this very slowly changing condition to reach an advanced state, or, in those less elderly people in whom it does so, there may be some contributory predisposing constitutional factor.

If this assumption is correct, that the differing cases recorded represent various stages in one disease, it is convenient to divide it into say four classes, though no sharp division exists between these classes. The very earliest stage consists of very fine appearances, confined to a small region at or near the centre of the endothelium, whose understanding, and, in part, detection call for knowledge of the appearance of the normal endothelium in the axis of its specular reflection. As these early pathological changes are very slight, an observer who is not expert in slit-lamp work will probably not detect the condition in this very early stage; this is all the more likely because, at this stage, it practically does not reveal itself by the easier method of retro-illumination. Next there is a class in which the changes, though still affecting only a small area of the endothelium at or near the centre, are evident both by specular reflection, and even more characteristically by retro-illumination; in this stage a beginner may come across it if, while his microscope is focused upon the level of the endothelium, he applies by accident or design one of the special methods of retro-illumination which are described below.

In what, for convenience, one may call a "third" class, the condition may be readily evident by retro-illumination even though this R.I. is applied in a haphazard manner; but careful technique is required to detect the limits of its peripheral extension. In this third class the central endothelium may, or may not, show peculiarly striking appearances by direct illumination. In another, and let us say, fourth class these same appearances by direct illumination, confined mainly to the centre, are very evident; and the appearances by R.I., seen at the periphery are also evident, whilst, in addition, the epithelium may reveal characteristic changes which, unlike the insidiously persistent endothelial changes, seem prone to show remissions.

The first portion of this report will be confined to certain principles of technique; and in describing these I refer to the subject of detecting fine vacuolar changes within the corneal epithelium, and within the lens, mainly because of its usefulness in illustrating and establishing a precise technique.

In the *Transactions of the Ophthalmological Society*, Vol. XLIII, 1923 ("Microscopy of Living Eye") a classification of methods of observation and illumination was given, which I now prefer to modify to the following five varieties:

- (1) Sclerotic scatter ("S.S.")—see Fig. 69, *Trans. Ophthalm. Soc.*, Vol. XLIII, 1923.
- (2) Direct illumination ("D.I.")—see Figs. 58 and 64, *Trans. Ophthalm. Soc.*, Vol. XLIII, 1923, also Fig. 31 A and B, below.
- (3) Direct illumination, with observation along the axis of specular reflection ("D.I.S.R."). Some diagrams illustrating certain aspects of this will be seen under: "The Slit-lamp and Histological Features of a Small Tumour at the Limbus," in the *Trans. Ophthalm. Soc.*, Vol. XLIV, 1924. Also see Fig. 5 and Fig. 31 C, below.
- (4) Retro-illumination ("R.I."), e.g.—Figs. 66 and 67, *Trans. Ophthalm. Soc.*, Vol. XLIII, 1923; also Figs. 6, 12, 17 and 19 below.
- (5) Proximal illumination ("P.I."), e.g.—Fig. 68, *Trans. Ophthalm. Soc.*, Vol. XLIII, 1923.

Proximal illumination concerns translucent tissues which are not transparent. Save that the spread of light within a lightly pigmented iris-stroma makes it difficult to obtain a sharp margin to a light-patch focused on it, it is not necessary to refer further to proximal illumination in this report. I will discuss certain aspects of the other methods.

Sclerotic Scatter. This method is mentioned first because, from a purely clinical point of view, it is desirable to apply it as a routine before proceeding to the other methods. Briefly, it very readily discloses the presence and extent of intra-corneal changes—and also it enhances changes affecting the surface-contour of the iris—as viewed by the naked eye, or by low ($\times 9$) binocular microscope magnification. It is not suitable under higher magnification than that given by Oculars 2 with Objectives *f55*.

Direct Illumination. Light passing through transparent and translucent tissues is subject to various possible effects, e.g.,

reflection (diffuse and specular), refraction (regular and irregular), scattering, diffraction, etc., concerning which it is not necessary, for ordinary slit-lamp work, to draw fine distinctions provided two principles are grasped: (1) All these and other processes, except that of specular reflection, may conveniently be grouped under the non-committal term "Relucency," which was suggested to signify the property of living tissues whereby they are visible, superficially or internally, when under direct illumination. The phenomenon of specular reflection stands out so clearly and definitely from all the other grouped processes, in examination of the eye-media, that it alone is best accorded separate reference. Space does not here permit a discussion of the practical reasons for suggesting this, but this distinction is implied whenever I use the term "relucency." (2) Neither the relucency nor the specularly reflecting property of a tissue is in any way to be taken clinically as a measure of its capacity to obstruct the passage of light. The term "opacity" has long been misused in ophthalmology, as when we focus a light by ordinary oblique illumination direct upon an area of pathological change in, e.g., the cornea or lens, and, judging from its visibility as it is thus seen by direct illumination, we call the area an "opacity." To make a simple comparison: a splash of dark pigment on the anterior lens-capsule, in the direct course of the entering slit-beam, is by no means so readily visible as a small white-looking "lens-opacity" thus vividly illuminated; yet the pigment may be for all practical purposes completely obstructive to the passage of light and the "opacity" often but slightly so. Certain forms of fluffy white "lens-opacities," whose visibility is very bright indeed under the direct illumination of the slit-lamp, scarcely show to any marked extent by the transmitted light of retro-illumination. It is a common fault for beginners to look upon tissue-areas (e.g., the zones of disjunction of the lens) which are more relucant than the tissue (the general lens-substance) around them, as being more "opaque." The normal cornea by D.I. is very relucant; but it is not opaque. Although the term "opacity" should not be used in reference to features as seen by D.I., we are not altogether free of difficulty if we allot its use to R.I., in connection with which it is, from many points of view, a not unsuitable term. By R.I. the transmitted light may undergo refraction or scattering by partly "opaque" elements of a tissue, in a way which makes it difficult for us to judge of the obstructive properties of those elements. In the *Trans. Ophthal. Soc.*, 1923, I said that certain aspects of R.I. "conformed somewhat to that conception in physics when, in reference to the density of light-filters, the term opacity is defined as being the ratio of the intensity of the incident light to the intensity of the light transmitted." In employing this

analogy I purposely used the words "conformed somewhat to a conception" because the laws relating to this definition concern light-filters which are uniform (see Martin and Gamble, "Colour," Blackie & Son). However, the practical difficulties in connection with the use of the term "opacity" under conditions of R.I. are not such that we need avoid its use when dealing with this method of illumination.

Direct Illumination with Observation along the Axis of Specular Reflection.—This subject often puzzles beginners, but it should appear simple enough if defined as being no more than observation, by ordinary direct illumination, of any anatomical optical face which is sufficiently regular to have mirror-like properties, with the added condition that the chosen axis of

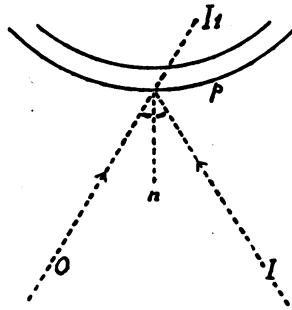


FIG. 1.

observation, through the microscope focused on that face, shall correspond with whatever direction, at the moment, constitutes the path of mirror-like reflection of the illuminating beam; in other words, the axes of illumination and observation must make equal angles with the normal, or, what amounts to the same thing, the normal must bisect the angle embraced by the axis of I and of O . These conditions obtain in Fig. 1 where p represents a curved mirror-surface. (The letters O , I , p , d , indicate respectively axis of observation, axis of illumination, corneal epithelium and corneal endothelium in any of the various eye-section figures in which they occur.) In everyday life we are accustomed to focus our attention, not on the mirror, but on the image (say I' , Fig. 1) which is formed along the axis of O somewhere behind the mirror; so if the microscope is focused along the axis of OI' on to the region of I' , the focused image of the source of light would be seen in the microscope; but if, looking along the same axis we focus with the microscope, not the image, but the selected reflecting region of the surface p , then we are seeing this in the axis of its specular reflection. It is this, instead of the images, with which we are more usually

concerned in microscopy of the living eye, though familiarity with some of the reflex images is of practical aid in searching for the reflecting areas.

Specular reflection, occurring as it does at regular faces demarcating two media of different refractive indices, can be seen in other places than at the anatomical faces of the cornea and lens. For example, it may be seen in the D.I. of small spherical vacuoles in the lens provided that these are not surrounded by areas of pathologically increased relucency to mask the visibility of the tiny reflections. It is this feature, together with that of shadow-streaks in the ensuing slit-beam behind them, which renders lens-vacuoles visible by D.I.

It is necessary in this connection to appreciate the simple differences between the conditions of specular reflection off a plane surface and off a spherical convex or concave surface whose radius

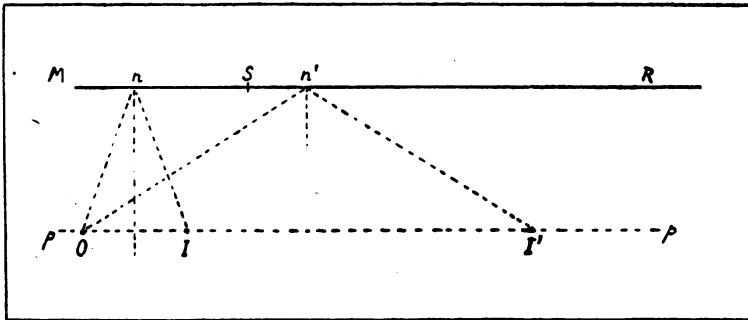


FIG. 2.

is small compared with the distances between the surface and the source of light, and between the surface and the observer. In Fig. 2 let MR be a plane mirror-surface and let an observer be situated at O ; the area of MR which is accessible to be viewed in the axis of specular reflection, in respect of a light-source situated at I , will then clearly be at n . Let the light now be moved along a line pp , which is at right-angles to the normal, to a second position I' . The area of MR now accessible to be viewed in the reflex will be at n' , a position which, in relation to the distance through which the light-source has been moved, is comparatively far from the position n . If the size of this plane reflecting surface did not exceed, say, that indicated by MS , then an observer at O , with a light-source at I' , could not view any part of the surface MS along an axis of specular reflection.

We may now consider curved surfaces, convex and concave, as, e.g., in Fig. 3. The distance between n and n' , or between m and m' , is small compared with that between O and I' along the line pp . It thus follows that an observer situated in a given

position can pick up specular reflection—off some part or other of a small reflecting surface—from a light-source whose situation may vary over a range which is much wider if the reflecting surface is spherical than if it is plane. In Fig. 4, for an observer at *O*, the only situation for a small light-source, from which he could not receive a specular reflex off the front hemisphere of the small spherical surface, would for all practical purposes be one within the cone defined by the shaded area. Hence, the seeing of a

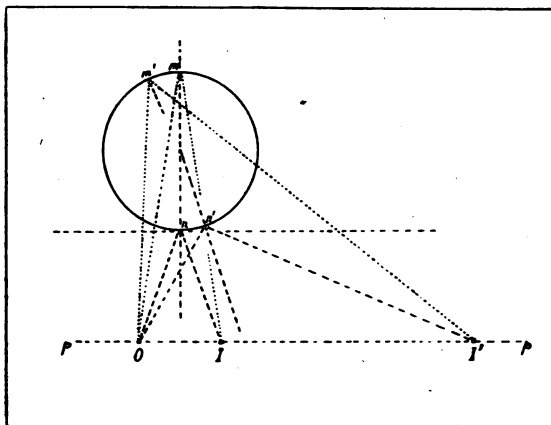


FIG. 3.




FIG. 4.

reflex from small spherical lens-vacuoles is independent of the relative positions of microscope and slit-lamp.

If a particular region of a given reflecting surface is selected with a view to its being observed in the axis of specular reflection, then much manipulation of the apparatus may be required to adjust this to the necessary axes, whether the surface be curved or plane; but if it is immaterial as to what part of the given surface shall be seen thus, then the reflex may be picked up the more easily off the surface which is spherical. This is, of course, a matter of common every-day experience. Witness the window-reflex off the curved corneal surface, or the reflexes in an artist's picture of any small spherical reflecting object. There is, however, this difference in slit-lamp work: we are not dealing with a source which is radiating light in all directions but with one from which the rays follow a very narrow path. The width of the focused beam with which we ordinarily work varies from 2 to 25 micrometer-divisions with ocular 2 and objective a2. So in

the case of the curved cornea—large in relation to the diameter of the beam—we have to move the tiny beam to and fro over its width to find the area whose reflection can be visible under the conditions of the moment. But lens-vacuoles of medium size measure from 2 to 5 divisions (Oc. 2, Obj. a2), in relation to the size of which the beam-width is not relatively restricted. The observer will, therefore, pick up some of the specularly reflected rays which are leaving the whole of the convex front half of the illuminated vacuole (and for that matter part of the concave back-half) with no further manipulation of the apparatus. Such considerations as these have bearing on questions relating to the specular glints from minute irregularities of the endothelium of the cornea in the affection to be described.

When we are detecting a lens-vacuole by D.I. it is immaterial, in practice, from what tiny portion, of either its convex front-half or concave back-half, a specular reflex comes, provided a reflex is seen. (In practice the electric ophthalmoscope, with plus 20 lens, affords the readiest means, provided there is a proper fundus-reflex, of detecting all but certain varieties of very small or very flat lens-vacuoles). We may be of the same mind when viewing the endothelium of the cornea which, being curved, readily displays its specular quality, in some portion or other of its area, with but little manipulation of the apparatus; all we have to do is to find, for impact of the beam, the region whose normal bisects the angle between the microscope and the illuminating systems. But when we previously select the area to be seen thus, we have, in order to get the proper relationship with this normal, to adapt the direction of the patient's eye, or else that of the heavy apparatus, and at the same time not lose sight through the microscope of the small selected area. It is a matter for consideration in slit-lamp work because the construction of the apparatus is such that it is difficult rapidly to vary the relative angles which the *I* and *O* axes make about any one point on a surface under observation. Thus studying selected areas of the corneal endothelium by D.I.S.R. is at no time easy, but it is facilitated for anyone who will familiarize himself with a certain small faint reflex-image—and with the behaviour of this on movement of the axis of *I* or *O* or on movement of the observed eye. I do not want here to encroach on space by diagrams explaining this reflex and its behaviour; it can be demonstrated practically so much more quickly. The little reflex-image has a characteristic shape—that of the aperture in the diaphragm-cover of the focusing-lens* on the slit-lamp arm. .It

* Confusion would be avoided if the slit-lamp lenses were denoted by the following terms: The two lenses in the casing of the lamp, behind the slit—"collecting lenses" (front and back); the lens on the end of the slit-lamp arm—the "focusing lens." This avoids the ambiguity caused by use of the term "condensing lens."

can always be found easily; it is due to internal illumination of the glass of the focusing lens which on this account can be seen from any angle of view. Its position affords a guide to manipulating the apparatus.

The specularly reflecting anatomical faces of the cornea and lens are curved. Although specular reflection occurs from all the area of such a face upon which the beam is incident, however large may be the diameter of the beam the area of the face which may be seen in the axis of its specular reflection at any one time is never a large one, because of the curvature of the face (for a diagram on which see *Trans. Ophthal. Soc.*, Vol. XLIV, 1924, Fig. 16, page 202). In Fig. 5 the area of endothelium seen in

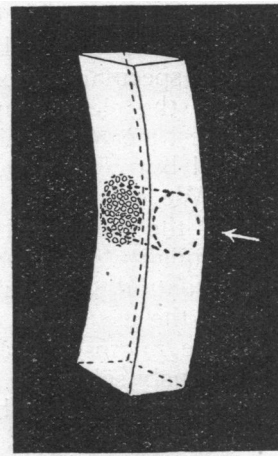


FIG. 5.

the axis of specular reflection, when the slit-beam is used, is represented by the small patch in the centre of the posterior face of the corneal block. Under these circumstances the remainder of the beam, above and below this level, is not required and its presence is usually disadvantageous when studying the endothelium thus. It is better, and it is certainly less inconvenient for the patient, to use the circular dot-beam whose path, under equivalent conditions, is indicated in the same figure.

Retro-illumination.—Vacuoles within the lens afford a clear and easy demonstration of a certain feature of retro-illumination which it is desirable to understand. The visibility of lens-vacuoles can be by far at its best by R.I. properly applied, provided, of course, that the vacuole is not situated so close back to the posterior capsule that R.I. is not feasible: the beam within a normal vitreous is not sufficiently intense to provide R.I. for features within the lens.

Small spherical vacuolar objects are not seen to advantage by R.I. when the illuminating area behind them is relatively large (in relation to its distance) and of uniform intensity. It is true that under these conditions their inconspicuous silhouette can be seen as fine thin rings, but the visibility is poor. For good visibility it is necessary to produce behind the vacuoles an abrupt contrast-effect—the meeting of light and darkness along a margin

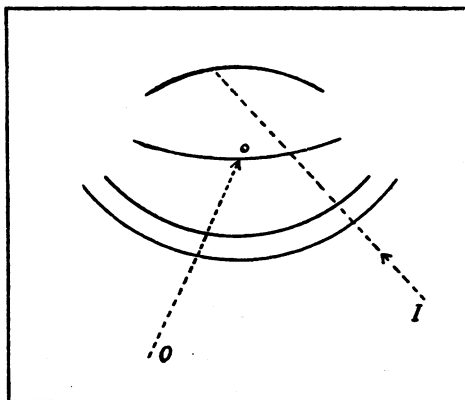



FIG. 6.



A

FIG. 7.

B

which is well defined. The view of the margin is displaced by refraction as it is transmitted through the vacuole and can, therefore, be seen in the tiny vacuole when this is out of line with the corresponding effect in the illuminated background. This is in part illustrated by rain-drops which, adhering to the window of a railway carriage, are viewed against a background whose upper part is formed by light sky and lower part by dark land; but the analogy is not altogether apt because the raindrops are infinitesimally small in relation to the area of the light-source.

Let a small lens-vacuole be viewed by R.I., as shown in Fig. 6. If the ribbon-like slit-beam is used the visibility of the vacuole

will be poor, unless the vertically-disposed discontinuity, or disjunction lines demarcate areas which show marked visibility-contrasts one from another, as may be the case, for example, in senile lenses. But the discontinuity of the lens-regions shows at its best when the slit is made very narrow—an arrangement which at the same time much reduces the illumination-intensity because the diaphragm acts as a dimmer. Hence a slit-beam, such as that shown in Fig. 7A, is usually unsatisfactory for R.I. of lens-vacuoles. It is necessary, for good visibility, to cut down the vertical diameter of the beam and to create a sharply focused, but vertically narrow beam as shown in Fig. 7B. This may be done by using the dot-diaphragm, or by rotating the diaphragm-plate in front of the adjustable slit so that the path through the slit is obstructed except for a small part left exposed at one of its two ends. Under these conditions, vacuoles viewed by R.I., from a




FIG. 8.

beam such as that in Fig. 7B, are seen very clearly, as represented diagrammatically in Fig. 8. It is desirable to have a term to denote this method of illumination and I think it convenient to refer to it as "marginal R.I."* Other methods will presently be described of procuring this effect, by which should be understood a R.I. in which the background is illuminated over a relatively small area which, by accurate focusing of a small beam, has a sharply-defined margin separating it from the surrounding unilluminated tissue. If this principle is adopted in looking for vacuoles in the anterior two-thirds of the lens it will be found that very minute almost flat vacuoles, especially certain varieties sometimes seen immediately beneath the anterior lens-capsule, are readily detectable, when by an illumination less precise, they would scarcely be seen.

It will be noted (Fig. 8) that, in the case of the lens-vacuoles, their R.I. is "unreversed," that is they show light to light and dark to dark. This applies also to corneal intra-epithelial vacuoles. I shall point out later that the individual punctate elements of the

* If the term "marginal" is likely to lead to confusion with respect to the margin of say a pathological area under focused observation in the microscope, the term "junctional R.I." might be better.

corneal affection I shall be describing, show, by marginal R.I., a reversal of the contrast-effect, namely, dark to light and light to dark, i.e., crossed or "contralateral" illumination.

The entering lens-beam (Fig. 6), whilst adequately bright for R.I. of lens-vacuoles, is a poor source for marginal R.I. of



FIG. 9.

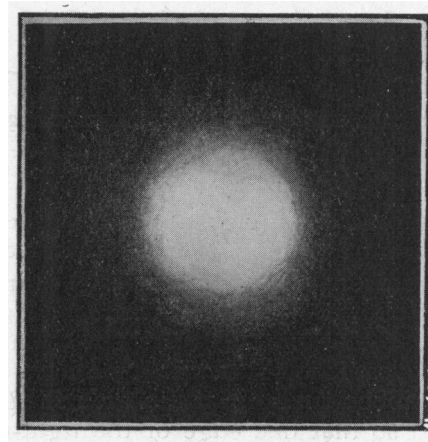
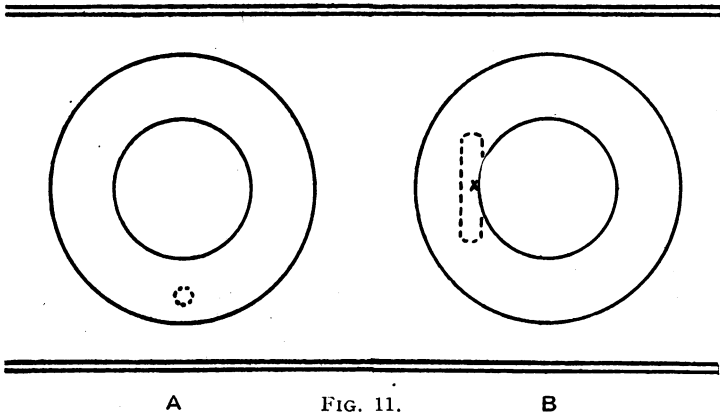


FIG. 10.

features to be observed within the cornea. For these the following two methods are available: (1) From the iris; (2) by axial observation along the efferent beam produced by specular reflection at the posterior lens-capsule.

Marginal R.I. from the Iris.—The aim should be to avoid spreading of the light and to produce a patch small and sharply defined, as represented in Fig. 9, and not one whose edge, as in

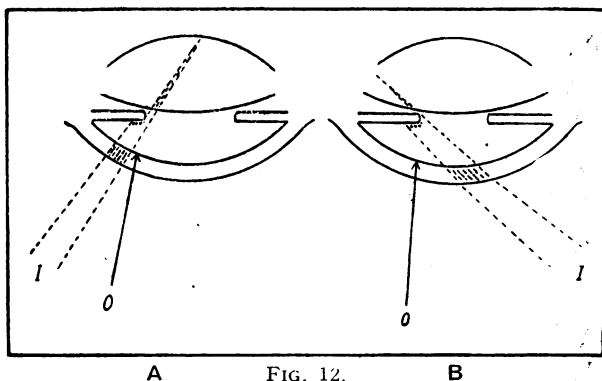
Fig. 10, is diffuse. The cylindrical dot-beam should, therefore, be used and it should be critically focused on the surface of the iris. An observer, using any but the $f55$ objectives, is very apt when his view is in focus on the cornea to forget to attend to this critical focusing of the illumination upon a plane which is, at the time, far beyond the focal range of his microscope system. Fine punctate elements of the cornea which I am going to describe later are not revealed by a R.I. which is not critical. The dot-beam is shown diagrammatically, in Fig. 11A, in critical focus upon the surface of the iris. One may here point out that the stromal pigment of a brown iris tends to interfere with the spread of visible light within the depth of the translucent stroma, so that the margin of the illumination-patch is sharper in the case of a



brown iris than in the case of, e.g., a blue or a grey iris in whose stroma light much more readily scatters and spreads.

There is, however, for the viewing of features in the cornea an alternative way of obtaining marginal R.I. from the iris which, allowing of the use of the ribbon-like slit-beam, is frequently very useful; moreover, it is as critical for a light iris as it is for a dark iris. The ribbon-beam from the wide slit is focused upon the iris (Fig. 11B) so that one edge of the light-patch coincides with the pupil-edge, or perhaps to be more accurate very slightly overlaps it. The free edge of the pupil then provides the necessary sharp demarcation between illuminated iris and dark unilluminated lens, and features in the cornea which call for marginal R.I. stand out, against this sharp pupillary edge, much more clearly than they do against the diffusely defined remainder of the light-patch border. For this effect the beam must be directed, not as drawn in Fig. 12A, but as drawn in Fig. 12B; any light passing beyond the

pupil-edge, under the conditions of Fig. 12A, will be seen within the lens and will impair the desired contrast, whereas the light passing the pupil-edge, under the conditions of Fig. 12B, will enter only a part of the lens which is inaccessible to the observer's view. I am not sure that another factor may not contribute to poor visibility under the conditions of Fig. 12A as compared with those of Fig. 12B, namely, that under those of Fig. 12A light may be reflected somewhat intensely off the surface of the iris on to the region of the cornea (defined by arrow *O*) which is under observation; in fact, for examining the back of the cornea in certain conditions this method can with advantage be resorted to (see Fig. 19), but it is not advantageous that it should occur when



A FIG. 12. B

we are making observation by marginal R.I. off the iris. There is a certain variety of sparse exceedingly fine deposit on the back of the cornea, following some inflammatory affections, which is generally best detectable by the method of Fig. 12B. This oblique application of the slit-illumination as a vertical tangent to the pupil-edge is not applicable to other parts of the circumference. Hence the regions of the cornea accessible to being viewed by this method are rather restricted, and for the purpose of ascertaining what is its peripheral extent, in later stages of the affection I shall describe, it is better to resort to the dot-beam (Fig. 9) which may readily be focused upon any required part of the iris.

Axial Observation along the Efferent Beam produced by Specular Reflection at the Posterior Lens-capsule.—A method is represented in Figs. 13 and 14 to which I have long resorted when wishing to get a fairly intense but restricted R.I. of the cornea or of the anterior part of the lens—or for that matter of material in the aqueous fluid. Let the beam (*I*, Fig. 13) be focused along the axis *u* on to the posterior lens-capsule at *pc*; let the

illuminated area pc be viewed along the axis (a') which is so disposed as to make, with the illumination-axis (a), an angle which is bisected by the normal (not drawn) to the capsule at pc . When the microscope (pc') is in focus on pc along the axis a' , the area pc is then being viewed in the axis of specular reflection. The golden lustre of this picture is familiar to anyone who has practised slit-lamp work. I would point out that for this purpose it is far better to use the small round beam from the 1.0 mm. dot-aperture than the slit-beam, for reasons connected with the

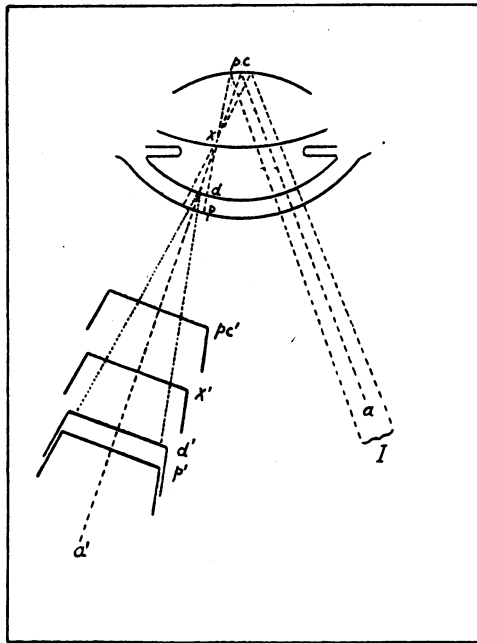


FIG. 13.

curvature of the capsule which are analogous to those already referred to for the cornea under Fig. 5. The excess of unused light from the slit-beam used for this purpose impairs the observer's appreciation of contrast and is inconvenient to the patient. When the 1.0 mm. dot-beam is used the picture of the posterior capsule seen by D.I.S.R. may be represented by the circular patch in Fig. 14A; the half-tone areas to one side, on the observer's right, represent the entering (afferent) beam, seen out of focus as it passes through the posterior cortex before reaching the posterior capsule.

Now let the observer, still keeping the beam accurately focused upon the same area of the posterior capsule and without altering the direction of the axes of I and O , rack the microscope towards

himself so that (at x' , Fig. 13) it is focused upon a level (x) at which, somewhere at or beneath the anterior lens-capsule, the rays of the reflected (efferent) beam converge to form an image of the spiral filament of the nitra lamp. The picture then seen in the

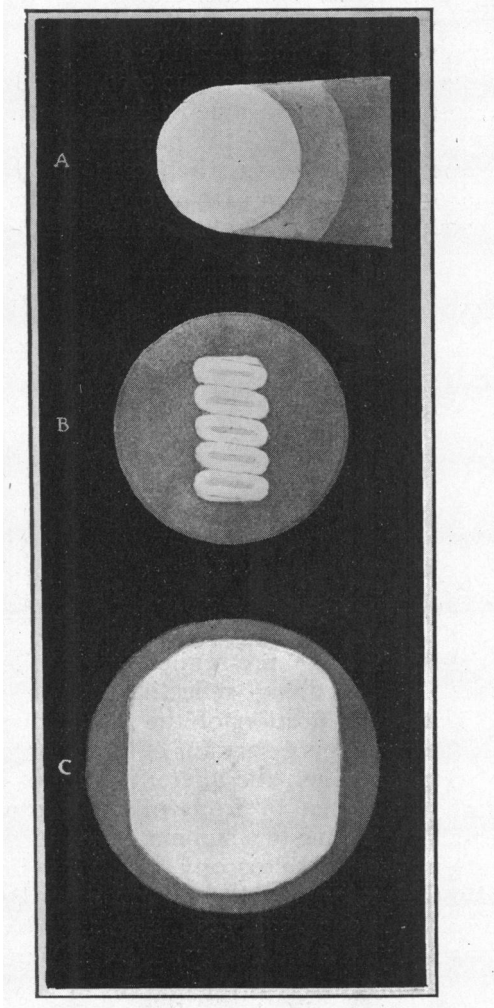



FIG. 14.

microscope is represented by Fig. 14B. The absence of colour in such a drawing as this is a disadvantage; in reality the filament-image is a vivid gold, set in a surrounding which in most lenses is dull grey-blue. This grey-blue border surrounding the image partly represents some rays which, diffusely reflected from the

illuminated patch of the posterior lens-capsule, do not suffer convergence to form the central image of the filament. Now, maintaining the same conditions, let the observer rack the microscope still further towards himself so that (d' or p') it is focused on the level of the corneal endothelium (d) or epithelium (p); as the microscope leaves the position x' the observer will see the filament-image spread out so that, by the time the microscope is focused upon the level of the cornea, he sees (Fig. 14C) a yellowish golden patch, surrounded by a much fainter narrow grey margin which we may conveniently call the paraxial halo. The paraxial halo, though larger than it was when seen as in Fig. 14B, has not undergone an increase in size proportionate to that of the bright axial patch because the rays forming the axial patch are



diverging at a relatively wide angle after they leave their level of intersection x .

In some lenses showing pre-senile and senile changes the posterior cortex has intrinsic reflecting qualities due in all probability to some modification of the lamination of structure; and, at or near the angle necessary for observation of the posterior capsule in its specular reflex, the afferent beam of these cases, in passing through the cortex in front of the capsule, assumes a shining golden character due to a summation of successive multiple specular reflections (see "Microscopy of Living Eye," report of Section of Ophthalmology, Annual Meeting British Medical Association, 1924). In such patients the paraxial halo is relatively much larger than that drawn in Fig. 14C, and instead of being faint and grey it is brighter and more yellow, so that it tends to match the brightness and colour of the axial patch which it surrounds. In these cases it is easy to distinguish the axial from the paraxial light because, on slight moving of the slit-lamp arm, the two behave differently; the comprehension of this is a matter of simple optics.

Features thus under retro-illumination in the cornea and elsewhere may be observed by looking along the efferent beam

specularly reflected in this manner from the posterior lens-capsule. If they are seen against the central bright patch the method may be noted as "R.I., axial S.R.p.l.c.," or if against the paraxial margin as "R.I., paraxial S.R.p.l.c." Fig. 15 shows, for example, a group of very minute anterior subcapsular lens-vacuoles seen against the axial beam; here the beam is seen in the form of an image of the filament because the microscope is focused on a level just beneath the anterior lens-capsule. Illustrations will be seen below of some features in the cornea which show very clearly by this method. The present mechanical design of the slit-lamp apparatus, the presence of the iris, and the radius of curvature of the posterior capsule, are factors which prohibit the application of this particular method to all parts of the cornea; but it so happens that the peripheral region of the affected area in the condition to be described, for which this method of examination is so useful, lies in a moderately advanced case not far from half-way between the centre and the periphery of the cornea—a region through which the efferent S.R.p.l.c. beam can be directed with ease.

By the use of objectives (e.g., a 2 or a 3), whose power is moderately high and focal depth therefore slight, features under R.I. occurring at the same time in two close-set levels, say the epithelium and endothelium of the cornea, may be visually separated from each other with ease. When the microscope is focused upon the endothelial face (d) the observer might see changes, characteristic of the affection about to be described, without his view being impaired by intraepithelial vacuolation should this be present at the same time. Conversely, by racking the microscope toward himself (to focus on p) any intraepithelial vacuolation is visible without confusion by the endothelial changes which are now out of focus. As in the eye pathological changes are so prone to be located at levels defined by anatomical boundaries, this method of discrimination by exclusion, taking advantage of the small focal depth of the higher power objectives, is one of practical significance in this work.

This method of axial observation along the specularly reflected beam from the posterior lens-capsule, though needing a little practice is not particularly difficult, save that when the cornea is normal, and therefore clear and transparent, a beginner finds it difficult to know when his microscope is focused on that level; even the chance presence of a tear bubble does not give the aid that might be expected because we are dealing with a microscope system having relatively low apertures. The size of the light-patch forms an approximate guide to one who from practice is familiar with it; and the entering (afferent) beam may be momentarily deflected to render visible by D.I. that part of the

cornea through which the axis of observation is passing. It is best to bring the slit-lamp arm fairly close up to the microscope and to direct the patient to look slightly upwards at the observer's forehead. If the pupil is not dilated the efferent beam can be seen axially only through the objective which is nearer to the illumination-axis; if the pupil is dilated such a beam may be seen alternatively through either one or other of the objectives by means of a slight lateral displacement of the free end of the slit-lamp arm. If the specularly reflecting property of the posterior capsule is impaired by pathological changes the method is obviously unsuitable.

I wish now to allude briefly to the subject of intraepithelial vacuolation. It is a subject which has many interesting aetiological

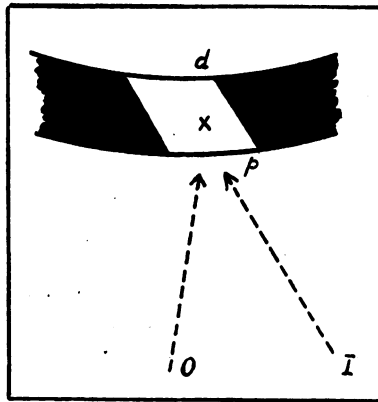


FIG. 16.

features, but it is not the aim in this report to discuss it from this standpoint. Intraepithelial vacuoles may be very numerous. When they are very small they need not impair the specularly reflecting qualities of the surface of the epithelium; in other words, they can be truly intraepithelial and not affect the surface-contour. The associated presence of larger vacuoles, many of which may be presumed to be more superficial in the epithelium, may impair the reflecting properties of the surface. The loss of lustre of the surface of a glaucomatous cornea is familiar.

One of the reasons why fine close-set intraepithelial vacuoles are not seen in the corneal beam of direct illumination is that when directly illuminated (Fig. 16 *I*) they are at the same time under the close R.I. of the intracorneal part of the beam (*x*) just behind. If the dimensions of the corneal beam are made quite small, by the use of one of the dot-apertures, it can, if sharply focused, be used for marginal R.I. of intraepithelial vacuoles. This is

shown in Fig. 17 where vacuoles, relatively much smaller than they are drawn here, lying in the position shown in the upper figure, are seen against the margins of the tiny beam in the manner indicated in the lower figure. This method is, however, not good for the finest of intraepithelial vacuoles. In this subject of marginal

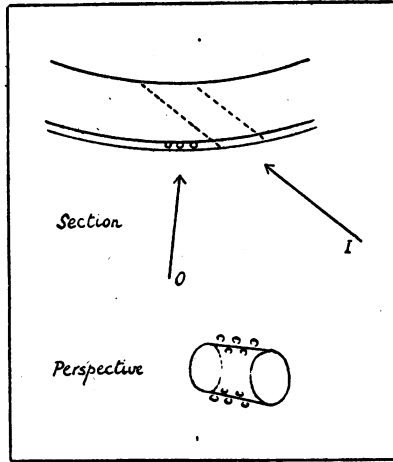


FIG. 17.

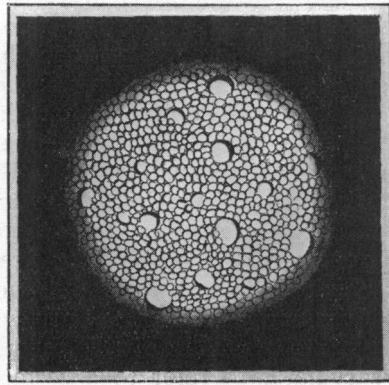


FIG. 18.

R.I. the obtaining of a sharp illumination-margin is not the only factor to be considered; the illumination, besides being of relatively high intensity, needs restricting sharply to an area which is reasonably small in relation to its distance from the feature under observation. Fig. 18 shows a fairly representative though diagrammatic picture of close-set intraepithelial vacuolation which

was seen in a girl who was the subject of what was considered to be tuberculous irido-cyclitis. The vacuoles were seen much as they are here shown by marginal R.I. from a very small iris focal-patch. In this case they are very close-packed, and whilst the majority are more or less of one size, some few are considerably larger. The individual vacuoles show as clearly evident but very thin fine rings; in Fig. 18 their outlines have been made rather too coarse and heavy. The drawing in this case perhaps errs in being a little too uniform, but it is remarkable how numerous intraepithelial vacuoles can be when the condition is spread over a large area of the cornea. Clinically, one may meet with the smaller vacuoles only; or they may be associated with scattered larger ones, as shown in Fig. 18. Certain types of cases, e.g., a variety of interstitial keratitis, show intraepithelial vacuoles which in size are intermediate between these; and all may be practically equal. These epithelial vacuoles in some conditions may differ much more in size and may be more separated; they may be isolated, or dotted about in little groups.

Epithelial vacuoles, like lens-vacuoles, exhibit uncrossed illumination by marginal R.I., i.e., the one-sided intensification shows as light to light and dark to dark. In the case of lens-vacuoles, which are common and very easy to see, the beginner will readily appreciate this; a little more experience is needed in order to be able to appreciate it in the case of corneal epithelial vacuoles. Lens-vacuoles are more readily visible than intraepithelial vacuoles because, apart from the mere question of ease of technique, possibly the difference between the refractive index of the contents and that of the surrounding tissue may be different in the two cases. Also it is probable that those lens-vacuoles which show very clearly are more nearly spherical, i.e., not antero-posteriorly flat, and have a greater depth. When lens-vacuoles are antero-posteriorly flat, as certain fine subcapsular vacuoles may often be, by D.I. their reflexes, from anterior or posterior face, are scarcely apparent and their shadow-streaks are but faint; by marginal R.I., which is the best way to see them, their refracted light-edge is very thin and is apparent only when the marginal R.I. is getting close into visual line with them.

It will be necessary later to refer to a certain variety of very weakly pigmented fine deposit sometimes seen on the back of the cornea. By D.I., though it may not be possible to be certain as to its colour, it may be appreciated that it is in some measure coloured even though its component particles are very small. Now some of this may be so faintly coloured that where it is not dense it may appear not to obstruct the light of R.I. (i.e., be opaque) even though the intensity of R.I. may be made faint by, e.g., making use simply of the beam which depends on the

relucency of the lens. D.I., however, suffices for its recognition in ordinary circumstances; but difficulty arises where this deposit is superimposed on other conditions, such as numerous fine specular glints like those to which I shall refer later. In these circumstances the faintly pigmented deposit is often revealed very vividly by R.I. thus: low-power objectives, $f55$; let the wide slit-beam be directed on the limbal sclera as for sclerotic-scatter illumination which may reveal the pigment faintly illuminated; now let the end of the slit-lamp arm be swung a little so that the beam strikes the iris, off which the light is intensely reflected on to the back of the cornea, in the manner of Fig. 19. The lightly

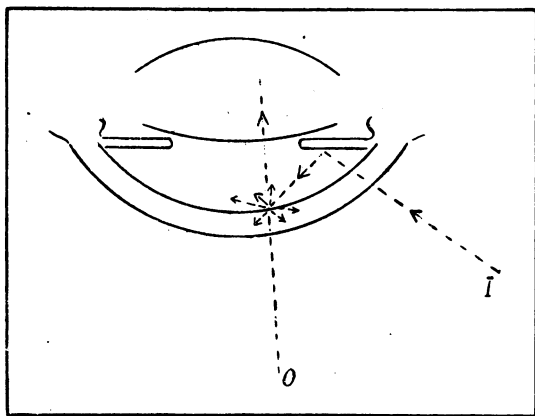


FIG. 19.

pigmented deposit scatters light, and may be seen vividly against the unilluminated visual background of the pupil-area.

I wish now to describe a particular clinical condition in terms of its appearance under various methods of illumination and observation. The twenty-two cases which I have carefully recorded and followed show different types of the affection—in many it is early, in some it is advanced. It seems fairly probable that, after beginning at the endothelium* of the centre of the cornea, it spreads centrifugally towards the periphery. As far as I can discover, the condition does not readily spread quite to the periphery of the cornea—or if it does so it must take a very long time—so that by the periphery of the affected area in a fairly

* In slit-lamp work, the method of specular reflection affords the only means of distinguishing between the endothelium and the back face of Descemet's membrane. Except in certain pathological circumstances Descemet's membrane is as one (optically) with the general corneal substance.

pronounced case it may be understood that I mean a boundary situated probably about the outer point of trisection of the distance from centre to periphery of the cornea. If the observer studies a very early case of this affection, he will see certain fine changes at or near the centre of the endothelial face of both corneae; whereas if he comes upon a more pronounced case he should look for these fine beginning ("younger") characteristic changes in the region of the edge of the affected area. Until the appearances of a moderately evident case have been familiarized, the beginner is not so likely to detect the very early cases; but I will begin the description with such a case.

When the cornea at or near its centre is examined by D.I. (wide slit) some very fine sparse scattered discrete glinting specks will be seen at the endothelial face (Fig. 20). In quite an early case they are by no means very evident, especially under the $f55$ objectives,

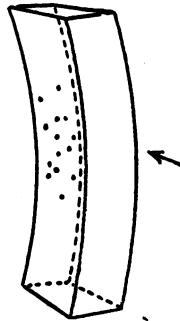


FIG. 20.

but when a little more obvious they should be detected by any careful observer. Their colour tends to appear brownish-gold and a beginner, chancing upon them for the first time, may think that these specks, thus seen, represent pigment deposited on the endothelial face. (Without colour, representation by diagram is not easy. Each speck thus seen may be taken to be somewhere about half a micrometer division with Oc. 2 and Obj. a2, i.e., about $20\ \mu$, or rather less). It should be noted that these small glinting points are visible at practically any angle of I and O (provided the total angle is not too wide), and hence so long as they exist, they are seen at any part of the vertical extent of the slit-beam (compare Fig. 5 under which it has been pointed out that the visible reflection off the regular endothelial face is restricted as regards the vertical diameter of the slit-beam). From this we are justified in wondering if we are dealing with curved irregularities at the endothelial face which show a glint at most angles of I and O according to the principles referred to under

Fig. 3. However, before coming to this conclusion the observer should first satisfy himself that the glinting specks are not pigment-deposit by applying ordinary R.I. (iris or lens) when it will be seen in all probability that they do not show obstruction to R.I. In some of the cases which I have recorded some pigment-deposit in various degrees, to which I shall refer again, has in addition been present, especially in the later stages; but this is not necessarily the rule, particularly in early cases. When the R.I. is applied some punctate elements, to be described later, may be seen in the affected region, but unless the case has reached what I call the second stage, R.I. reveals only a hint of very fine ones detectable only by very careful scrutiny; in viewing these it is necessary to

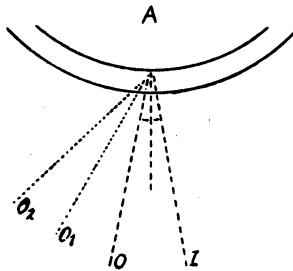


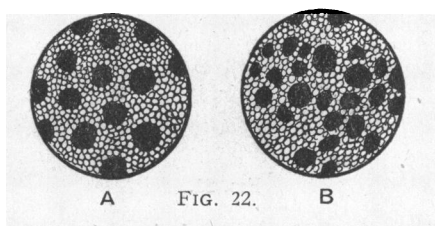
FIG. 21.

direct *O* very obliquely in order to bring the centre of the cornea into visual line with the illuminated iris.

In this earliest stage certain other features may be noticed by D.I. and by D.I.S.R. I have pointed out that the irregular discrete glints are detected irrespective of the angles of *I* and *O*, i.e., provided these angles are not too wide. An attempt should next be made to vary these angles. Now, with the existing apparatus it is very difficult to do this by swinging the microscope-base or the table lamp-arm whilst attempting at the same time to keep *I* and *O* on the same patch of endothelium about 0.5 mm. in diameter.* However, an easy means of varying the angle of *O* is provided in the fact that the objectives of the microscope-system converge. Hence (Fig. 21), by shutting first one eye then the other, we may take observation along either *O1* or *O2* in quick succession without needing to alter the setting of the apparatus. The observer should try to appreciate that the visibility of these small glinting points becomes greater as the axis of observation tends to approach *O* (Fig. 21), viz., the D.I.S.R. angle.

*Using the larger of the two dot-beams, with the 10.0 cm. focusing lens, Oc. 2 and Obj. a2, the diameter of the small patch of endothelium seen by D.I.S.R. covers about 13.0 micrometer-divisions. With Oc. 2 and Obj. a2, each division is 1/24th mm. or about 40 μ .

On looking by D.I.S.R. at the affected central endothelium of these early cases two features are evident: Firstly, numerous irregularly round dark non-reflecting areas showing, of course, no cell-outlines; secondly, the golden reflection from the regions between these dark areas seems a little bright and the cells perhaps rather more than normally clear. Dark areas, small and round, may be seen here and there in many a normal endothelium by D.I.S.R. In Vogt's "Atlas," Figs. 5, 6, 28, and 29 show them in senile and pathological conditions. Fig. 22A (herewith) is a purely diagrammatic representation of dark areas in the endothelium by D.I.S.R., intended to convey an idea of their appearance by contrast with the shining regions in which the endothelial cells are seen; it is not intended to be characteristic of any special condition. It is probable that dark areas can be caused in more than one way in different conditions. Whatever may be the immediate cause of such areas, it may at least be said



that they can be either areas of the endothelium which fail to give a specular reflex at all, or else areas which, though possessing reflecting properties, fail, say from alteration of contour, to reflect the light along the same axis as the light reflected by the rest of the endothelium.

On looking along *O* (Fig. 21) at the affected area of endothelium of these very early cases—that is the area in which we saw the specular glints at other angles—we see a picture something like that of Fig. 22B: dark areas of different sizes may be irregularly close-crowded, and so numerous that they almost dominate the small circular (dot-beam) field, some here and there being separated by the width of no more than one row of endothelial cells, or even in places seeming to touch one another. Their size may be said to cover one, two, up to three divisions of the micrometer scale with Oc. 2 and Obj. a2; they are in general round; some may be triangular or rather irregular here and there where they are crowded. There may be many in the beam-field, especially in the central region most affected; or a little further away only a few may be seen at one time. Fig. 22B gives a fair representation in an averagely crowded field, it being understood that the carpet of cells, in between these dark areas, everywhere shines

with a specular lustre, often conveying the appearance that the narrow regions, between close-set dark areas, tend slightly to stand forward with a mildly rounded contour towards the observer.

Careful attention is needed to make the following observations; and the patient must be steady: Let the slit-lamp be say on the observer's right, set with the larger of the two dot-apertures; Oc. 2 and Obj. a3. With the left eye shut, the observer should adjust *I* and *O* so that through the right objective he is seeing the affected endothelial area by D.I.S.R., but at a rather wider angle than is indicated in Fig. 21. The adjustment must be very exact, so that the whole dot-beam field is carpeted by endothelium uniformly bright except for the dark areas which it contains; the patch must not be brighter on one side than on the other. Under these conditions it will be observed that the borders of

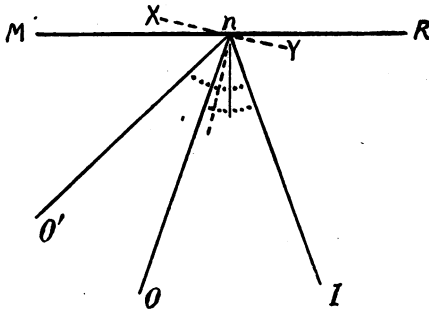


FIG. 23.

the dark areas are for the most part sharply defined and of uniform brightness all round. Let the observer (being careful not to move *I*) now quickly shut the right eye and open the left. He will then see that at the wider angle of *O* the general endothelial golden carpet is no longer visible, but that that part of the edge of many of the dark areas which is to his right shines vividly. This may be reversed, starting with a view of the endothelium by D.I.S.R. through the left objective, and the end-result is to see, through the right objective, reflexes from the observer's left edge of the dark areas. The experiment can be done in other ways, but this is the easiest. The explanation is that some of the reflected rays, when most of them are invisible, are deflected by part of the edge of the dark areas into the necessary direction to be seen through the second objective. In Fig. 23, if a view of part of the surface *MR* is mostly being seen through the right objective *O* by D.I.S.R., then any irregularly disposed part of that surface which, at the same time, may be seen through the left objective *O'* by D.I.S.R. must be inclined in the direction *XY*.

From this it is now clear that the endothelium at the edge of each D.I.S.R. dark area in these cases must be tilted always in a direction towards the centre of the dark area; in other words the edge is a base rim where the endothelium is gradually, not abruptly, leaving the general level to form a little elevation—corresponding to the dark area—whose apex, invisible, is directed towards the anterior chamber.

The specular glints, already familiar at any not too wide angle of D.I., are due to reflections off whatever portion of the rims of these elevations has the inclination necessary to reflect rays along the observation-axis of the moment. It would not be unreasonable to explain the increasing visibility, already referred to, of the D.I. glints as we approach the D.I.S.R. angle, on the basis that the inclining edge, in section, may follow a tiny curve having gradually increasing radius-vectors.

Thus far, deduction has been easy from the observed facts, but if we pursue the subject further we soon meet with aspects requiring further explanation. For example, in later stages of the affection specular D.I. glints may be found without the appearance in the same region of an adequate number of D.I.S.R. dark areas; and, wide of the obviously affected area, regions may be found which, showing pathologically numerous and crowded D.I.S.R. dark areas, yet show scarcely any D.I. glints. The subject is too long to pursue further here. My reason for already having gone to a certain extent into this question of the correlation between "glints" and "dark areas" is that in this stage at any rate the observations recorded above throw light on the nature of these changes; they are points which anyone who has acquired a little experience in slit-lamp work should be able to see for himself; and they afford an illustration of technical principles in slit-lamp work.

We have, then, in this type of very early case, which we may call of the first class or first stage, the D.I. glints and the D.I.S.R. dark areas, at or near the centre of the endothelium. In this stage not the slightest sign can be seen by means of the electric ophthalmoscope (used with its plus 20 lens): the slit-lamp affords the only means of detecting the condition. In a very slight case the glints may be seen over an area measuring perhaps little more than 1.0 mm. in diameter; they may easily be overlooked.

Specular glints on the deep face of the cornea are seen in other conditions, for example sometimes in irido-cyclitis. Their cause is not always apparent. One surmises that there is some minute irregularity of the endothelium or perhaps some small irregular deposit having specular properties. In the latter case the glint would be hidden behind the bright endothelial carpet at the D.I.S.R. angle, unless the endothelium were abnormal or the

deposit were in such close association with it as locally to impair its reflecting properties. These glints from other causes are often coarser and are usually less crisply defined; if few, they have not the tendency to the same grouped disposition; the endothelium as a whole by D.I.S.R. may or may not show abnormalities whose characteristics are somewhat different to those described above; there are no "punctate elements" by R.I. (see below); and there would probably be a history and associated other evidence of ocular trouble. In these affected cases of the "first (and second) stage" the patient is unaware of his trouble, and there is no change elsewhere in the eye, even in any other part of the cornea, to suggest its presence.

The second stage is defined by strikingly characteristic appearances under marginal "R.I." The condition, still central, or more or less so, will generally be found to be rather more in evidence in one eye than in the other. Care is necessary to avoid overlooking regions when mapping out the distribution of the affection because, certainly near the centre of the cornea, the iris is not everywhere easily available for marginal R.I. (hence it is advantageous to have the pupil undilated) and the area of the cornea within the field, being curved, does not all lie in the flat focal field of the microscope. Again, if R.I. by axial S.R.p.l.c. be used, which gives a very striking picture, the regions of the cornea through which we are able to project the efferent beam are restricted. Anyone who comes upon this condition himself for the first time, in a case which has reached the second stage, is likely to do so by seeing one or both of the following features: (1) Specular glints, about the central corneal region, in the deep face of the beam, at most ordinary angles by D.I.; they are similar to but cover a wider area than those already referred to in the description of the earliest stage (and as previously, it should be determined by R.I. that they are not pigment specks; though occasionally some pigment specks as an additional feature will be seen, here and there, adherent to the affected area); (2) a very characteristic appearance by marginal R.I. when the microscope is in focus on the back face of the cornea, at a region in front of a part of the pupil-edge on which the slit-beam is incident (see Figs. 11B and 12B). Under these conditions of marginal R.I. the observer will see the endothelium studded with minute discrete clear-cut features which, for want of a better term, I refer to as the "punctate elements" of this affection. Fig. 24 is a schematic representation of these, but to be critical it is inaccurate, as many such diagrams must be, because it would not be possible to see the corneal punctate elements in focus and also, at the same time, the pupil-border and the iris light-patch clearly defined behind them. For the sake of clearness the punctate elements are drawn

relatively larger than they should be, but this diagram gives a fairly accurate representation of the general conception. Their distribution for any field varies: it may be more crowded or less so, and it may be much less uniform. It will be noticed, from the


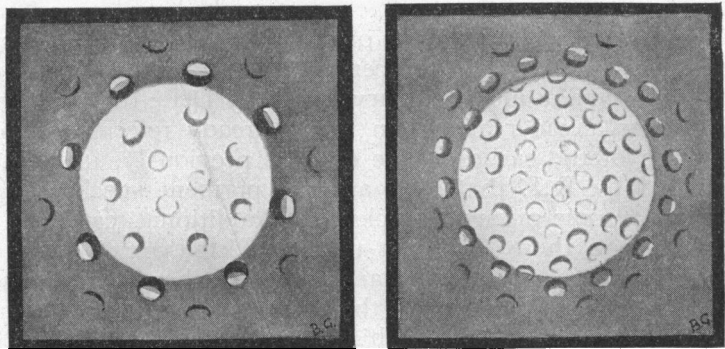


FIG. 24.



A FIG. 25. B

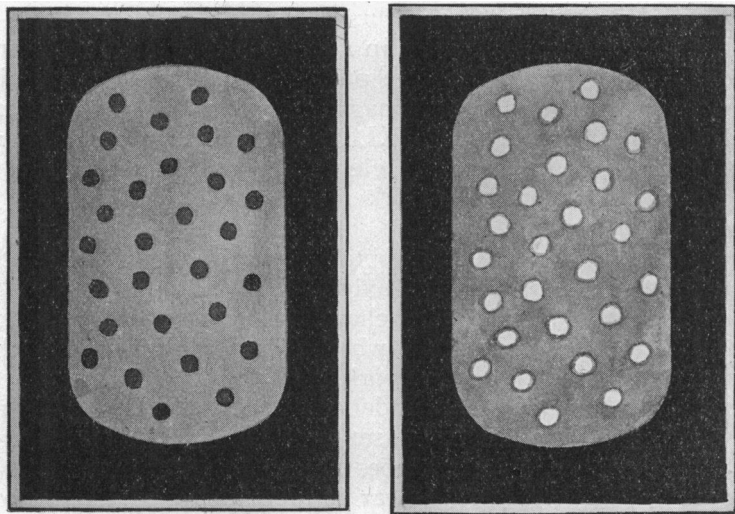
diagram (Fig. 24), how the punctate elements are more in evidence against the sharply defined junction of light and dark areas, defined by the pupil-edge. Oculars No. 2 with Objectives a2 are very suitable for thus viewing them; but when their presence is detected Objectives a3, though not necessary, may conveniently be used. With Oc. 2 and Obj. a2 they measure 0.5 to 1.0

division of the micrometer-scale. This clinical picture is a very characteristic one in slit-lamp work and when once it has been appreciated it need never be misunderstood.

Although it is unnecessary, for purposes of the clinical recognition, it is interesting to note a minute feature about these punctate elements, namely, that they show "reversed" illumination by marginal R.I.; that is, unlike lens-vacuoles and epithelial vacuoles, which show light to light and dark to dark, the punctate endothelial elements show light to dark and dark to light. I have endeavoured to indicate this diagrammatically in Fig. 24. These punctate elements in small clusters may be fairly close-set. Examples of such distribution in a cluster of them are shown in Figs. 25A, and 25B, which are purely schematic representations of clusters viewed under high magnification against a very small, but sharp and intense, focal R.I. from the arc diaphragm-lamp. When close-set the punctate elements convey somewhat the suggestion of beaten silver work referred to under "type A" in class 3.

Another striking picture is obtained by viewing the punctate elements retro-illuminated by axial S.R.p.l.c.; and though the picture thus seen is one very characteristic of this condition, a certain feature manifests itself which in principle is met with in other instances in slit-lamp work. When the microscope is focused on these elements under axial S.R.p.l.c. they appear sharply defined and dark in the setting of the brightly illuminated field; but when the microscope is racked a little towards the observer they change and appear lighter still than the unaltered field in which they are set. This is a feature which is easily seen; it can be appreciated with much less effort of attention than that required for discerning the reversed illumination by marginal R.I. described above. Fig. 26A is a schematic representation of the elements thus seen by axial S.R.p.l.c. with "forward" (i.e., towards the patient) racking of the microscope; and Fig. 26B with slight backward (i.e., towards the observer) racking of the microscope. The picture of the type of Fig. 26 is useful as helping to establish clinical recognition of this affection, but the alteration of relative illumination with focusing of the microscope cannot be used to provide inference as to the nature of the punctate elements, because alterations, on variation in the focusing of the microscope, may be seen—akin but not identical—in examining, under certain conditions by R.I., such irregular material as inflammatory unpigmented, and even pigmented, corneal deposits. It is unsafe to deduce the nature of these punctate elements from their appearance by the transmitted light of R.I. Even when we proceed to compare (by marginal R.I.) the reversed illumination of these elements with the unreversed illumination of vacuoles

in the substance of the lens, it must be remembered that an additional complication is introduced from the fact of the punctate endothelial elements being situated at the face of demarcation of two media (cornea and aqueous fluid) whose refractive indices differ. Interpretations of effects of this nature, based on their appearance by transmitted light, are so difficult that, as Mr. J. E. Barnard, F.R.S., informed me, even now there are features in ordinary microscopy work which have been known and studied



A

FIG. 26.

B

for years, concerning which it is not yet possible to say if they are depressions or excrescences.

From the clinical point of view the appearance of the punctate elements by axial S.R.p.l.c. is very striking and in my experience no condition in ophthalmology gives an appearance likely to be confused with it. One may well apply the term "honeycomb" to the idea which this picture conveys; its characteristic feature is the discrete nature of the small but sharply defined elements. Their distribution may in some cases be very uniform or in others, and according to the area in the field, it may be rather irregular. Fig. 26 is not to be taken as representative of the relative size (they are drawn relatively too large) or necessarily of the distribution of the punctate elements as seen by this method. When the microscope is focused upon the level of the corneal endothelium, the width of the axial S.R.p.l.c. beam is about 15 micrometer divisions (Oc. 2, Obj. a2); the size of the punctate elements thus

seen may be taken as 0.5 to 0.75 of a division. I think, however, that anyone, when seeing these features thus, will readily correlate them with the general conception of Fig. 25. If the paraxial margin is narrow, faint and inconspicuous, the observer may see reversed illumination in those elements which lie approximately in visual line with it.

In this second stage or class the observer will, therefore, expect to see, in the endothelium near the centre of the cornea, by D.I. irrespective of the chosen angle, an area studded with discrete specular glints, much as in Fig. 20; whilst by marginal R.I. (e.g., from pupil-edge, Fig. 24) or by R.I. axial S.R.p.l.c. he will expect to see the characteristic punctate elements. From a practical clinical point of view, provided proper attention is paid to manipulation of the apparatus, no difficulty should be experienced in thus recognizing the affection. In fact, when it is moderately advanced, the punctate elements will often show fairly well by a R.I. which is less critical, e.g., R.I. indiscriminately from the iris, or from the spread specular reflection of the anterior lens-capsule. On examining by D.I.S.R., dark areas will be found distributed probably over a much wider area than was the case in the first class described.

I have said that a hint of the punctate elements may have been seen in the earlier less pronounced stage. They represent little well-defined endothelial elevations such as we have discussed; and it is by an interpretation of the reflections at the rims of D.I.S.R. dark areas that we are justified in applying the term elevations. It should particularly be noticed that in the immediately underlying corneal tissue there is no increase of relucency or any other visible abnormality by D.I. The optical effects at these elevated rims indicate that the rims, anteriorly, are in contact, not with fluid, but with a material which is in optical continuity with ordinary corneal tissue, or at any rate material similar to it in its optical properties.

In the second stage the patient's vision is not impaired. When the observer has detected the condition by means of the slit-lamp, it is just possible to appreciate its presence against the red reflex by the electric ophthalmoscope used close up with plus 20 lens; but thus seen it is so faint that from a practical point of view the condition in this stage is detectable only by microscopy.

Third class: The distribution is wider; if Fig. 27 (1) might represent it in the class described hitherto, Fig. 27 (2) represents what it might be in an average case of the third class. I have seen two types of this class: (A) in which the condition is practically uniform throughout an area as wide as is indicated, or even wider, practically reaching the periphery; and (B) in which the central region shows quite peculiar features, whilst the marginal region

shows characteristic punctate elements [Fig. 27 (2)]. It is this last feature especially—the presence of punctate elements round the margin—which makes me suggest that these cases, perhaps first starting in the centre in the manner of cases already described, may subsequently spread centrifugally. But the period of observation on cases—up to nearly two and a half years—has not been sufficient to enable me to settle this, and I readily admit that type “B” might possibly prove to be a class of serious chronic endothelial affection more apart to itself from the beginning.

Vision is affected in this third stage; the abnormality can perhaps just be detected, but not primarily identified, by means of the electric ophthalmoscope (with plus 20 lens); the view of the

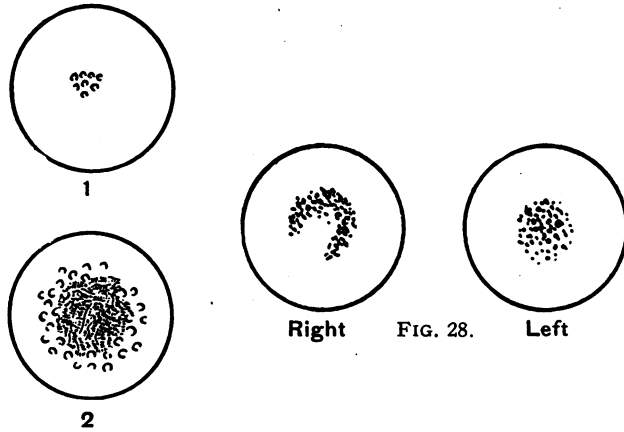


FIG. 27.

FIG. 28.

fundus is probably hazy. Type “A” is by far the commoner. By D.I. it shows multiple specular glints (as those of Fig. 20) at most angles; they are numerous and fine. Another clear feature may be weakly pigmented debris which may show brightly by the method of Fig. 19. The pigment is prone to lie near the centre: its distribution in one such case is shown in Fig. 28. This type by D.I.S.R. may reveal no striking view of the endothelium, as though to a large extent it had lost its reflecting properties, save for the multiple fine glinting specks; in other cases and in other areas the picture may tend more to resemble that of Fig. 22B. Marginal R.I. reveals the most characteristic feature. One sees not so much well-defined round punctate elements, but fine and close-set granular or grained multiple refracting irregularities, causing a patterning very suggestive of certain forms of beaten-silver work. At the periphery the

irregularities may tend to be more punctate and discrete. The individual irregularities show (by marginal R.I.) reversed illumination. Another suggestion which this picture conveys by R.I. is that of a very thin transparent membrane which has become dried and crinkled; whence at one time I thought to name this condition "ichthyosis" of the endothelial face, but there are obvious objections to borrowing this term. One of these patients whom I have now had under observation for two years, now aged 64, says that her sight has been failing subjectively for six years or possibly more. There is a record that four years ago R.V. was 6/24 and L.V. 6/12, without glasses; also "hazy view of fundus, refraction about normal." Her unaided vision now is R. 6/36; L. 6/36; but R.V. with +0.5 sph. is 6/24, and L.V. with +0.75 cyl. horiz. is 6/24. The lenses are senile in type (relief of nucleus, reflection in posterior cortex) but there are no "lens-opacities" in the ordinary sense. The vitreous is clear. Anterior to the endothelium are a few very faint and fine traces of short vertical folds of Descemet's membrane; these were noted as being present eighteen months ago.

Type "B" in this class is much rarer. I have careful records of two cases and brief notes on a third patient whom I lost sight of a year ago. The more central region (see Fig. 27, 2) shows very visible and striking changes by D.I. and scarcely any appreciable change by R.I., save that in axial S.R.p.l.c. there is a certain vaguely gelatinous appearance, with perhaps also evidence of some deposited pigment here and there. This faintly gelatinous look by R.I., S.R.p.l.c. tempts one—unjustifiably on such evidence alone—to suggest that they may be slight general thickening. Although the slit-lamp appearances of such a central area by D.I. are so very striking and very visible, it is by no means easy to give them an exact verbal description. Dr. G. E. de Schweinitz has told me that he recognized a corneal affection confined to the endothelial region in elderly persons; I have heard Mr. A. C. Hudson say the same, and I think it likely that these opinions are based on a very critical appreciation by oblique illumination of the central region of cases of this type. I recommend a wide-slit (D.I.); angles as Fig. 29, i.e., far from D.I.S.R. The view of the irregular endothelial face now stands out in the picture so visibly that the observer scarcely notices the ordinary grey relucency of the corneal substance in front; it is almost as if he were looking straight on to the uneven endothelial face through an unseen corneal substance in front. Fig. 30 (the D.I. beam) is a representation of this very visible irregular face. I can best liken the appearance to the greyness, the unevenness and the hueless lustre of the surface of pewter which has become partly corroded. Some pigment specks may also be seen, some of which are minute and

hair-like. If the angle of I is rather less oblique, parts of the endothelium may suggest more the appearance of uneven and pitted asphalt sparsely bespattered with coarse sand, due to the appearance now of specular glints. By using high magnification with the arc slit-lamp the appearance suggests stereoscopically

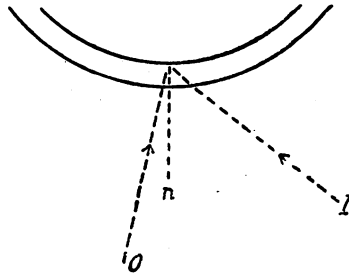


FIG. 29.

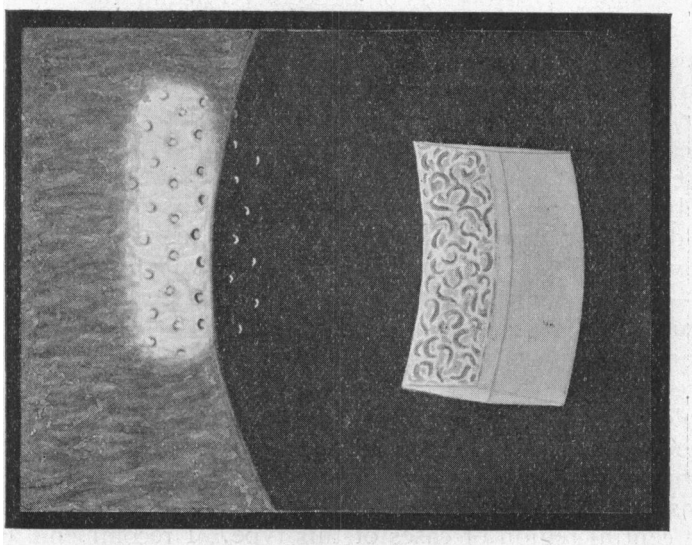


FIG. 30.

that this central endothelium is of uneven contour, with close-set concavities and convexities facing the observer; yet the edges of by no means all these give rise to specular glints. After the unusual and striking visibility of the endothelial face has been noted thus by D.I., the transparent featureless view of the same region by R.I. comes almost as a surprise.

This central region in general may now be examined by D.I.S.R.. The type of picture of Fig. 22B is then seen, the

visibility of the individual cells being very distinct. It is not so easy to correlate these features with those seen at the other angles which gave the "corroded pewter" type of picture; but there is not space to discuss this now. The central region of this type (B) therefore shows features, depending on the relative angles of *I* and *O*: (1) When as in Fig. 31A—irregular, uneven, grey, like corroded pewter; (2) when as in Fig. 31B—visible irregularity

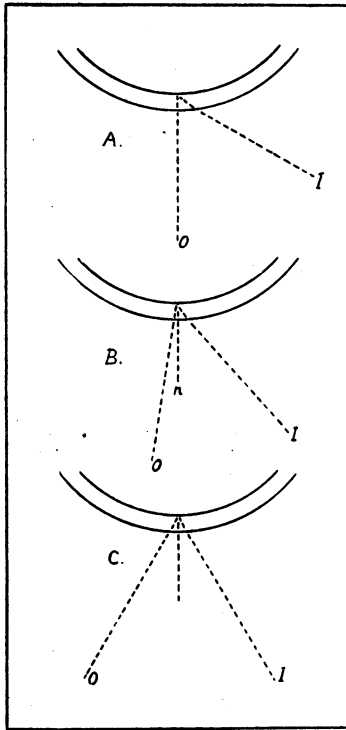


FIG. 31.

of contour, with numerous glinting specks; (3) when as in Fig. 31C—dark non-reflecting areas in a reflecting setting whose endothelial cells are very plainly seen.

Attention must now be turned to the peripheral region of the affected area of these cases, which presents a different appearance (see diagrammatically in Fig. 27, 2). For this, the round dot-beam may be directed through the cornea somewhere towards its lower periphery (Fig. 11A), or elsewhere. When this beam is critically focused on the iris, typical punctate elements may be seen in the endothelium. These seem reluctant to reach the extreme periphery of the cornea, which is generally clear; but

they extend further in some regions, almost reaching the periphery. If the beam is directed as in Fig. 32, I have found that specular glints by D.I. can be seen (O_1) where (d_1) the beam traverses the cornea; and near by, punctate elements can be seen (O_2) where (d_2) the endothelium is retro-illuminated. The numerical distribution for a given area is about the same in both. This combined viewing is easy because, towards the periphery, the cornea is close to the iris. Fig. 30 is a diagrammatic, and composite picture to show the corroded pewter-like central region by D.I. and also the punctate elements peripheralwards, by marginal R.I. A picture, with all the features which this shows could not,

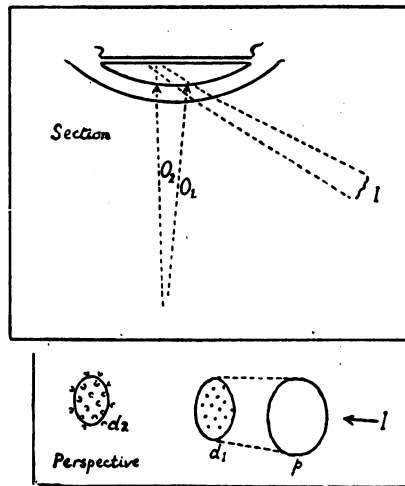


FIG. 32.

in practice, be obtained in one effect (and again, as in Fig. 24, the iris could not be in visual focus whilst the punctate elements are visible). Seen by R.I. from the dot-beam or from axial S.R.p.l.c. these peripheral punctate elements are identical with those which characterize the central region of "stage 2." They were not revealed by the R.I. of the slit-beam in the clear manner indicated; but they showed very sharply by R.I. of the dot-beam.

Class four remains to be described. By it I mean cases of the type described in class "three" which reveal, in addition, changes in the corneal epithelium, and, if any are to be seen, in the intermediate corneal substance. I have in only one case seen the epithelium affected in the cases referred to under "type A," stage three; the other three cases in which I have studied associated epithelial changes have been of the rarer type (B). The epithelial disturbance was central in distribution. I can best give an account of a patient (woman) who came to Moorfields

Hospital under Mr. Herbert Fisher early in 1923. (The diagrams Figs. 30 and 27 (2) indicate the condition of her endothelium.) The following information is quoted from extensive notes which I have made at various times on this patient :

On her first attending hospital : "Sight of both eyes poor for about three years; right sometimes gets clearer but never the left; never redness or pain in the eyes" (patient not of observant type; it is conceivable that deterioration of vision might have begun before the alleged period and not have been noticed). Aged 54 years; general health good; lenses clear; tension normal; fields normal. Slit-lamp examination: Endothelial changes, very striking, right and left, evidence and extent being slightly more in left than right; type as Fig. 30; a little sparse pigment peppered here and there on the deep aspect of the altered irregular looking endothelial face. A very slight suspicion of patchy increase in superficial part of corneae near centre. No vascularization. In both right and left the epithelium at and near centre shows, by R.I., discrete, isolated, thinly ringed areas (vacuoles) of various sizes, but not very numerous; the biggest distort the surface specular reflex.

April 20, 1923.—Much the same.

June 1, 1923.—Left—epithelium, central (not peripheralwards) shows by ordinary clinical examination gross oedema with bullae; right—slight oedema, with smaller bullae. Tension normal. Slit-lamp—changes characteristic of a very oedematous (vacuolar) epithelium.

June 8, 1923.—The same.

June 22, 1923.—Epithelium appears much clearer, especially in right; but slit-lamp shows vacuoles, over centre, in right and left, especially left.

Slit-lamp examinations revealed no change in the condition of the endothelium before, during or after the attack of epithelial oedema in June.

March 18, 1924.—Only complaint is that of impaired vision. "Left eye varies, its vision being dimmer sometimes than at others; never redness or pain." Slit-lamp: Left—a small very faintly nebulous oval patch of increased relucency, in superficial substance beneath the epithelium. Endothelium of both eyes as last year. Left epithelium—many isolated medium and small vacuoles in centre. Right epithelium—an occasional flat inconspicuous shrunk-looking vacuole, a few only, near centre. Watery homatropin and cocain was then put into both eyes. Right eye was then investigated and notes made, occupying two hours: after that, on returning to left eye I could find no epithelial vacuoles.

March 25, 1924 (7.0 p.m.).—A cold night. No drops used. Right epithelium—inconspicuous shrunk-looking (ill-defined) vacuoles, as last week, but I cannot say whether or not they are the same ones. Very little time spent on this examination of right; I then proceeded without delay to examine left epithelium, which showed, in centre, very definite intraepithelial vacuolation: vacuoles discrete and isolated but in moderate number; size unequal; very clearly seen by axial S.R.p.l.c.; largest visible by marginal R.I. of the corneal dot-beam itself (as described under Fig. 19); I showed the vacuoles by R.I., S.R.p.l.c., etc., through a demonstrating eye-piece attached to microscope, to Mr. Thomas Colley, Senior House Surgeon, and to Mr. H. M. Armstrong, Second House Surgeon, who saw and appreciated them quite clearly. I then proceeded to show the features in the endothelium of the right eye, spending ten to fifteen minutes. On then returning to left eye, I could find no small epithelial vacuoles, and only two vacuoles of medium size; but R.I. of medium intensity, widely reflected (S.R.) off the anterior lens-capsule, revealed a slightly vague boggy appearance of this left epithelium where, in general, the vacuolation had been just now. The patient sat aside one hour with eyes shut; when I then re-examined left eye I found multiple small very discrete vacuoles in the central epithelium (each about 30 to 40 μ), seen very clearly by R.I. axial S.R.p.l.c., moderately by R.I. of critically focused dot-beam on iris, and not at all by R.I. of corneal dot-beam (arranged as in Fig. 17).

March 27, 1924 (7.0 p.m.).—A cold night. Patient walked some way to hospital because of bus strike. I examined left epithelium without delay. Centre showed

sharply defined, discrete, irregularly distributed vacuoles, isolated or in patchy collections, as in Fig. 33; typical unreversed illumination (by marginal R.I.). Size —1, 2, up to 3 micrometer divisions with Oc. 2 and Obj. a3. For three-quarters of an hour I made other examinations of both eyes: then, returning to the left epithelium, I found no vacuolation. Patient took a walk for quarter of an hour; on her return I found in centre of her left epithelium a fair number of vacuoles,

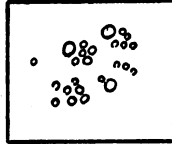


FIG. 33.

but not so many as on first occasion that evening; they soon disappeared after I had spent a little time examining them. I then examined other parts of her eyes during about one hour, but no vacuolation reappeared in the epithelium during or by the end of that time.

May, 1924.—She came up on a warm afternoon. She rode to the hospital. There was fine central intraepithelial vacuolation in both eyes. Circumstances prevented me making more than a brief examination. She considered she was about "the same." Endothelium as previously.

The following features concerning the epithelium are therefore presented by this case:—An intraepithelial vacuolation which, confined to the central regions, is more in evidence in the eye in which the endothelial affection is slightly more pronounced; that though the endothelial condition remains stationary (or? insidiously becomes worse) the epithelial vacuolation is prone to show remissions; a severe remission early in the summer of 1923, showing crude oedema of the central epithelium, lasted about two months; subsequently the epithelium, in the worse eye, though appearing by ordinary methods of clinical examination bright and normal, revealed, under slit-lamp examination, a fine central vacuolation subject to variations under some influence whose nature is uncertain: neither temperature nor exertion seemed to be influencing factors. It does, however, seem that this fine unobtrusive vacuolation disappears shortly after slit-lamp examination of the eyes is begun.

Throughout the period over which this patient was kept under observation there was practically no visible change in the intervening corneal substance. The corneae were not especially sensitive, but the patient could appreciate their being touched with cotton-wool.

The following general remarks are based on a review of all the notes which I possess on cases revealing, in whatever "stage," this affection of the deep face of the cornea. The ages range from 40 to 82 years; the sex-distribution is about even. In none have I found any abnormality of the corneal nerve-fibres. The aqueous fluid reveals no increase in visibility of the homogeneous

flare. The lenses in most are clear, or show only ordinary senile characteristics. The vitreous fluid does not display "floaters" or "dust," save in two or three of the cases. One patient had diabetes and diabetic lens-changes. Many naturally had pyorrhoea, but some, on the evidence only of surface-inspection, had not. One of the early central type, a man, aged 57 years, came because of very early degenerative changes (reducing vision to "6/9 partly") at one macula; incidentally there was a small superficial degenerative brown line in one cornea; he had very bad pyorrhoea, and his whole health improved after extraction of all his teeth. A patient aged 40 years, with a very slight beginning central affection in both corneae, has patchy faint iridescence of one posterior lens-capsule; vision is normal. Save that this bilateral condition affects elderly persons, I am aware of no common aetiological factor. I have seen no case undergo resolution, treated or untreated. It would be merely empirical to suggest whether in the severe cases tapping of the aqueous fluid might prove of benefit.

I have never had an opportunity to examine with the slit-lamp an established case of Fuchs' "Dystrophia Epithelialis Corneae"; I do not know if any relationship exists between this condition and that of cases of the fourth "class" which I have described.

As to the nature of the pathological processes which give rise to the clinical appearances I have described: that there are little elevations of the endothelium towards the anterior chamber we have definite evidence by interpretation of the reflections occurring off the rim of the elevated areas. Without prolonging this report by giving the reasons now I would mention that I have been unable to come to a definite conclusion as to the state of the endothelium towards the apex of these little elevations, on which account I did not discuss them beyond the region of their small curved rim. If aqueous fluid could gain access, through these regions, to the overlying substance, we should, on known principles, expect visible changes. It would be in keeping with the optical slit-lamp features to suggest the possibility that elevations of the endothelium towards the anterior chamber might be caused by some local product of the metabolism of its own cells—a structureless product which might have properties analogous to those of the material composing Descemet's membrane, its optical continuity with which would thereby be accounted for. The appearance by D.I. of coarse irregularity of the central region, and the absence of any marked peculiarity of the same region by R.I., in cases of the type indicated by Fig. 30, could be explained by assuming either a lateral spread and fusion of small multiple changes which early are discrete, or else a more diffuse and ill-defined initial manifestation of the process.

Dr. Vogt refers to the dark areas in Figs. 5 and 6 of his "Atlas" as representing Hassal-Henle warts.

I have on different occasions in the past showed to Mr. Treacher Collins some of the cases I have described, and he kindly made a slit-lamp examination of them. He suggested that the punctate elements may represent hyaline thickenings of Descemet's membrane, and he pointed out, as an analogy, that the pigment epithelium on the elastic membrane of Bruch may form hyaline thickenings whose distribution is either plaque-like and spread, or, as in Tay's so-called "choroiditis," nodular. In one of his Erasmus Wilson lectures (*Lancet*, February, 1900) Mr. Treacher Collins gave instances of the new formation of a hyaline membrane following perforating wounds of the cornea, and concluded as follows: "If, as seems to be shown, under some abnormal stimulus, the endothelial cells lining the posterior limiting membrane are capable of producing nodules or a layer of a substance indistinguishable in structure from that membrane, it seems fair to assume that it itself is originally developed from them." An illustration of a section showing hyaline excrescences on the deep face of Descemet's membrane will be found in Fig. 216, page 485, Collins and Mayou, "Pathology and Bacteriology of the Eye."

As the slit-lamp manifestations I have described seem prone to start about the centre of the cornea, it is interesting to note Colonel R. H. Elliot's findings of hyaline thickenings on Descemet's membrane in discs removed from the periphery in trephining (*Trans. Ophthalm. Soc.*, Vol. XXXVIII, 1918, page 239, "The Histology of the Trephined Disc in Glaucoma Operations").

As regards individual dissimilarity of the cases described, considering them as a whole from the clinical point of view: the difference between "class 1" and "class 2" is really artificial and no dividing line exists between them. Other clinical instances in ophthalmology reveal epithelial vacuolation secondary to disturbance of the endothelium, e.g., I have found epithelial vacuolation strictly limited to the geographical sites overlying large massed precipitates on the endothelium. I admit that the greatest "gap" in similarity of clinical types is between the earlier restricted "central" type and the severer more widely spread type. Of the latter, the commoner "beaten silver" form has all over, and especially peripheralwards, optical appearances by R.I., which, though minute, in principle closely resemble those of the smallest punctate elements of the "class 2" type; finally, the "corroded pewter" type (Fig. 29) shows definite and characteristic punctate elements peripheralwards.

I admit that the suggestion that the types described may all represent different possible stages in the course of one affection

is certainly open to question. The reasons for this suggestion may be summarized, in conclusion, as follows: That the condition is always bilateral and chronic; that the eyes, excluding possible epithelial changes, show no particular peculiarity in any other parts than at the endothelial face of the cornea; that the distribution, if over a small area, is central, but if extensive, seems also to reach the extreme periphery; that the endothelium in all the cases recorded, whatever pictorial differences it may show as between one case and another, has certain general peculiarities common to all the cases, namely, that the changes, excluding some adventitious pigment, are not of the nature of formed deposits derived from the anterior chamber, but are intrinsically of the deep corneal face; and, finally, in all the cases by R.I. these changes influence light in a manner which is refractile rather than obstructive or dispersive.

I ought to add that I have no evidence to disprove that in the severer cases the condition may begin evenly, and at the same time, over the whole of the subsequently affected area.

May it be that the endothelium, threatened in places with loss (?senile) of its very necessary impervious qualities, resorts to the formation of this hyaline material in an attempt at making a protective barrier against incursion of the aqueous fluid?

The chief interest in establishing that the various cases are different stages of the one affection, inevitably, if imperceptibly, extending, might lie in the matter of prognosis, because the wide-spread form is a serious one; I have no knowledge of the ultimate fate of patients so affected.

Since rendering this report in August I came upon a case of this affection whilst demonstrating, by Dr. Vogt's courtesy, at his course in September. It was a case showing the typical "beaten-silver" appearance. When I spoke to Dr. Vogt about it he referred me to the following communication he had made, of the existence of which I was previously unaware. It is appended herewith in full. I am indebted to Mr. Harrison Butler for the following literal translation, which he very kindly read to me whilst we were demonstrating in Zurich together.

Arch. f. Ophthal., 1921, 106 Band, page 102. "Drop-like Endothelial Prominences." In senile persons, especially those who have rich pigmentation of the posterior wall of the cornea, which takes place after irido-cyclitis and in total cataract, and also frequently in old persons having clear media, many and closely packed cavities, directed facing the chamber in the endothelial mosaic, appear upon the whole of the posterior corneal mirror-area, which appear not only in the mirror-axis but also at a considerable distance from it, giving the impression of shining points; and they shine out from the surrounding darkness so that one is reminded of drops. The optical appearances suggest prominences directed towards the anterior chamber. If I examine such cases in transmitted light well-developed and obvious coarse bedewing is revealed in the region of the prominences. All the same, it could be determined in my cases that the dew-drops corresponded, not to the oedema of single cells, but represented the size and position of these prominences. The dew-drops were definitely coarse. The many small individual cells showed sharp outlines and no oedema could be detected. For the present there is no ground for supposing that these shining prominences are anything else than especially close-set Henle's warts of Descemet's membrane. Normally these features are well known as being found at the periphery. In advanced age

I often found them as senile changes absolutely opposite the pupillary area in especially crowded numbers.

If these prominences, as is not unusually the case, are combined with plentiful pigment-dust (previously described, page 102) a highly pathological aspect may be suggested to one who is not experienced in slit-lamp microscopy.

In focal light one sees the drop-like shining prominences and near them the brown pigment-dust; and, in the mirror-area, the dark round holes in whose sides the cells are very clear. Finally, one recognizes the gross bedewing and at the same time the fine black peppering which the pigment causes. In sympathetic ophthalmia the knowledge of such appearances is of importance; an inexperienced observer could easily see beginning precipitates in the dust and wart-like formations. Also in industrial accidents the appearance could cause difficulties, so that an accurate knowledge is indispensable for every slit-lamp observer. (Two illustrations accompany the text.)

ANNOTATION

Mistakes

Froude once wrote "instruction does not prevent waste of time or mistakes; and mistakes are often the best teachers of all." In ophthalmic surgery, as in other walks of life, the best performer is not the man who makes no mistakes but he who makes the fewest. It is not easy to give a classification of mistakes. The cynic will divide them into those that matter and those that do not, and will probably qualify this by saying that as long as the patient does not realize that a mistake has been made, no mistake matters. Then, again, there are those we make for ourselves and those we see made by other people; the wise men will learn from both kinds, but, if he is really wise, he will learn more from his own mistakes than from those of others, though he will surely get more amusement from those of his neighbours than from his own. The patient will almost certainly estimate a mistake at its wrong value; for how often do we get credit for a deed when we really deserve blame? And the reverse. It is not always wise to ask a female patient her age, and it is a mistake to handle a patient without first washing the hands. When all is said, mistakes in our profession are usually those of omission rather than of commission; most of them arise from the failure on the part of the surgeon to put into practice the routine examination of the case, often due to the patient coming late for the appointment, or to the surgeon trying to fit more work into the day than can be dealt with in the time at his disposal.

It is a mistake for a man so to concentrate on any particular branch of his work that he loses sight of other equally important parts of the examination; for instance, there is little excuse for a man who is so bound up in eighths of a dioptré of astigmatism that he misses a detachment of the retina, except the time honoured excuse of "mere ignorance."