

Male
68In
Room:
Loc:2

Caucasian
345lb

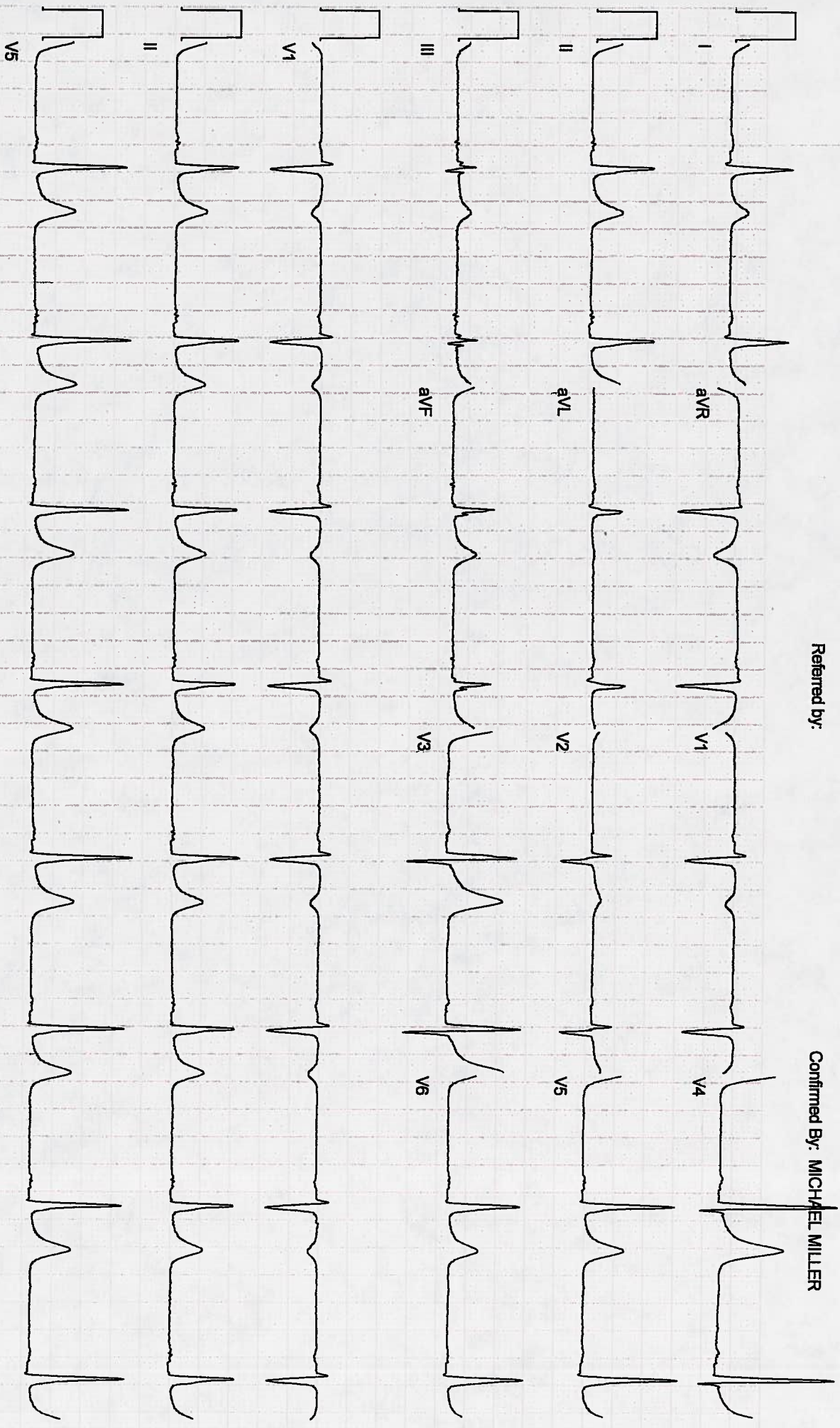
Vent. rate 48
PR interval 184 ms
QRS duration 110 ms
QT/QTc 480/428 ms
P-R-T axes 27 36 51

Marked sinus bradycardia
Abnormal ECG
When compared with ECG of 28-AUG-2015 22:01, (unconfirmed)
No significant change was found

Technician:
Test Ind:

Referred by:

Confirmed By: MICHAEL MILLER



Male
68in
Room:
Loc:2

Caucasian
345lb
Vent. rate
PR interval
QRS duration
QT/QTc
P-R-T axes

55
160
94
478/457
23 29
37

BPM
ms
ms
ms
ms
ms

Sinus bradycardia with frequent Premature ventricular complexes in a pattern of bigeminy
Otherwise normal ECG
When compared with ECG of 01-SEP-2015 10:40, (unconfirmed)
Premature ventricular complexes are now Present

Technician: FRANCES TAYMIES
Test Ind:

Referred by:

Confirmed By: MICHAEL MILLER

