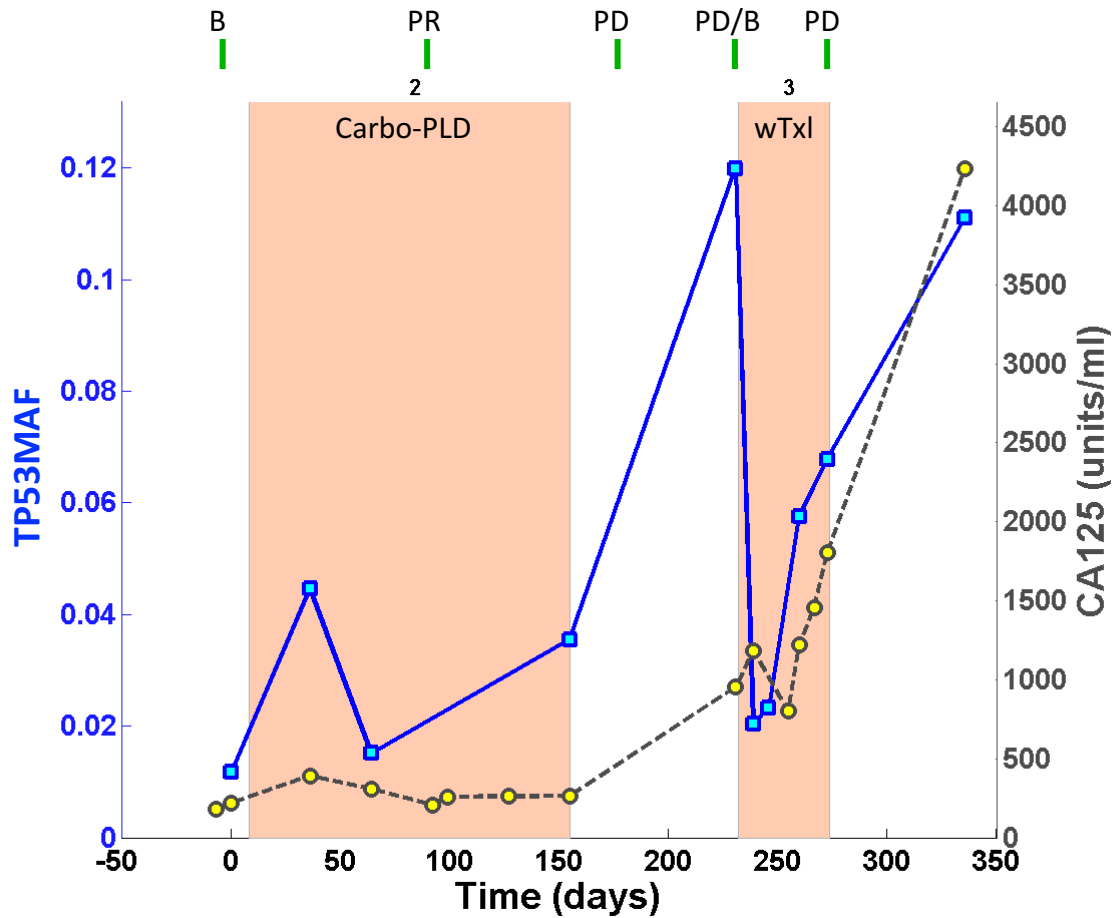


S3 Fig. Graphs of TP53MAF and CA-125 changes by patient.

Table of Contents

OV04-21	2
OV04-30	3
OV04-33	4
OV04-36	5
OV04-39	6
OV04-47	7
OV04-49	8
OV04-52	9
OV04-57	10
OV04-63	11
OV04-64	12
OV04-65	13
OV04-68	14
OV04-70	15
OV04-72	16
OV04-73	17
OV04-74	18
OV04-75	19
OV04-76	20
OV04-79	21
OV04-81	22
OV04-90	23
OV04-95	24
OV04-97	25
OV04-98	26
OV04-102	27
OV04-105	28
OV04-112	29
OV04-114	30
OV04-116	31
OV04-127	32
OV04-129	33
OV04-133	34
OV04-135	35
OV04-142	36
OV04-144	37
OV04-145	38
OV04-150	39
OV04-161	40
OV04-200	41



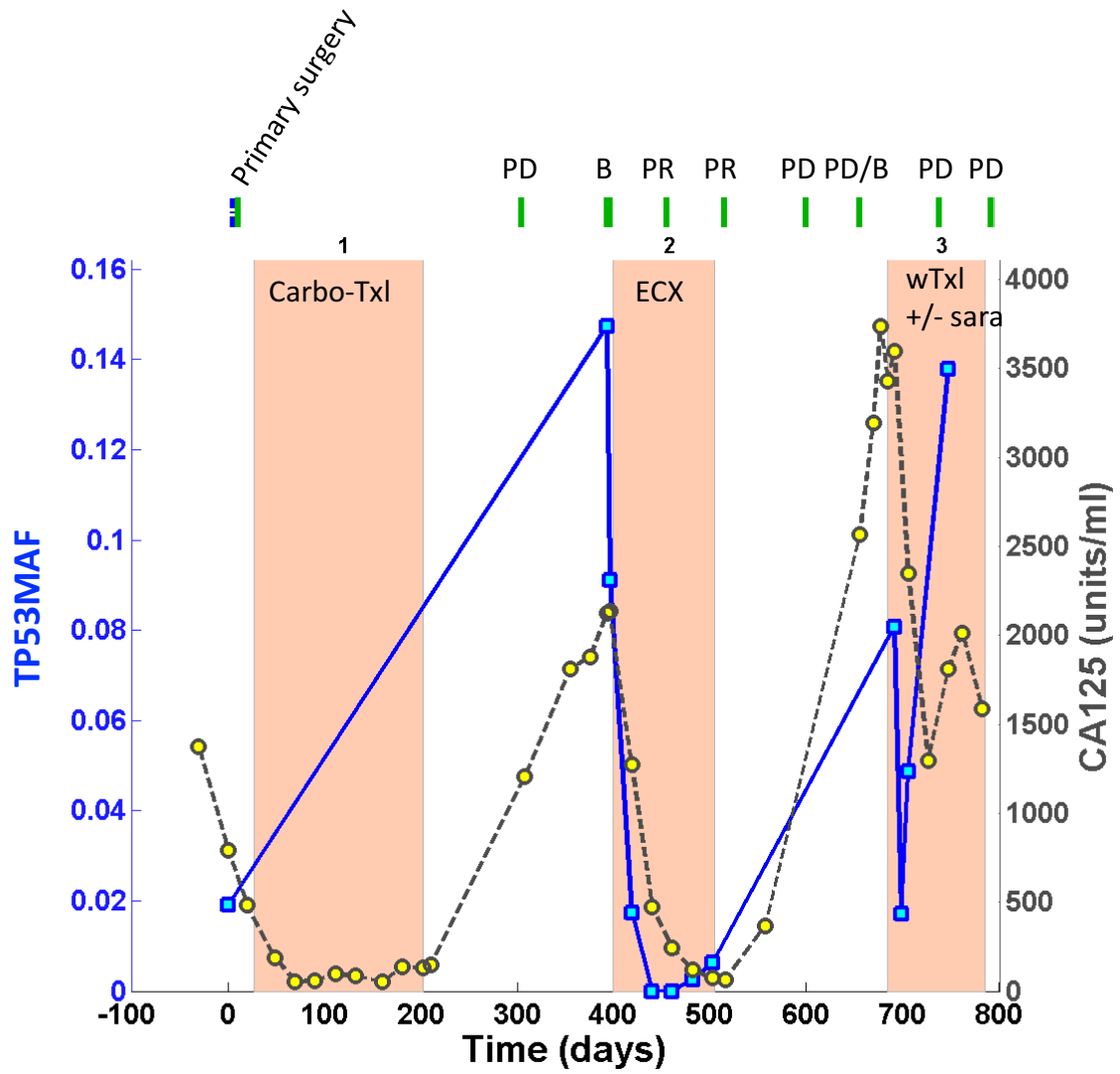
Key:

■—■, ctDNA; ●---●, CA-125; , course of chemotherapy; |, CT scan; |, clinical progression; ▼, ascitic or pleural drain. Number above the orange block refers to the course (line) of treatment. B, baseline CT; CR, complete response on CT; PR, partial response on CT; PD, progressive disease on CT; SD, stable disease on CT. Carbo, carboplatin; Carbo-Txl, carboplatin and paclitaxel; Cis-PLD, cisplatin and liposomal doxorubicin ECX, epirubicin, cisplatin and capecitabine; Gem, gemcitabine; PLD, pegylated liposomal doxorubicin; wTxI, weekly paclitaxel; xTxI+/-sara, weekly paclitaxel +/- saracatinib (on SaPPrOC trial); Topo, topotecan; RT, radiotherapy

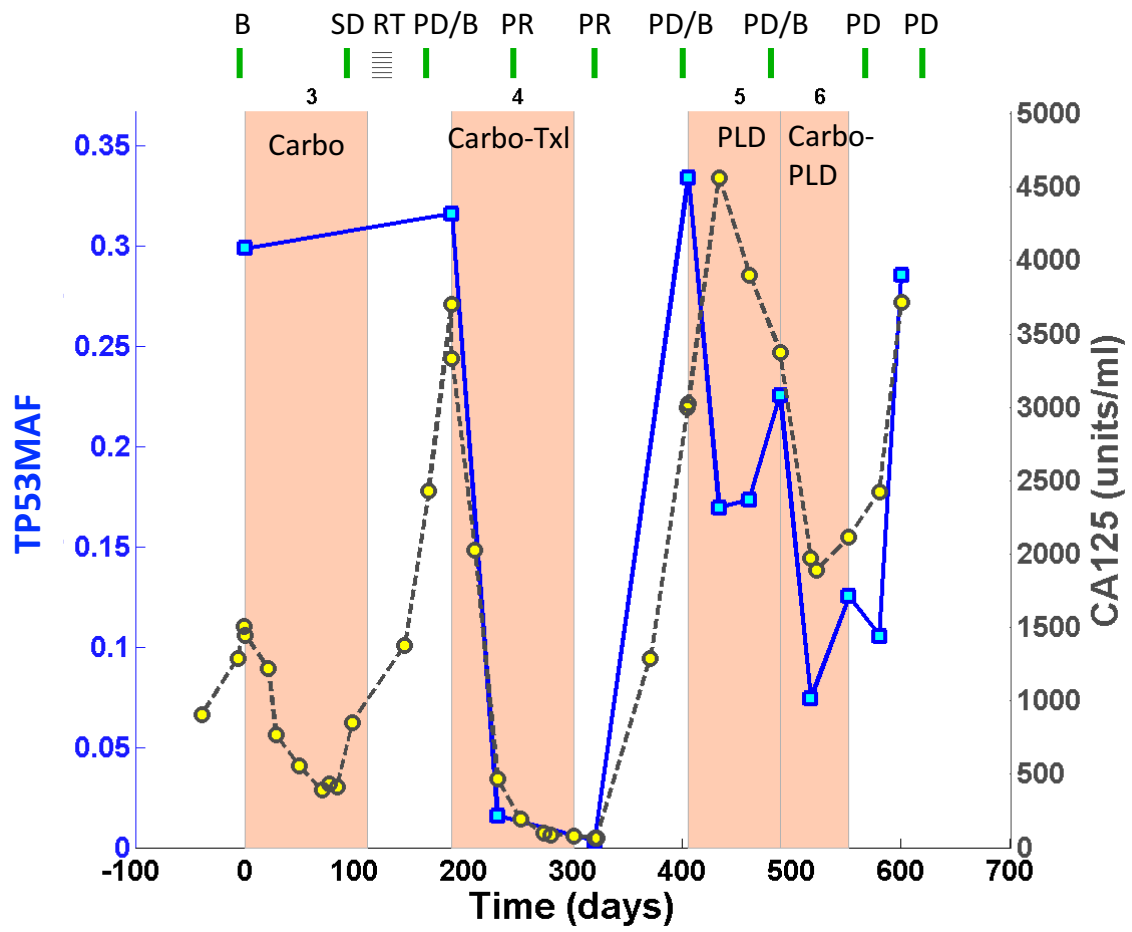
OV04-30

Stage at diagnosis: IIIC

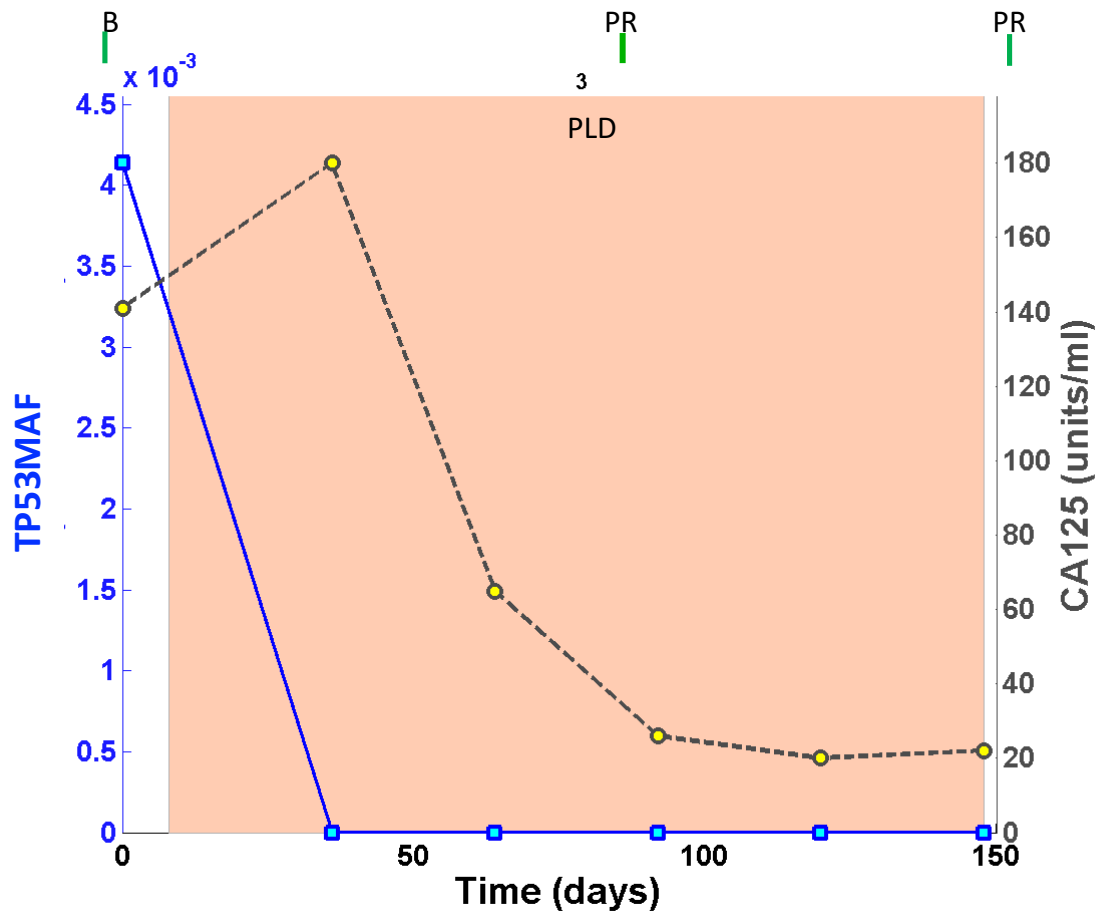
Residual disease: no residual



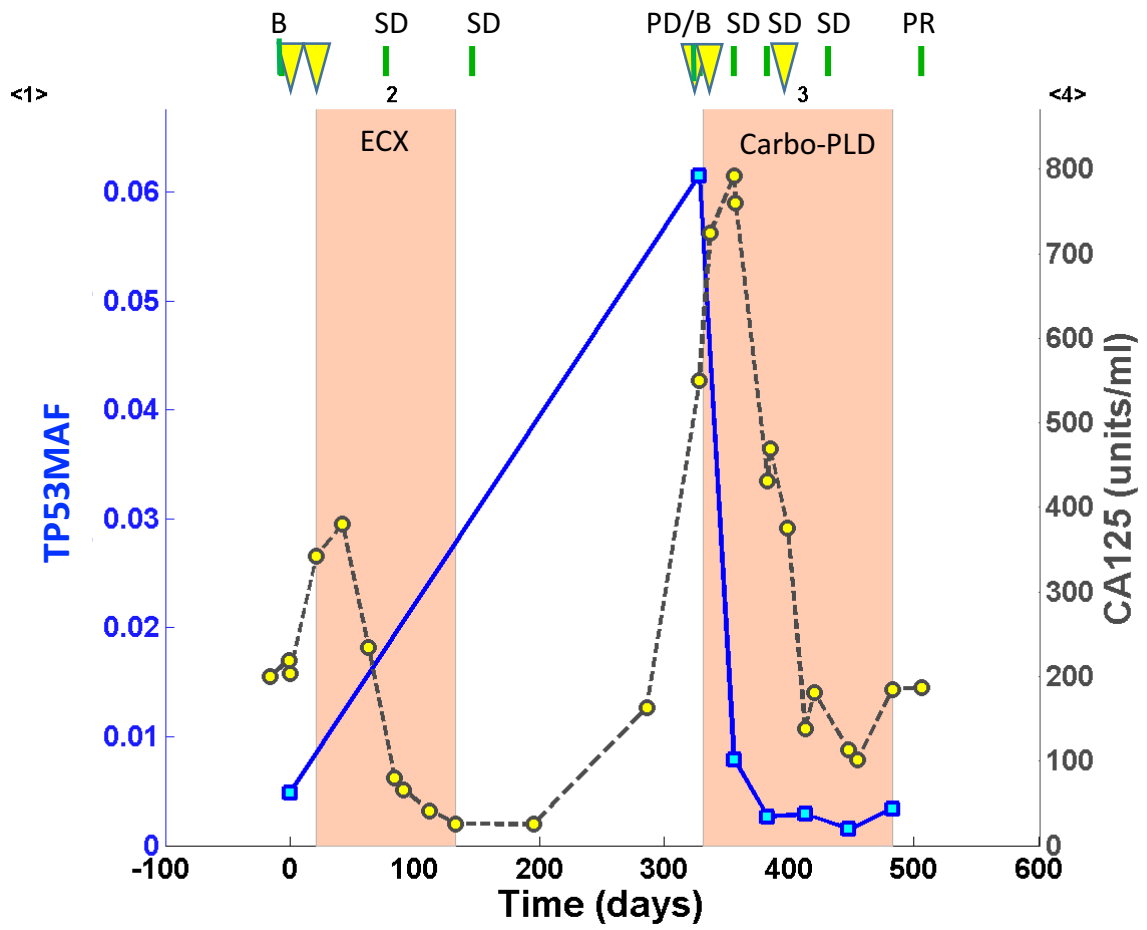
OV04-33



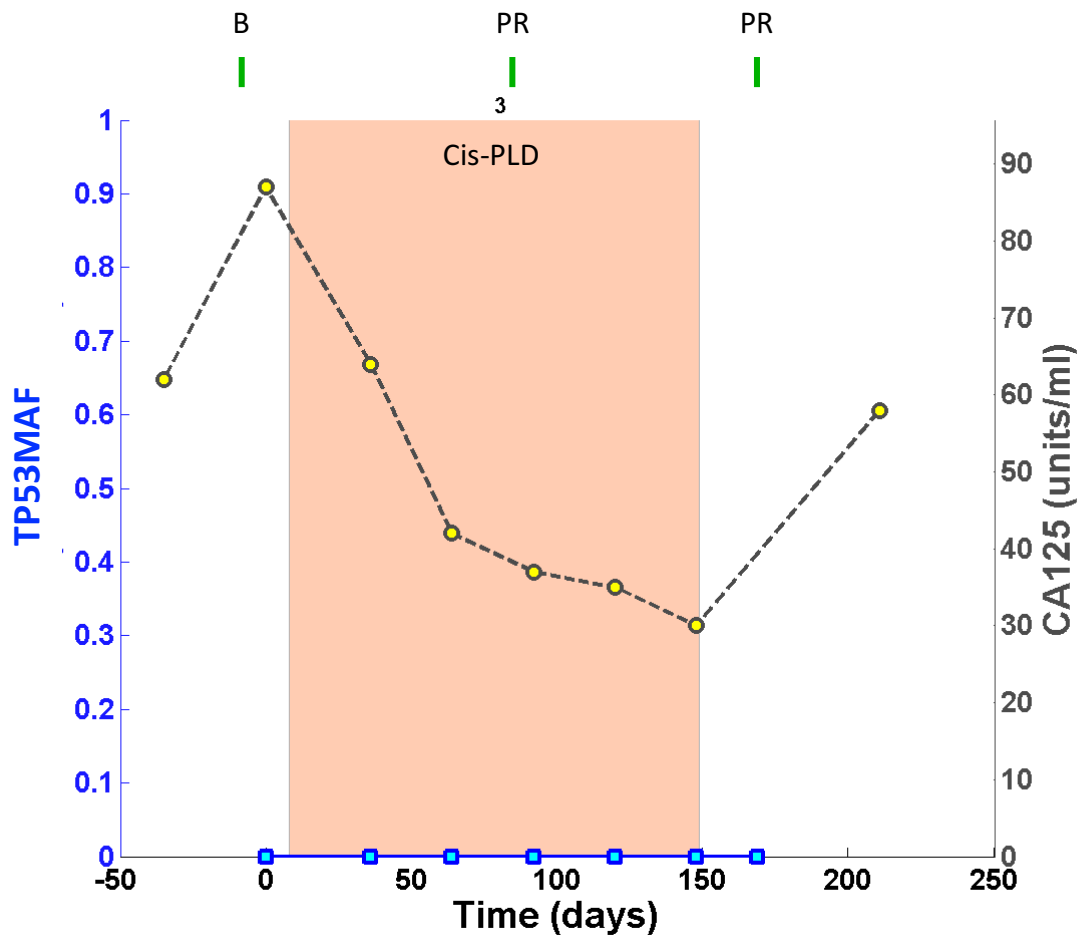
OV04-36

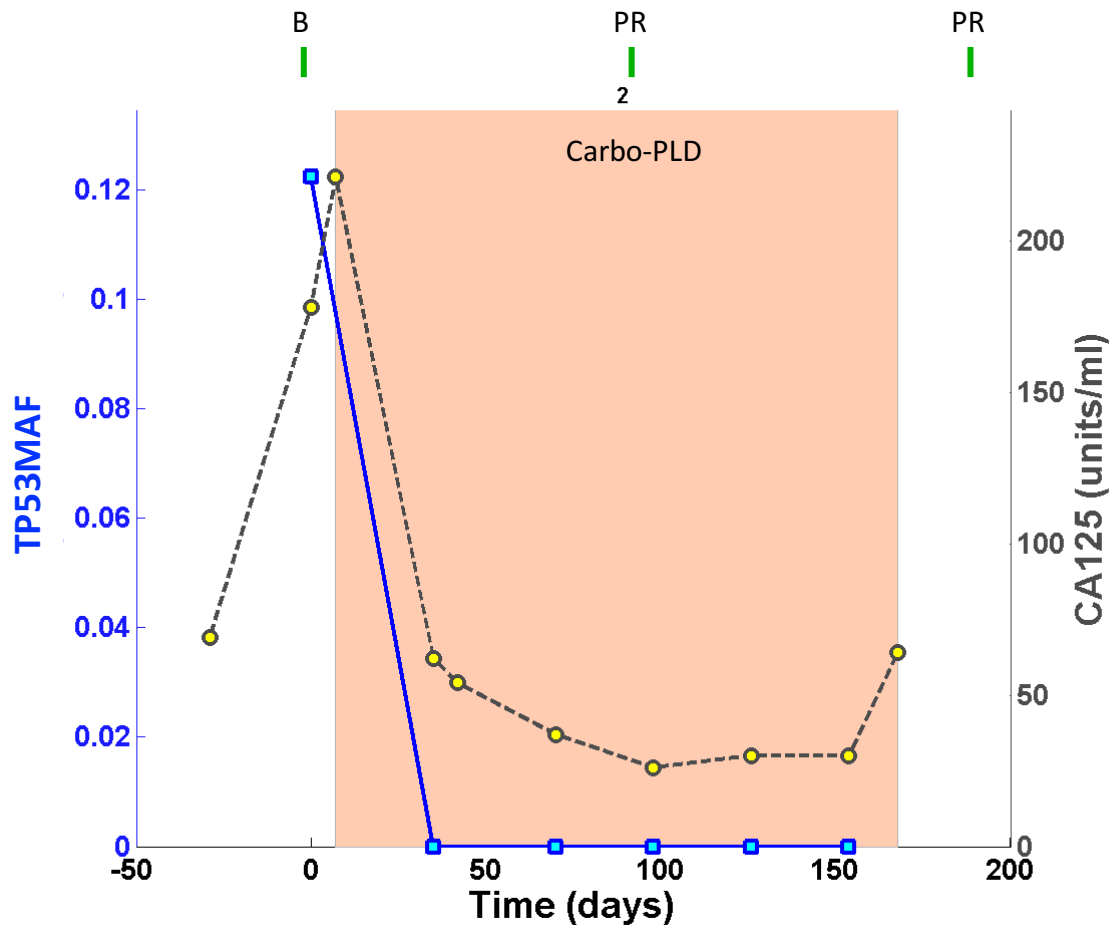


OV04-39

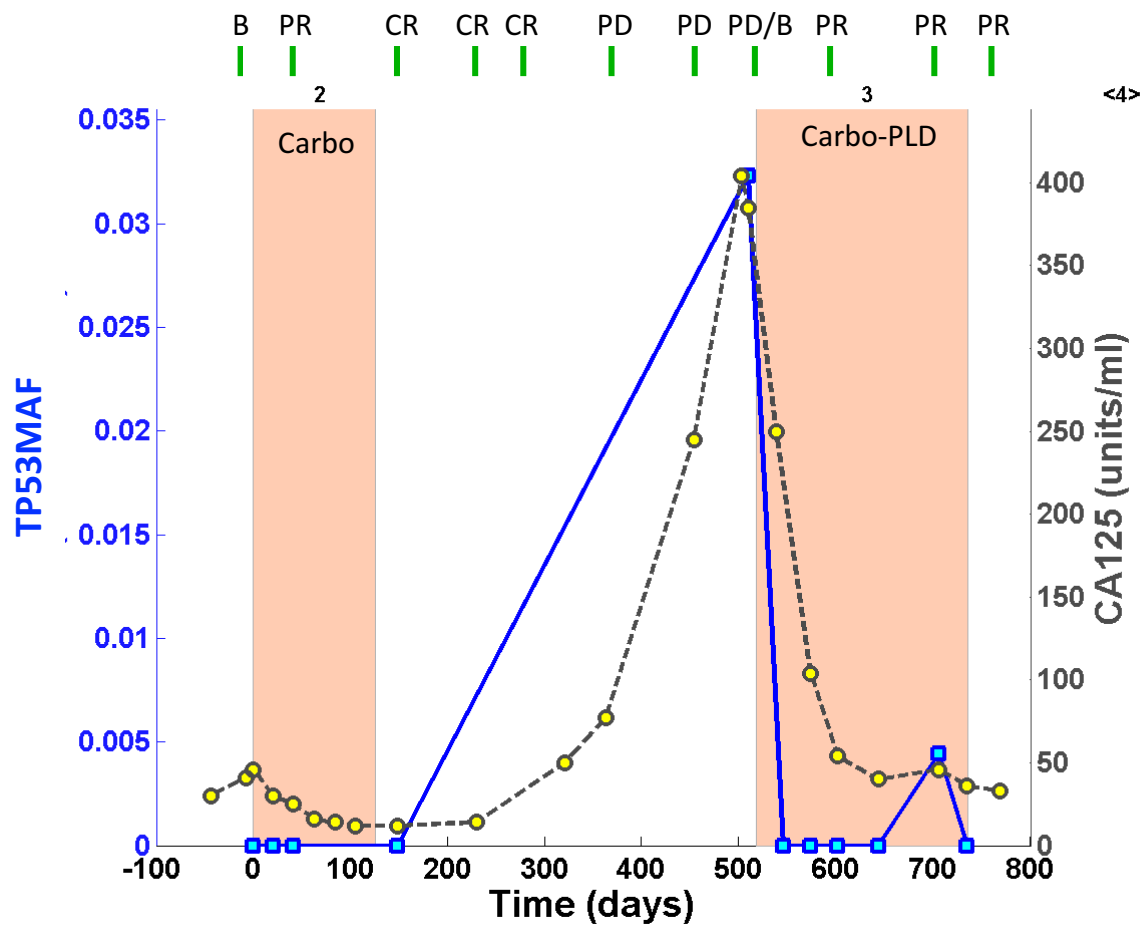


OV04-47

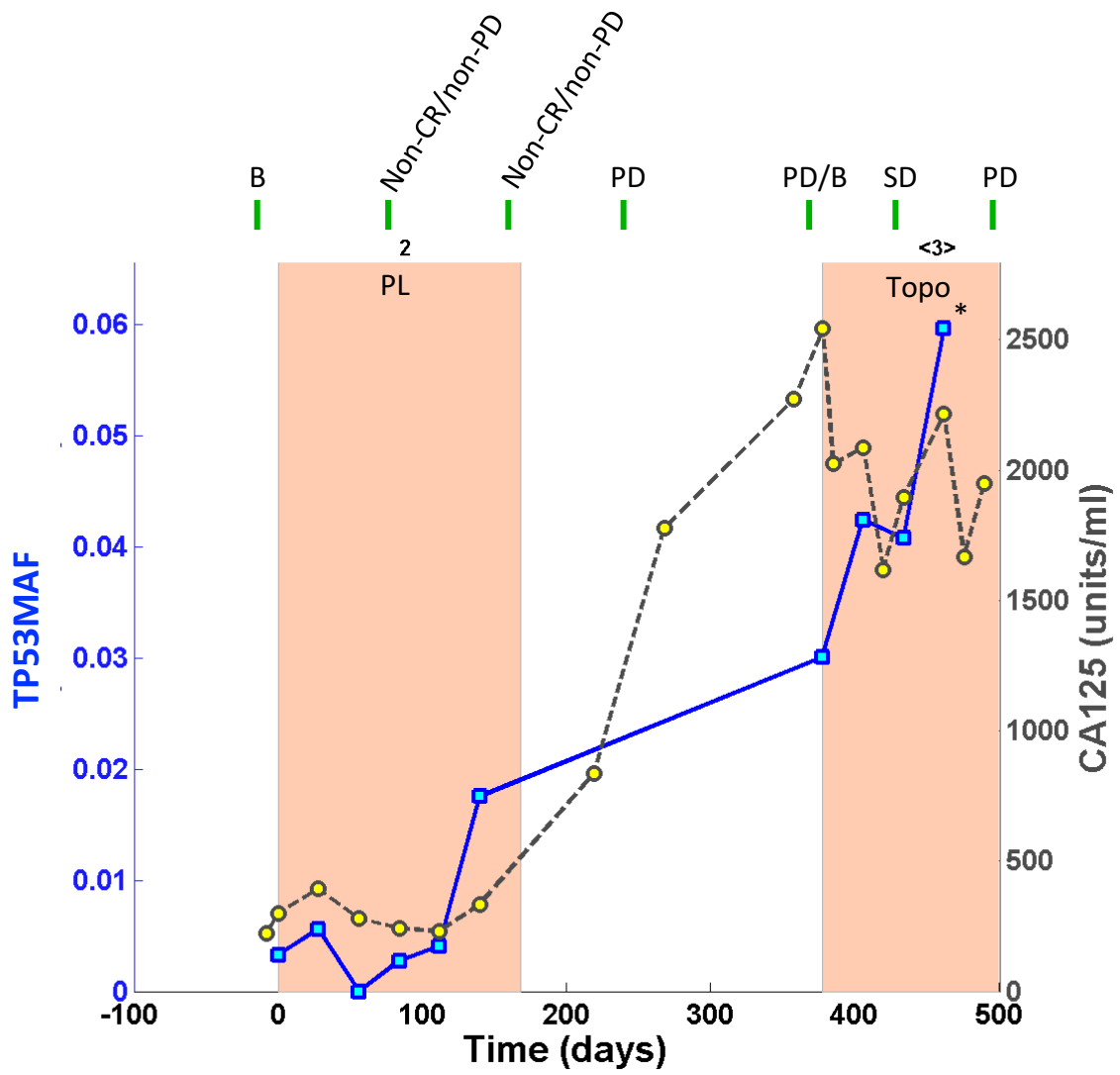




OV04-52

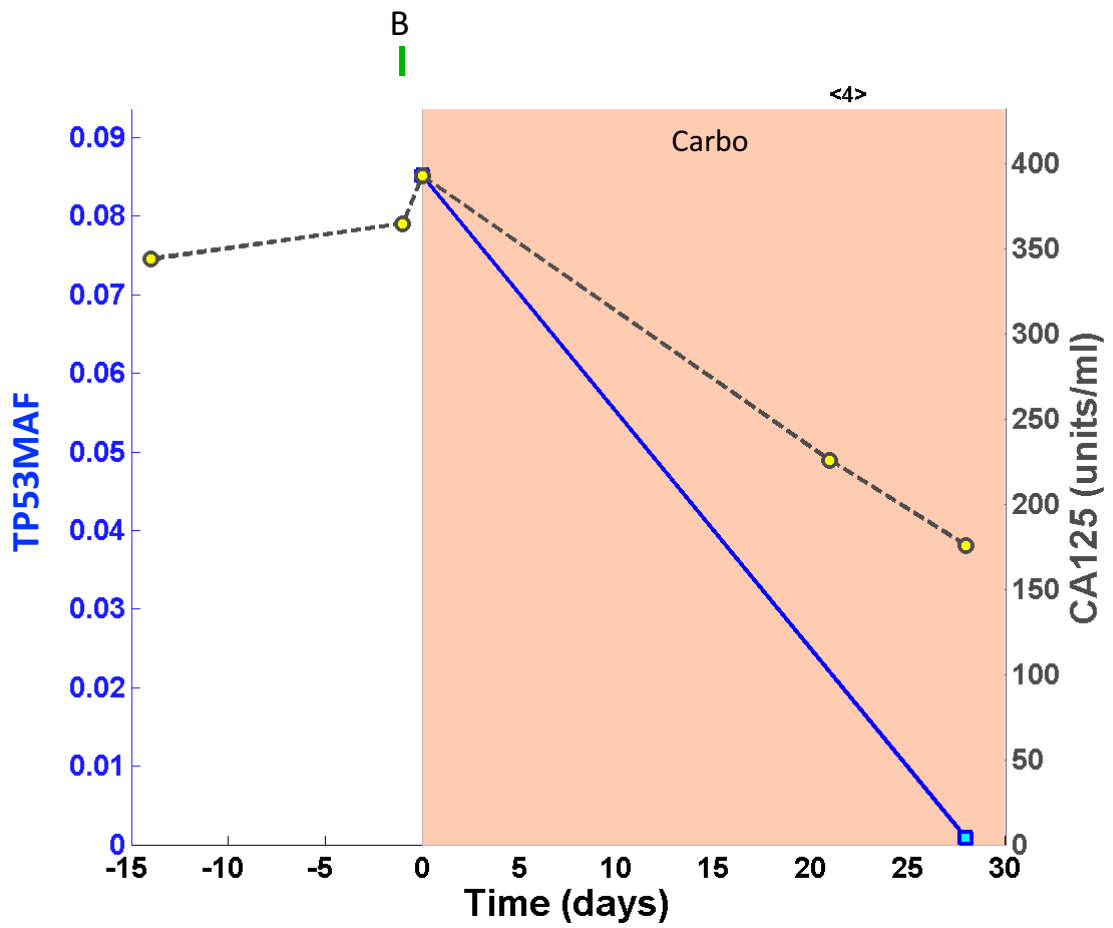


OV04-57

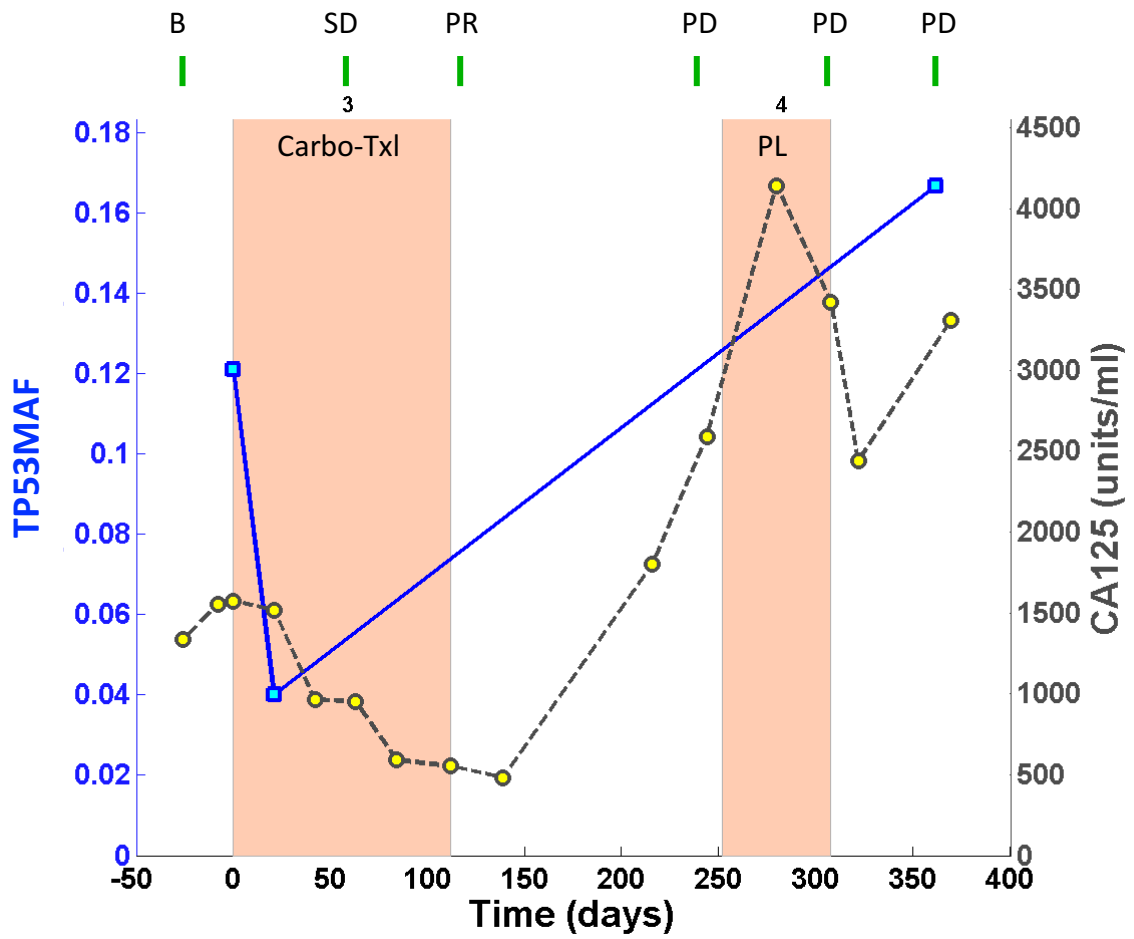


*new onset of headaches. CT shows new brain metastases (PD)

OV04-63

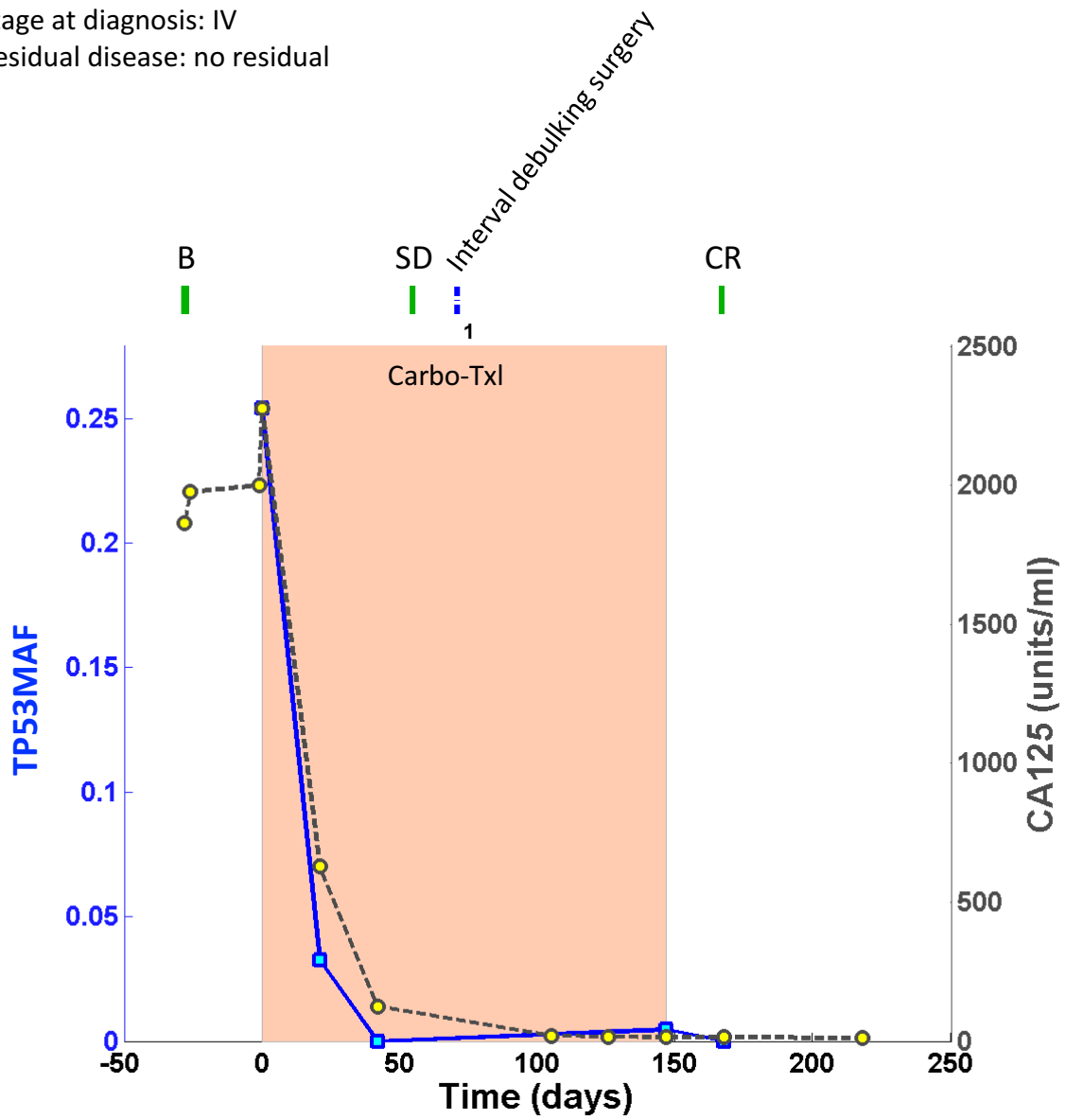


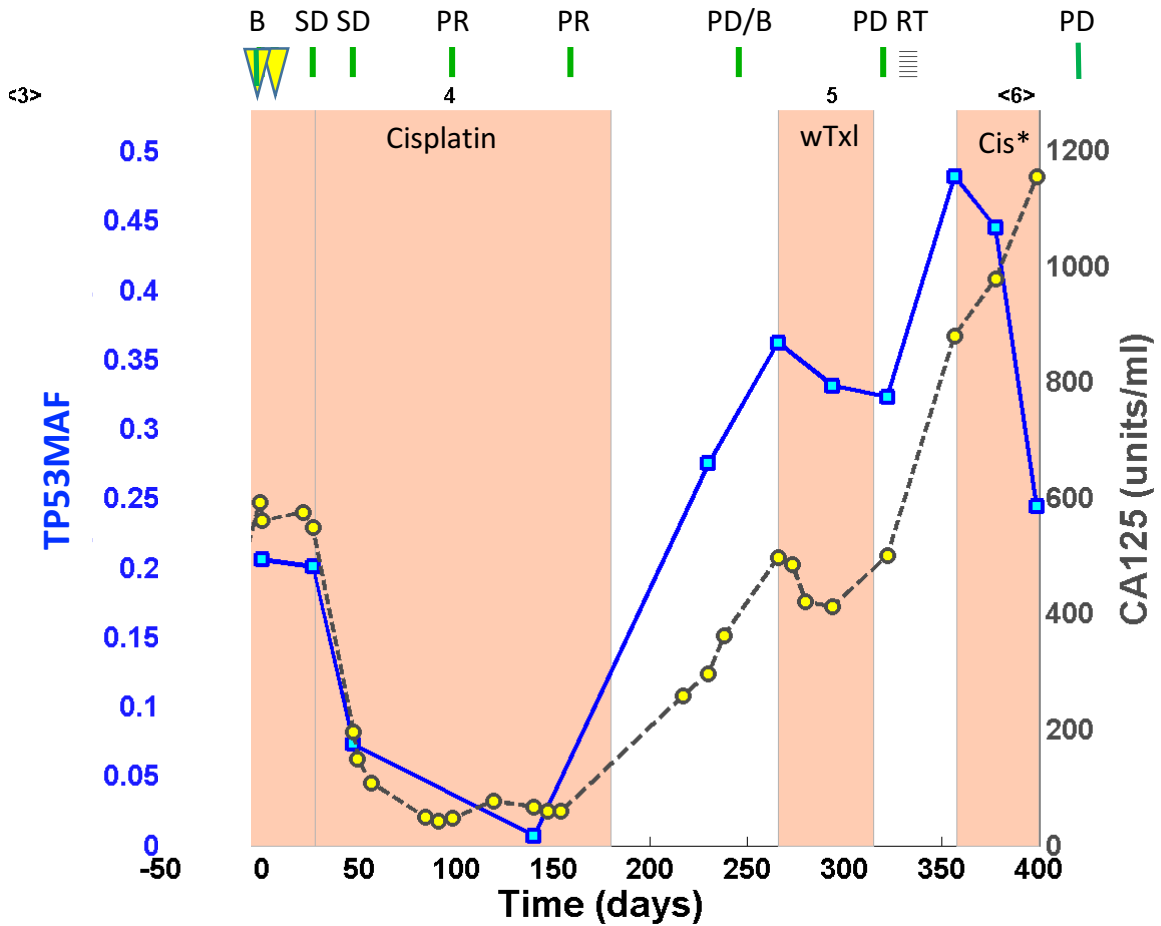
OV04-64



OV04-65

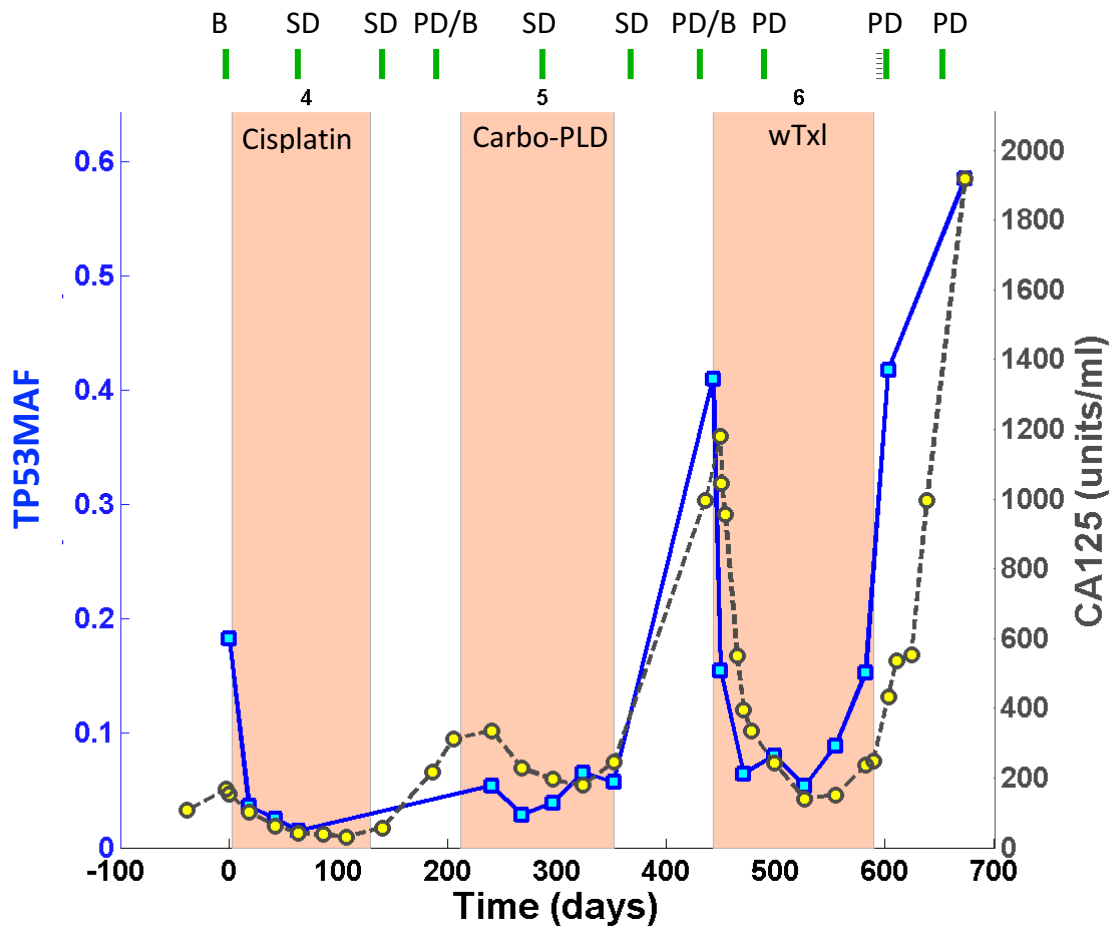
Stage at diagnosis: IV
Residual disease: no residual





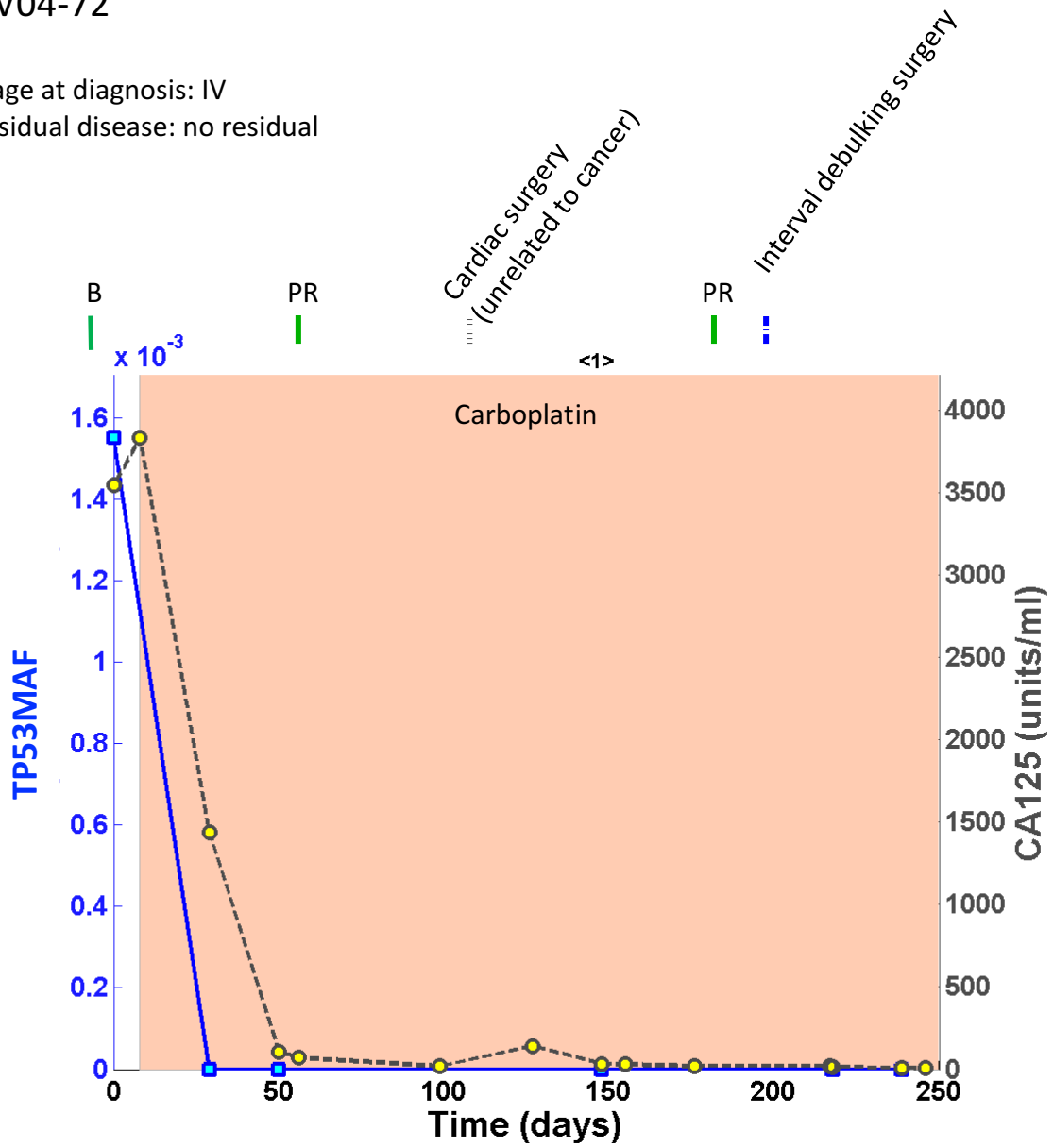
*This patient had discordant ctDNA and CA-125 on her 6th course of treatment. She stopped chemotherapy permanently after 2 cycles of cisplatin, since her CT scan showed progression and her CA-125 was rising (thought ctDNA falling). She was discharged from clinic with best supportive care. She went on to live 238 days (7 months) without any further treatment, indicating that the fall in ctDNA may have been a better predictor of outcome than the CT or CA-125. Of note her pre-treatment CT scan was 5 weeks before the start of treatment, and therefore the re-assessment CT scan carried out 8 weeks after the first cycle of chemotherapy could have overestimated progression on treatment.

OV04-70



OV04-72

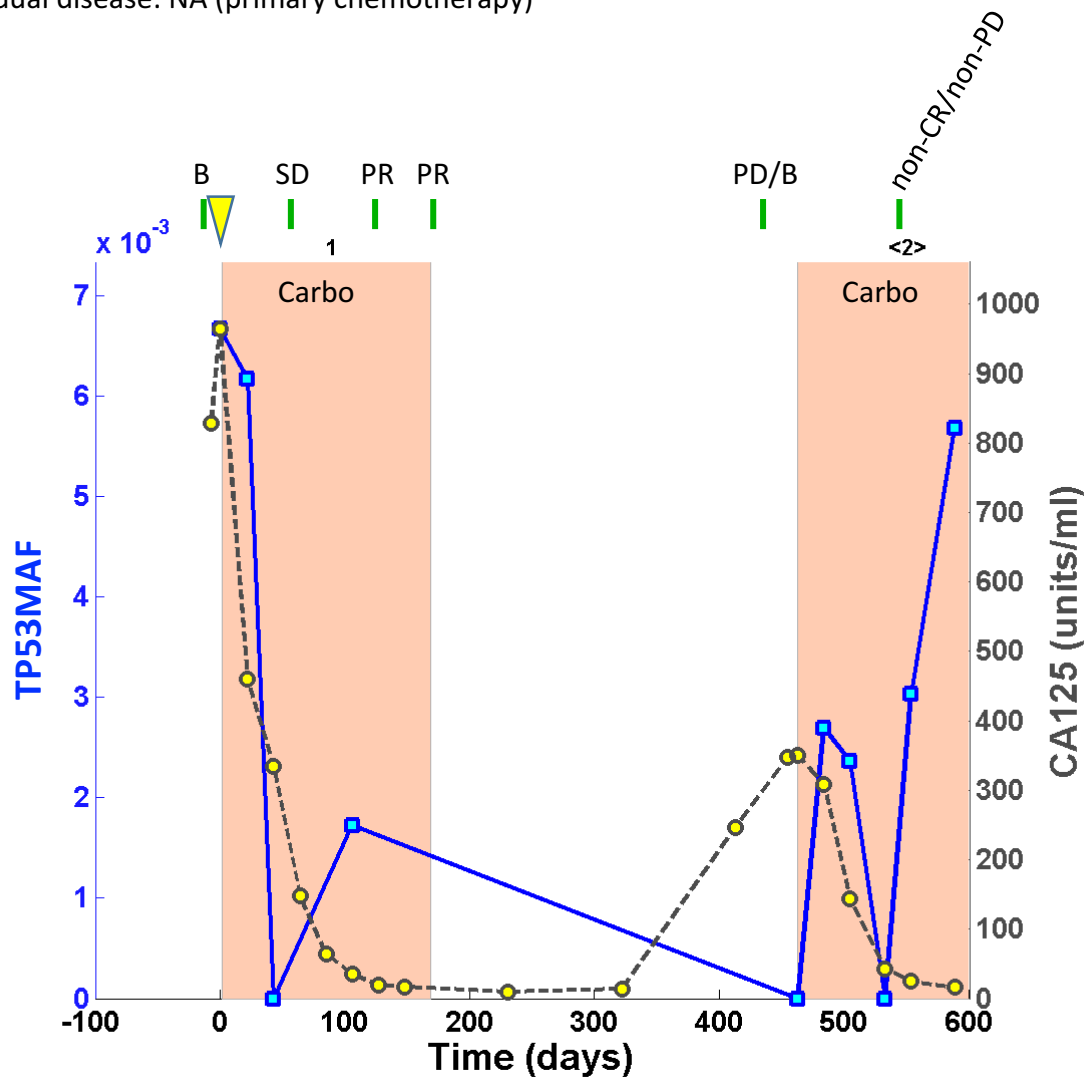
Stage at diagnosis: IV
Residual disease: no residual



OV04-73

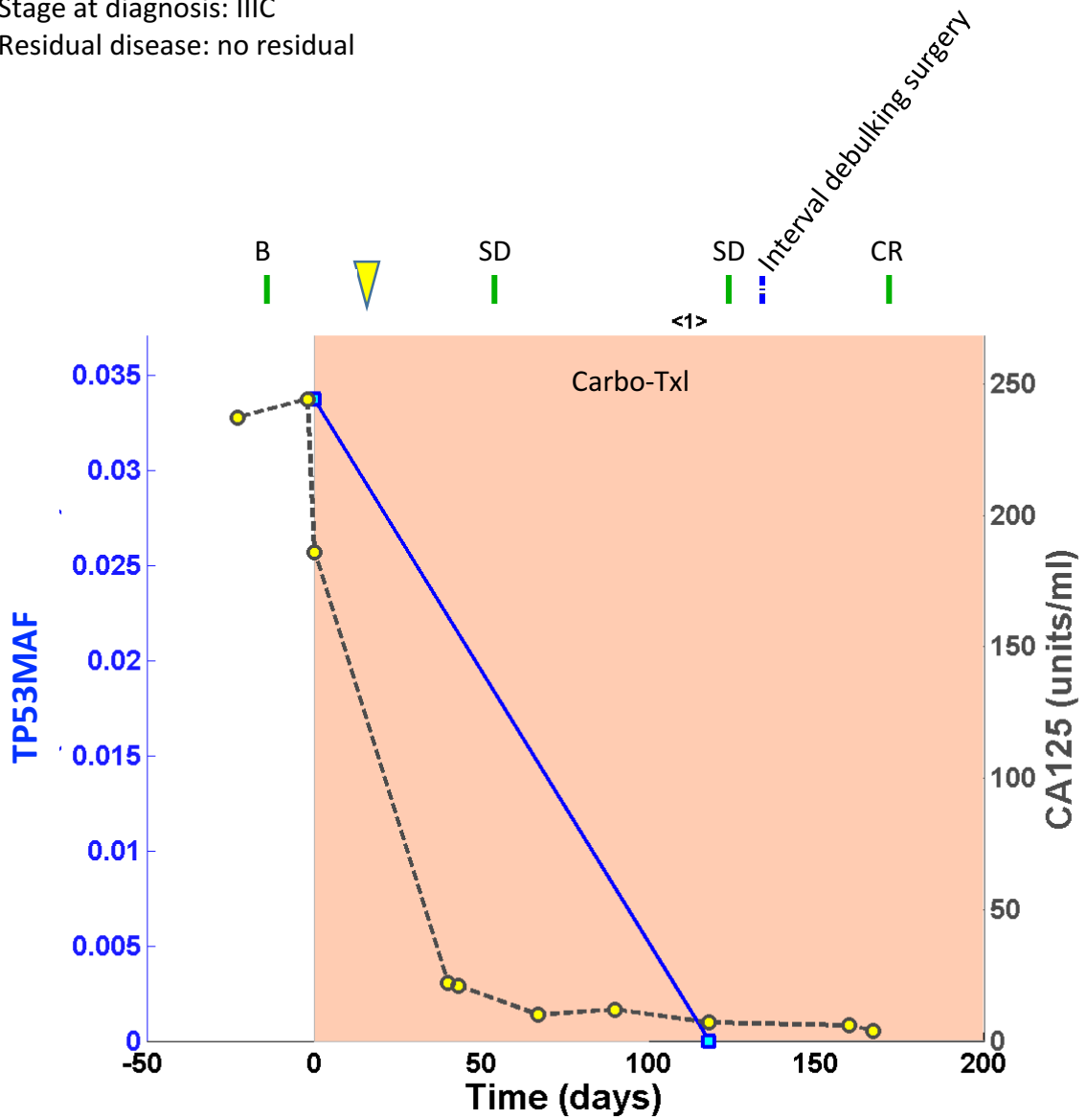
Stage at diagnosis: IIIC

Residual disease: NA (primary chemotherapy)



OV04-74

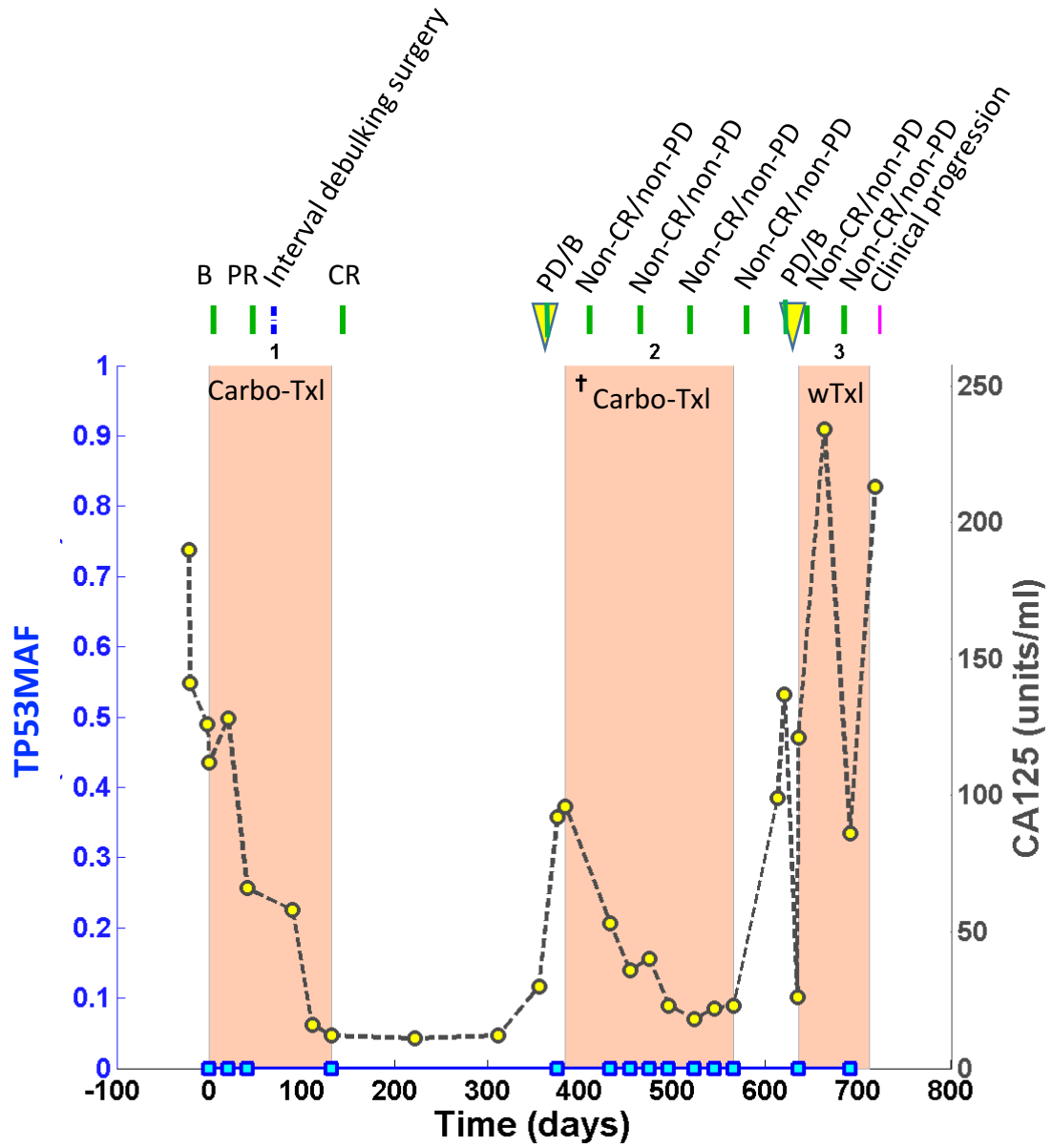
Stage at diagnosis: IIIC
Residual disease: no residual



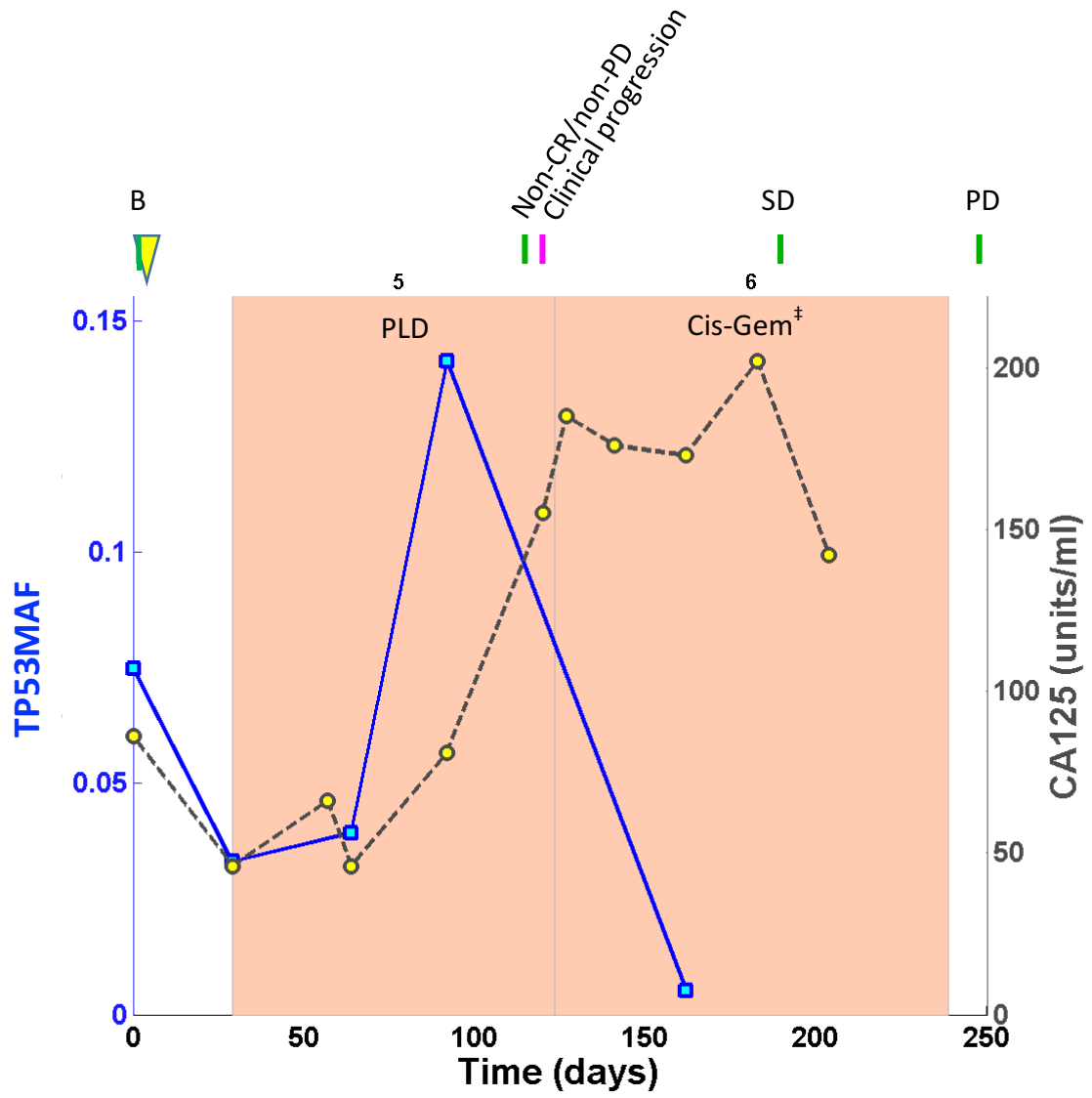
OV04-75

Stage at diagnosis: IIIC

Residual disease: no residual

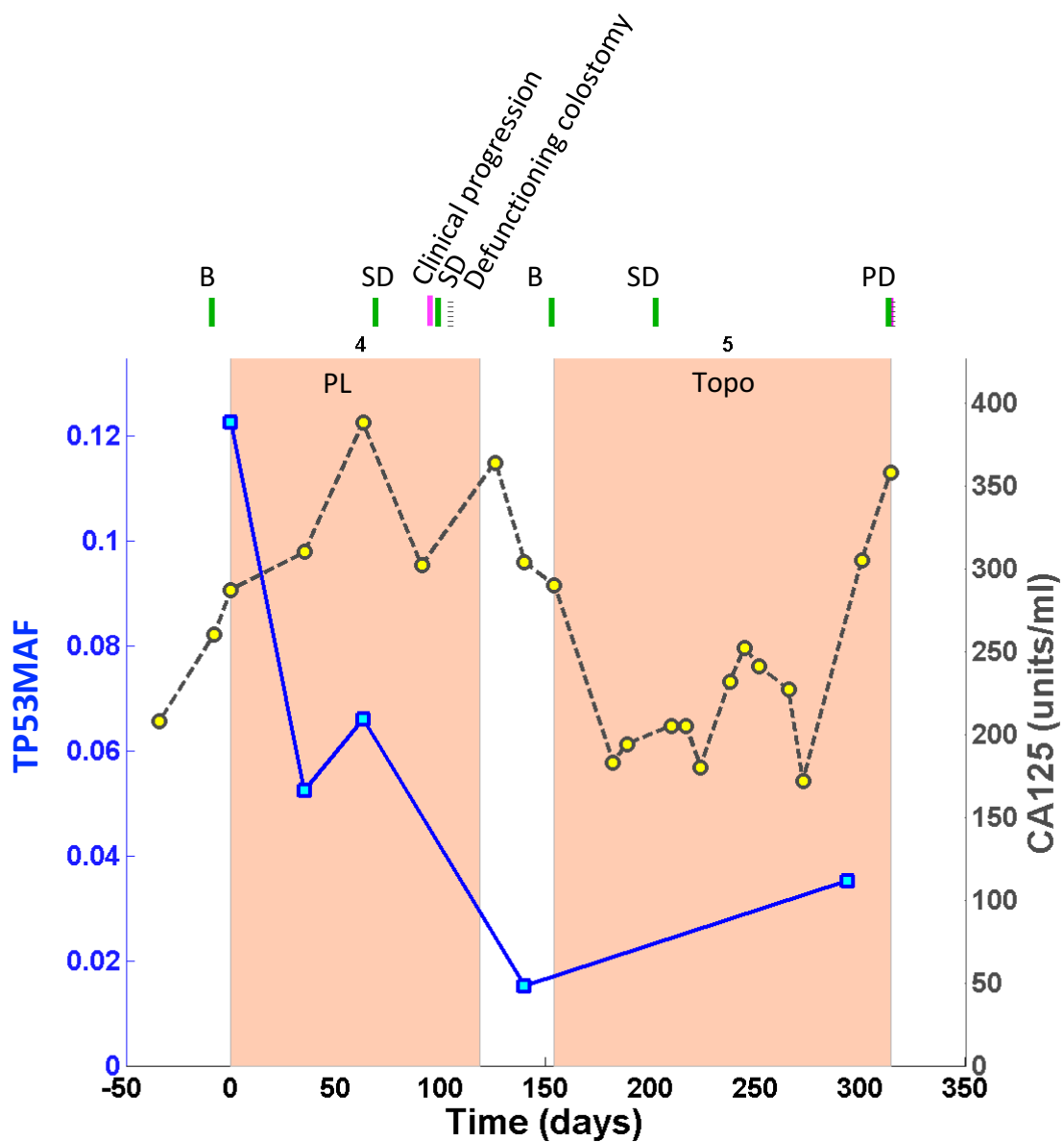


† 1st cycle with Cediranib/placebo on ICON6 trial (Cediranib/placebo stopped due to toxicity).



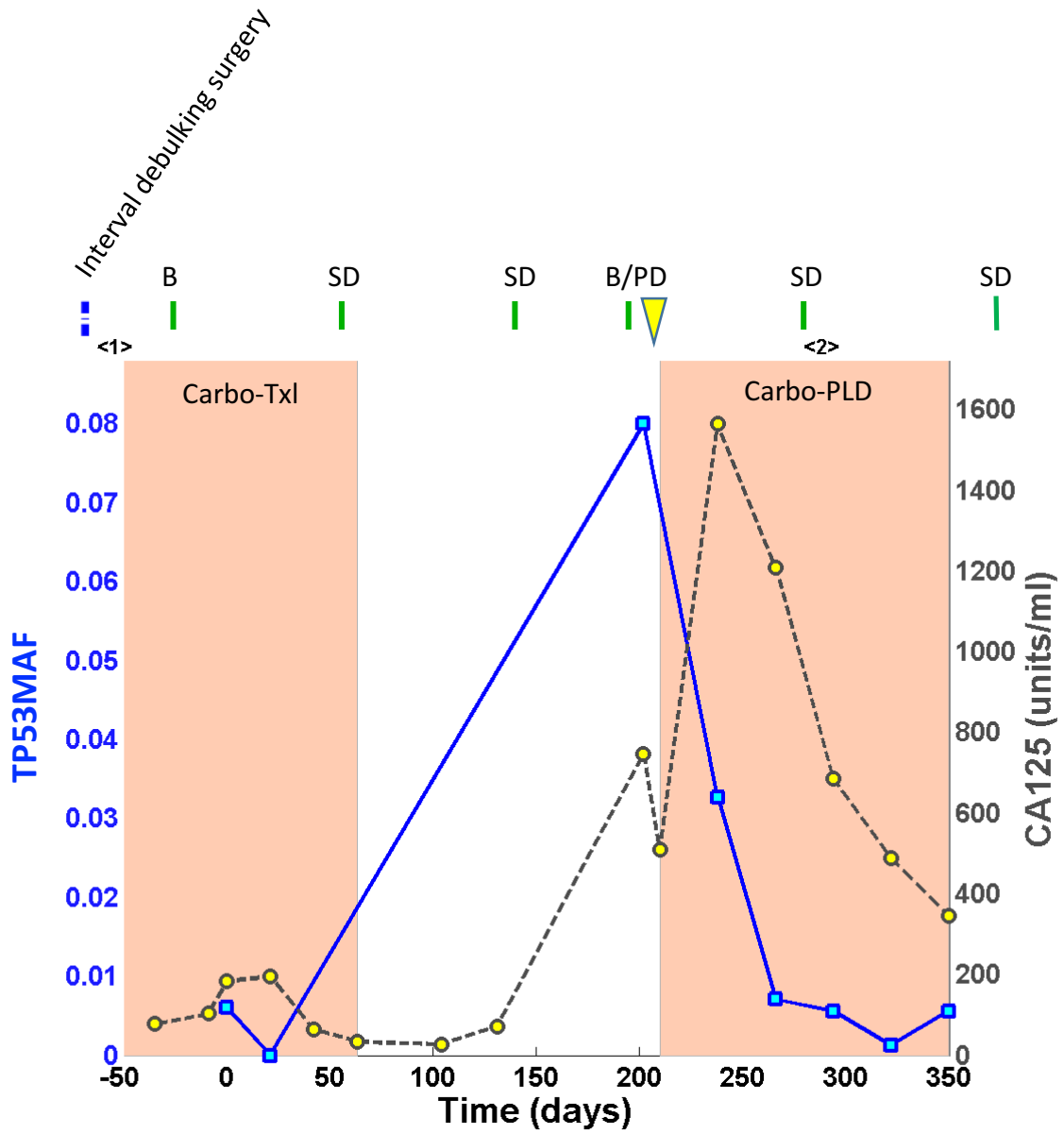
‡ Gemcitabine stopped for last 4 cycles (of total of 6 cycles)

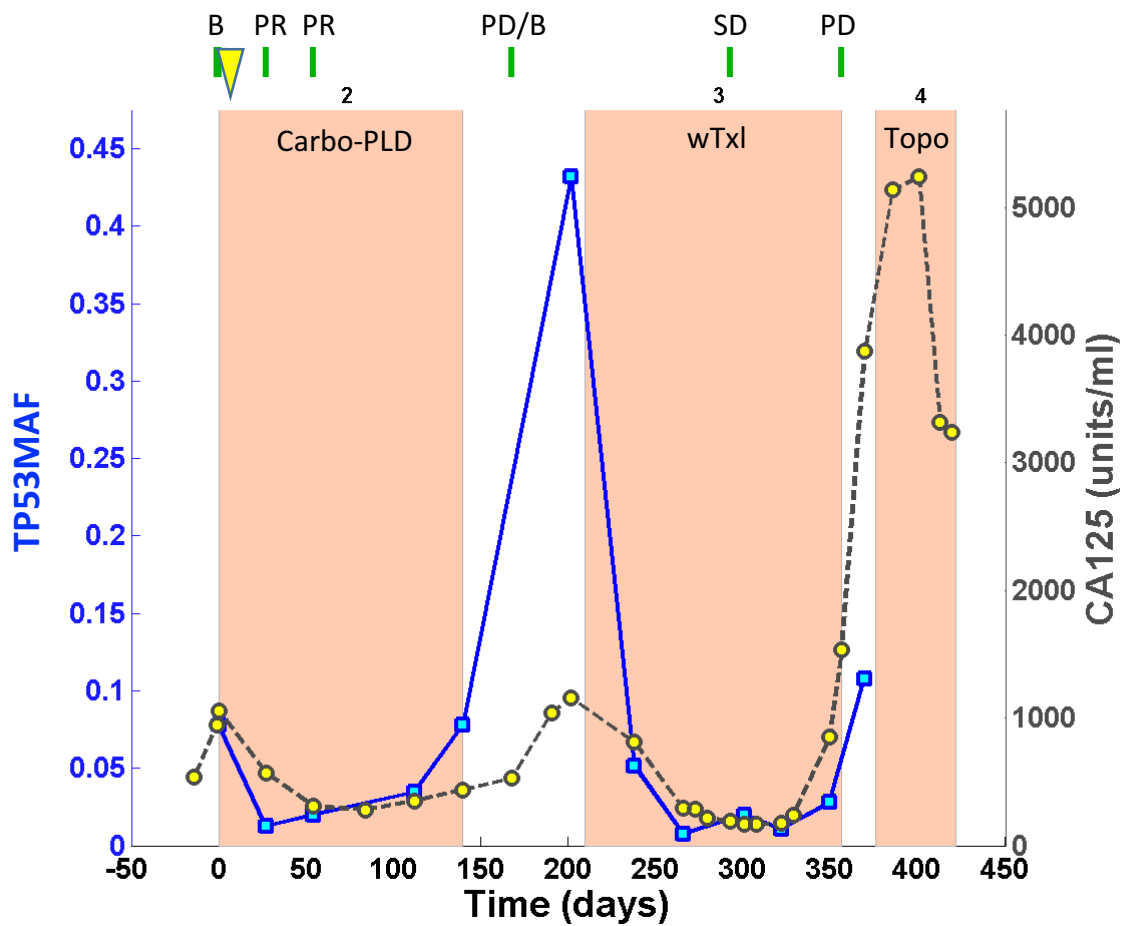
OV04-79



OV04-81

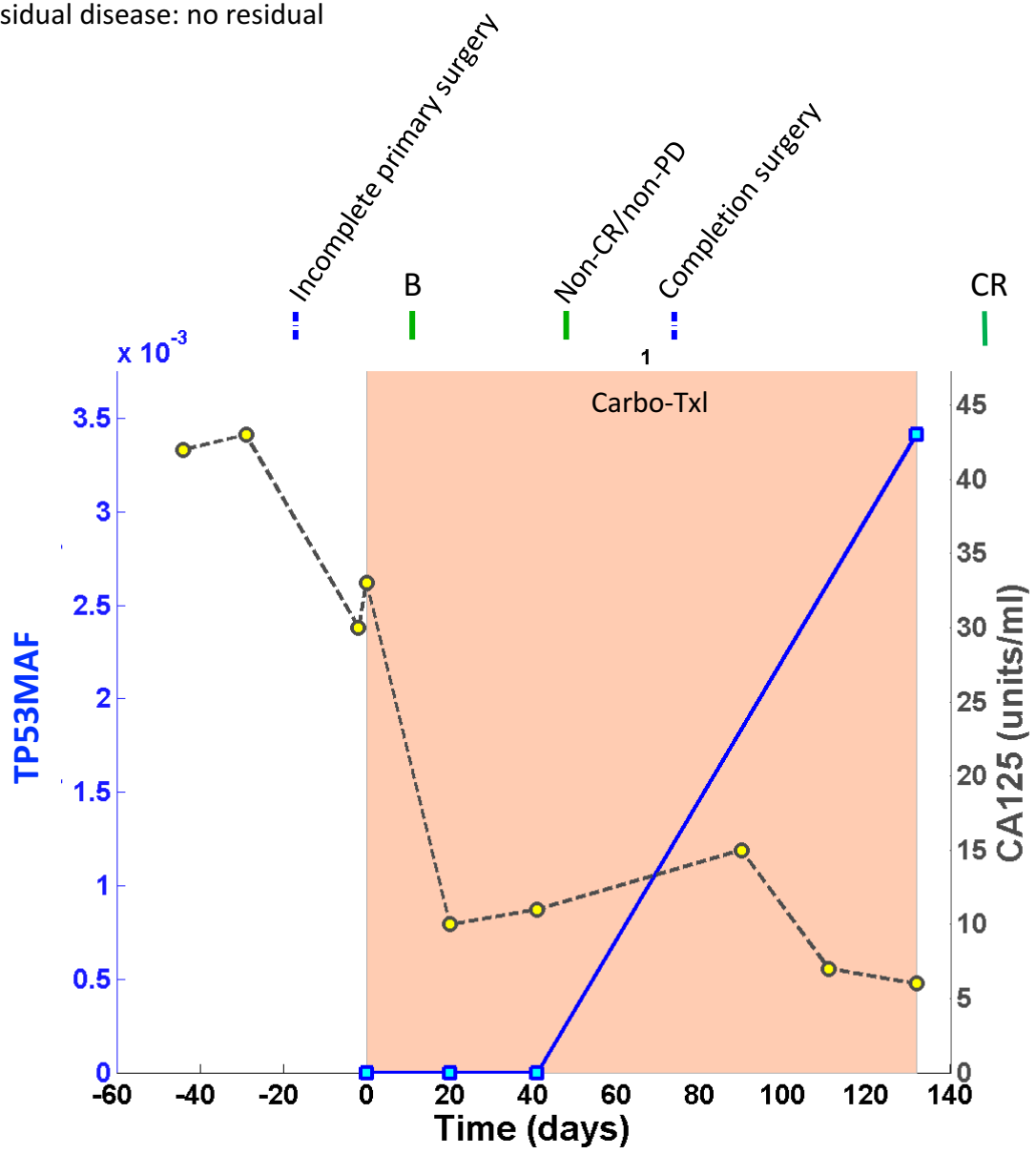
Stage at diagnosis: IIIC
Residual disease: >1 cm



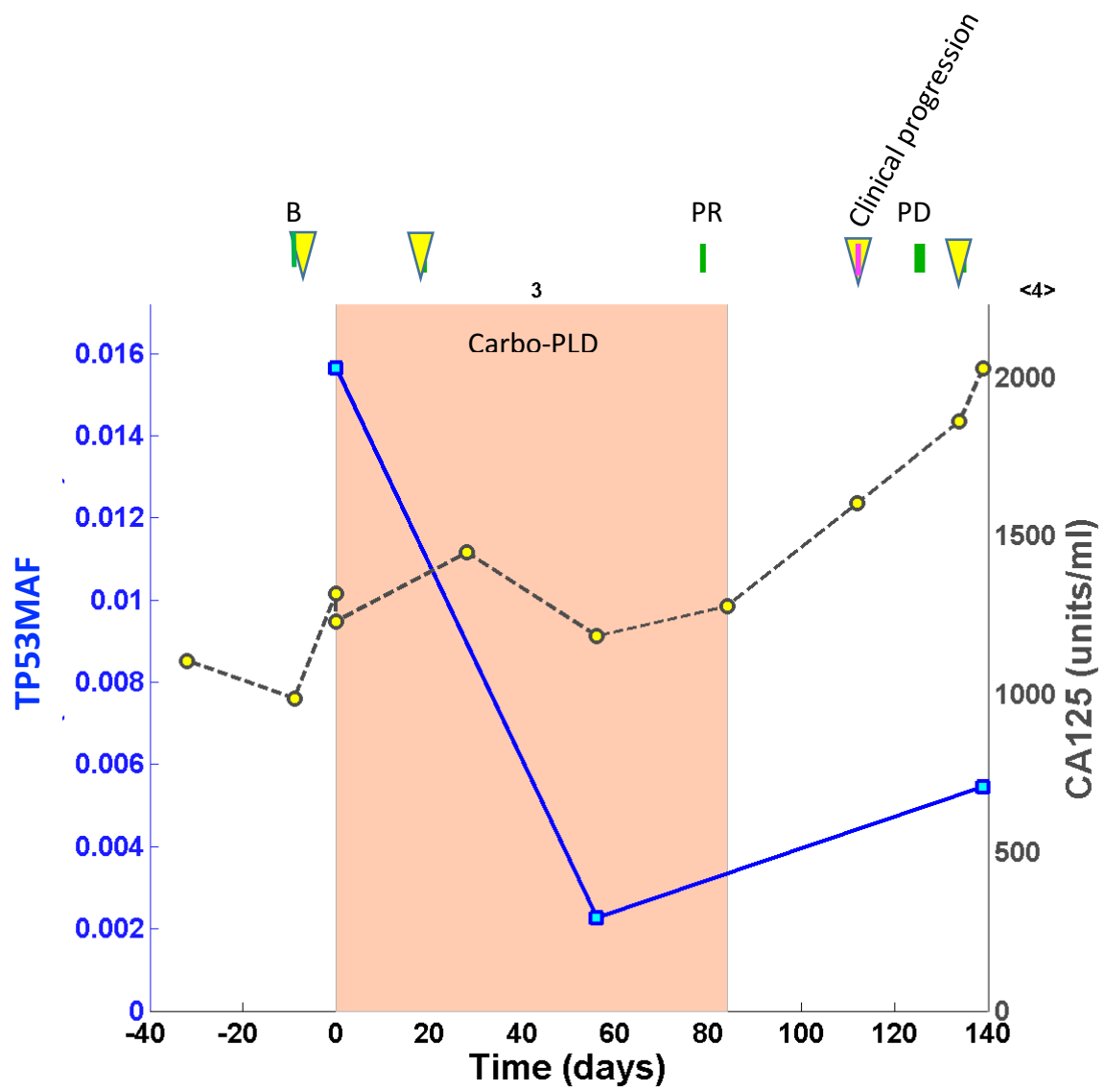


OV04-95

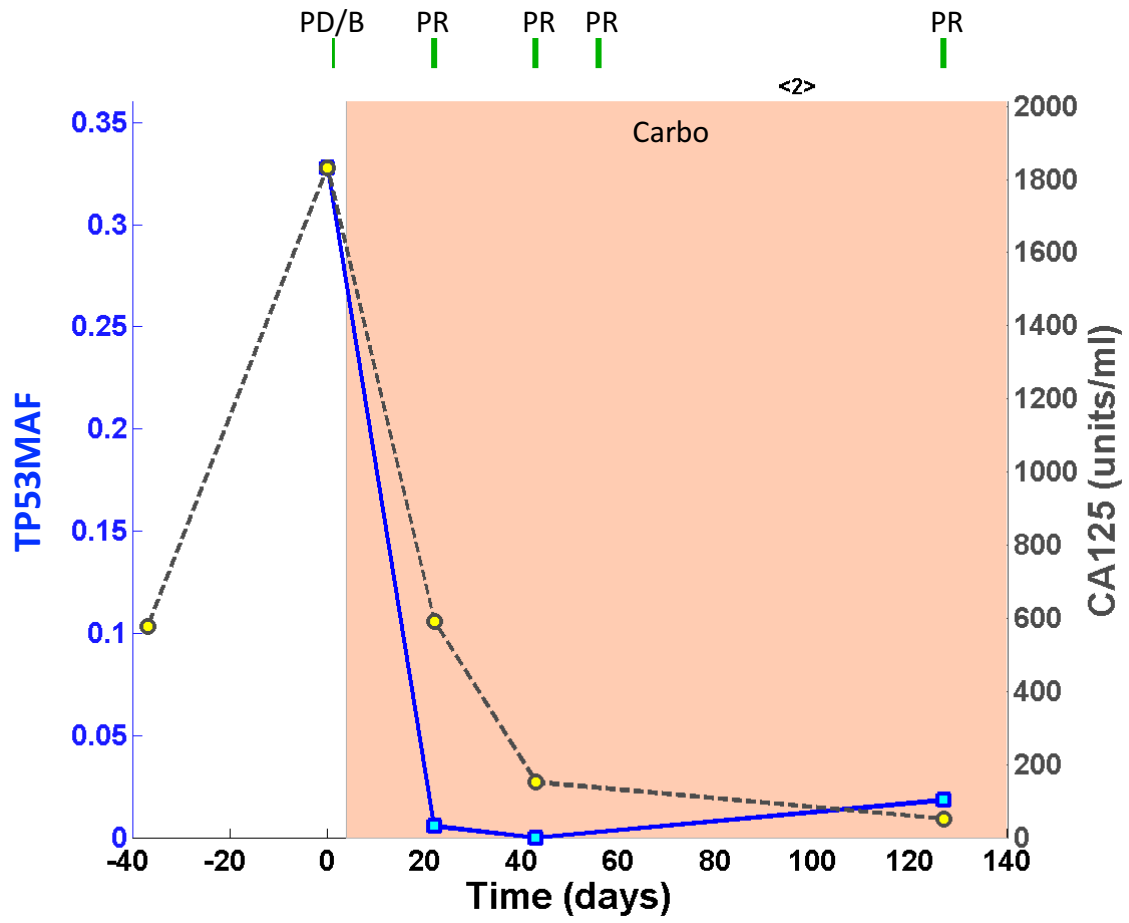
Stage at diagnosis: IC
Residual disease: no residual

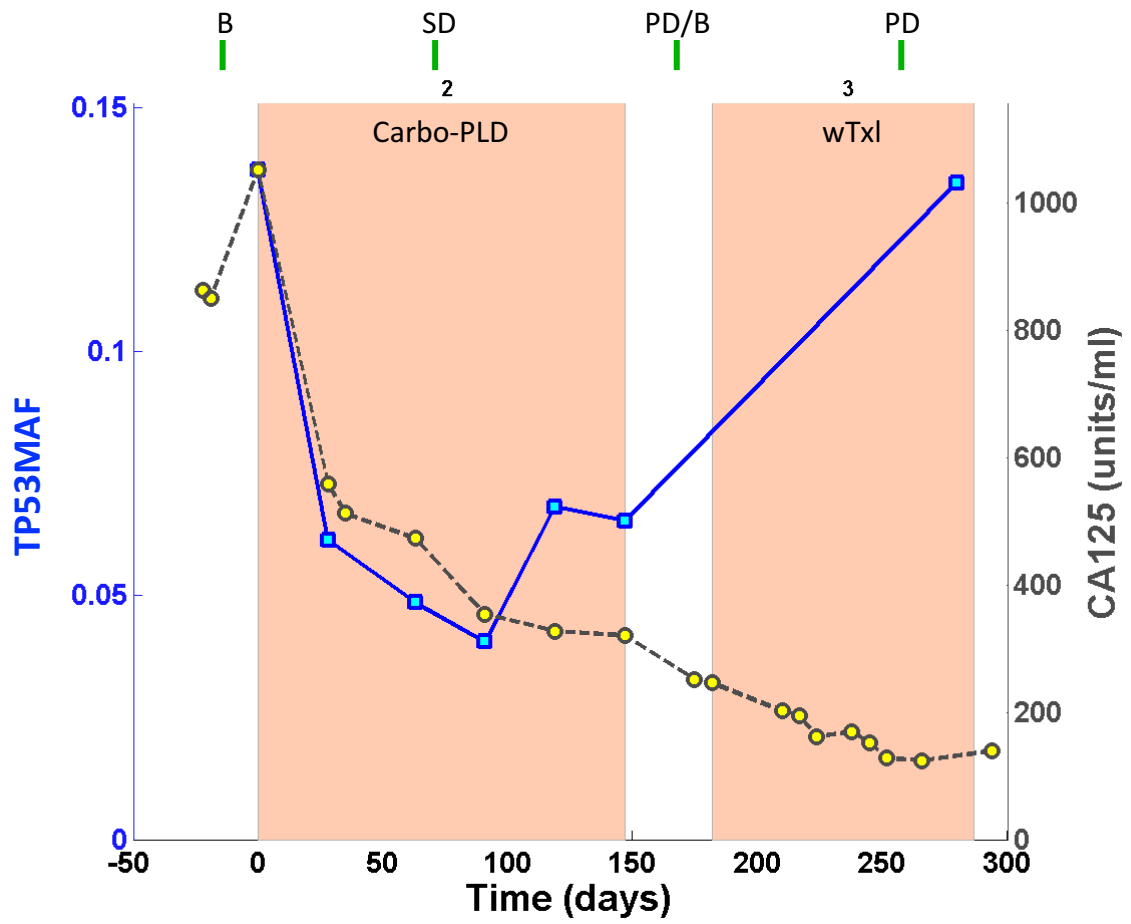


OV04-97



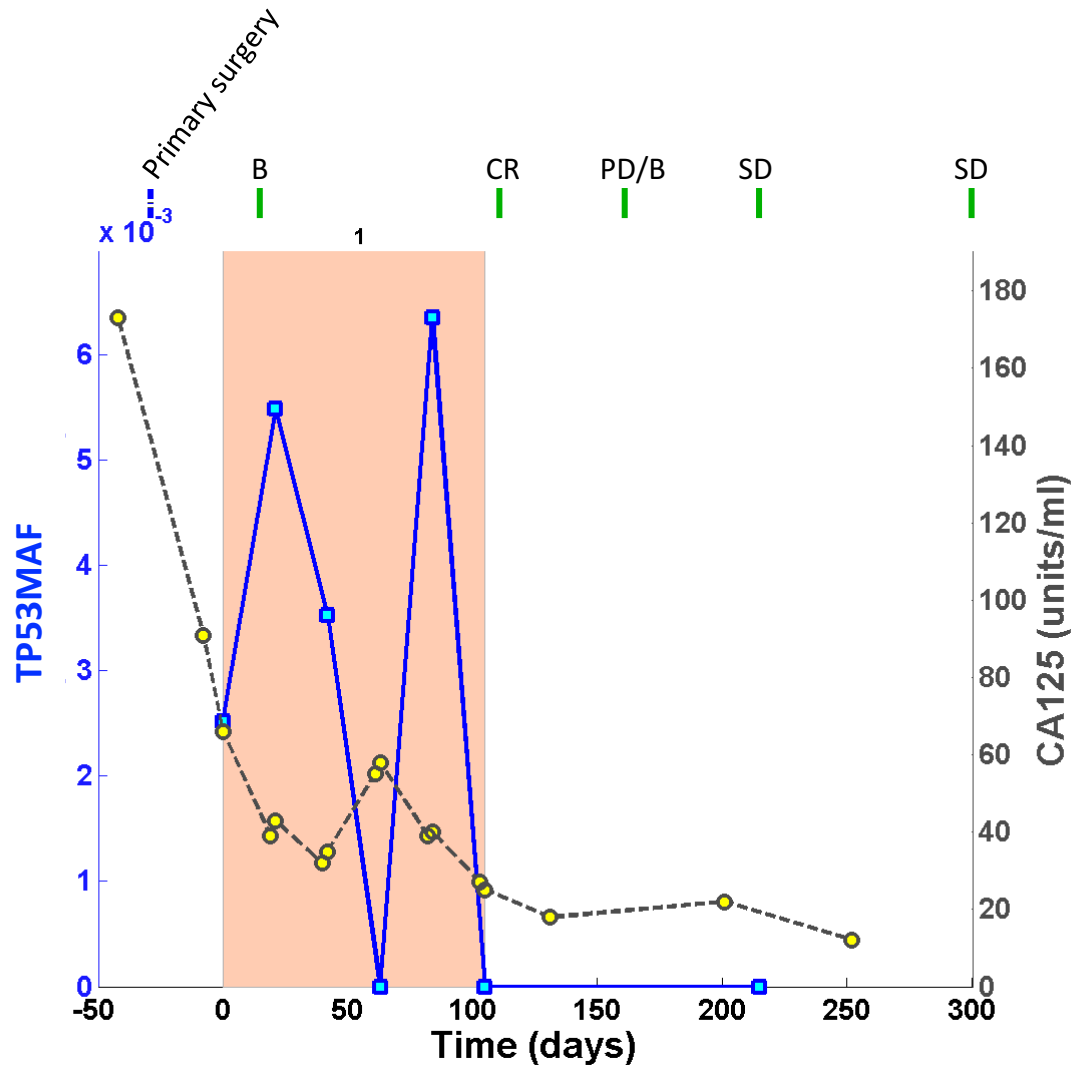
OV04-98

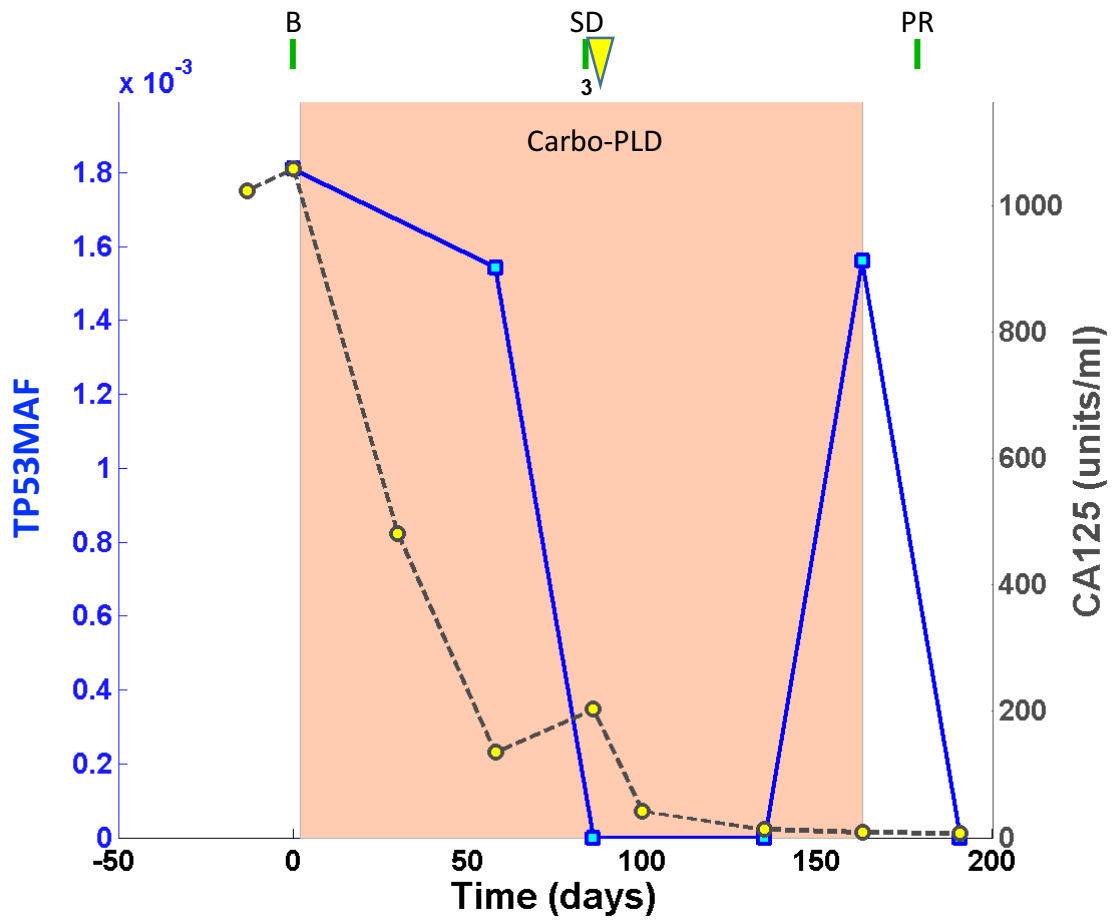


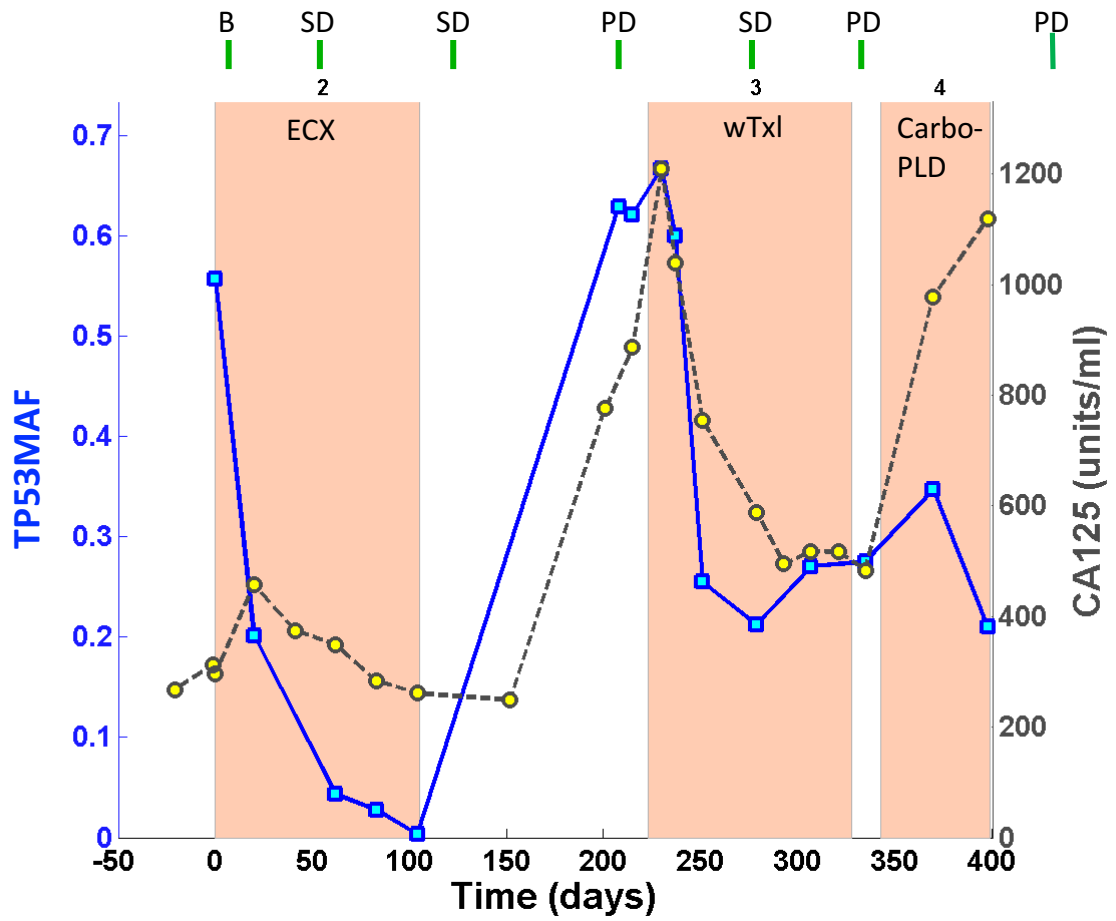


OV04-105

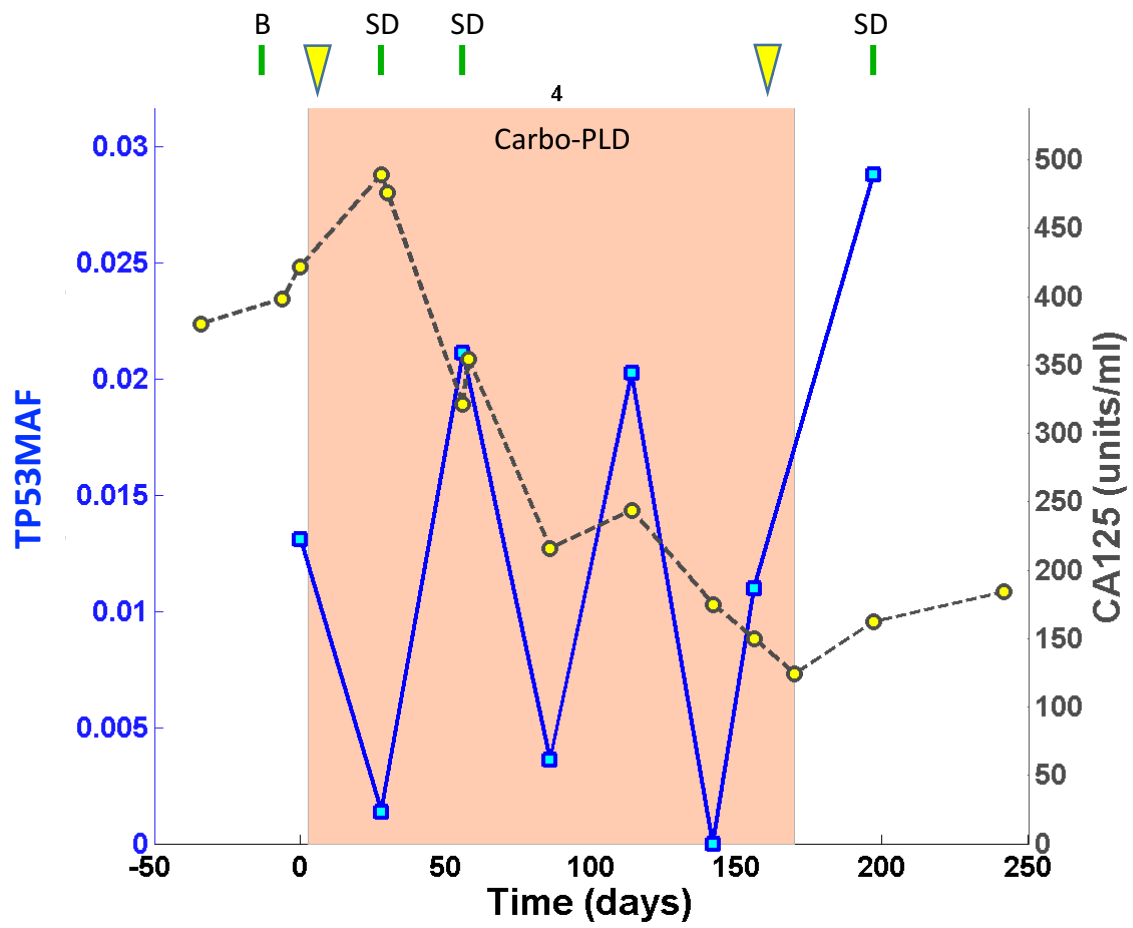
Stage at diagnosis: IIIC
Residual disease: >1 cm





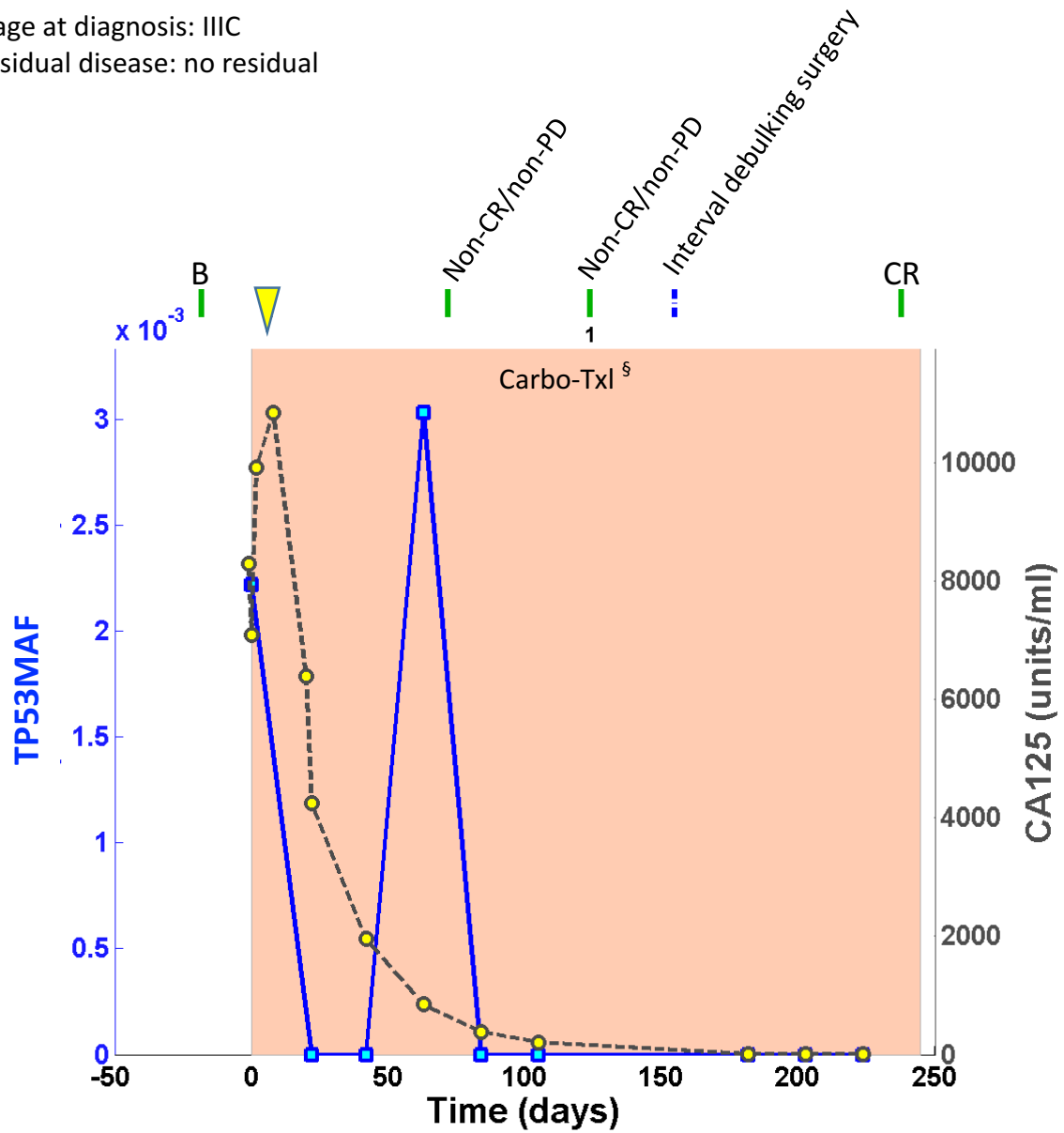


OV04-116

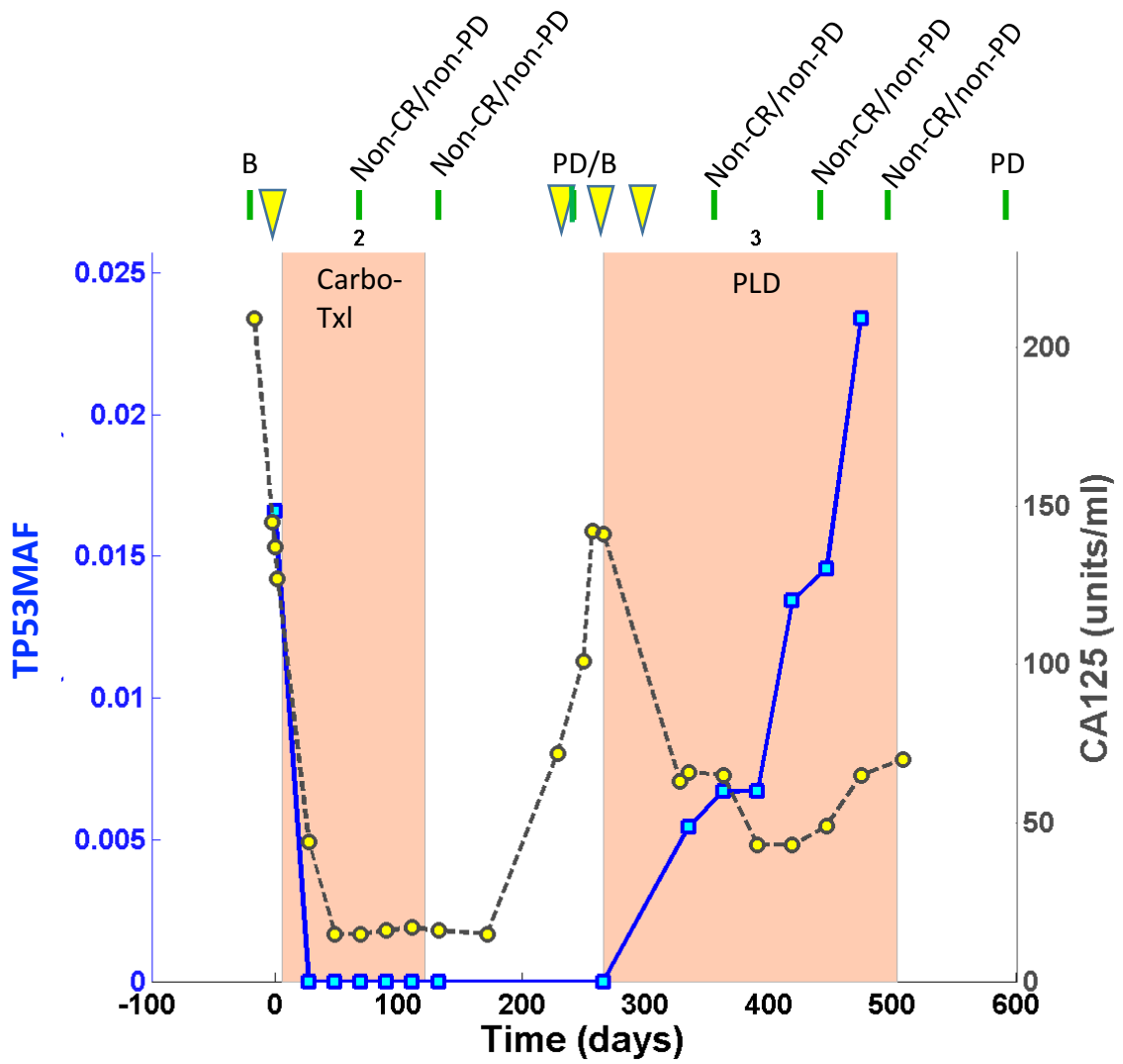


OV04-127

Stage at diagnosis: IIIC
Residual disease: no residual

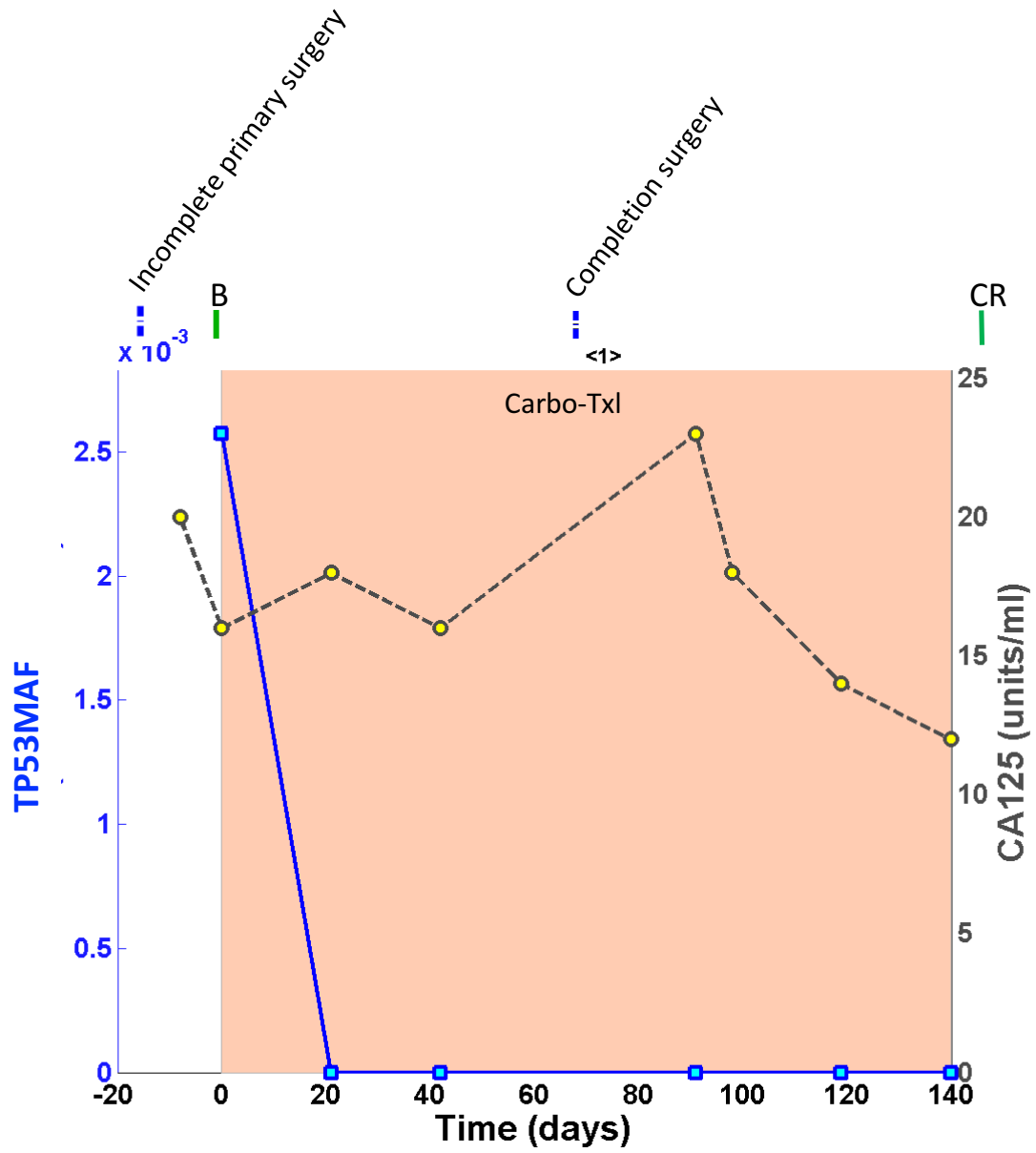


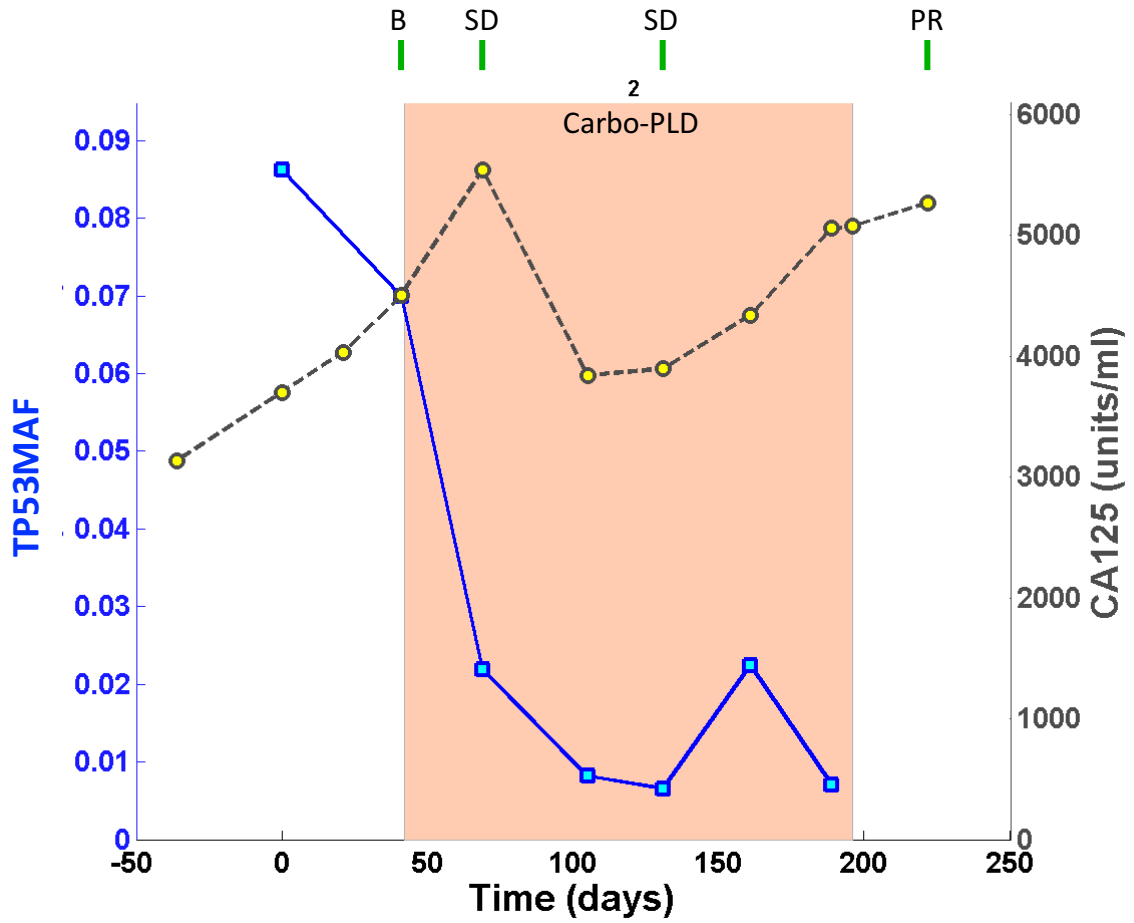
§ 1st 4 cycles carboplatin, last 5 cycles carboplatin and paclitaxel



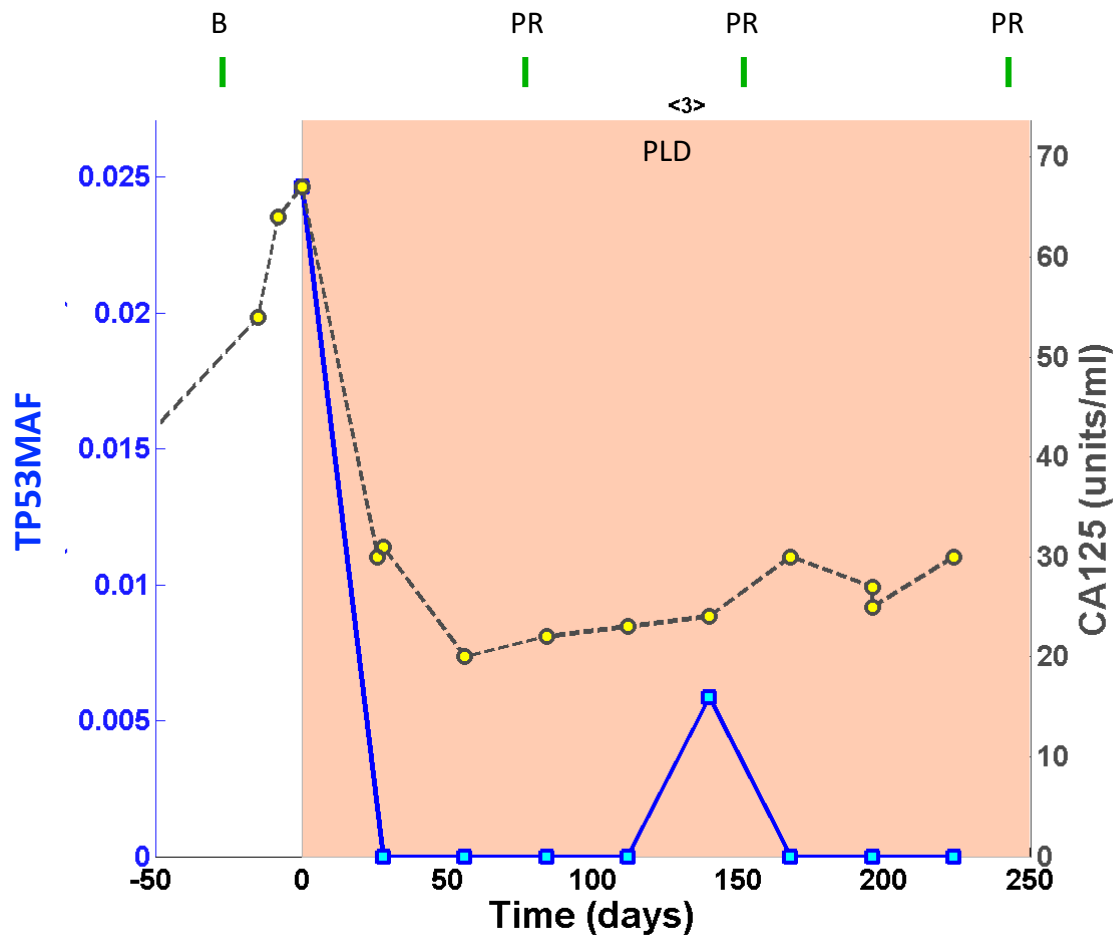
OV04-133

Stage at diagnosis: IC
Residual disease: no residual



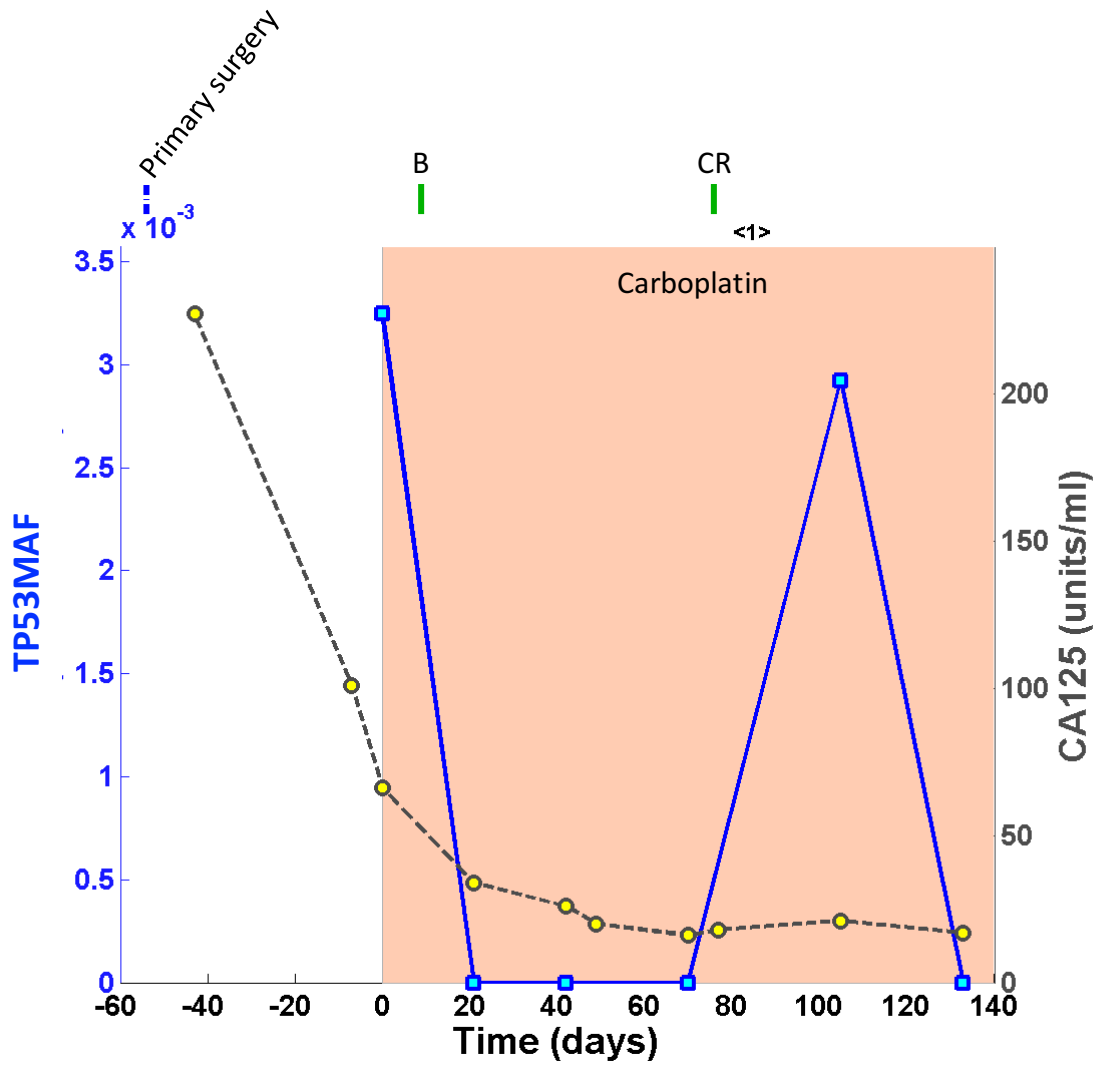


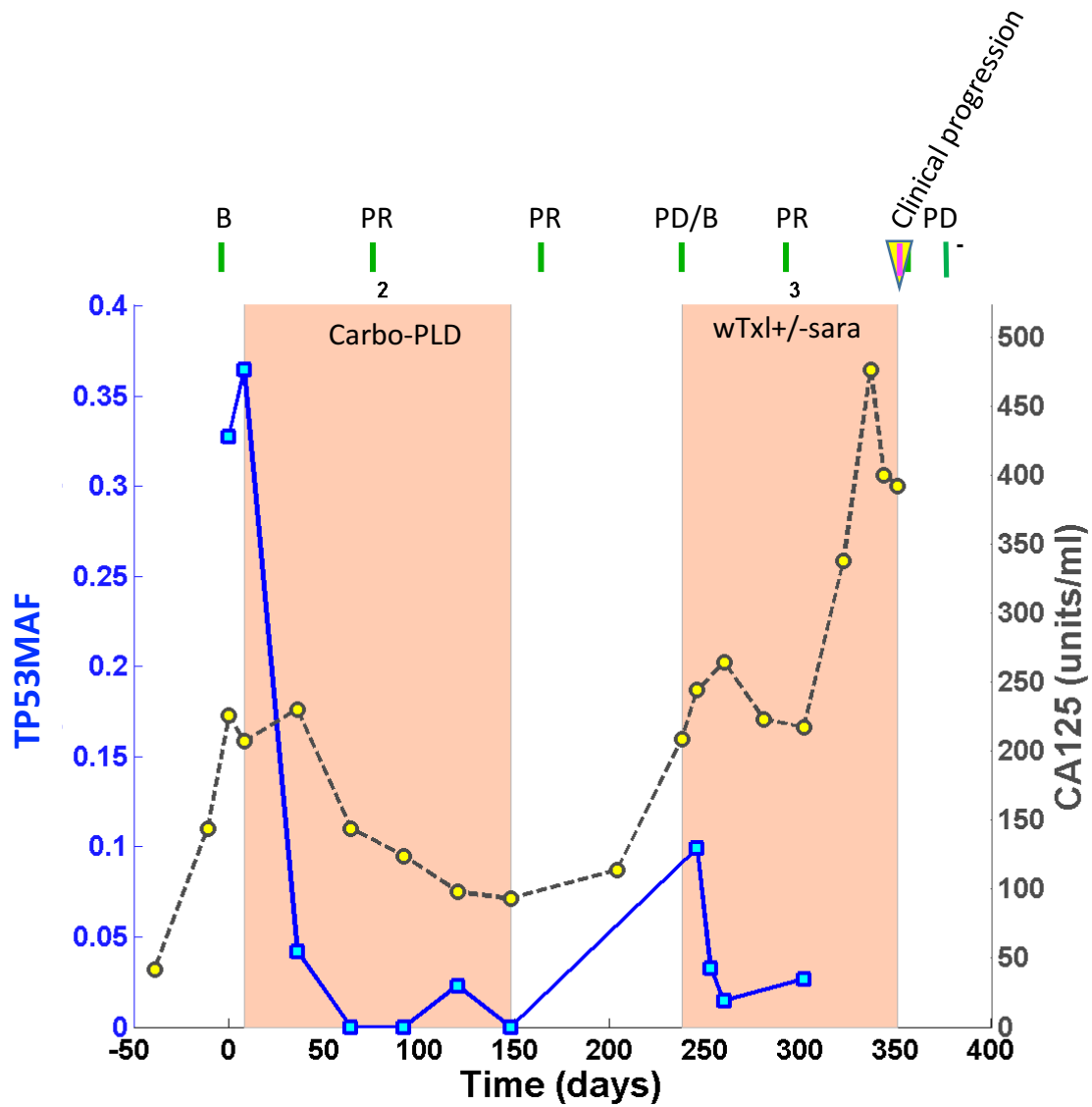
OV04-142

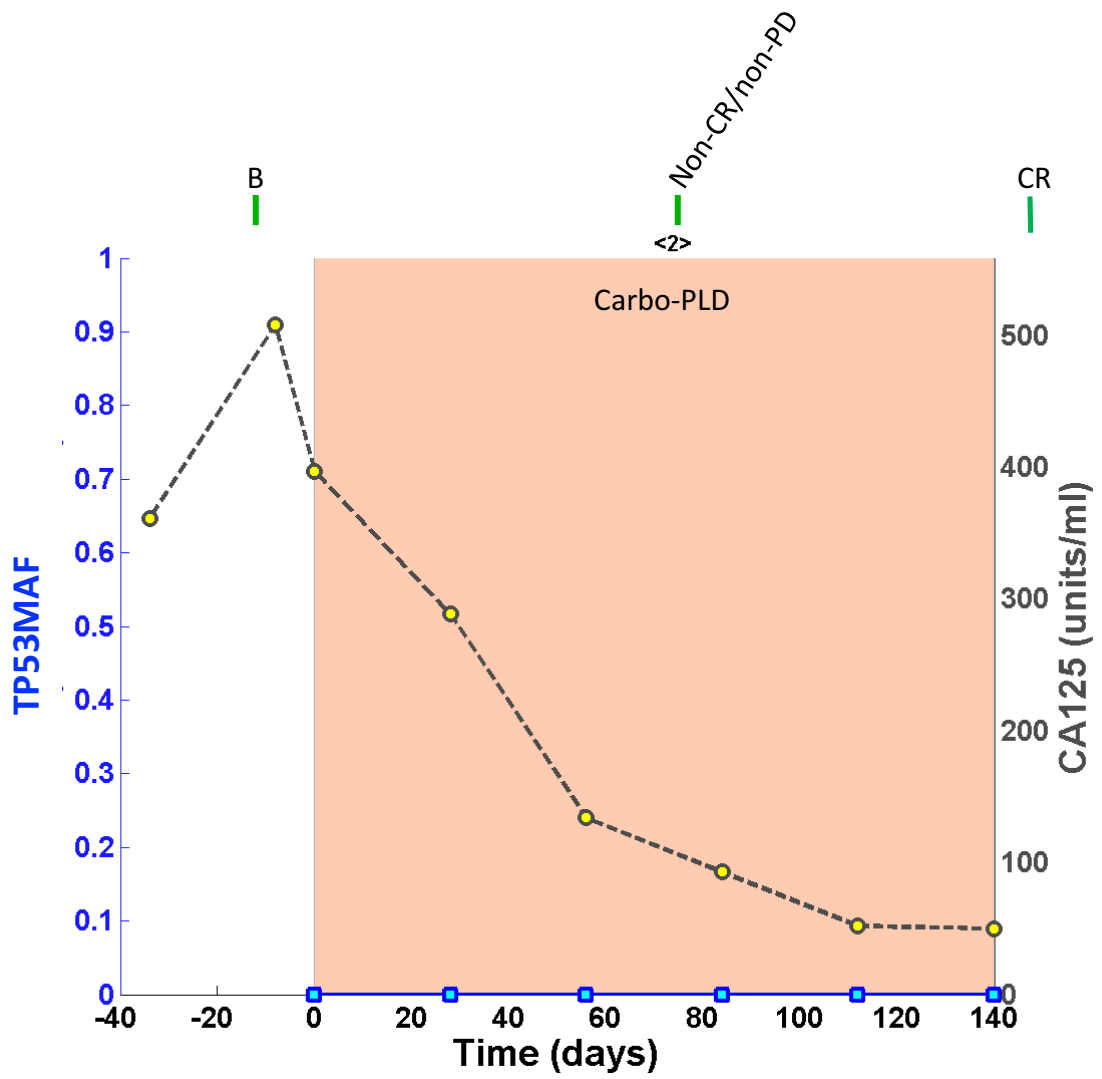


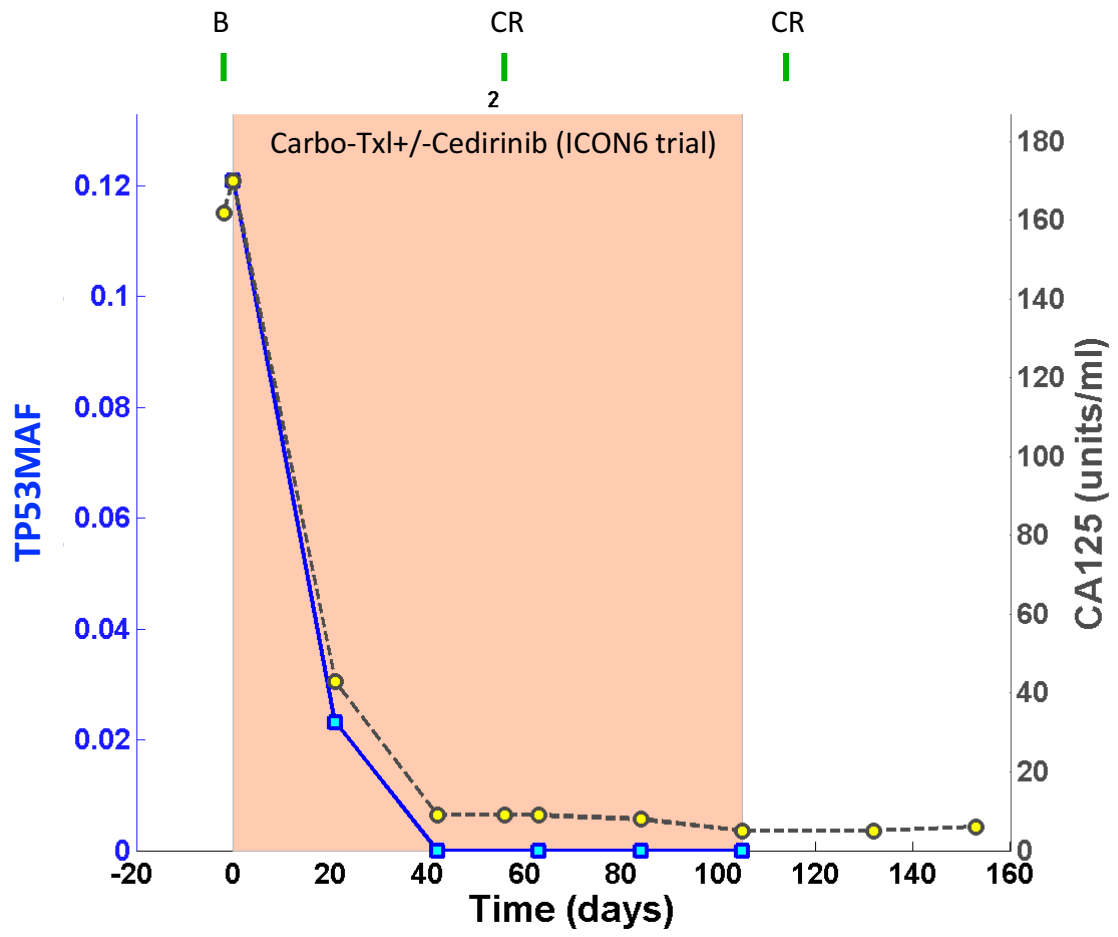
OV04-144

Stage at diagnosis: IIIC
Residual disease: <1 cm









OV04-200

