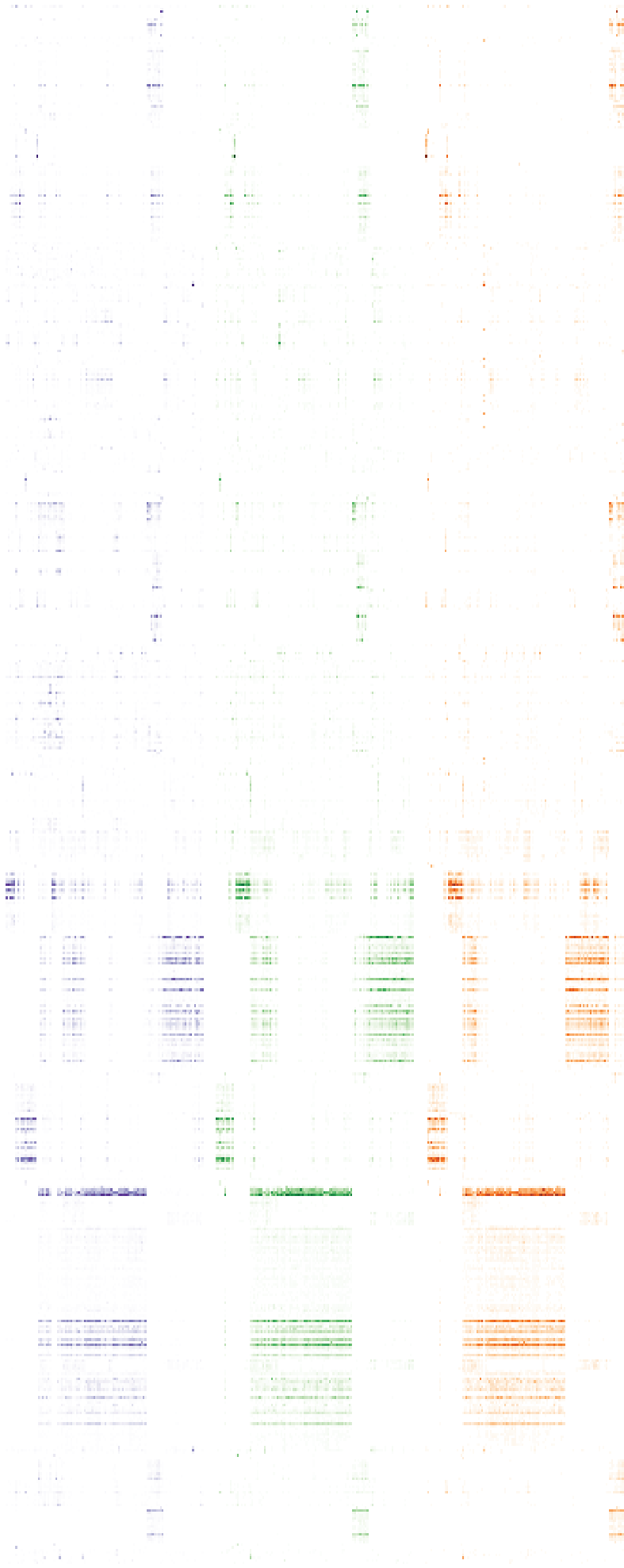
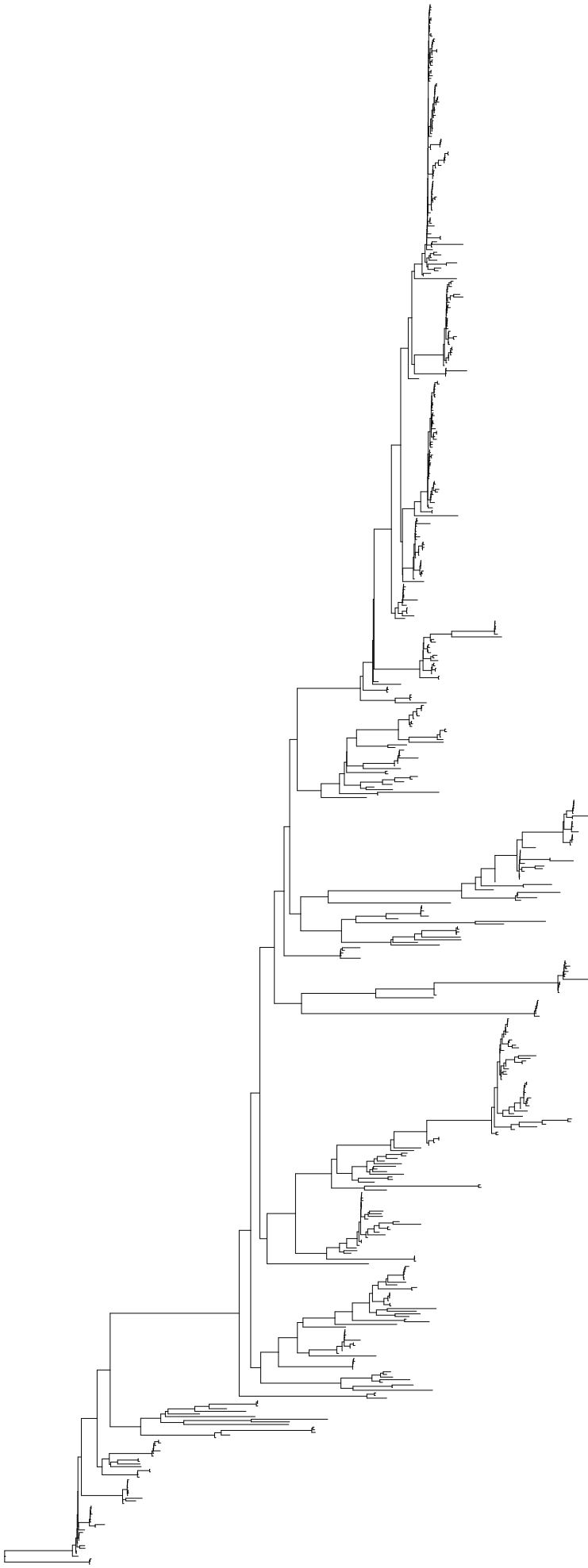

vaginal introitus

mid vagina

posterior fornix



(relative OTU abundance)^{1/3}