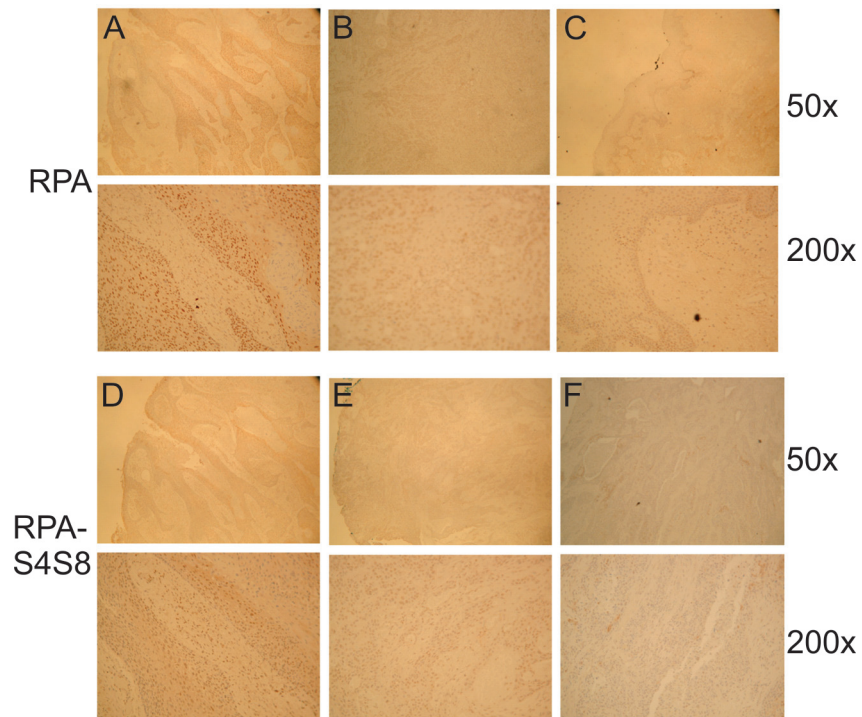


S4S8-RPA phosphorylation as an indicator of cancer progression in oral squamous cell carcinomas

Supplementary Materials



Supplementary Figure S1: Representative images of RPA (A, B, C) and S4S8-RPA (D, E, F) staining observed in OSCC via immunohistochemistry. Examples of representative of high (A, D), medium (B, E) and low (C, F) antibody signal at 50X and 200X.