

## **Estrogens enhance myoblast differentiation in facioscapulohumeral muscular dystrophy by antagonizing DUX4 activity**

Teveroni et al.,

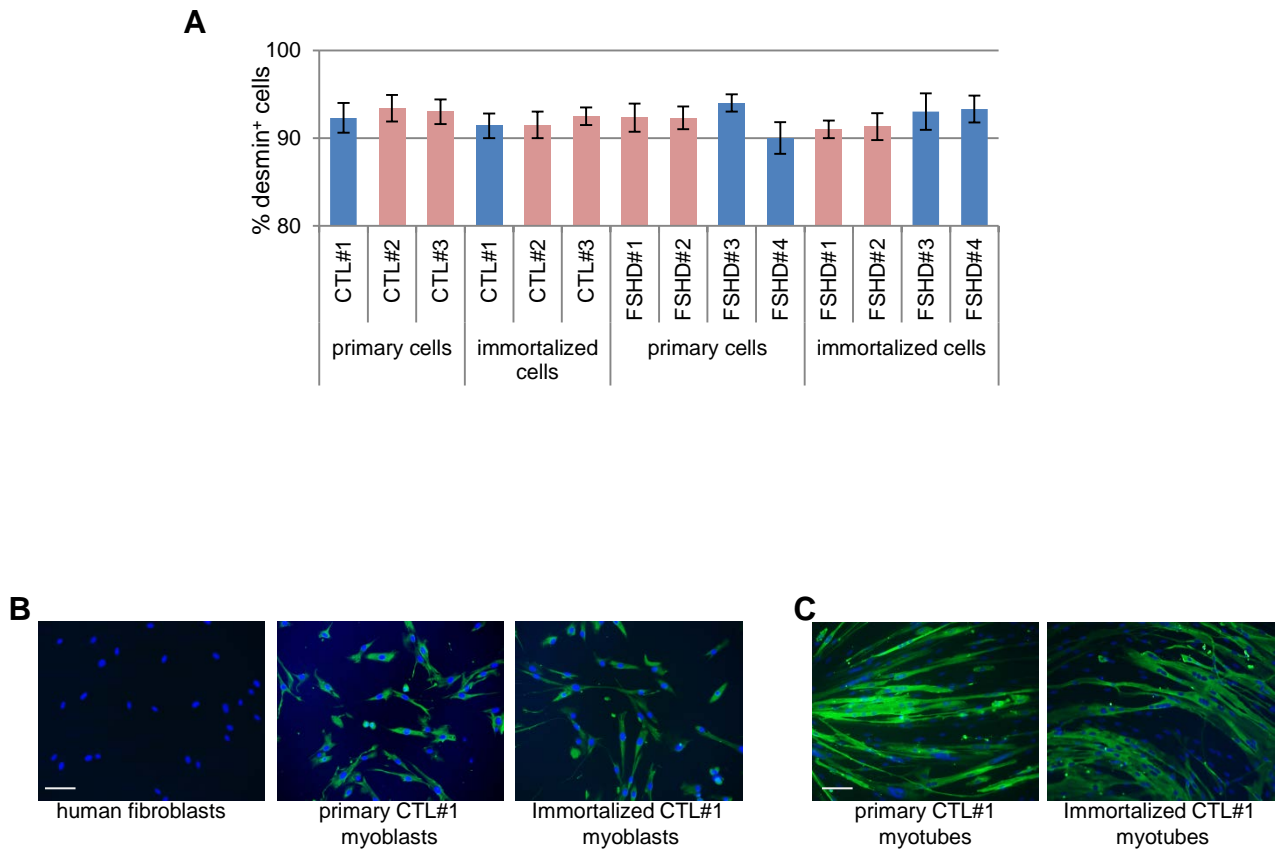
### **Supplemental data contain:**

- **Supplemental Table 1.** Features of FSHD and CTL individuals
- **Supplemental Figure S1.** Analysis of myoblast properties
- **Supplemental Figure S2** Analysis of myoblast growth
- **Supplemental Figure S3** Analysis of DUX4-induced cell death
- **Supplemental Figure S4.** Analysis of endogenous estrogen receptors and proliferation activity in myoblasts
- **Supplemental Clinical data.**
  - Clinical data and description of FSHD families
  - **Supplemental Table 2.** Clinical parameters of FSHD families
  - **Supplemental Table 3.** Clinical parameters of FSHD patients affected by cancer
  - **Supplemental Figure S5.** Pedigree of FSHD families
- **Supplemental Figure S6.** Source data of immunofluorescence analysis.
- **Supplemental Figure S7.** Full uncut gels

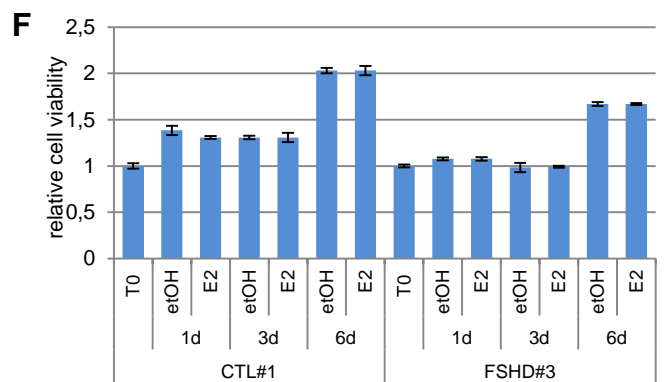
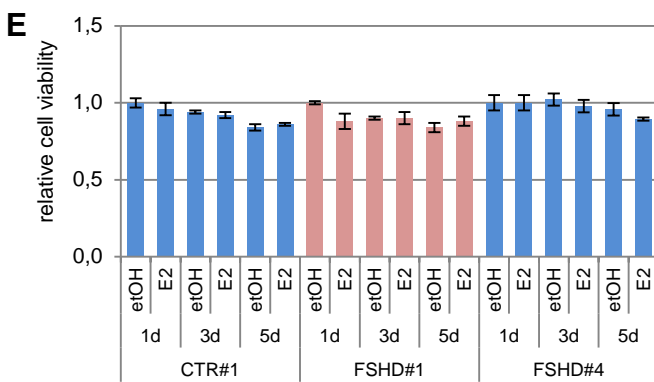
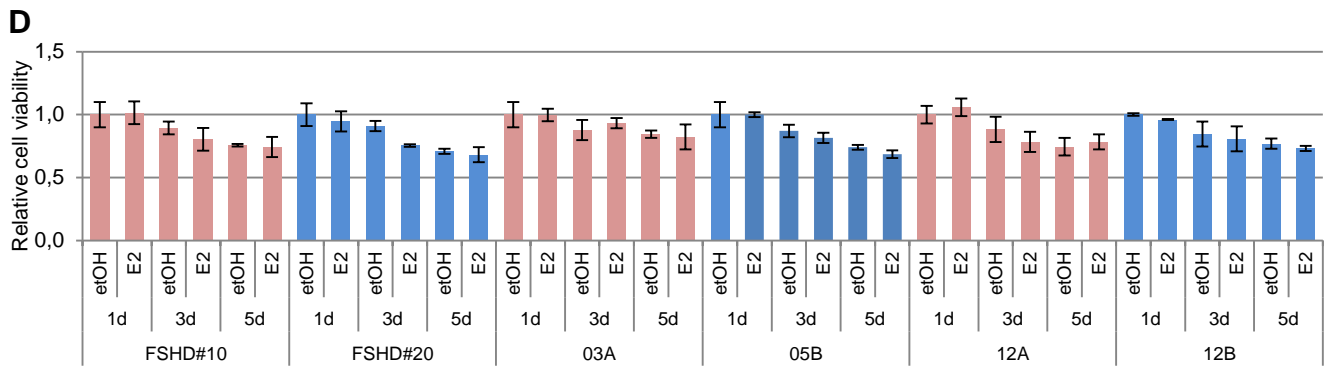
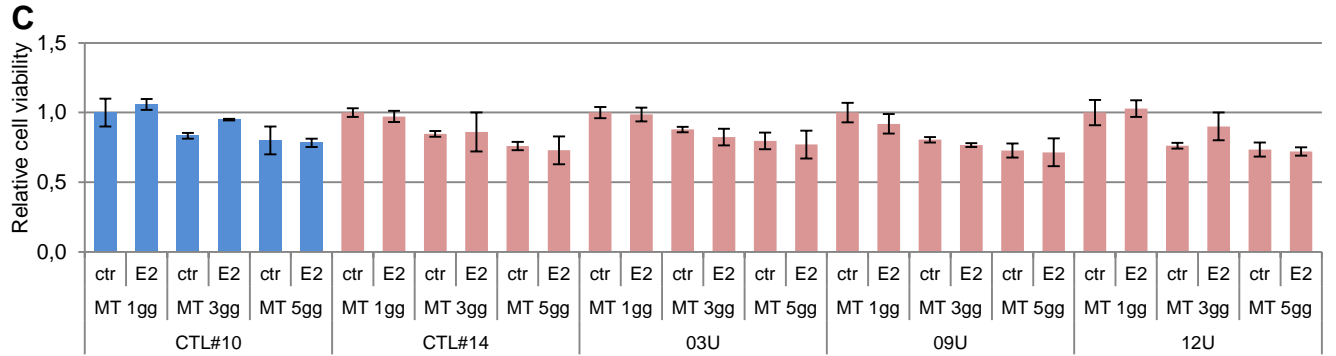
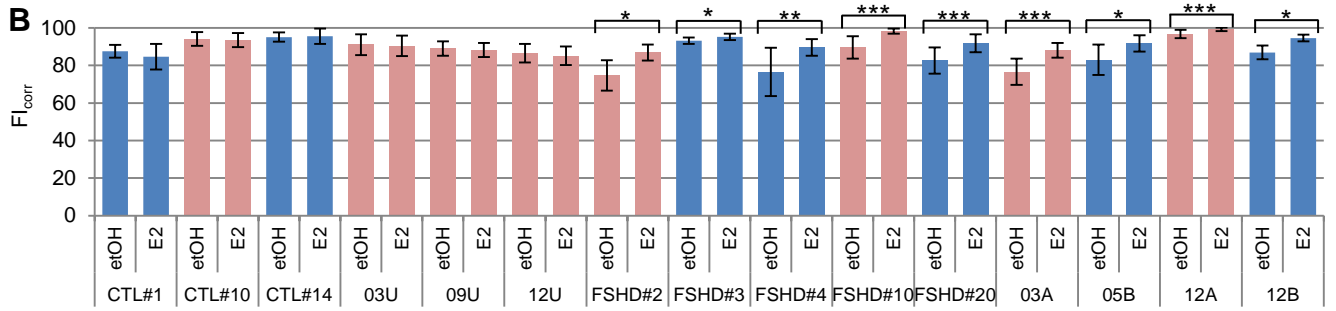
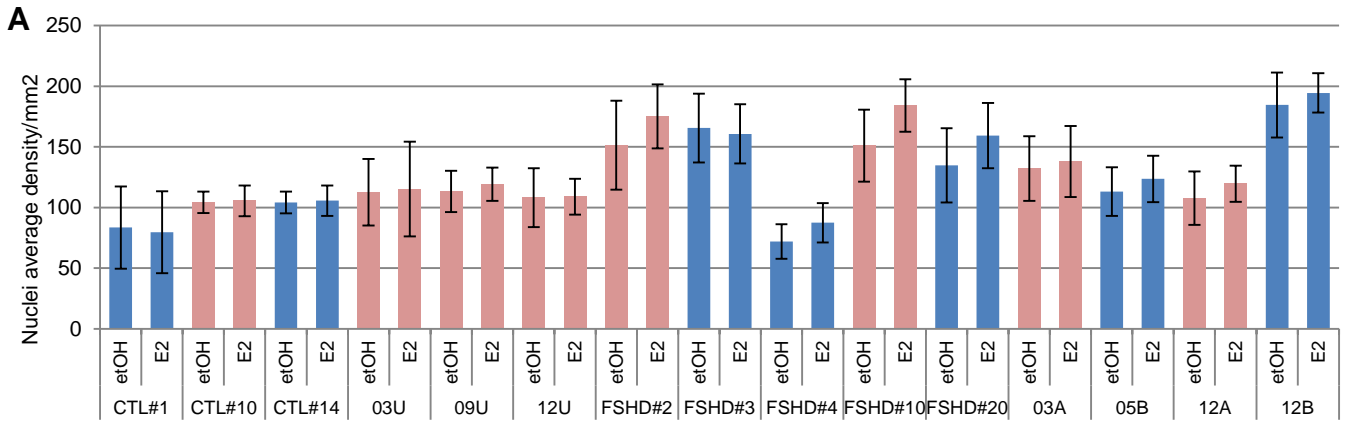
**Supplemental Table 1.** Features of FSHD and CTL individuals

	<b>Patient</b>	<b>Gender</b>	<b>Biopsy side<sup>A</sup></b>	<b>Fragment length (D4Z4 units)</b>	<b>CSS</b>	<b>Age at biopsy</b>
<b>1</b>	<b>FSHD#1</b>	Female	Quadr	4	3.5	37
<b>2</b>	<b>FSHD#2</b>	Female	Delt	3	4	48
<b>3</b>	<b>FSHD#3</b>	Male	Delt	6	1.5	36
<b>4</b>	<b>FSHD#4</b>	Male	Quadr	3	3.5	36
<b>5</b>	<b>FSHD#10</b>	Female	Delt	7	2.5	68
<b>6</b>	<b>FSHD#20</b>	Male	Quadr	6	1	25
<b>7</b>	<b>03A</b>	Female	Bic	3	4+	40
<b>8</b>	<b>05B</b>	Male	Delt	5	4.4+	19
<b>9</b>	<b>12A</b>	Female	Delt	3	4+	22
<b>10</b>	<b>12B</b>	Male	Delt	3	4+	49
<b>1c</b>	<b>CTL#1</b>	Male	Quadr			25
<b>2c</b>	<b>CTL#2</b>	Female	Quadr			17
<b>3c</b>	<b>CTL#3</b>	Female	Delt			36
<b>4c</b>	<b>CTL#10</b>	Female	Quadr			69
<b>5c</b>	<b>CTL#14</b>	Male	Quadr			67
<b>6c</b>	<b>03U</b>	Female	Bic			42
<b>7c</b>	<b>09U</b>	Female	Delt			57
<b>8c</b>	<b>12U</b>	Female	Delt			24

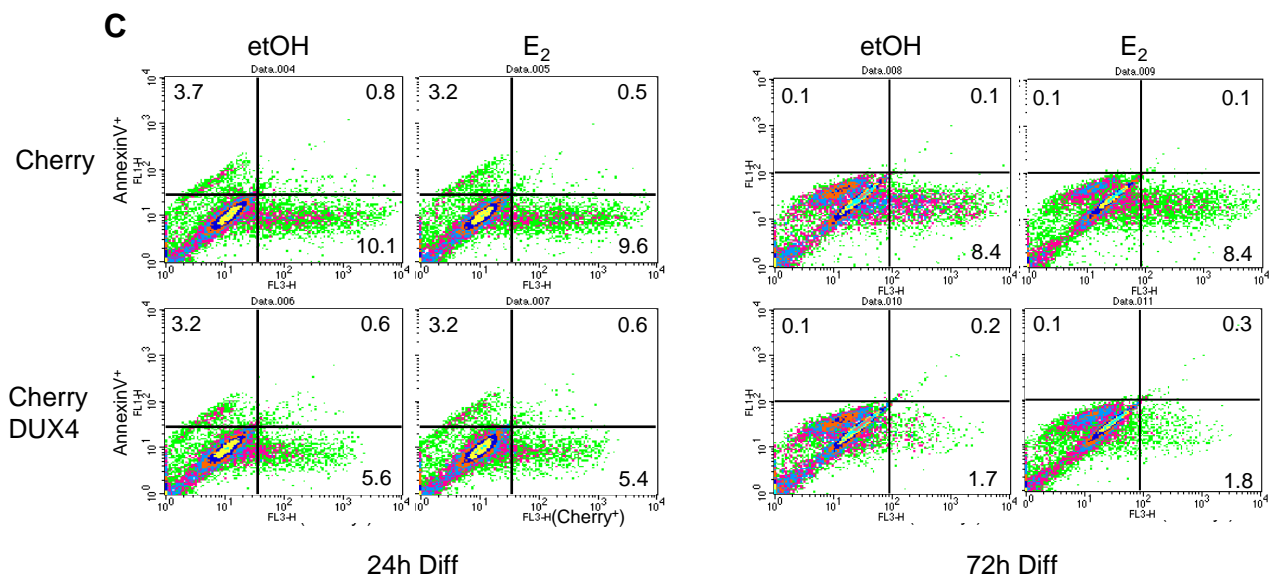
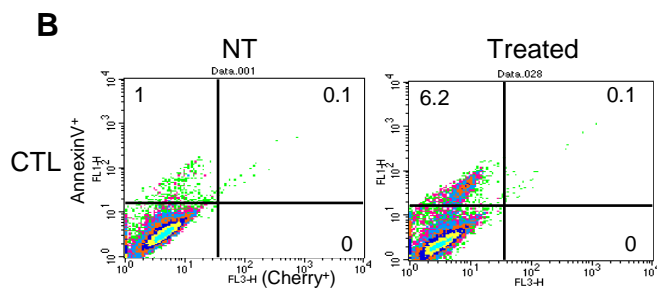
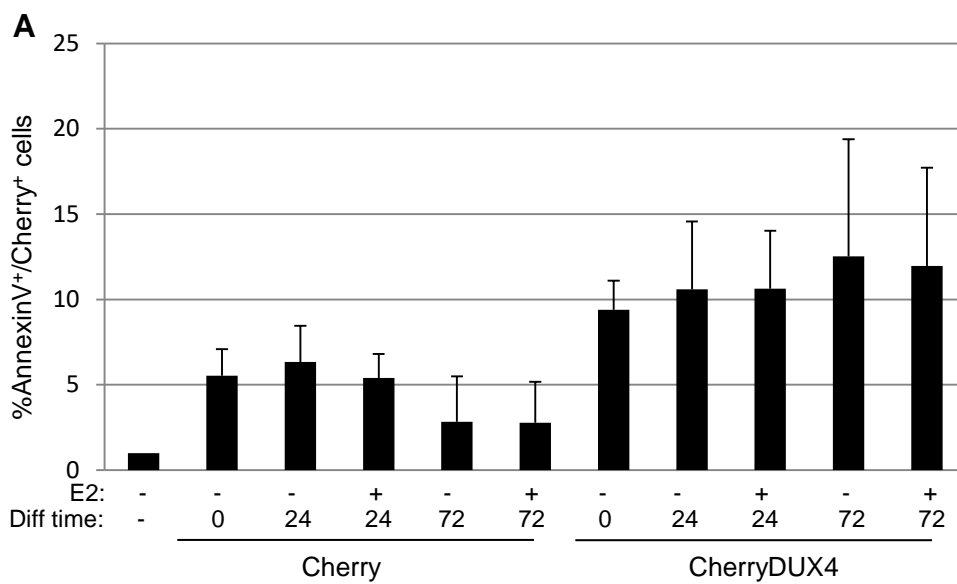
<sup>A</sup>Quadr: quadriceps, Delt: deltoid, Bic: biceps muscles.



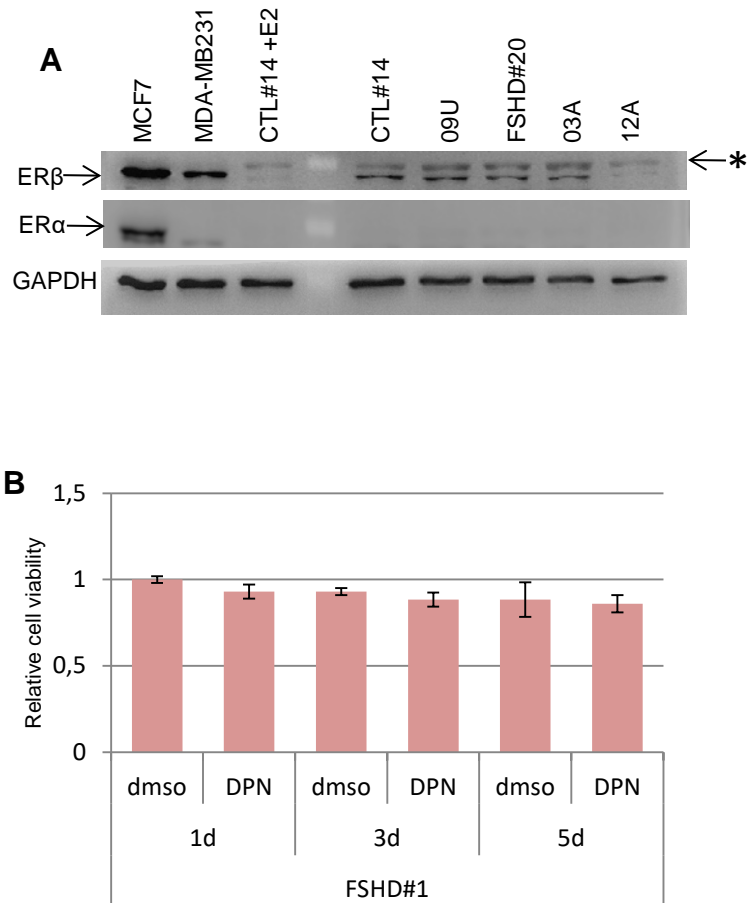
**Figure S1. Analysis of myoblasts properties.** (A) Percentage of desmin positive cells in indicated myoblast cultures. (Percentage desmin<sup>+</sup> cells = desmin<sup>+</sup> nuclei/total number of nuclei). Pink bars represent female, blue bars male myoblasts. Mean  $\pm$  SD of two independent experiments is shown. Six different fields/condition were counted (n=12). (B) Representative pictures of desmin immunostaining in indicated cell cultures. Scale bar: 75  $\mu$ m. (C) MHC immunostaining (green) of myotubes from primary and immortalized CTL#1 after 7 days of growth in differentiation medium. Scale bar: 75  $\mu$ m.



**Figure S2. Analysis of myoblast growth.** (A) Average density of nuclei/mm<sup>2</sup> after 7 days of culture in differentiation medium in the absence or presence of 10<sup>-8</sup>M E<sub>2</sub>. Pink bars represent female, blue bars male myoblasts. (B) Fusion index corrected (Fi<sub>corr</sub>) of myoblasts from FSHD and healthy individuals (CTL) cultured as in A.  $Fi_{corr} = \text{Percentage of nuclei in MHC}^+ \text{myotube} / \text{number of MHC}^+ \text{nuclei}$ , where a myotube is a MHC<sup>+</sup> cell with ≥3 nuclei. Data in A and B represent the mean ± SD of 2 independent experiments, but 1 experiment is represented for CTL#1, FSHD#2, and FSHD#3. For each experiment, 8 fields/condition were counted. (n=8 for CTL#1, FSHD#2 and FSHD#3, n=16 for all other myoblast cell lines). \*\*\* P<0.001, \*\*P<0.01, \*P<0.05, two-tailed Student's t-test. (C-E) Cell viability by Cell Titer assay in primary CTL (C) and FSHD (D) cell lines, or in indicated immortalized cell lines (E) cultured for 1, 3 or 5 days. For each cell line, the value of growth obtained at 1d with etOH was set to 1. Data represent the mean ± SD of two experiments performed in quadruplicates (n=8). (F) Cell viability as in E, in the indicated immortalized cell lines grown for 1, 3 or 6 days in proliferation medium. For each cell line, the value obtained at the starting point with etOH (T0) was set to 1. Data represent the mean ± SD of two experiments performed in quadruplicates (n=8).



**Figure S3. Analysis of DUX4-induced cell death.** (A) Percentage of double AnnexinV/Cherry positive cells in immortalized CTL myoblasts expressing Cherry or Cherry-DUX4 and cultured in differentiation medium in the presence or absence of E<sub>2</sub>. data represent mean  $\pm$  SD of three independent experiments (n=3). (B) Representative pictures of FACS analysis of untransfected control cells untreated (NT) or induced to apoptosis by anoikis for 2 hours (Treated). (C) Representative plots of FACS analysis of CTL cells expressing Cherry or Cherry-DUX4 treated as in A. Numbers indicate the fraction of each cell population. The analysis is representative of three independent experiments.



**Figure S4. Analysis of endogenous estrogen receptors and proliferation activity in myoblasts.** (A) Wb of the estrogen receptors in myoblasts from indicated primary myoblasts. Lysate from MCF7 cells was used as positive control for ER $\alpha$  and ER $\beta$ , MDA-MB231 cells as negative control for ER $\alpha$ . Lysate from CTL#14 cells treated with E<sub>2</sub> shows the decrease of ER $\beta$  after treatment. \* marks an unspecific band (faintly present in ER $\alpha$  blot too). (B) Cell viability calculated by Cell Titer assay of immortalized FSHD#1 myoblasts cultured for 1, 3 or 5 days in differentiation medium in the absence (dms) or presence of DPN. Data represent mean  $\pm$  SD of four replicates (n=4).

## Clinical Data

### *Clinical data and description of FSHD families*

Data on eight FSHD families followed at the Nice center in which at least one of the affected female patients was treated for breast cancer with anti-estrogen therapy or underwent early menopause, were collected retrospectively and disease progression analyzed (Supplemental Table 2, Supplemental Figure 5, A-G). In five families a female patient was treated with anti-estrogenic therapy for breast cancer (Families 1-4, 8) and in three families a female patient underwent early menopause (Family 5-7). In families 1, and 3, no previous history of FSHD was known, and the two patients (F1-Pt#II.2, and F3-Pt#II.1) underwent clinical examination following the development of clinical signs within 6 months of the beginning of tamoxifen and anti-aromatase letrozole therapy, respectively (Supplemental Table 2). The other 4 female patients (F2-Pt#I.1, F4-Pt#1, F6-Pt#II.1, and F8-Pt#II.2) were diagnosed as asymptomatic or mildly affected before the therapy. In all women a rapid and sharp worsening of clinical symptoms was observed during and/or at the end of the treatment (measured as age corrected clinical score, ACSS) (1). A similar abrupt worsening was observed in F5-Pt#II.3, F6-Pt#II.1, and F7-Pt#II.3 who underwent early menopause for hysterectomy and/or ovariectomy (Supplemental Table 2). As internal controls, relatives from the same family carrying the same pathologic D4Z4 contraction did not show a similar progression but remained asymptomatic (F1-Pt#II.1, F1-Pt#III.1, F3-Pt#II.2, F5-Pt#II.2, F7-Pt#I.2, F7-Pt#II.1, and F7-Pt#II.2) or mildly affected (F5-Pt#II.1 and F8-Pt#II.1) over the same time course. Patient F1-Pt#II.1, who entered menopause at the age of 49, is receiving hormone replacement therapy and is still asymptomatic. Furthermore, patient F3-Pt#II.2 who developed breast cancer similarly to her sister patient F2-Pt#II.1 did not undergo hormone therapy and remained asymptomatic. As a further control, we evaluated 5 FSHD patients who were diagnosed with other types of cancer and underwent surgery and/or chemotherapy (Supplemental Table 3). These patients, including three women one of which with breast carcinoma treated with anti-HER2/neu monoclonal antibody trastuzumab (Pt#5) did not experience a similar worsening of clinical parameters, and the ACSS did not undergo substantial changes (Supplemental Table 3).

### *Clinical description of FSHD1 families.*

F1. The proband (II.2) presented at age 40 with marked weakness and atrophy of the left scapular fixator muscles and mild weakness and atrophy on the right side. Orbicularis oris and oculi asymmetric weakness were also noted. The patient was diagnosed at age 39 with stage I infiltrating ductal adenocarcinoma of the breast which was treated by lumpectomy, followed by hormonal therapy treatment with tamoxifen (20mg/day). After 6 months of treatment, the patient noticed the appearance of left scapular winging. Blood test showed increased CK (twice the normal value and



the patient was addressed to Neuromuscular disease specialized center of Nice for further assessment. At admission, muscular examination assigned a Clinical severity score of 2 (ACSS=102.6). The patient's 47-year-old sister (II.1), and her son (III.1) were found to carry the same contracted allele and were asymptomatic at clinical examination. Her 78 year old father, carrying the same allele showed typical orbicularis oculi and oris weakness and a mild left scapular weakness (CSS=2, ACSS= 25.6).

In the three following years, patient II.2 showed a progressive decline of her muscular strength with progressive appearance of bilateral weakness in biceps brachii and tibialis anterior muscles, Beavor's sign and abdominal weakness, followed by severe hamstring and ileo-psoas weakness. At this point the patient required bilateral support to rise from a chair. Her walking was limited to 50mt on flat surfaces with the aid of a cane (CSS=4.5, Age=42, ACSS=214.3). At the end of the third year, tamoxifen was stopped. In the next 2 years, the patient's muscular weakness did not worsen but rather showed a small improvement (CSS=4, age= 44, ACSS=181.8). Family members II.1 and III.1 remained asymptomatic. The individual II.1 underwent menopause at age 49, she is still receiving transdermal 17- $\beta$ -estradiol and progesterone and is asymptomatic. Her father was not tested as he died of a stroke at age 81.

F2. The proband (II.1) presented at the age 5 with an infantile form of FSHD (CSS=3, ACSS=1200). Her 30-year-old mother (I.1), was diagnosed as carrying a 40% somatic mosaicism. She was totally asymptomatic, and her CK levels were normal. She was regularly seen in pediatric department until the age 40 because she came with his son for regular follow-up and clinicians refer to her as asymptomatic. At the age of 41, she was diagnosed with a stage I infiltrating ductal adenocarcinoma of the breast treated with lumpectomy followed by hormonal therapy with tamoxifen (20mg/day). The patient was addressed 6 months later to Neuromuscular disease specialized center of Nice for the sudden appearance of generalized muscle pain localized mostly at shoulder and calf. At admission, the patient displayed steppage gait. Muscular examination revealed orbicularis oculi asymmetry, weakness of scapular fixator muscles (symmetric), left tibialis anterior and hamstring (bilateral) (CSS =3, ACSS=146.3). CK levels were increased (3 times the normal values). After 6,5 months, tamoxifen treatment was stopped. Since then the patient was seen every year and did not show any substantial worsening until age 46. In the last year, she underwent menopause and developed abdominal and right tibialis anterior weakness (CSS=3, ACSS=130.4).

F3. The proband (II.1) presented at age 46 at Neuromuscular disease specialized center of Nice. Clinical examination showed mild symmetric scapular fixator and asymmetric tibialis anterior weakness scored at 3 on the right and 4 at the left side. She was able to walk unaided, but foot drop

on the right side required ankle-foot orthosis (AFO) to prevent falls (CSS=2.5, ACSS=108.7). Six months before, she was diagnosed a stage II infiltrating ductal adenocarcinoma of the breast. She was treated with mastectomy followed by local radiotherapy and aromatase inhibitor hormone therapy (letrozole 2.5 mg per day). After 1 month of treatment, she started to experience generalized muscle pain that was thought to be a side effect of the aromatase inhibitor and was treated with paracetamol 1 to 3 gr per day. Six months later, CK showed an increase to twice the normal value. A biopsy was taken from the vastus lateralis muscle. Mild inflammatory changes, consisting of a T cell lymphocyte infiltrate, were noted together with fiber type inequality and nuclear centralization. Her 44-year-old sister (II.2) displayed only minor signs of facial involvement. In her clinical history, she had had breast cancer at the age of 40 which was treated with mastectomy and radiotherapy without hormone therapy. She was not menopausal. Her 74-year-old mother (I.2) carried the contracted pathogenic allele, but she was not available for clinical examination. The two sisters were seen 3 years later at the age of 49 (II.1) and 47 (II.2). Both of them had undergone menopause one year earlier, and they were not receiving hormone replacement therapy. The younger sister was still asymptomatic; the older was assigned a CSS=2.5 (ACSS= 102.0). Recently, she developed a left foot drop needing ankle-foot orthosis (AFO).

F4. The patient is a woman was followed at Neuromuscular disease specialized center of Nice since the age of 25 for a very mild form of FSHD1 presenting with generalized pain, and mild facial and scapular weakness (CSS=1, ACSS=80). At the age of 35, she underwent mastectomy for a stage I infiltrating ductal adenocarcinoma of the breast followed by radiotherapy and tamoxifen therapy (20mg/day). Her clinical conditions worsened in the following months, and 6 months later she showed lower leg muscle weakness involving the tibialis anterior muscles, calves and hamstrings. Clinical evaluation gave CSS=3 (ACSS=171.4). She continued hormone therapy but two years later her muscles signs worsened (CSS=4, ACSS=216.2) and she decided to stop the therapy. She is now 45 years old, and the CSS and muscular testing are unchanged. Family members were not available for clinical evaluation, but none is reported to have symptoms.

F5. The proband (II3) presented at age 32 with mild scapular weakness predominant on the left side and facial involvement (CSS=1,5, ACSS= 93.75). Her 35 year old brother (II.1) and her 33-year-old sister (II.2) were at that time asymptomatic. At age 36, patient II3 went through early menopause after hysterectomy and ovariectomy. One year later her clinical conditions had remarkably worsened with the appearance of abdominal, humeral, and tibialis anterior weakness (CSS=2,5, ACSS=135.1). Three years later at age 40, she showed severe muscle weakness involving the proximal lower and upper leg muscles; she was still able to walk unaided on flat surfaces but was unable to climb stairs (CSS=4, ACSS=200). At age 41, she was wheelchair-

bounded (CSS=5, ACSS=243,9). Her sister is now 42-year-old and is still asymptomatic. Her brother, now 44 year old has CSS=1,5 and ACSS= 68.2.

F6. The proband (II.1), a 39-year-old woman, was diagnosed with FSHD1 at age 27 during a family genetic study but was asymptomatic. Her father, 56-year-old, was symptomatic since the age of 30. At age 56 he has (CSS= 6, ACSS= 107,1). The proband started to develop asymmetric weakness of orbicularis oris and oculi and fixator scapulae weakness 6 months after hysterectomy at 38 for uterine fibroids causing untreatable pain and bleeding (CSS=2, ACSS= 51,3). One year after the surgery, she showed the involvement of lower abdominal muscle with positive Beevor's sign, and of both tibialis anterior muscles (CSS=5; ACSS= 125). Two years after, she needed AFO because of bilateral foot drop and she developed mild hamstring and ileo-psoas muscle weakness with difficulty in climbing stairs and in rising from a chair (CSS= 7; ACSS: 166,6).

F7. The proband (II.3), a 31 years-old woman developed secondary amenorrhea after supra-cervical hysterectomy for abnormal cervical cytological results. One month after, she experienced muscle pain (mostly in her shoulders and calf). Clinical examination was normal, besides a mild asymmetric weakness of orbiculari oculi. CK values were mildly elevated (450UI/L; nv<200 UI/L) (CSS=1; ACSS: 32,2). Genetic analysis revealed a 4QA D4Z4 allele of 8 repeated units confirming the diagnosis of FSHD1. She was addressed in the Nice center one year later because she developed a clear FSHD phenotype including facial and severe scapular weakness (CSS=4; ACSS= 125) . Proximal lower limb involvement was also noted at the muscle CT scan (bilateral Grade 1 fibrofatty degeneration of semi-tendinous and semi-membranous as well as adductor magnus and right tibialis anterior muscles). At age 33, she had difficulty in climbing stairs and a steppage gate due to bilateral foot drop (CSS=6; ACSS=181,8). Her older sister (II.1), now 37 years old and brother (II.2) 35 years old, as well as her mother (I.2) 64 years old, carry the pathogenic allele but they are asymptomatic. They have normal clinical examination, normal CK values and normal CT scan.

F8. The proband (II.2), a 47 years old premenopausal woman was diagnosed with a stage I infiltrating ductal adenocarcinoma of the breast. During the screening that preceded lumpectomy, she was found having a moderate elevation of CK (CK 350UI/L; normal values <200 UI/L) and was addressed for further analysis to Nice center. At clinical examination, mild facial weakness was noted (CSS=1, ACSS=21,3). She came with her older sister, (II.1) 53-year-old- menopausal since the age of 47 with no replacement therapy- who display clear FSHD phenotype (CSS=5, ACSS=94,3). They harbor a 7 repeated units D4Z4 contracted allele. The proband started hormonal therapy with tamoxifen (20mg/day) and in the following six months experienced a rapid decline with the appearance of clear FSHD sign and symptoms (CSS=5; ACSS=104,1). At that time, tamoxifen was stopped. At one and two year control, she was clinically stable (CSS=5,

ACSS=102,4; CSS=5, ACSS=100 respectively). At age 51, she experienced menopause, and one year after beginning of menopause started to decline (CSS=6; ACSS=117,6) and two years later further progressed (CSS=7, ACSS=132).

## References

1. van Overveld PG, Enthoven L, Ricci E, Rossi M, Felicetti L, Jeanpierre M, et al. Variable hypomethylation of D4Z4 in facioscapulohumeral muscular dystrophy. *Ann Neurol*. 2005;58(4):569-76.

**Supplemental Table 2. Clinical parameters of FSHD families.** Patients females that underwent early menopause or antitumor hormone therapy are indicated in bold.

	Patient	Fragment length (repeat units)	Gender	Age at diagnosis of FSHD	ACSS at diagnosis	Event	Age at beginning treatment	ACSS at beginning treatment	Age at the end of treatment	ACSS at the end of treatment	Age at last examination	ACSS at last examination
<b>Family 1</b>	Pt#I.1	7	M	78	25.6	NA <sup>C</sup>	NA	NA	NA	NA	NA	NA
	Pt#II.1	7	F	47	AS <sup>B</sup>	NA	NA	NA	NA	NA	52	AS
	<b>Pt#II.2</b>	7	F	40	102.6	BC <sup>D</sup>	39 (TAM <sup>F</sup> )	102.6	42	214.3	44	181.8
	Pt#III.1	7	M	10	AS	NA	NA	NA	NA	NA	15	AS
<b>Family 2</b>	<b>Pt#I.1</b>	3(40%) <sup>A</sup>	F	30	AS	BC	41 (TAM)	AS	41,5	146,3	46	130,4
	Pt#II.1	3	M	5	1200	NA	NA	NA	NA	NA	10	1000
<b>Family 3</b>	<b>Pt#II.1</b>	7	F	46	AS	BC	46 (LET <sup>G</sup> )	AS	46,5	108,7	49	102
	Pt#II.2	7	F	44	AS	BC	NA	NA	NA	NA	47	AS
<b>Family 4</b>	<b>Pt#1</b>	8	F	25	80	BC	35 (TAM)	80	37	216,2	45	177,8
<b>Family 5</b>	Pt#II.1	6	M	35	AS	NA	NA	NA	NA	NA	44	68,2
	Pt#II.2	6	F	33	AS	NA	NA	NA	NA	NA	42	AS
	<b>Pt#II.3</b>	6	F	32	93,75	Hyst <sup>E</sup>	36	93,75	37	135,1	41	243,9
<b>Family 6</b>	Pt#I.1	7	M	30	NA <sup>C</sup>	NA	NA	NA	NA	NA	56	107,1
	<b>Pt#II.1</b>	7	F	27	AS	Hyst	38	NA	38,5	51,3	41	166,6
<b>Family 7</b>	Pt#I.2	8	F	62	AS	NA	NA	NA	NA	NA	64	AS
	Pt#II.1	8	F	35	AS	NA	NA	NA	NA	NA	37	AS
	Pt#II.2	8	M	33	AS	NA	NA	NA	NA	NA	35	AS
	<b>Pt#II.3</b>	8	F	31	32,2	Hyst	31	32,2	32	125	33	181,8
<b>Family 8</b>	Pt#II.1	7	F	53	94,3	NA	NA	NA	NA	NA	59	118, 6
	<b>Pt#II.2</b>	7	F	47	21,3	BC	47 (TAM)	21,3	47,5	104,1	53	132

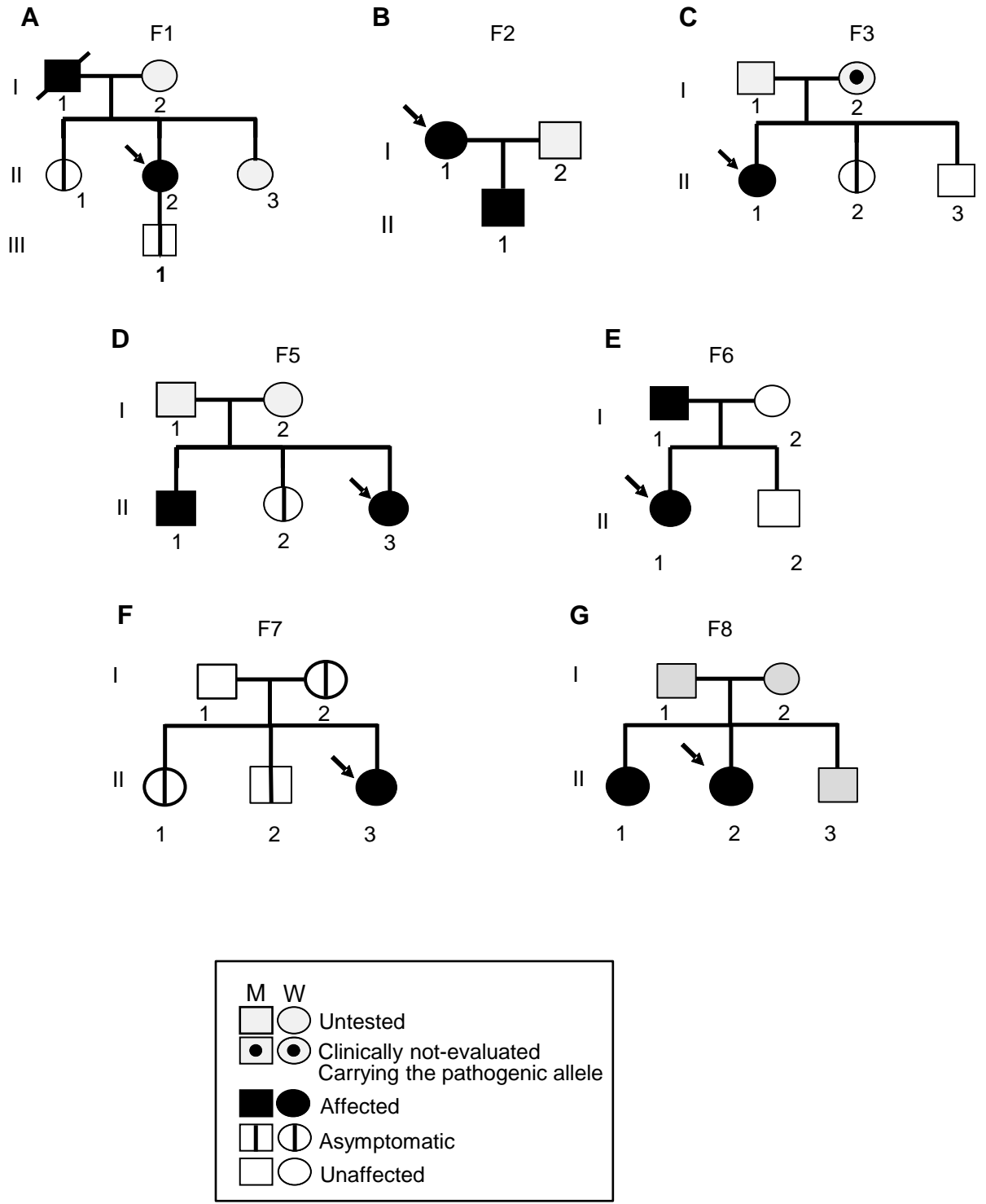
<sup>A</sup>This patient carries a 40% somatic mosaicism; <sup>B</sup>AS= asymptomatic; <sup>C</sup>NA= not applicable; <sup>D</sup>BC= Breast cancer; <sup>E</sup> Hyst= hysterectomy/ovarectomy;

<sup>F</sup>TAM= tamoxifen, <sup>G</sup>LET= Letrozole,

**Supplemental Table 3. Clinical parameters of FSHD patients affected by cancer.** Patients treated with chemotherapy are indicated in bold, the other patients underwent surgery.

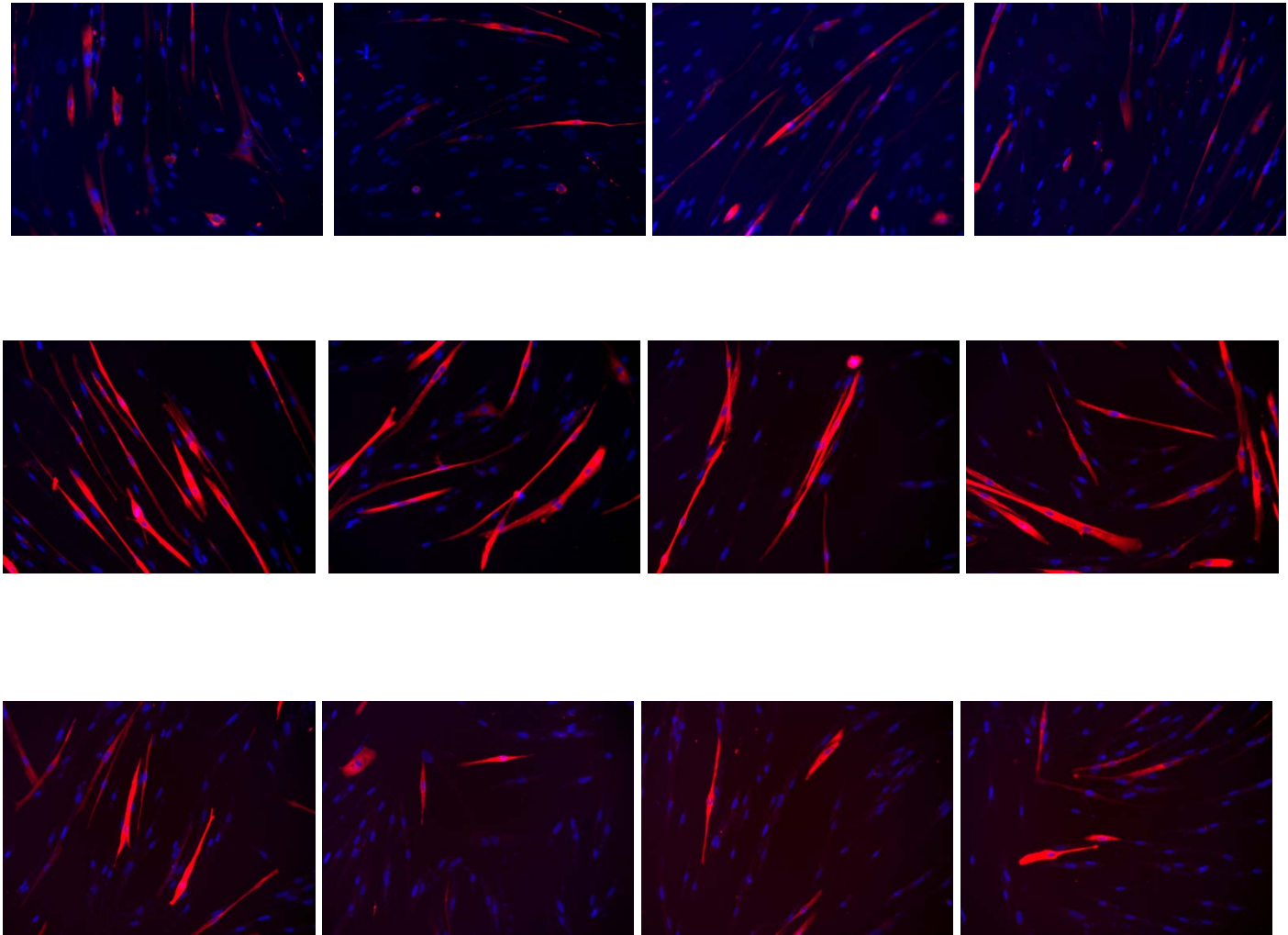
Patient	Fragment length (repeat units)	Gender	Age at FSHD1 diagnosis	ACSS at diagnosis	Type of cancer	Age at cancer diagnosis	ACSS at the time of cancer diagnosis	ACSS after one year	ACSS after two years	ACSS after three years
<b>Pt# 1</b>	<b>7</b>	<b>F</b>	<b>32</b>	<b>93,75</b>	<b>esophageal adenocarcinoma</b>	<b>47 (CBP, PAC)</b>	<b>106, 4</b>	<b>104,1</b>	<b>122,44</b>	<b>120</b>
Pt# 2	8	F	37	54	Papillary Thyroid cancer	41	48,7	46,51	NA	68,1
<b>Pt#3</b>	<b>4</b>	<b>M</b>	<b>25</b>	<b>320</b>	<b>Malignant Melanoma</b>	<b>27 (INFa)</b>	<b>333,3</b>	<b>321,4</b>	<b>310,3</b>	<b>NA</b>
Pt# 4	7	M	45	AS	Colon rectal cancer	55	AS	AS	AS	AS
<b>Pt# 5</b>	<b>6</b>	<b>F</b>	<b>30</b>	<b>133</b>	<b>Invasive lobular breast carcinoma</b>	<b>45 (TRA)</b>	<b>111,1</b>	<b>108,6</b>	<b>NA</b>	<b>125</b>

<sup>A</sup>NA= not applicable <sup>B</sup>AS= asymptomatic; <sup>C</sup>CBP= carboplatin, <sup>D</sup>PAC= paclitaxel; <sup>E</sup>INFa= Interferon  $\alpha$ ; <sup>F</sup>TRA= trastuzumab



**Figure S5. Pedigree of FSHD families.** (A-G) Pedigree of FSHD1 families described in Supplemental Table 2. The proband of each family represents a female patient who underwent anti-tumor hormone therapy or early menopause.

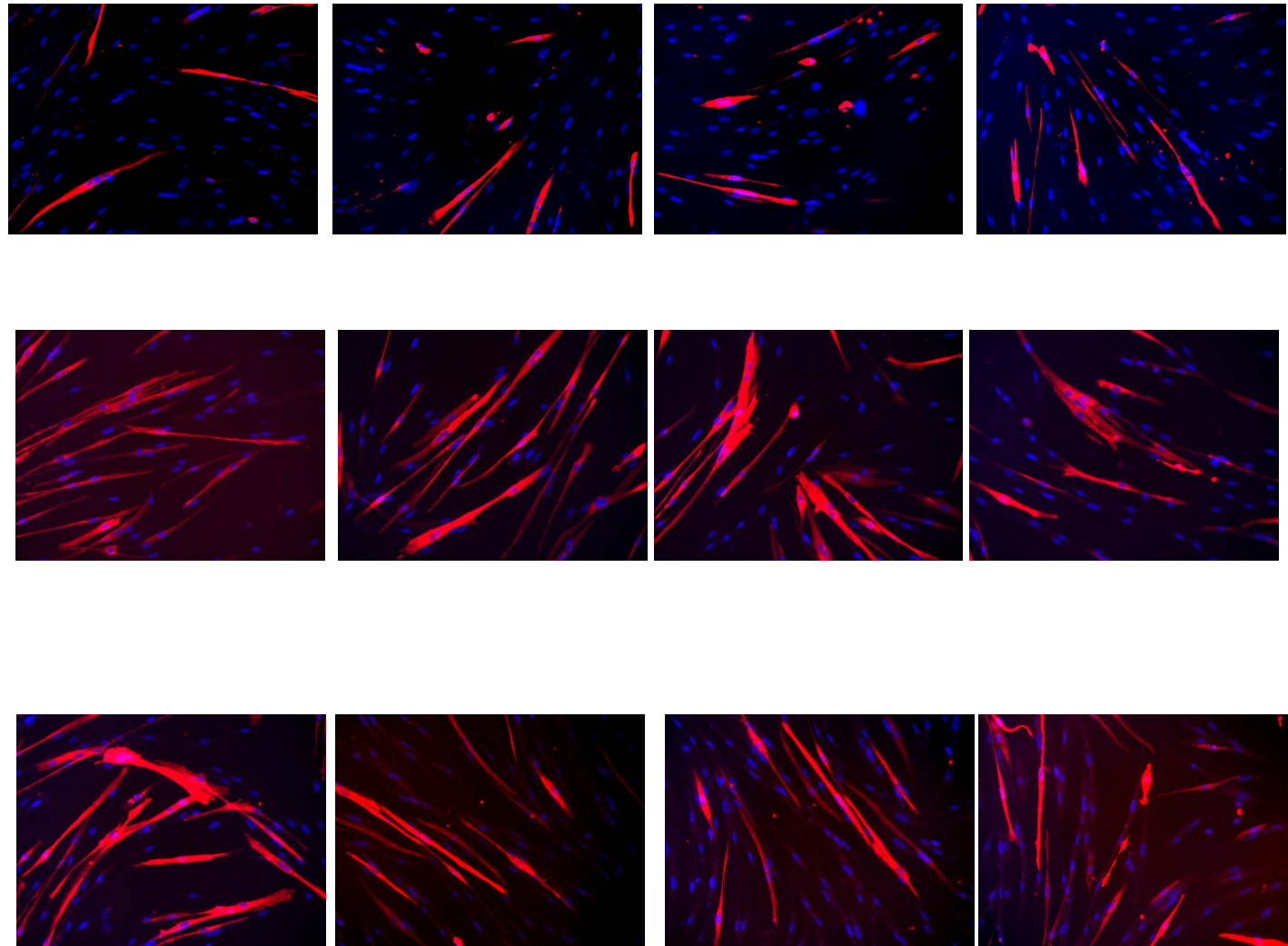
**Figure S6**  
Source data of Figure 1, M and N  
(immortalized FSHD#1 myoblasts)





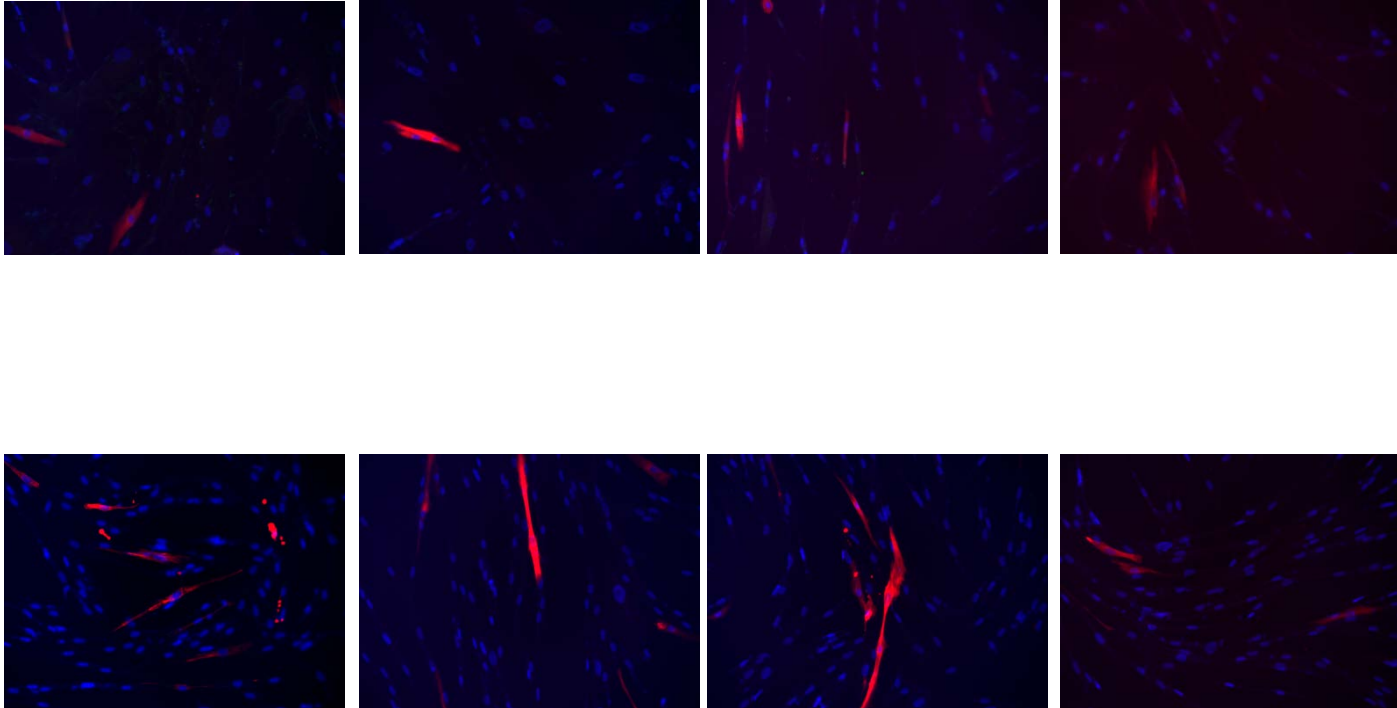
**Figure S6**

Source data Figure 1, M and N  
(immortalized FSHD#1myoblasts +E<sub>2</sub>)



**Figure S6**

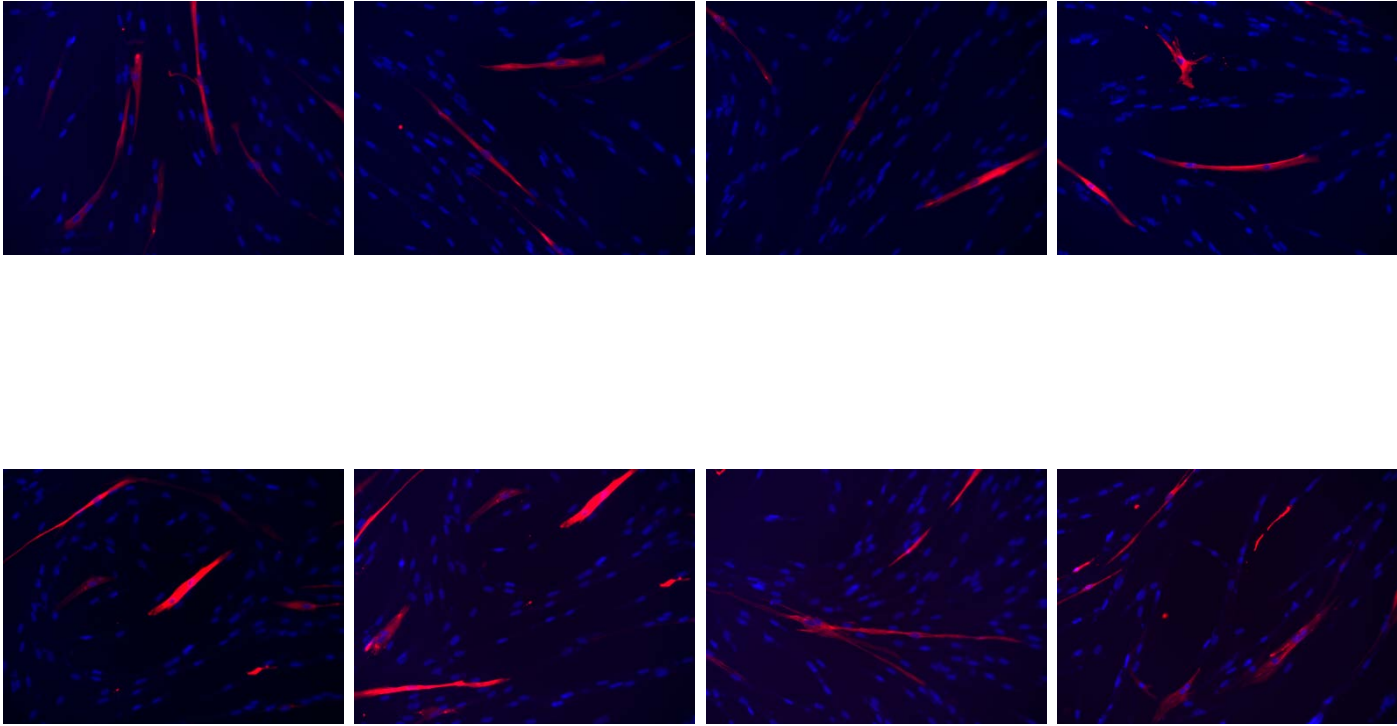
Source data Figure 1, M and N  
(immortalized FSHD#2 myoblasts)



**Figure S6**

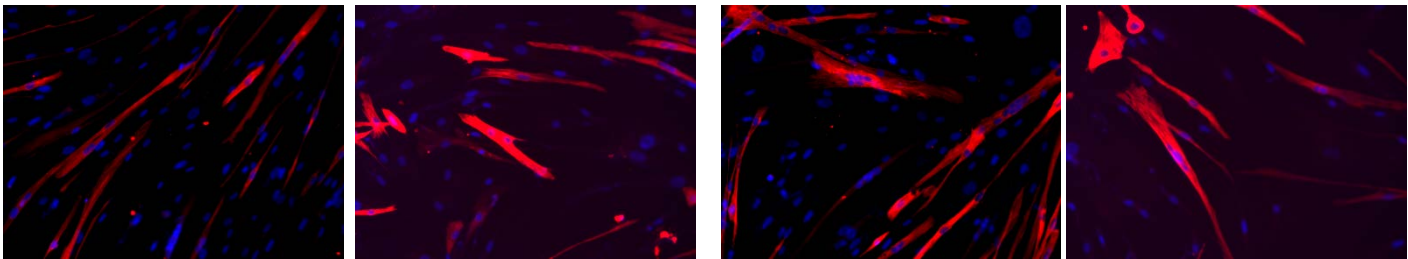
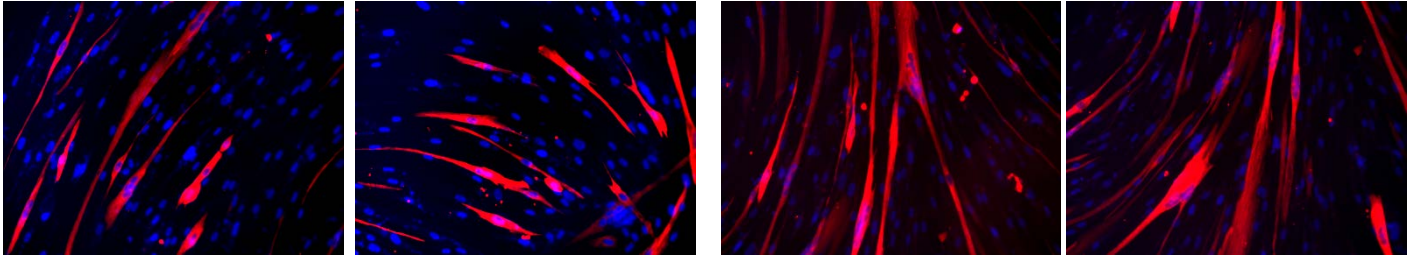
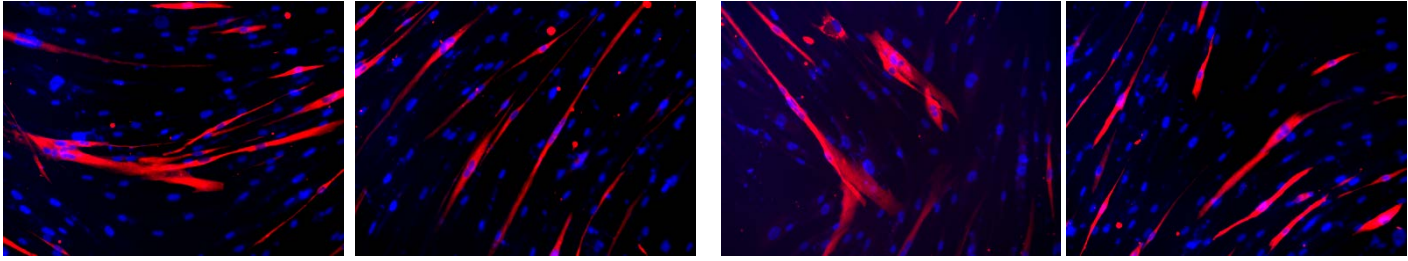
Source data Figure 1, M and N

(immortalized FSHD#2 myoblasts +E<sub>2</sub>)



**Figure S6**

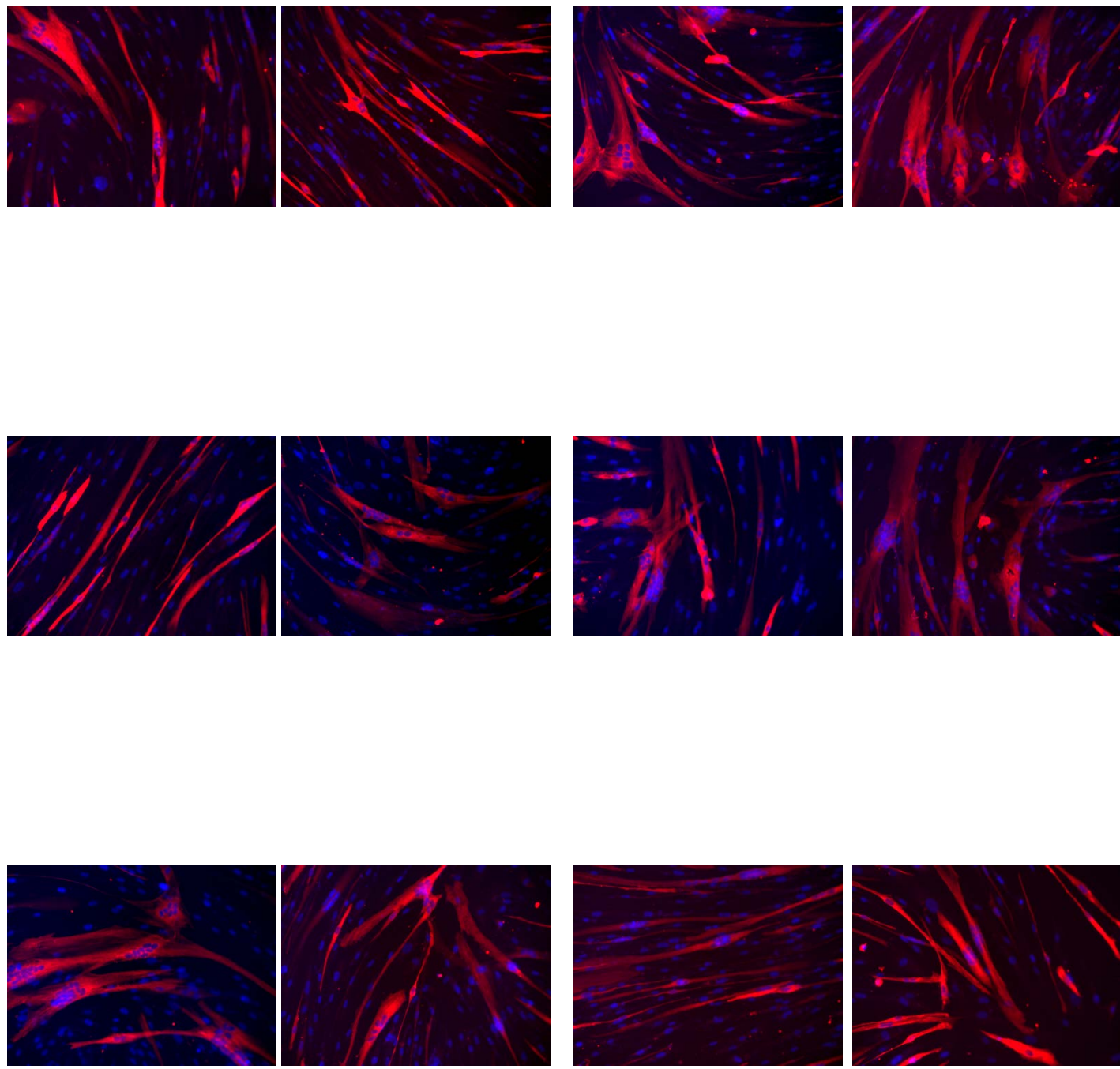
Source data Figure 1, M and N  
(immortalized FSHD#3 myoblasts)



**Figure S6**

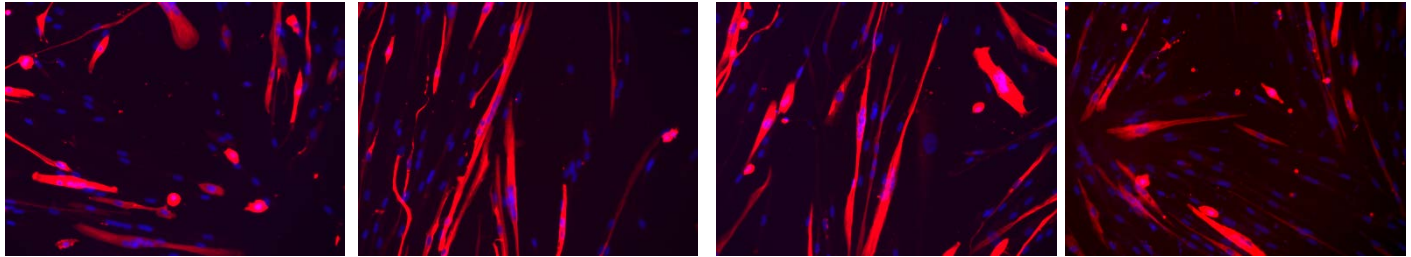
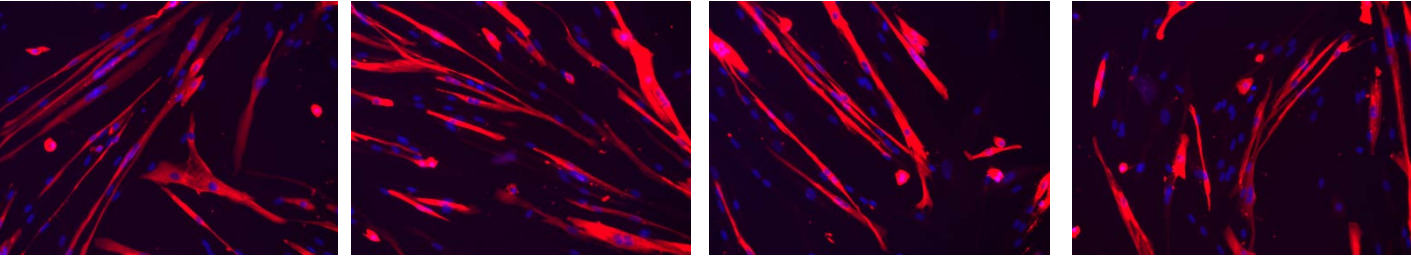
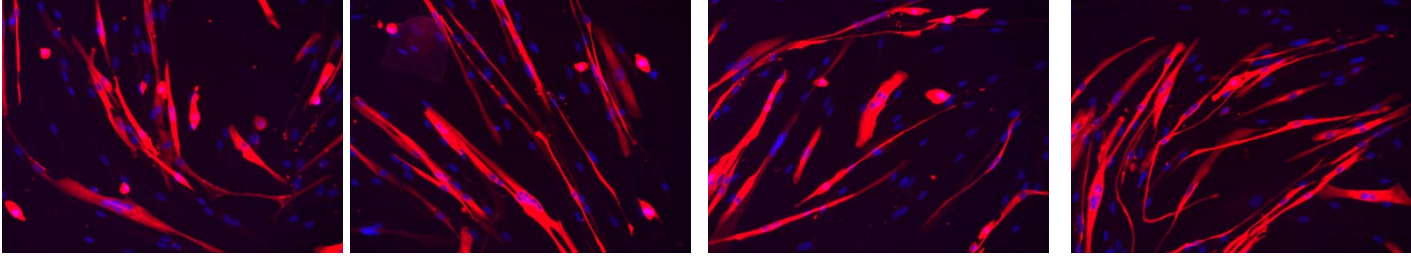
Source data Figure 1, M and N

(immortalized FSHD#3 myoblasts +E<sub>2</sub>)



**Figure S6**

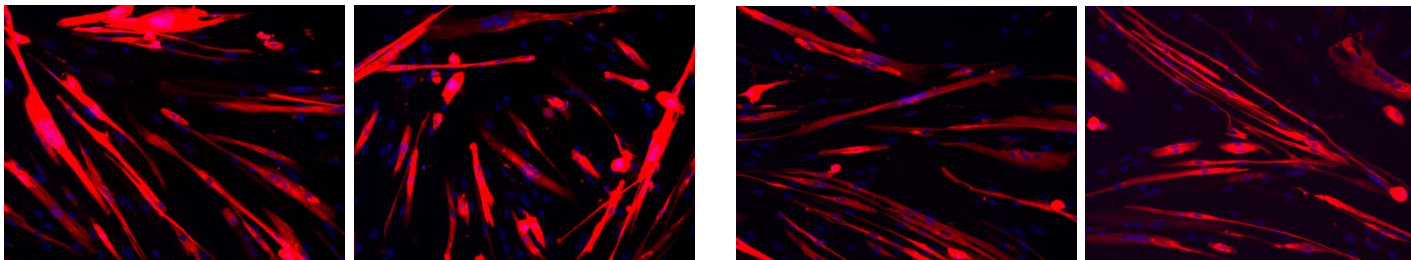
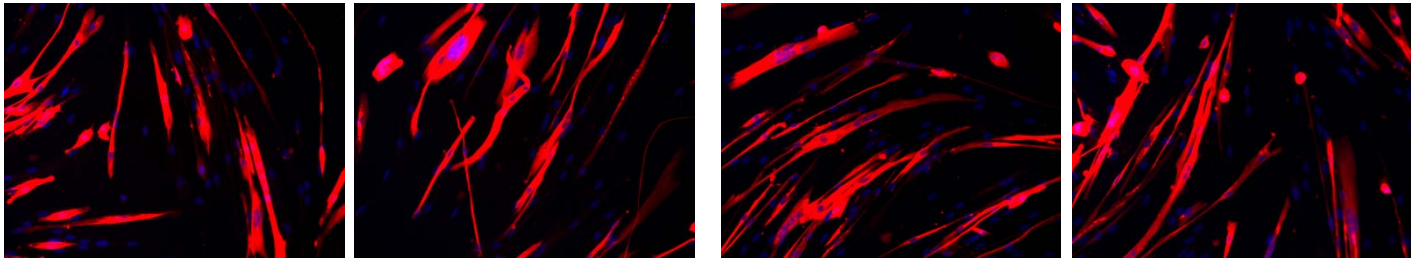
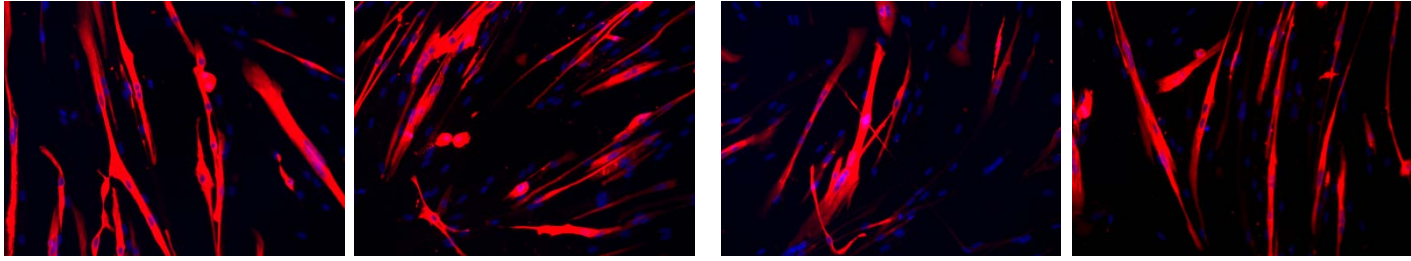
Source data Figure 1, M and N  
(immortalized FSHD#4 myoblasts)



**Figure S6**

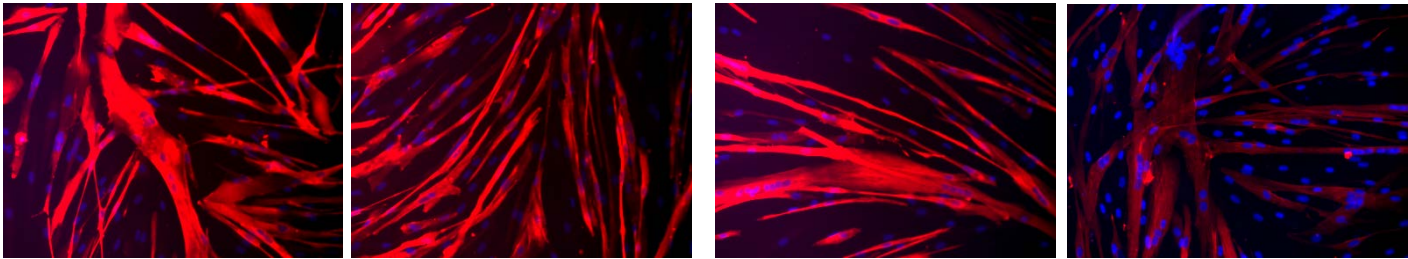
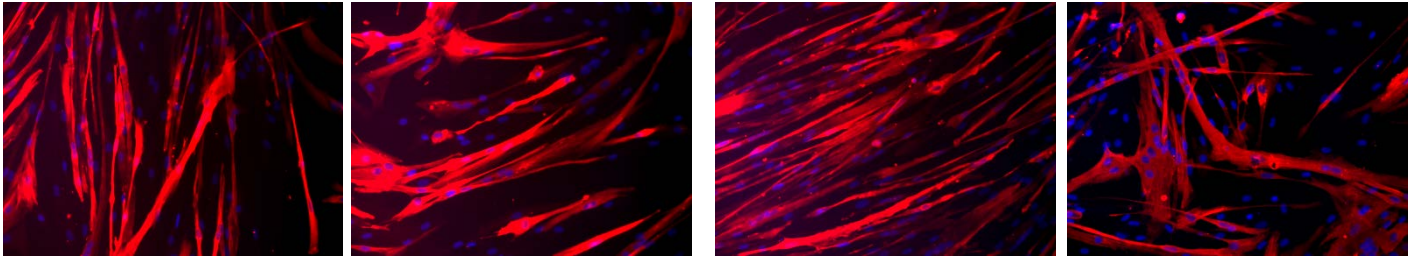
Source data Figure 1, M and N

(immortalized FSHD#4 myoblasts +E<sub>2</sub>)



**Figure S6**

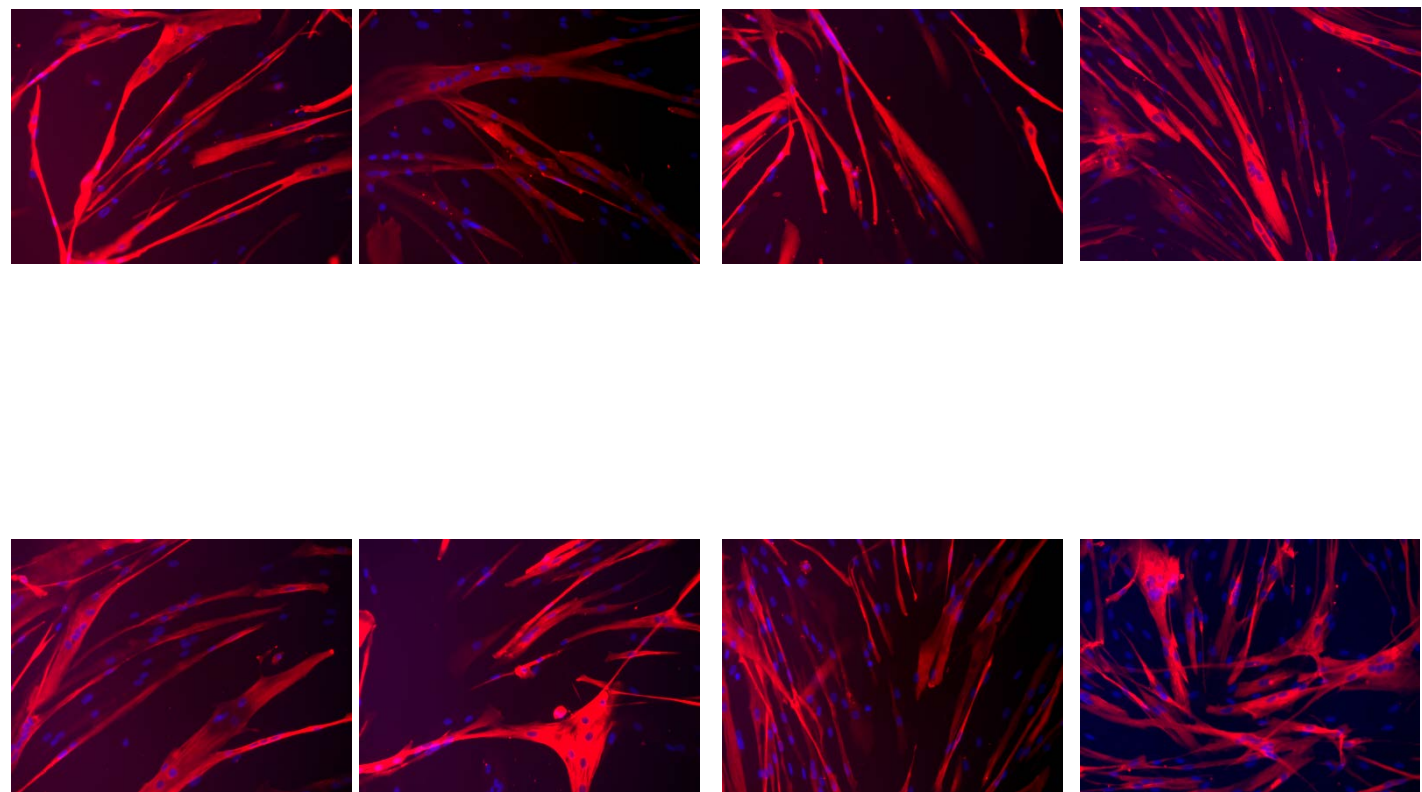
Source data Figure 1, M and N  
(immortalized CTL#1 myoblasts)





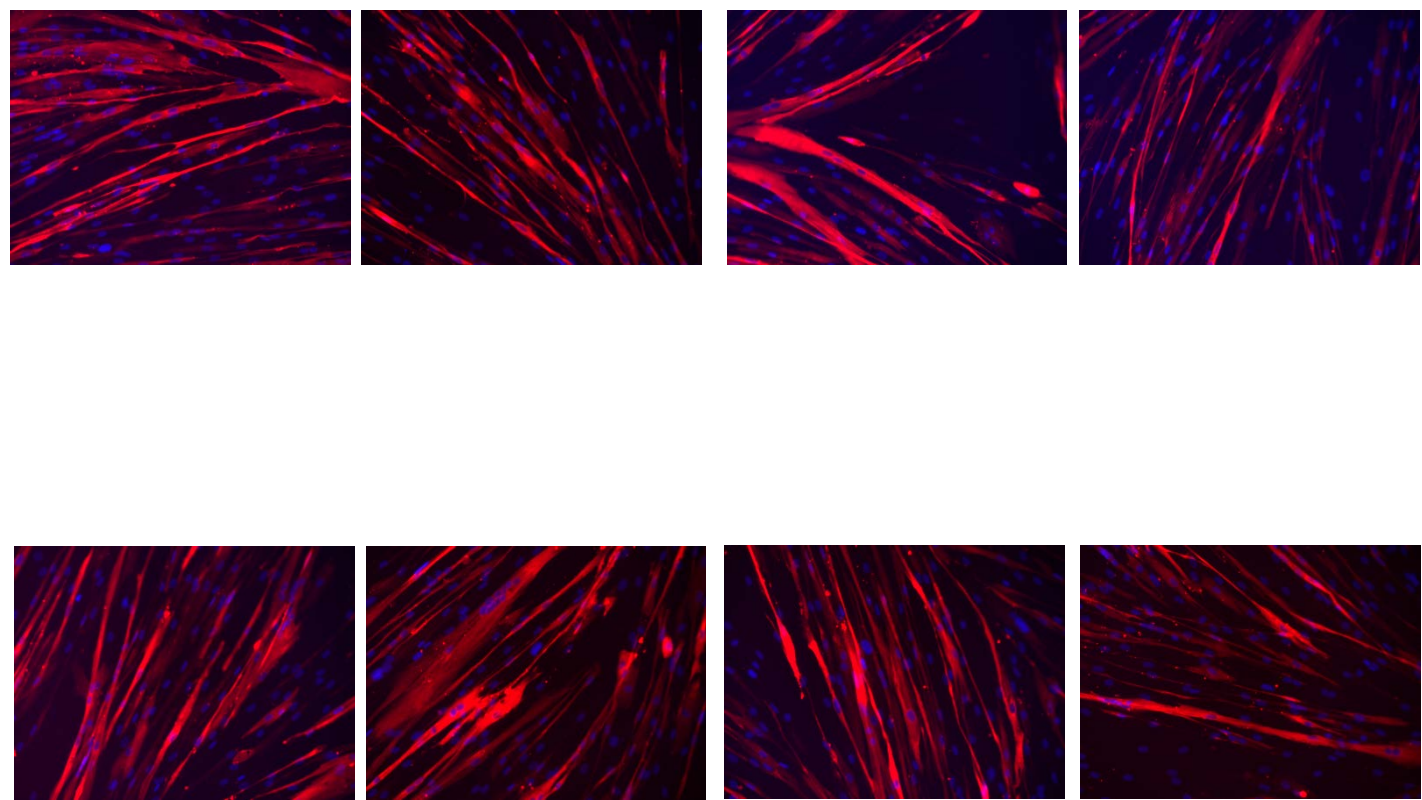
**Figure S6**

Source data Figure 1, M and N  
(immortalized CTL#1 myoblasts +E<sub>2</sub>)



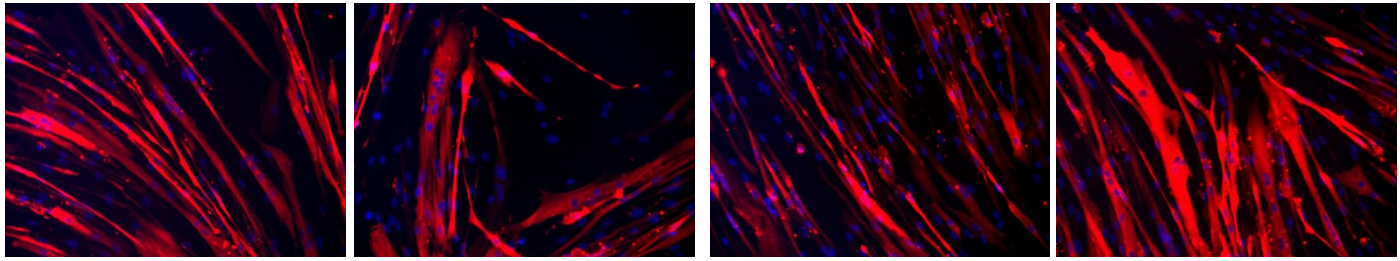
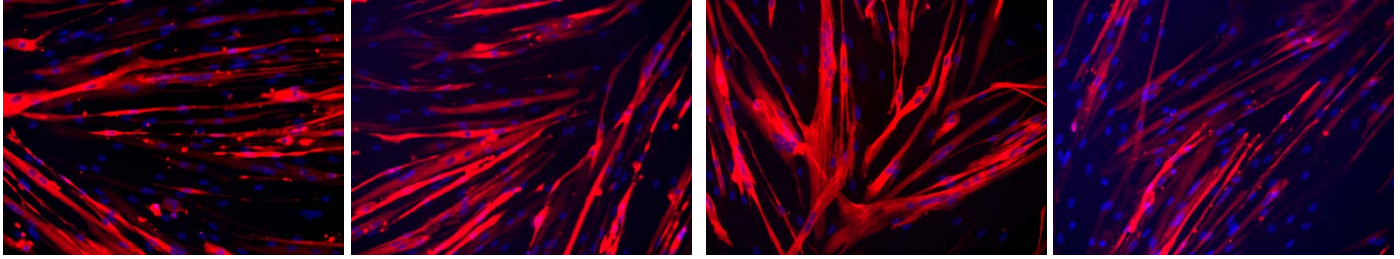
**Figure S6**

Source data Figure 1, M and N  
(immortalized CTL#2 myoblasts)



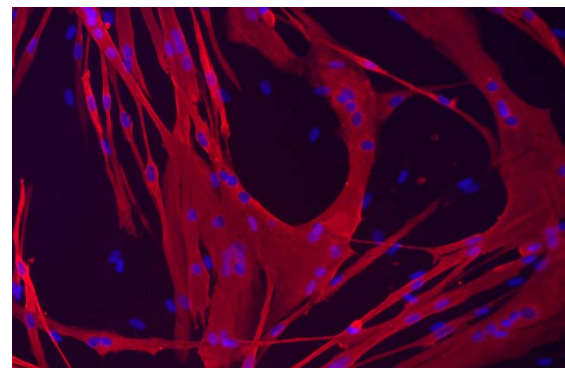
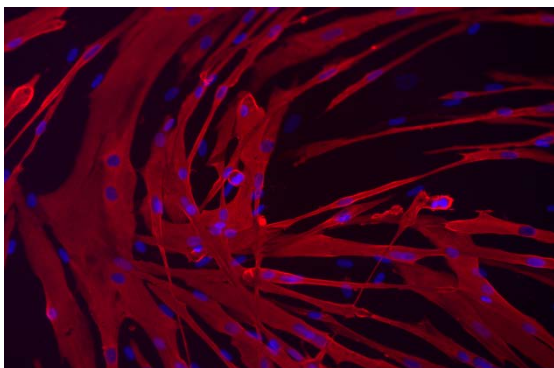
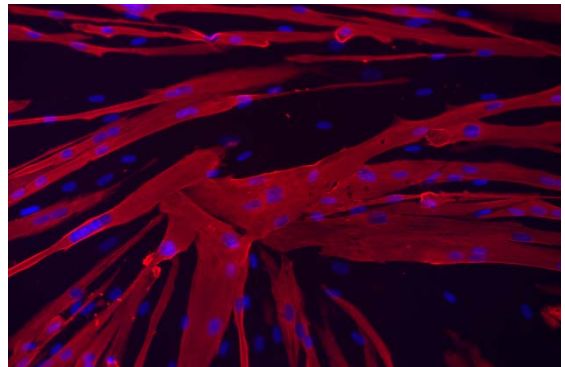
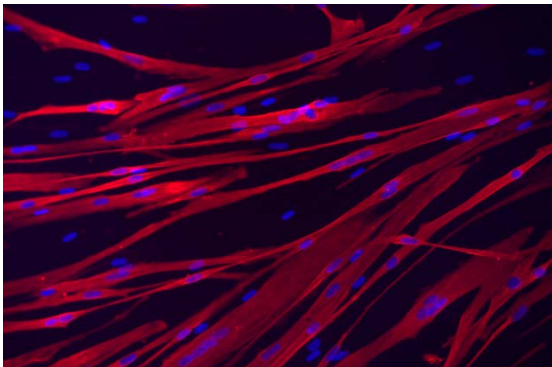
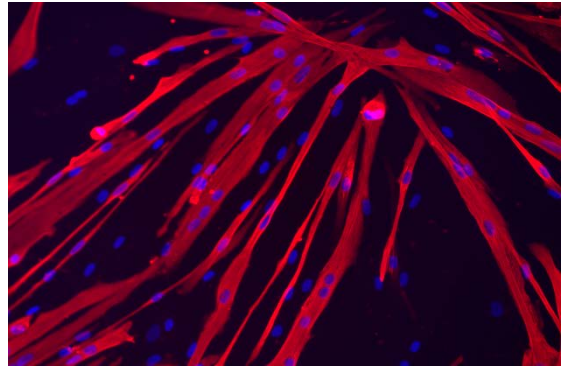
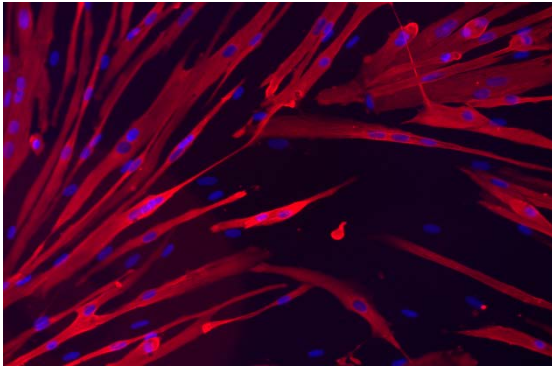
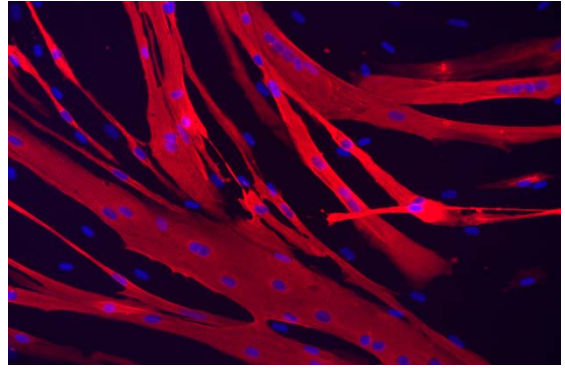
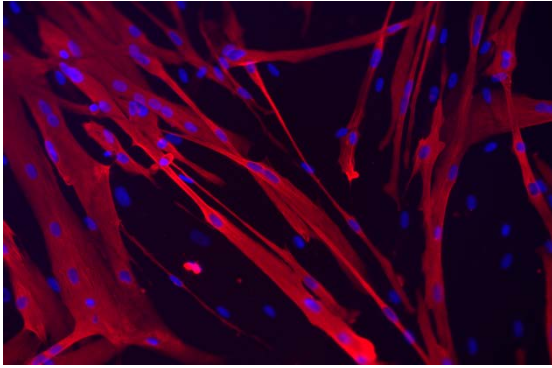
**Figure S6**

Source data Figure 1, M and N  
(immortalized CTL#2 myoblasts +E<sub>2</sub>)



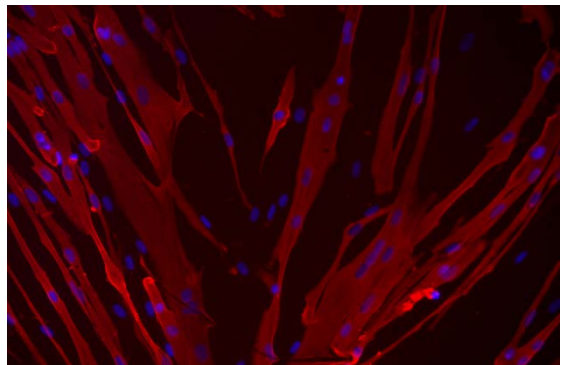
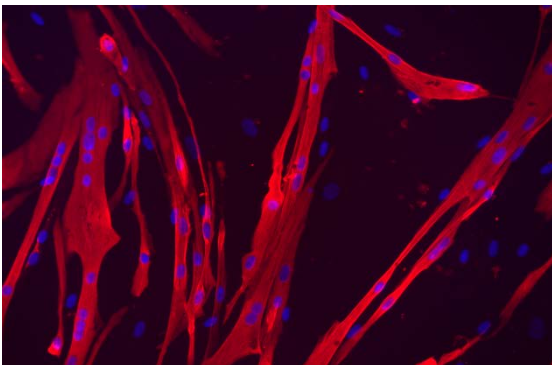
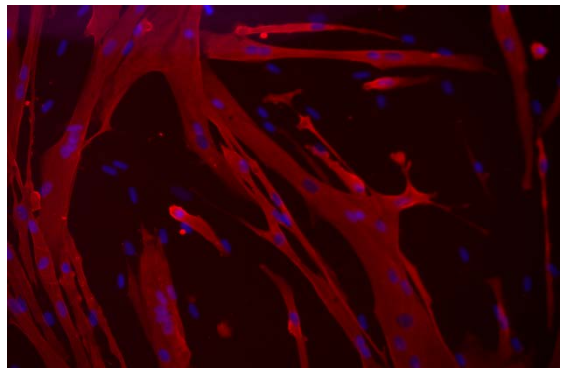
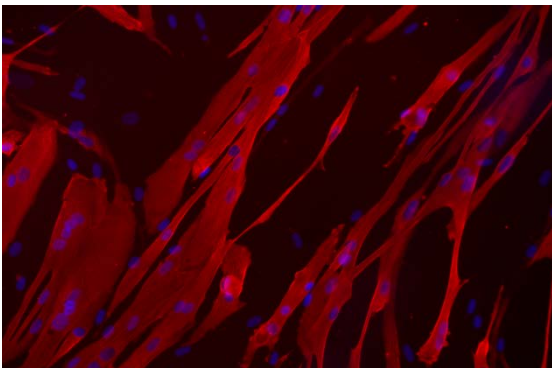
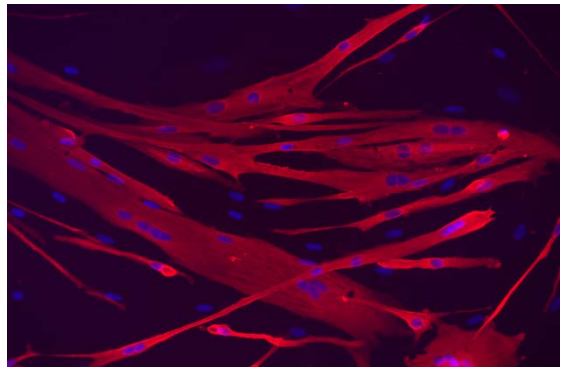
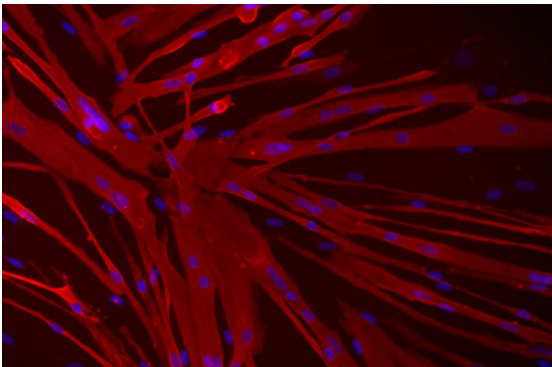
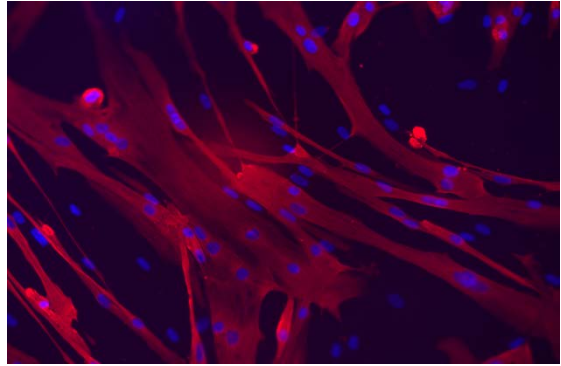
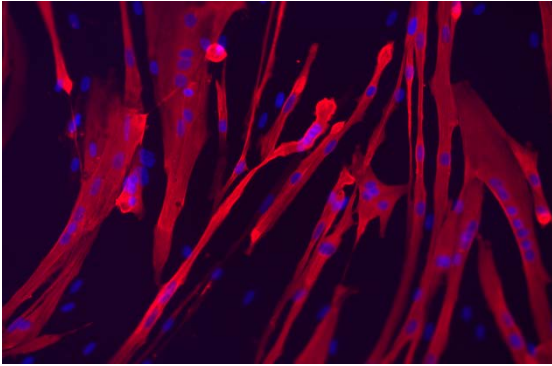
**Figure S6**

Source data Figure 2, A and B  
(primary CTL#14 myoblasts)



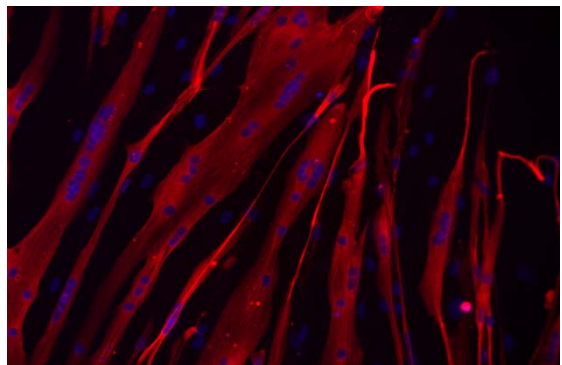
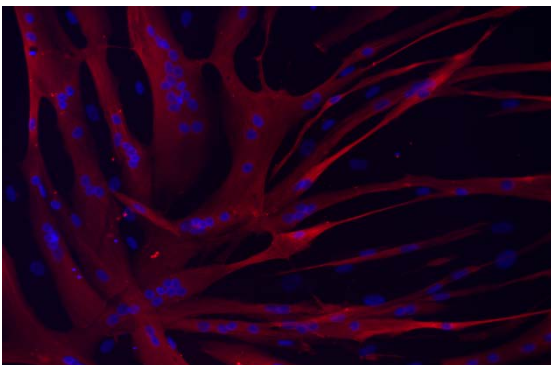
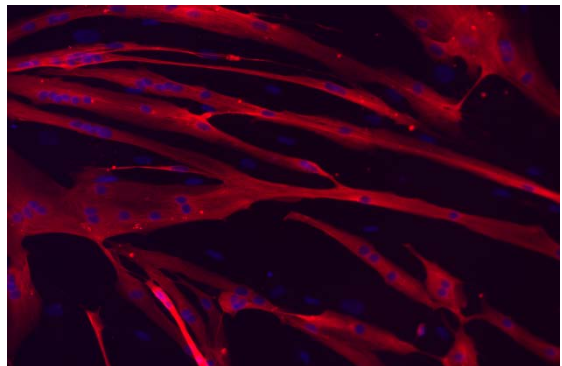
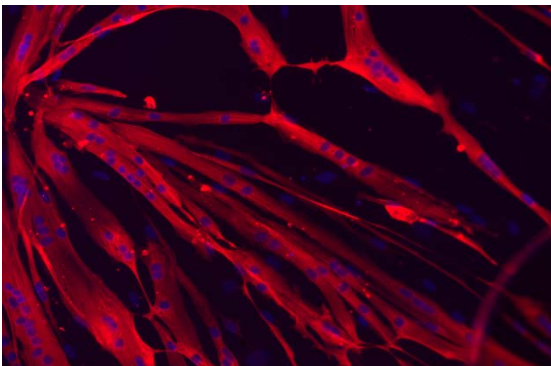
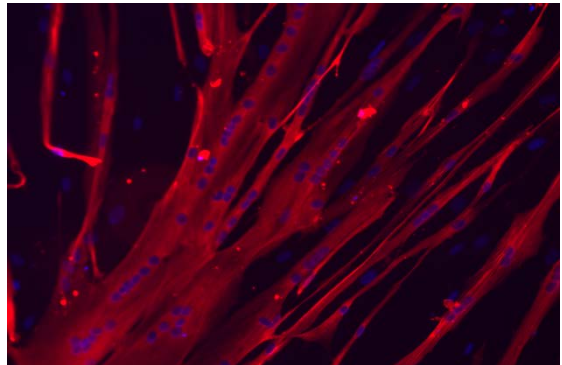
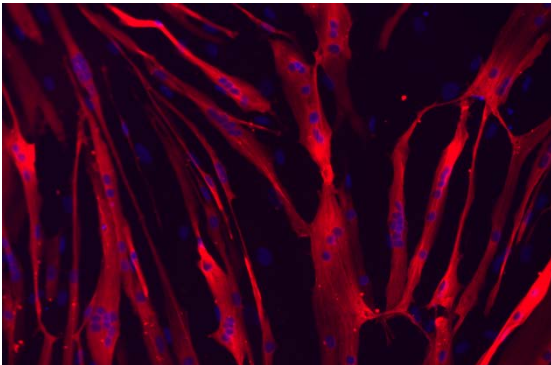
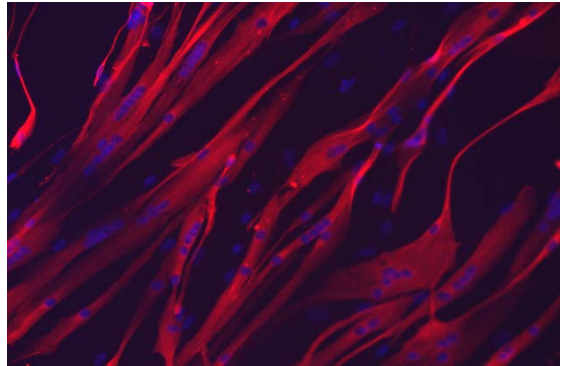
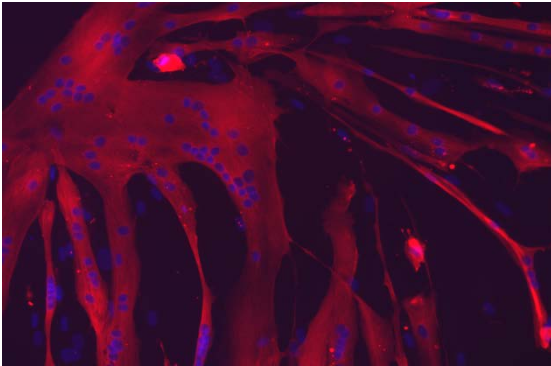
**Figure S6**

Source data Figure 2, A and B  
(primary CTL#14 myoblasts +E<sub>2</sub>)



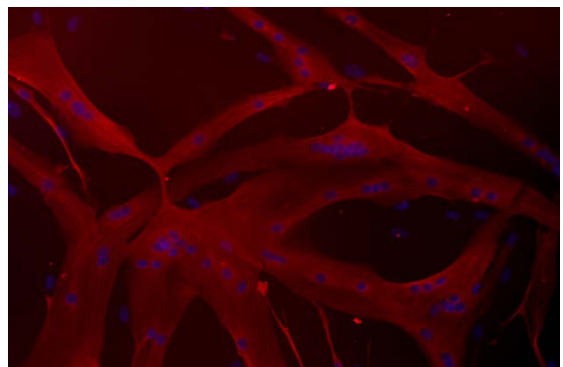
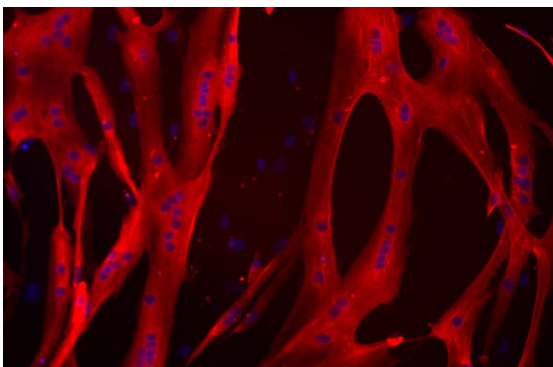
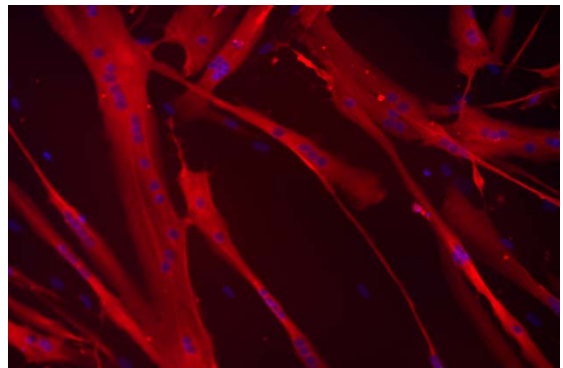
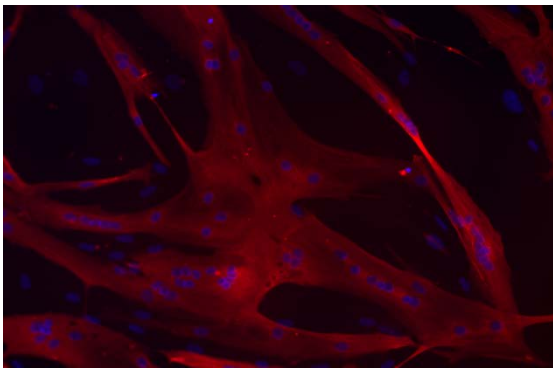
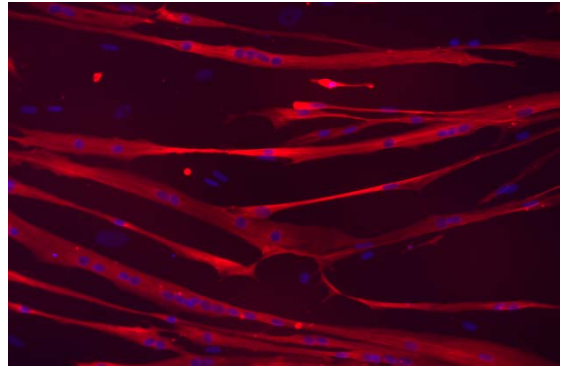
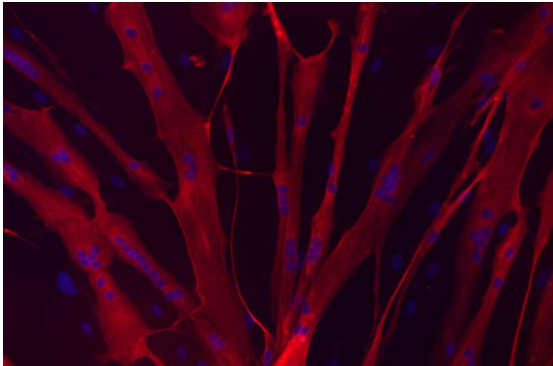
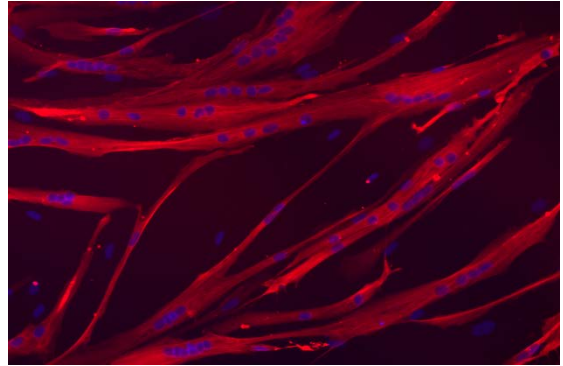
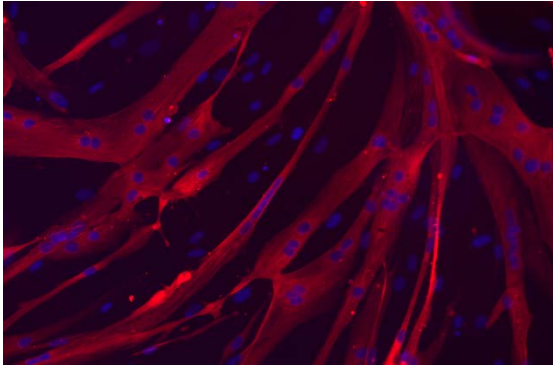
**Figure S6**

Source data Figure 2, A and B  
(03U primary myoblasts)



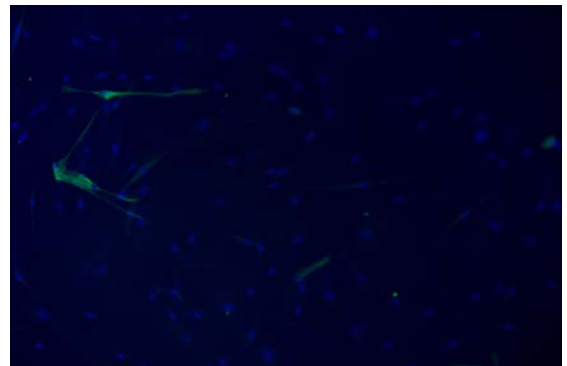

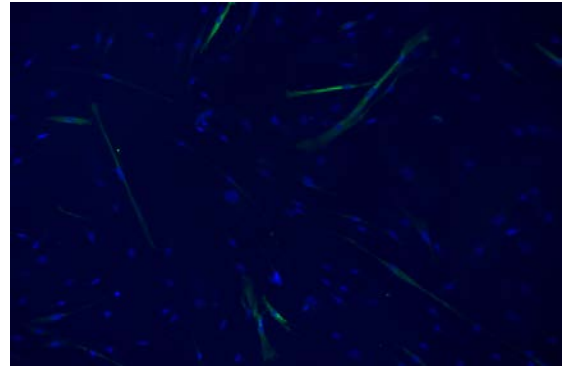
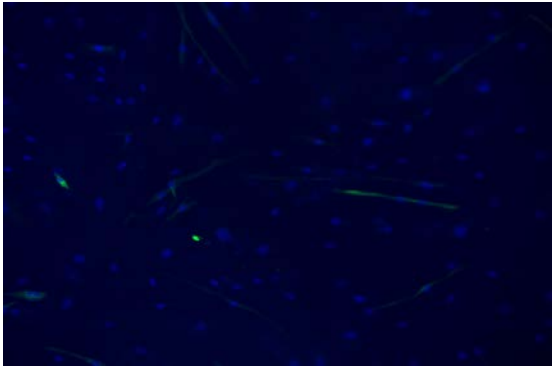
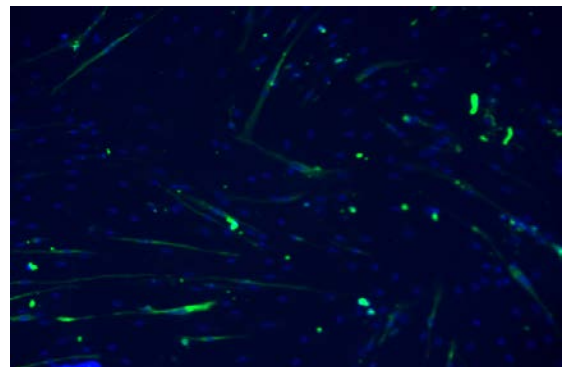
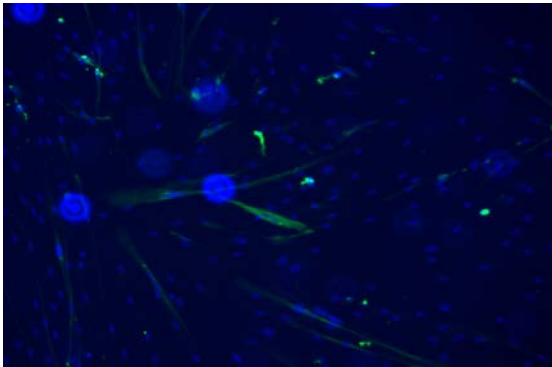
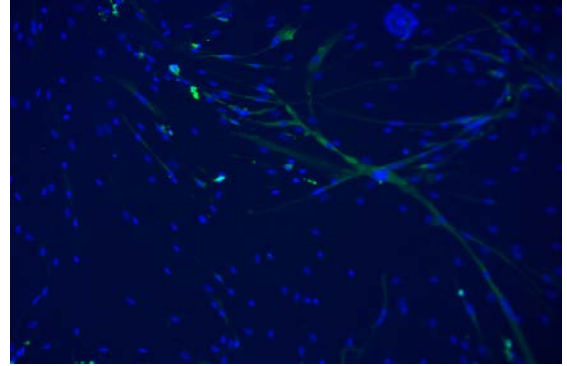
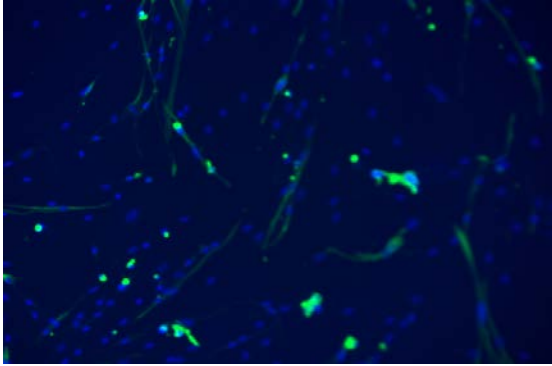
**Figure S6**

Source data Figure 2, A and B  
(03U primary myoblasts +E<sub>2</sub>)



**Figure S6**

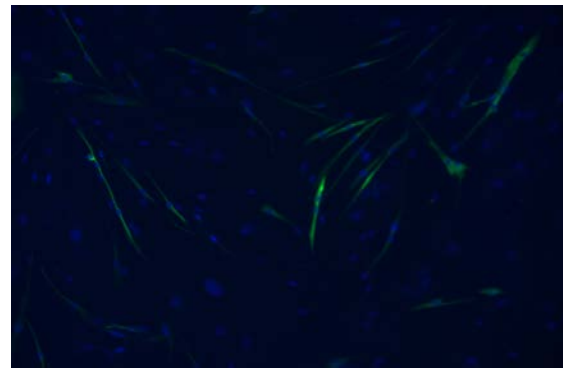
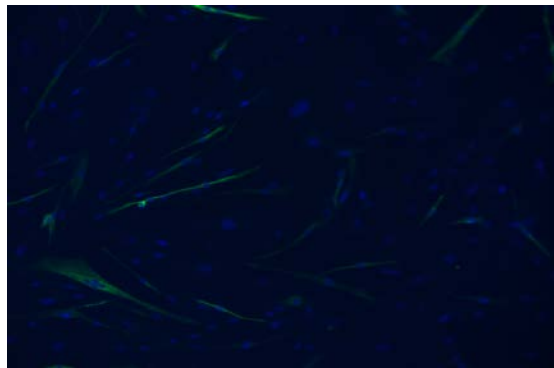
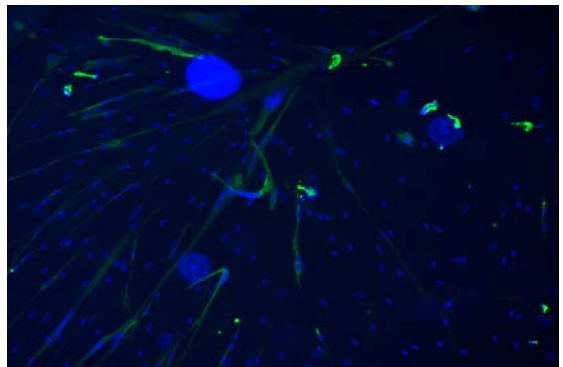
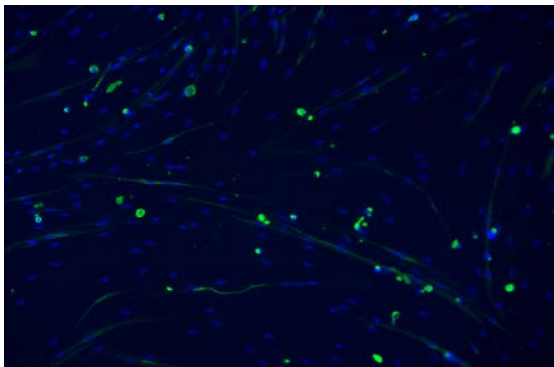
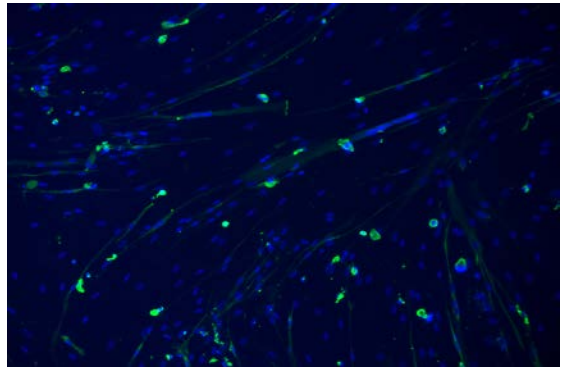
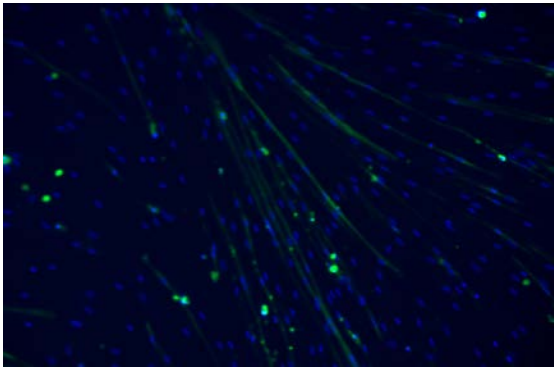
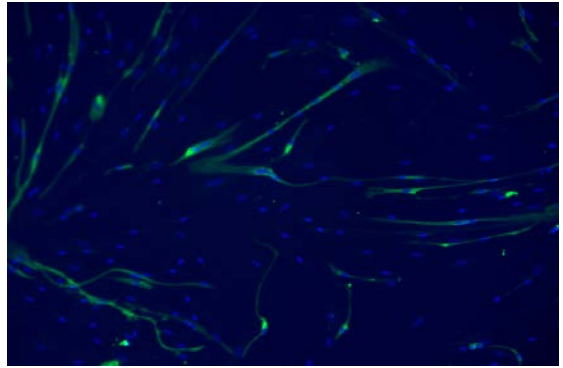
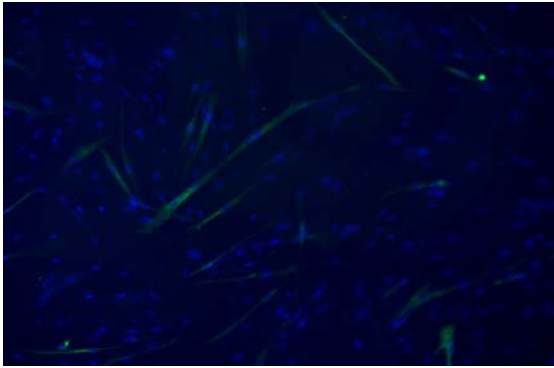
Source data Figure 2, A and B  
(primary FSHD#2 myoblasts)





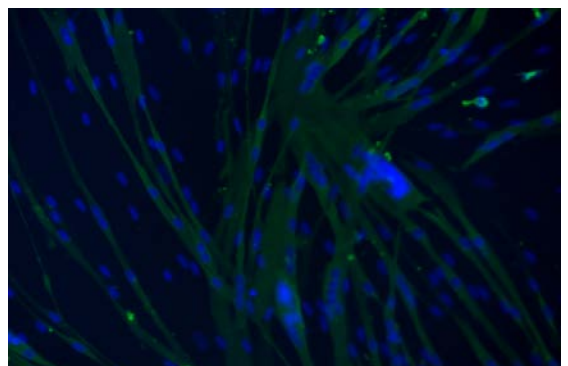
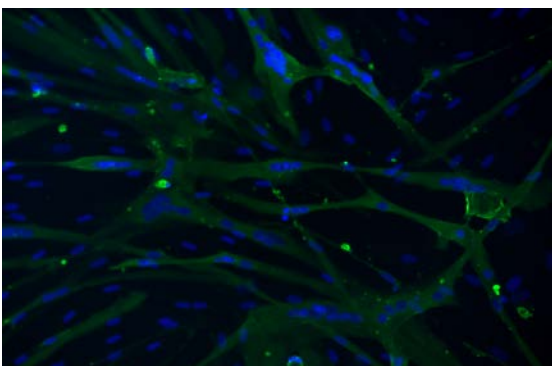
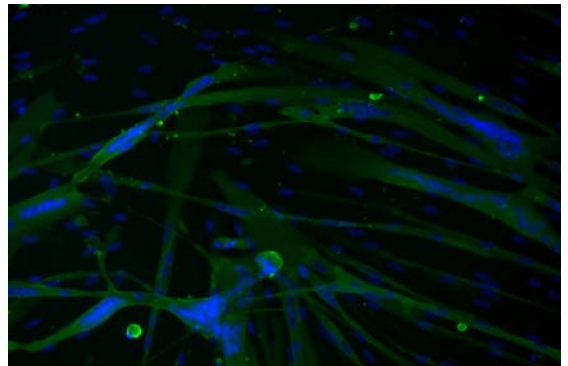
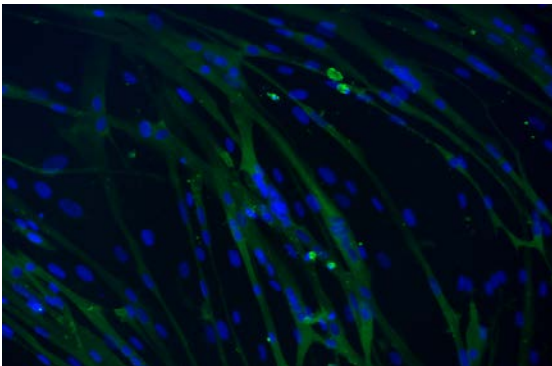
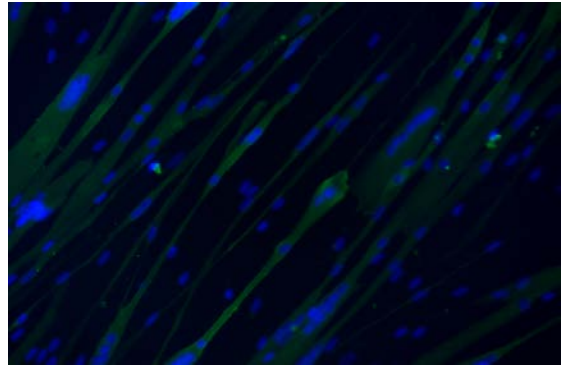
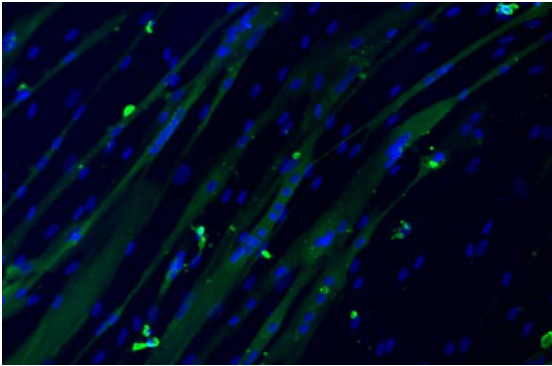
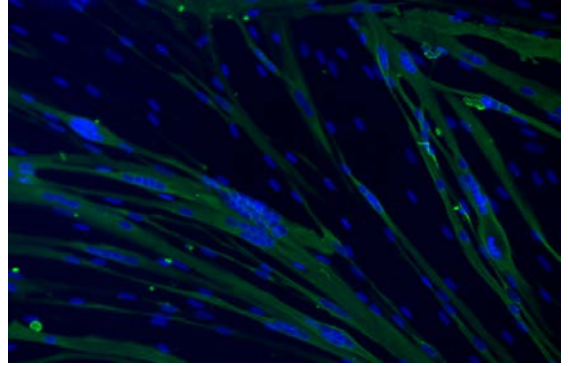
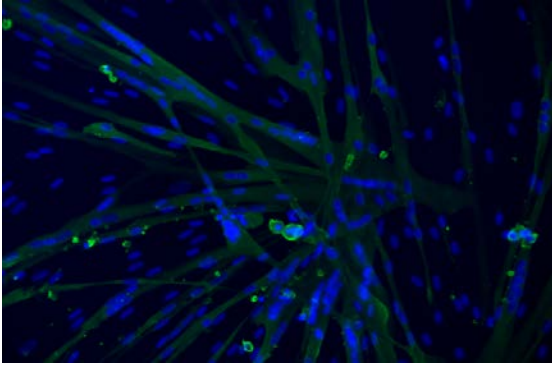
**Figure S6**

Source data Figure 2, A and B  
(primary FSHD#2 myoblasts +E<sub>2</sub>)



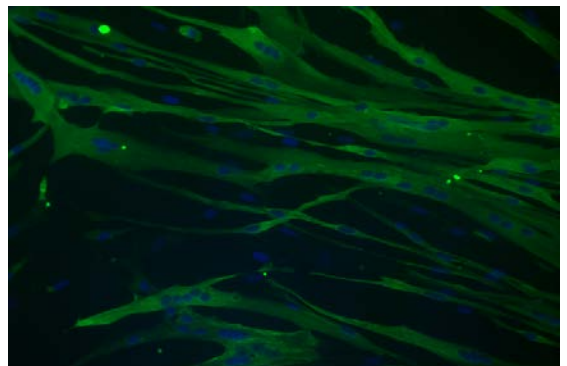
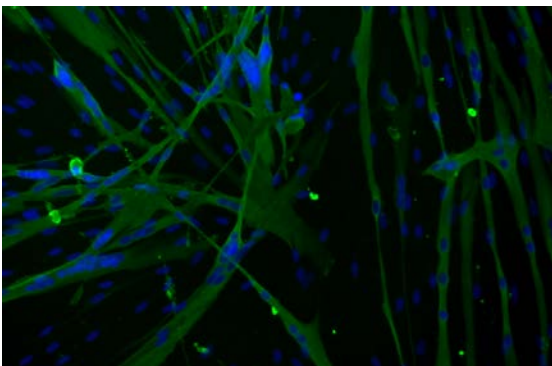
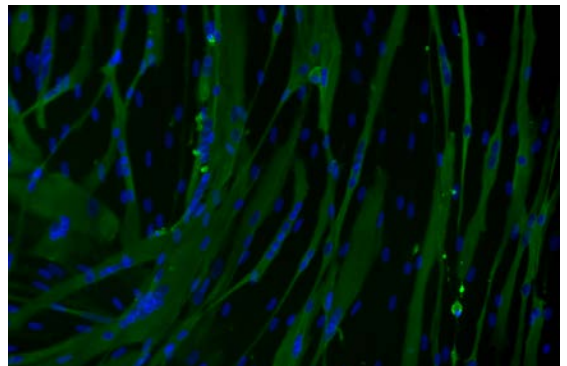
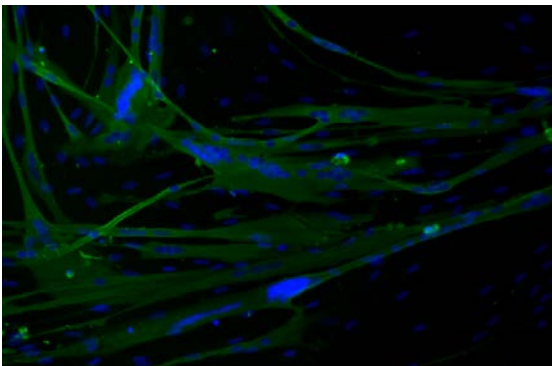
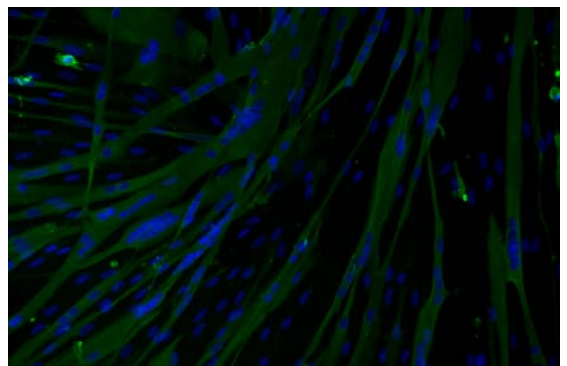
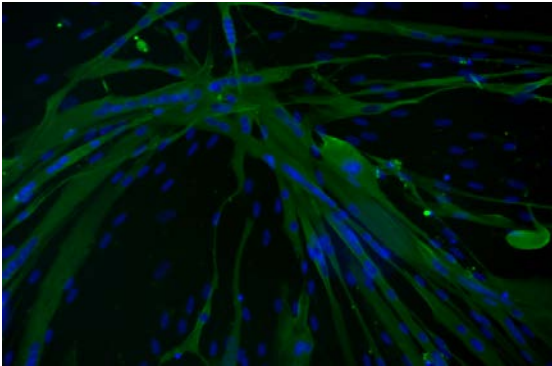
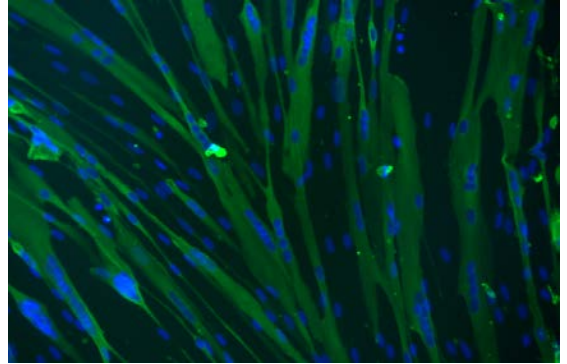
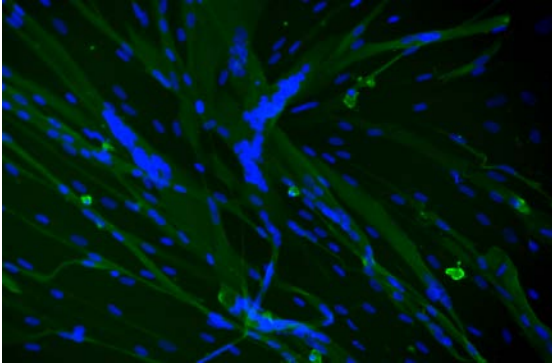
**Figure S6**

Source data Figure 2, A and B  
(primary FSHD#3 myoblasts)



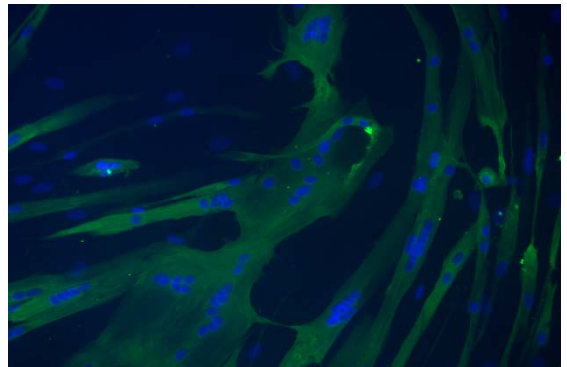
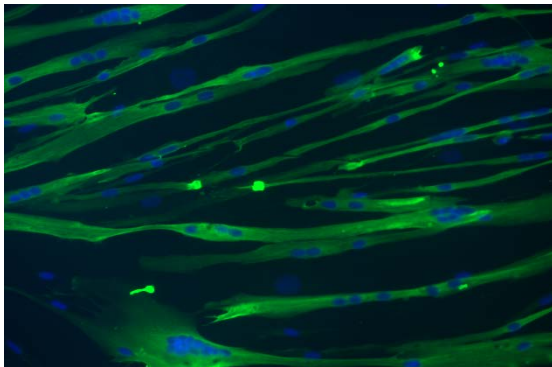
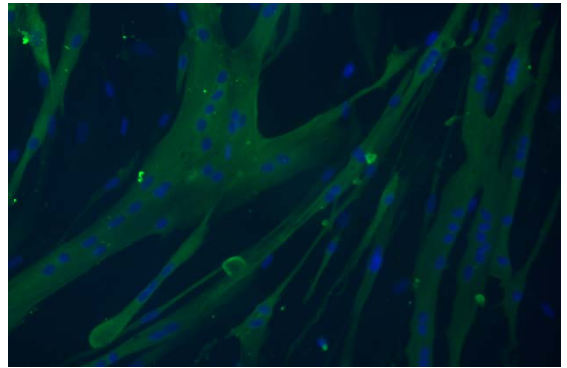
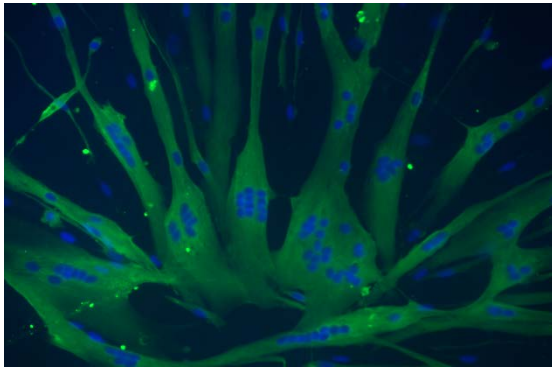
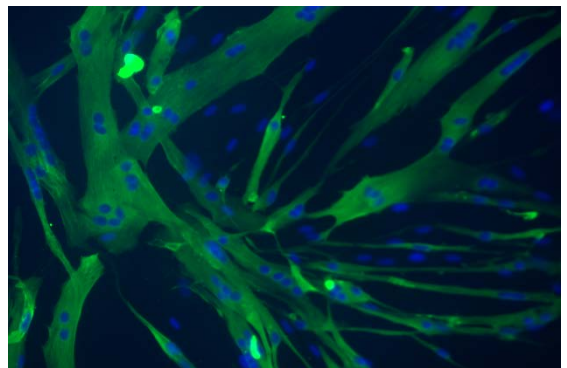
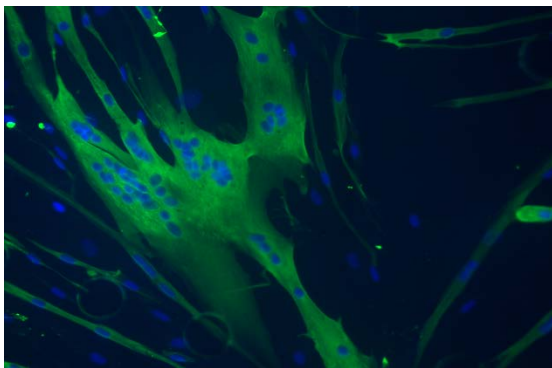
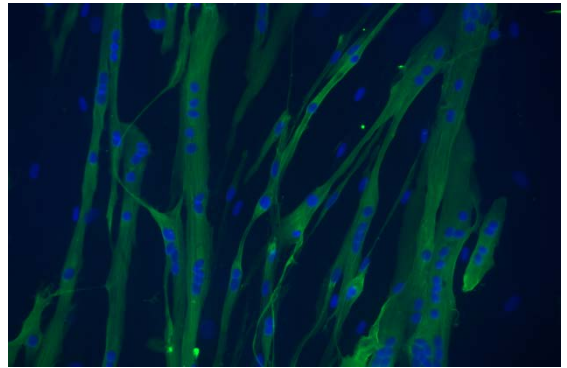
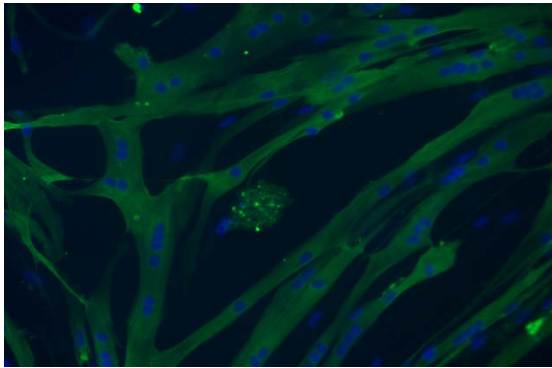
**Figure S6**

Source data Figure 2, A and B  
(primary FSHD#3 myoblasts +E<sub>2</sub>)



**Figure S6**

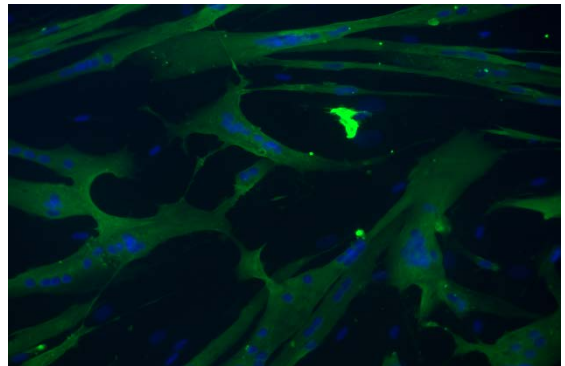
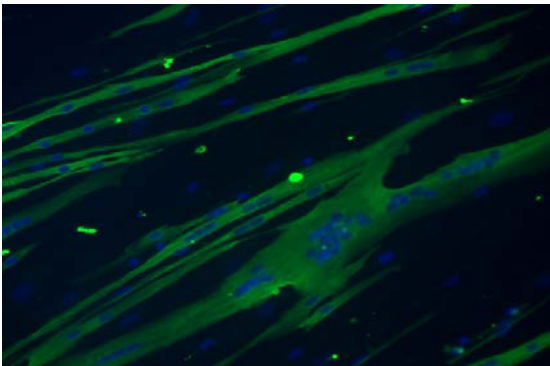
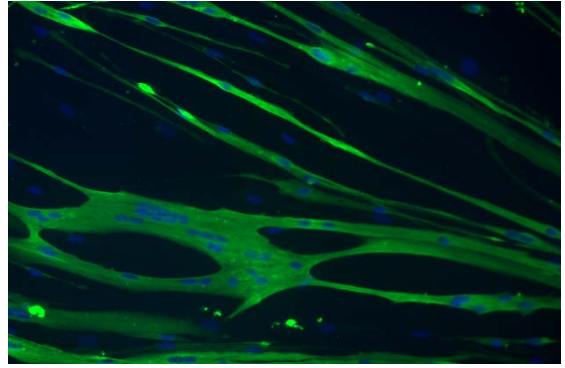
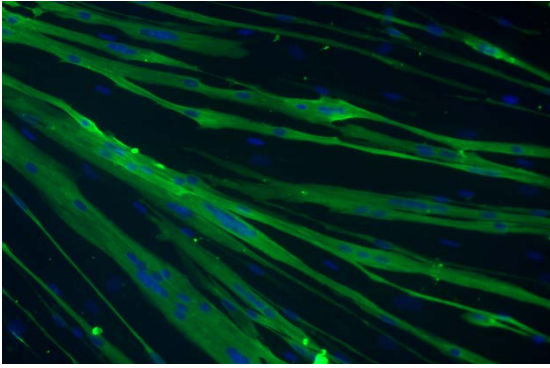
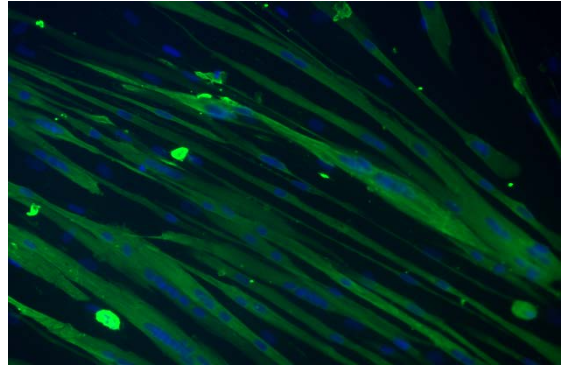
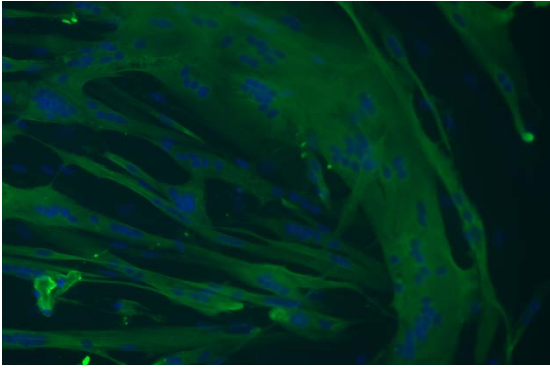
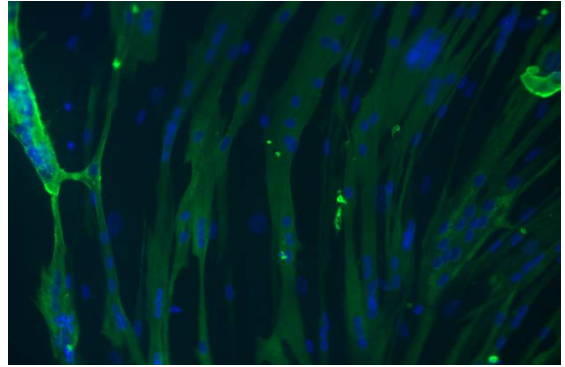
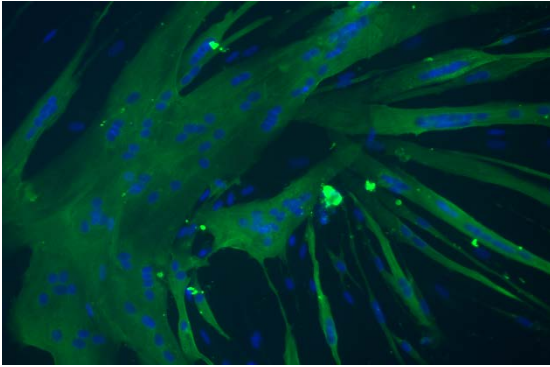
Source data Figure 2, A and B  
(primary FSHD#4 myoblasts)



**Figure S6**

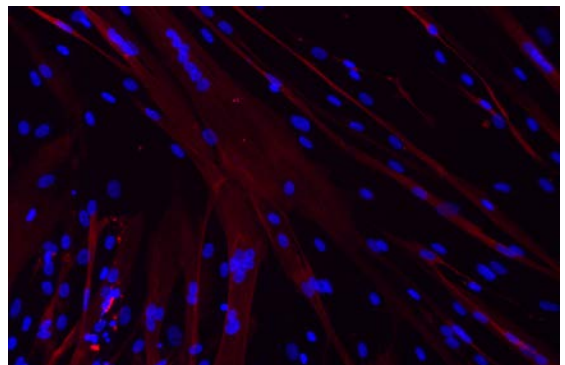
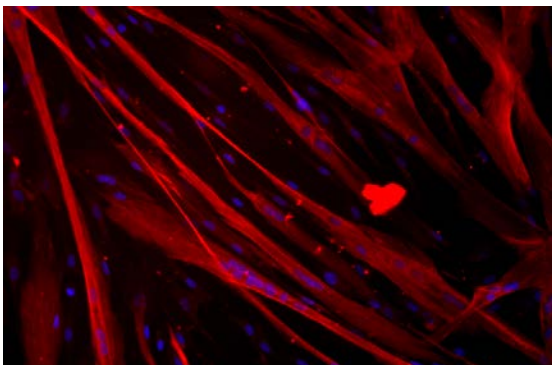
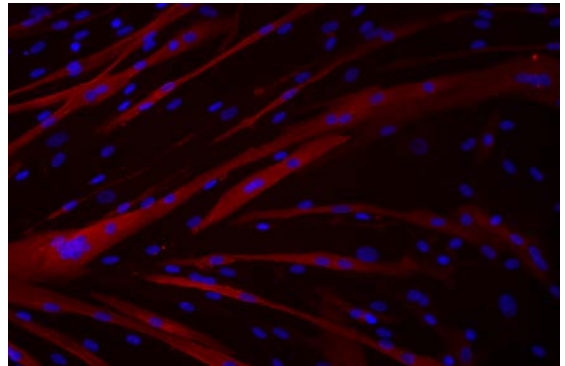
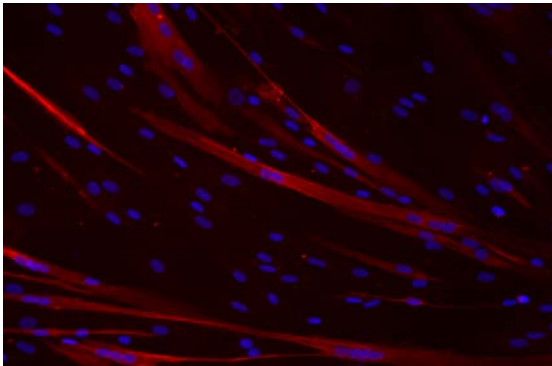
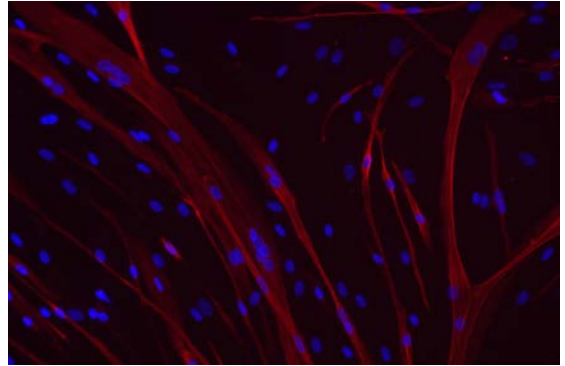
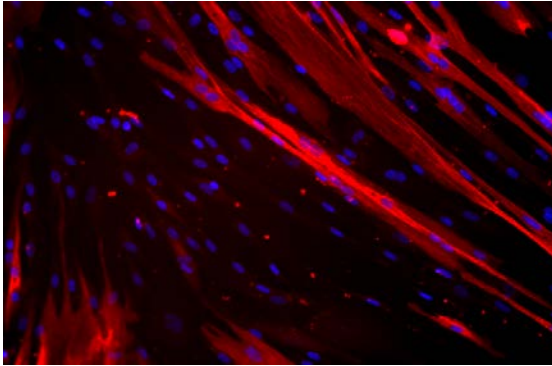
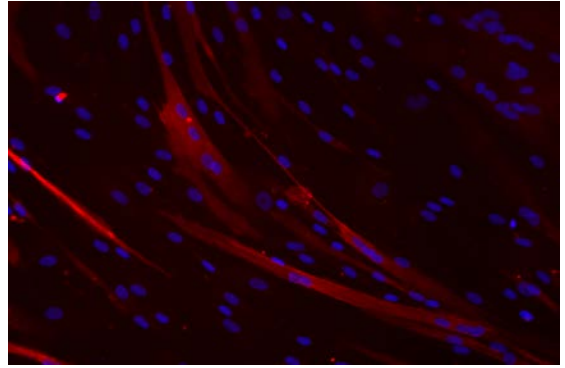
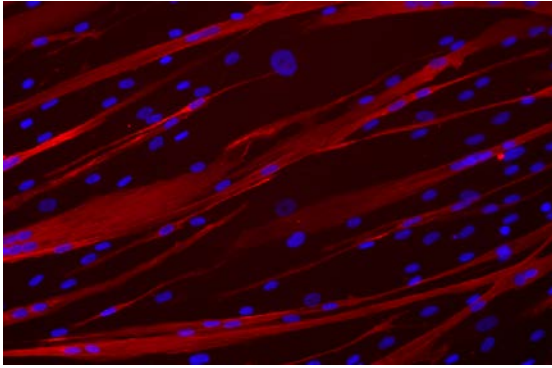
Source data Figure 2, A and B

(primary FSHD#4 myoblasts +E<sub>2</sub>)



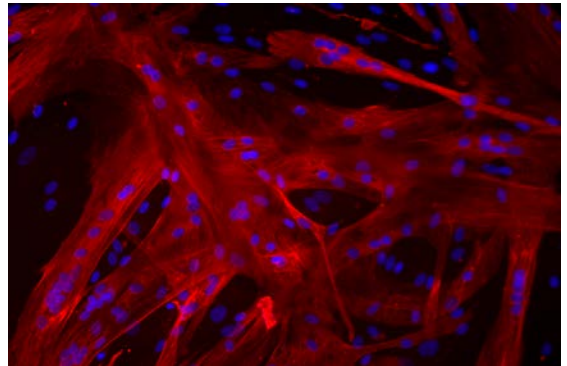
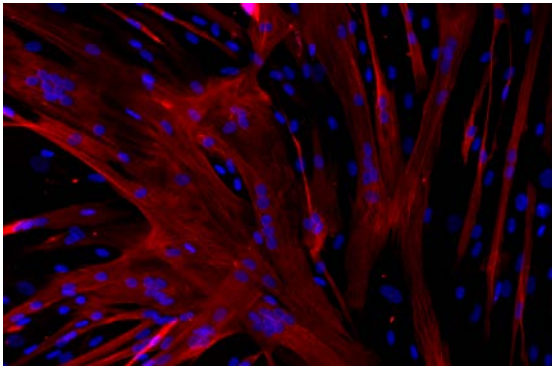
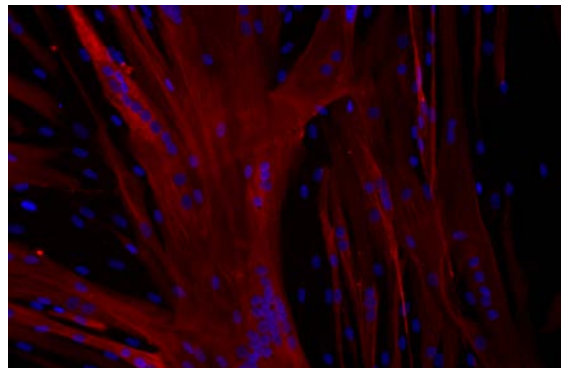
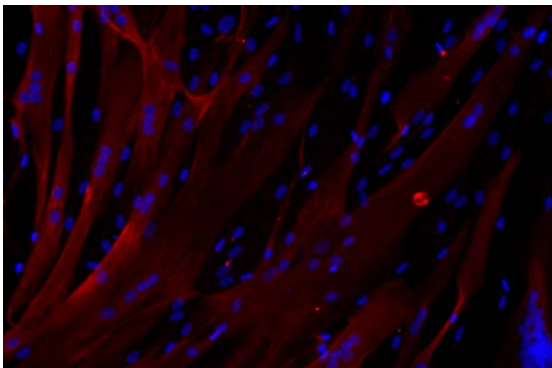
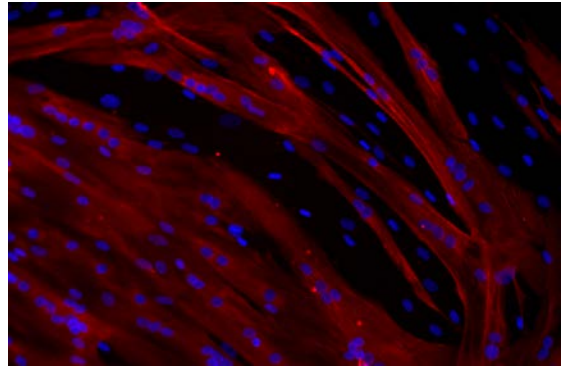
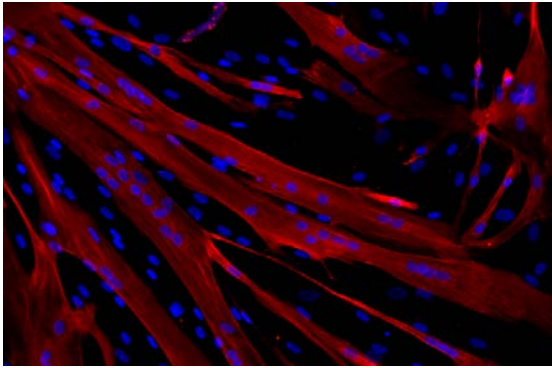
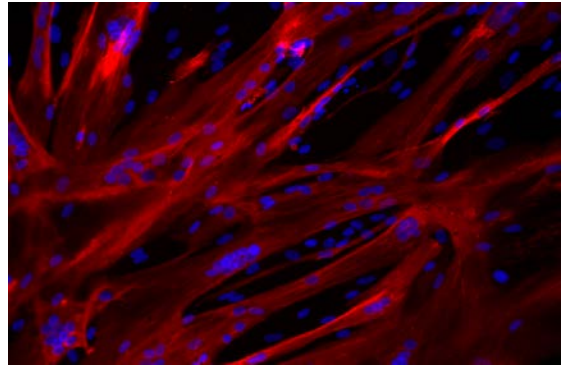
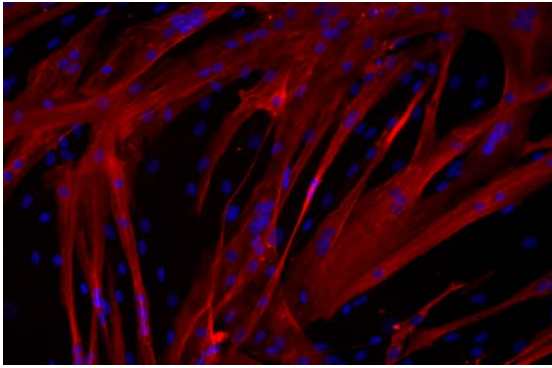
**Figure S6**

Source data Figure 2, A and B  
(primary FSHD#10 myoblasts)



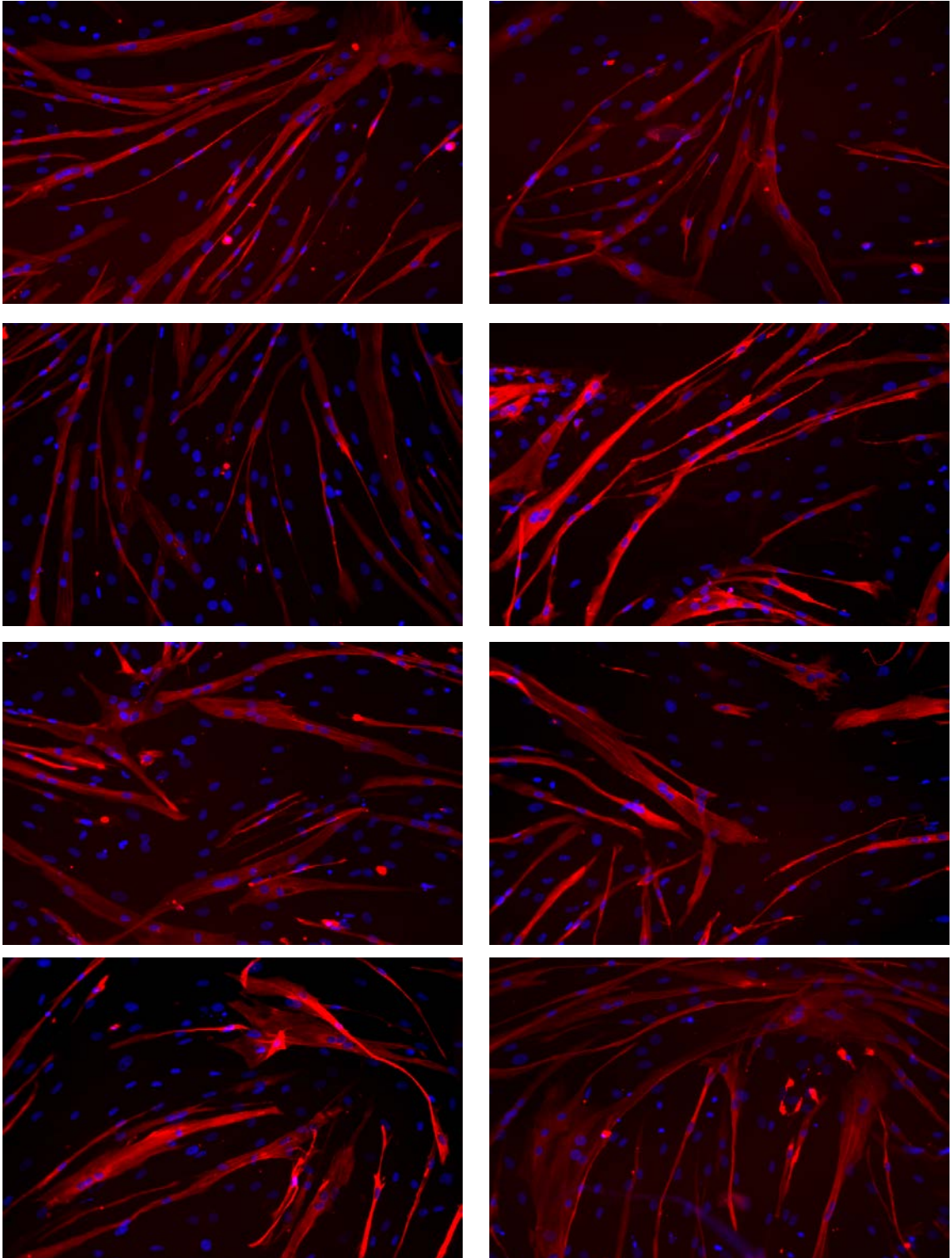
**Figure S6**

Source data Figure 2, A and B  
(primary FSHD#10 myoblasts +E<sub>2</sub>)



**Figure S6**

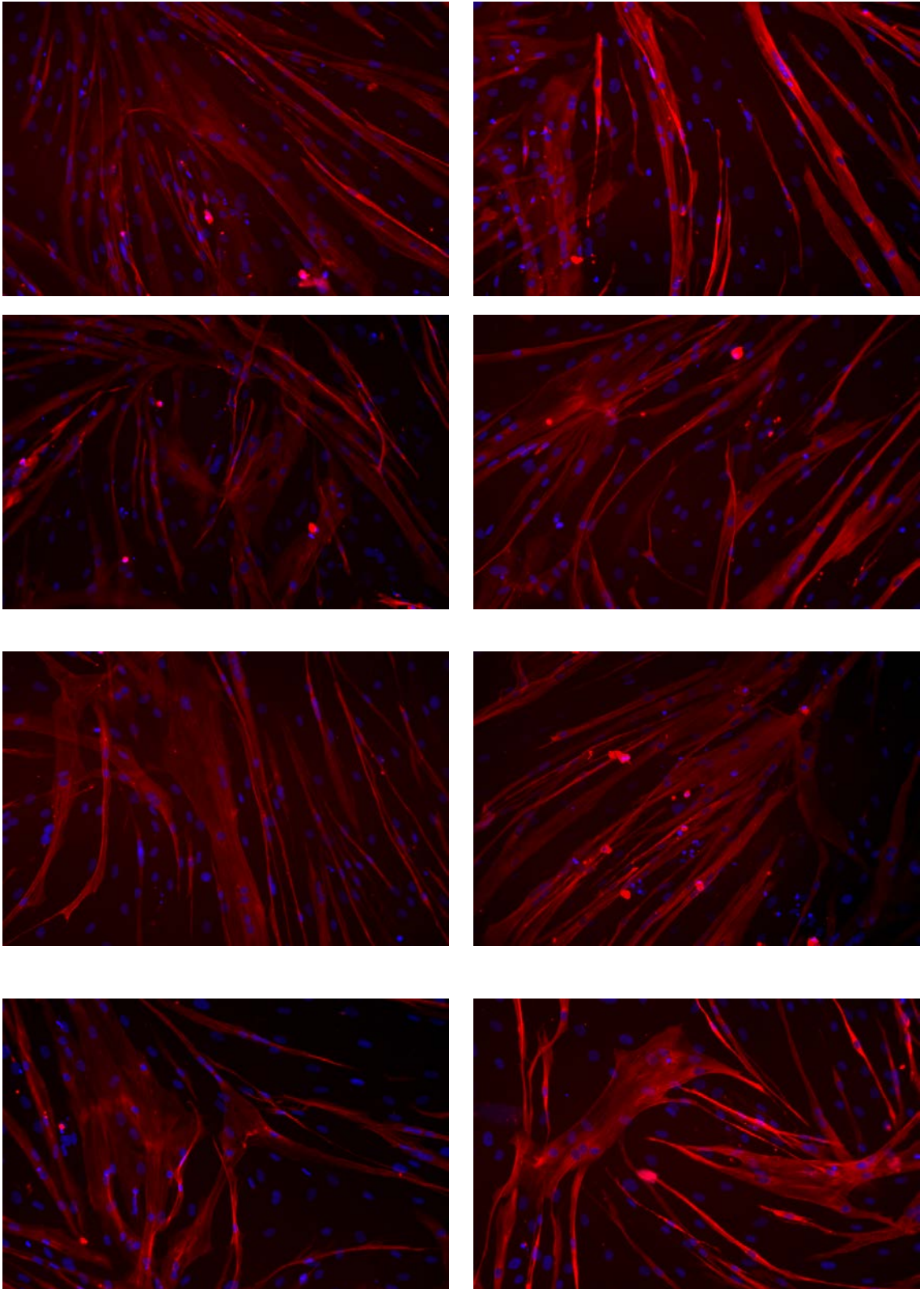
Source data Figure 2, A and B  
(primary FSHD#20 myoblasts)





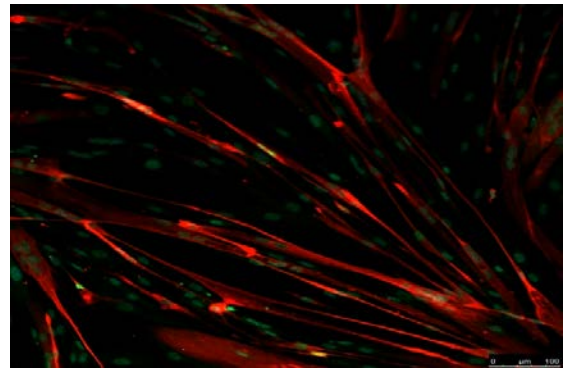
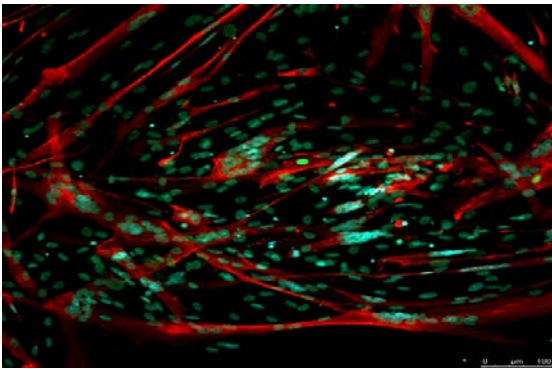
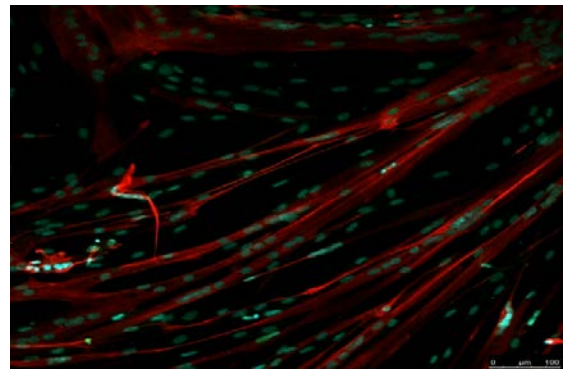
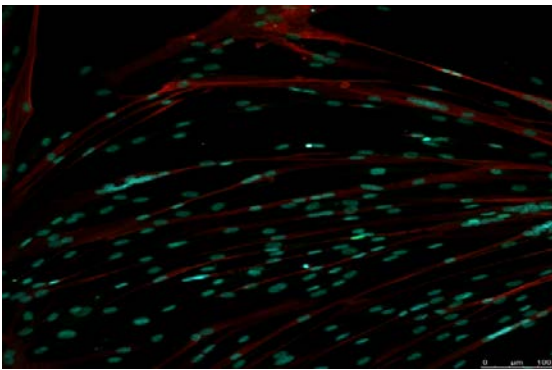
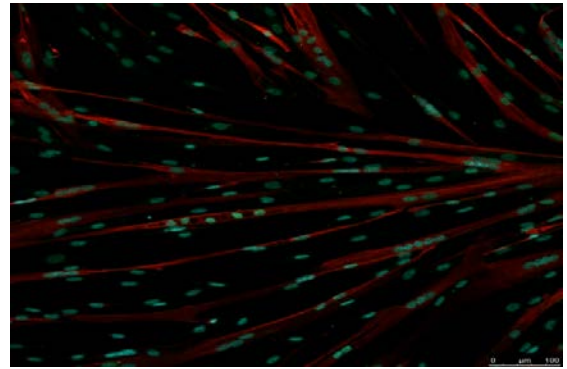
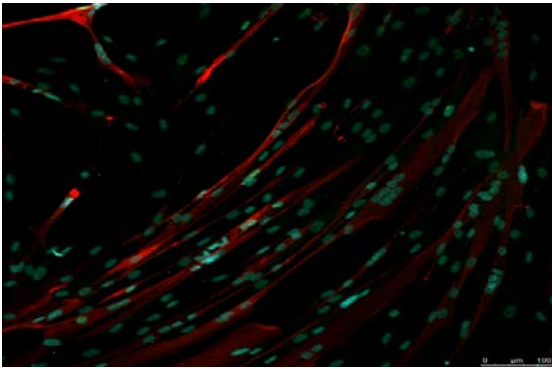
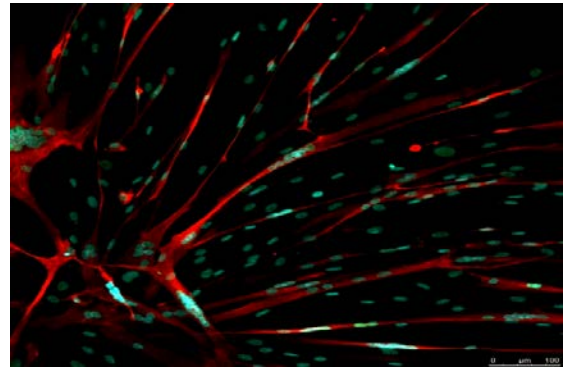
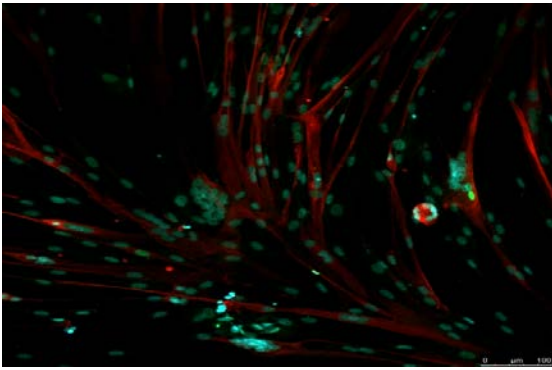
**Figure S6**

Source data Figure 2, A and B  
(primary FSHD#20 myoblasts +E<sub>2</sub>)



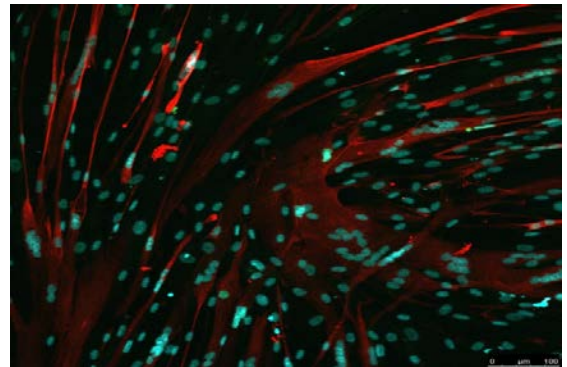
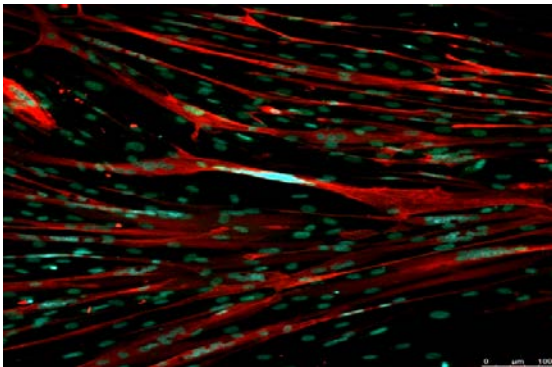
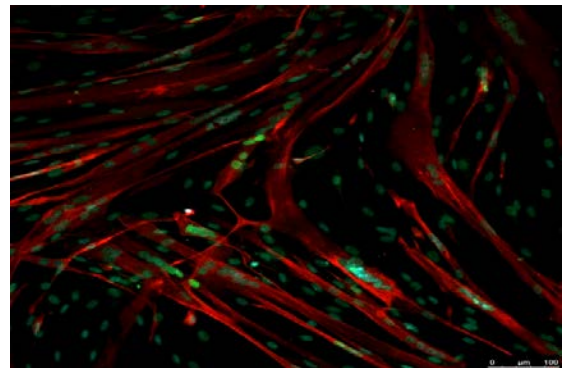
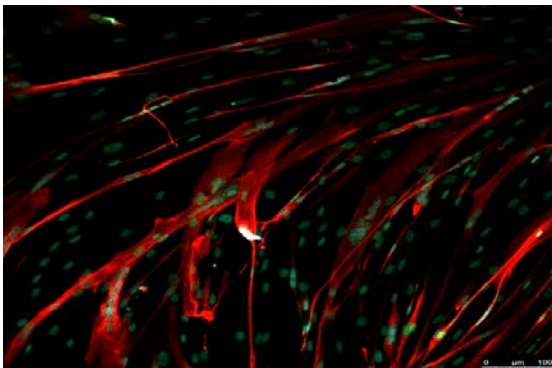
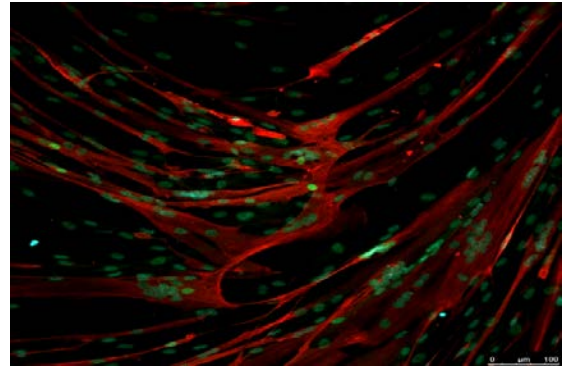
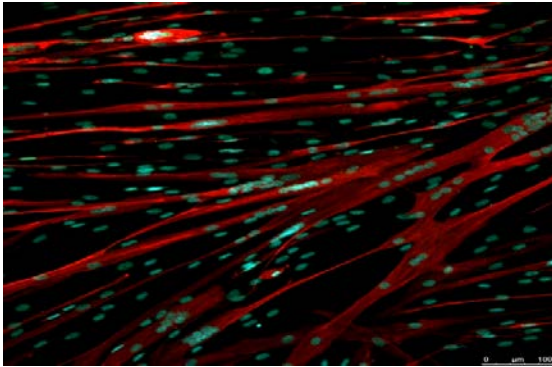
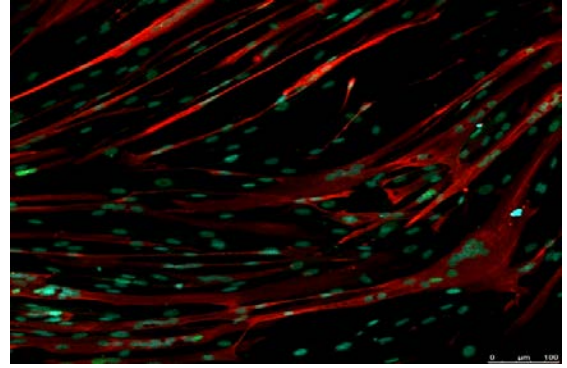
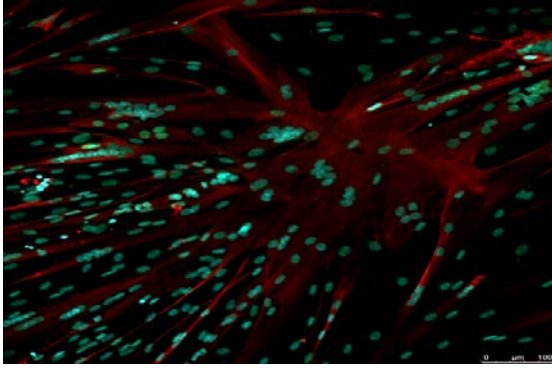
## Figure S6

Source data Figure 2, A and B  
(primary 03A myoblasts)



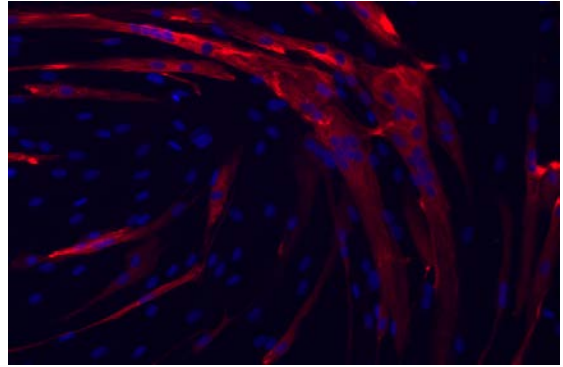
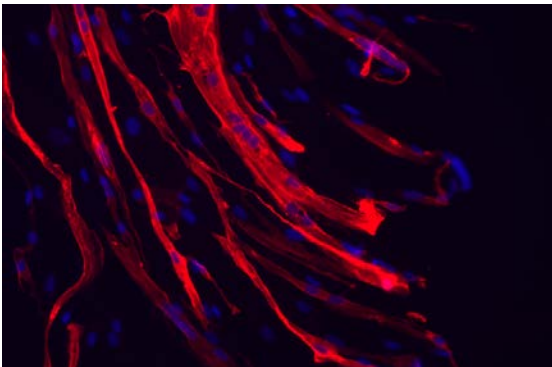
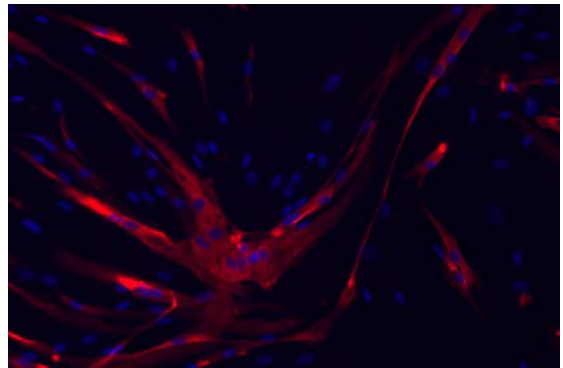
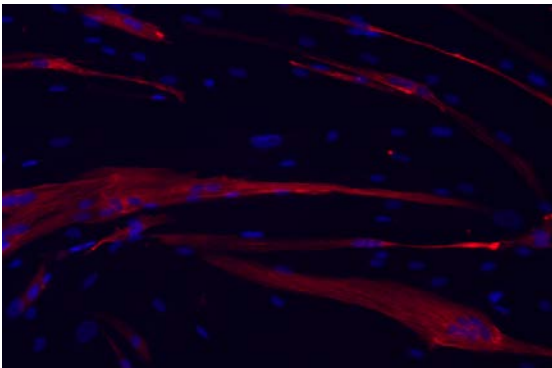
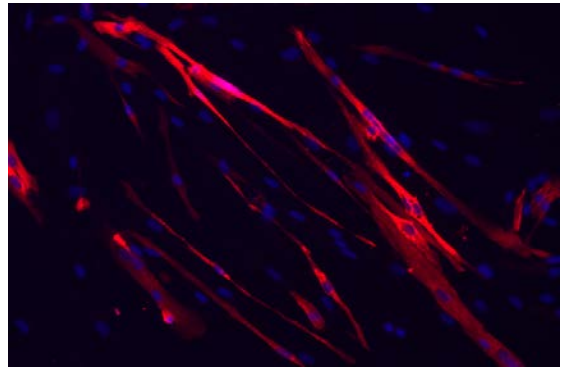
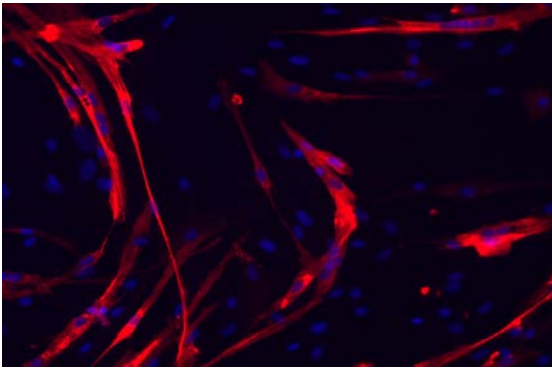
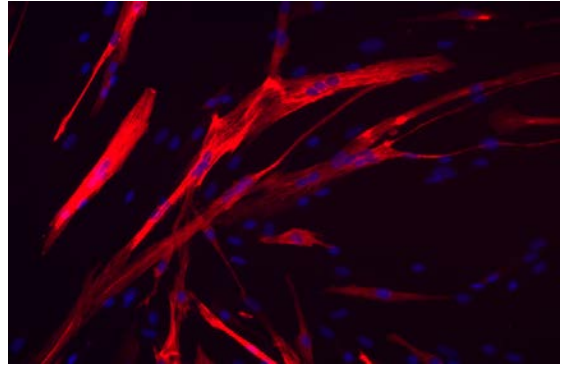
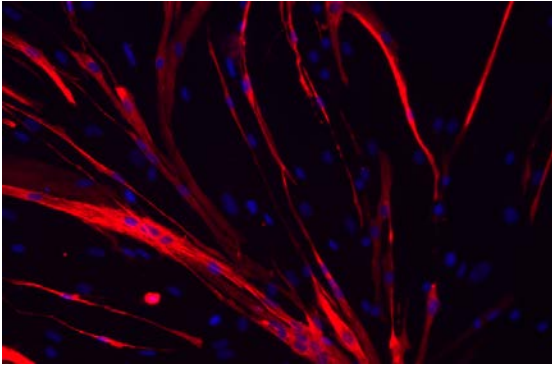
**Figure S6**

Source data Figure 2, A and B  
(primary 03A myoblasts +E<sub>2</sub>)



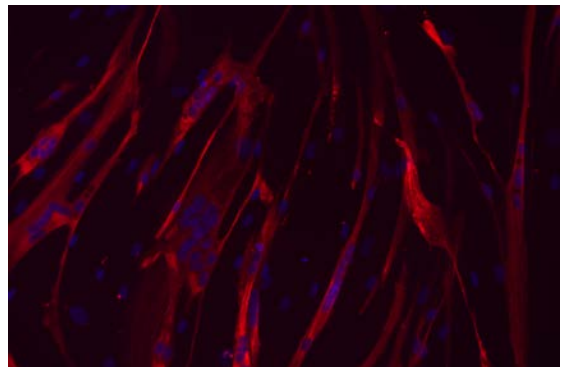
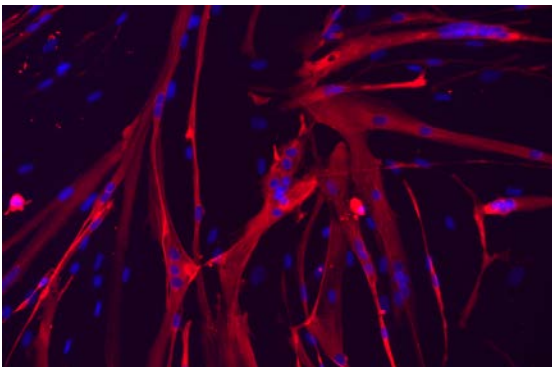
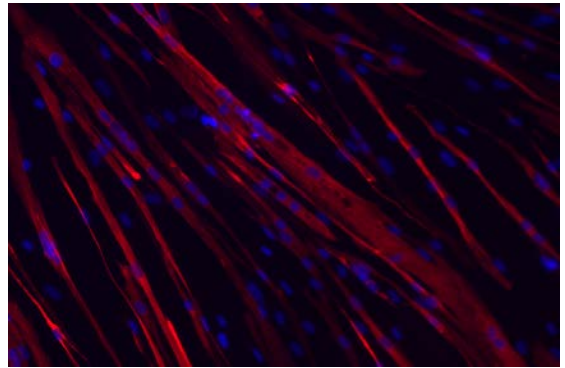
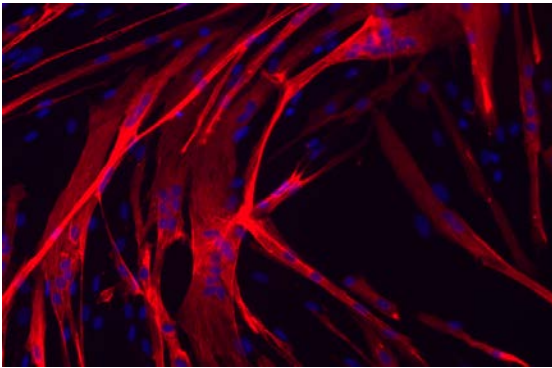
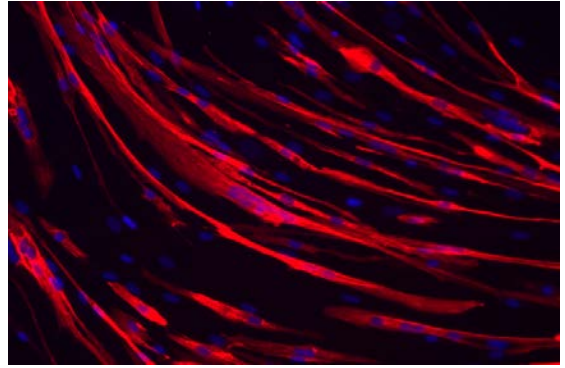
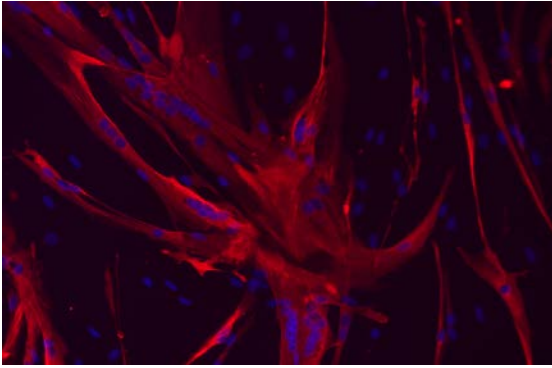
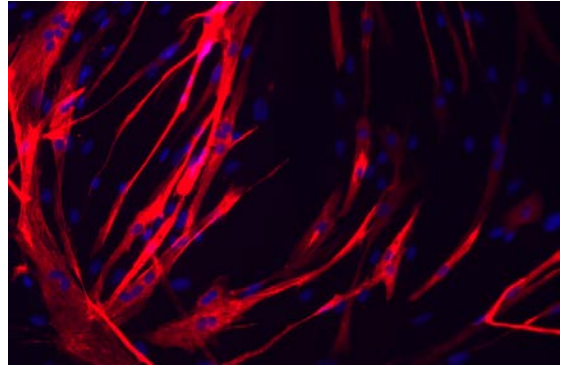
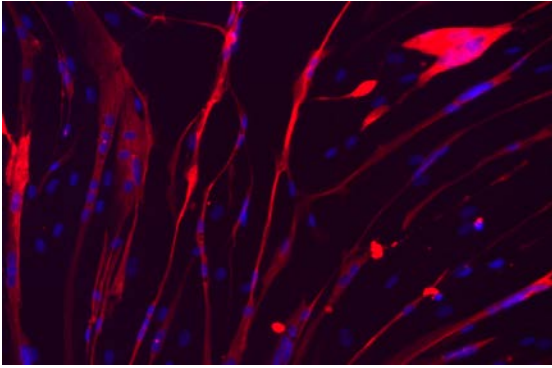
**Figure S6**

Source data Figure 2, A and B  
(primary 05B myoblasts)



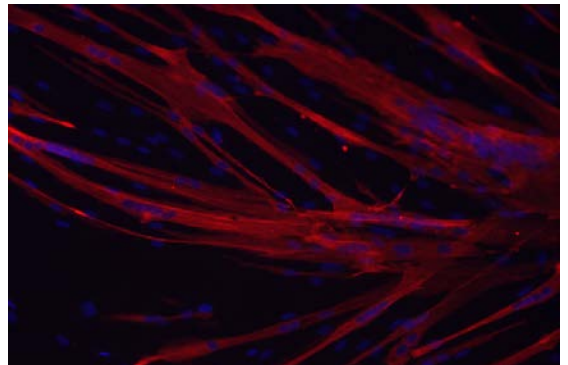
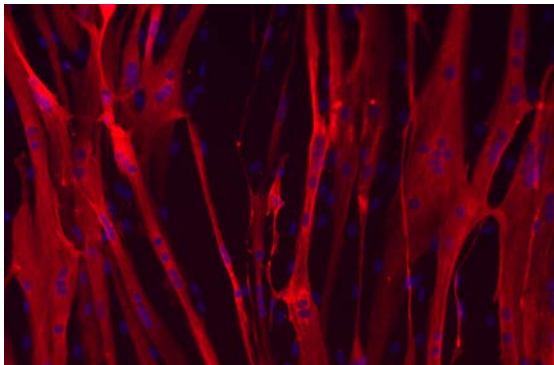
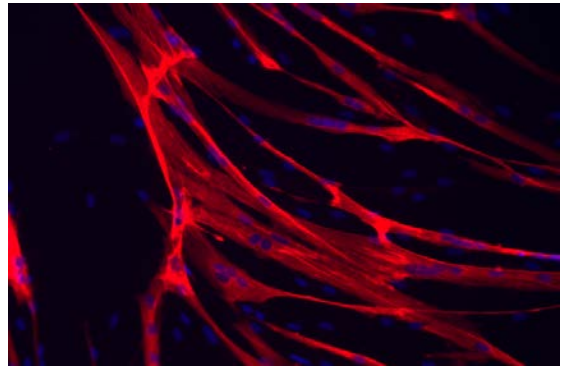
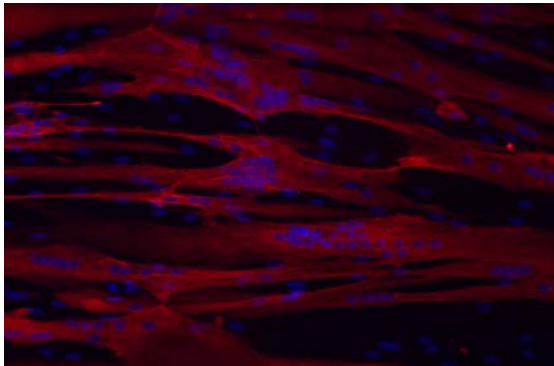
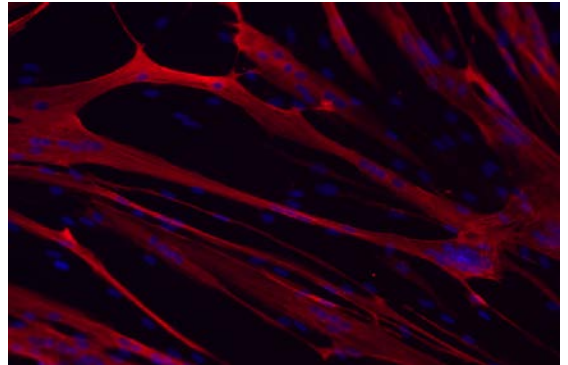
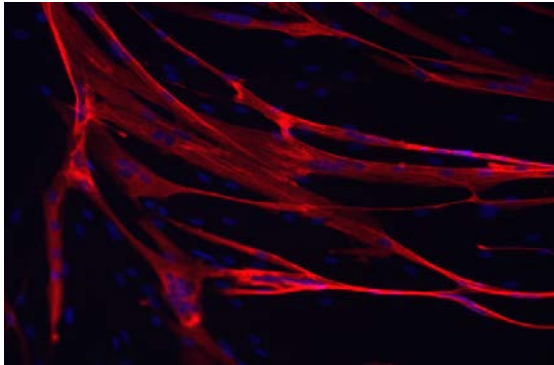
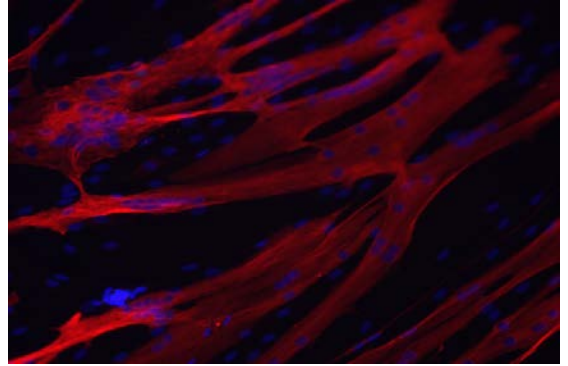
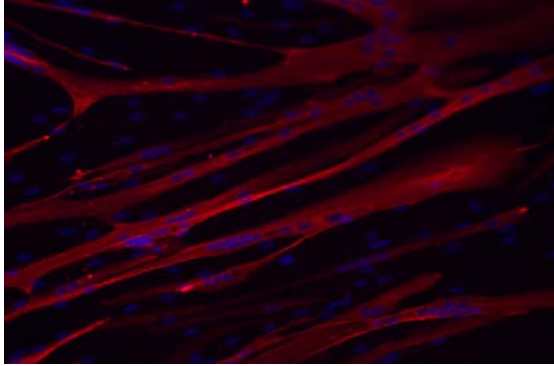
**Figure S6**

Source data Figure 2, A and B  
(primary 05B myoblasts +E<sub>2</sub>)



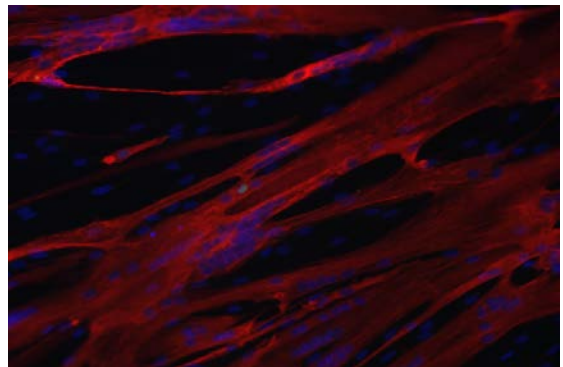
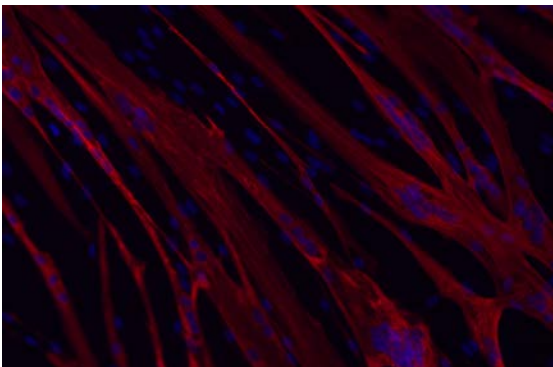
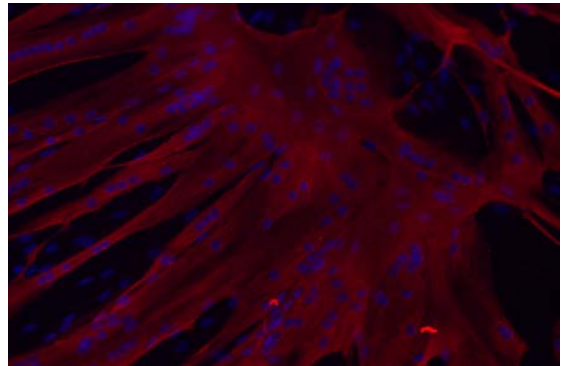
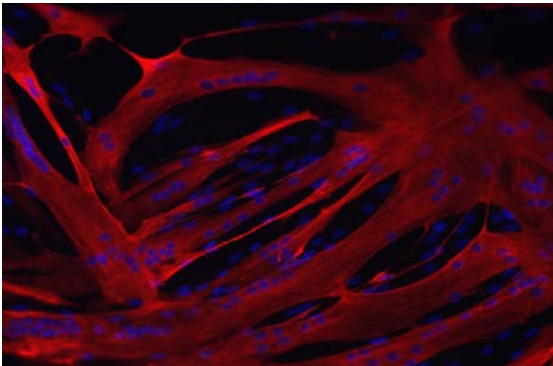
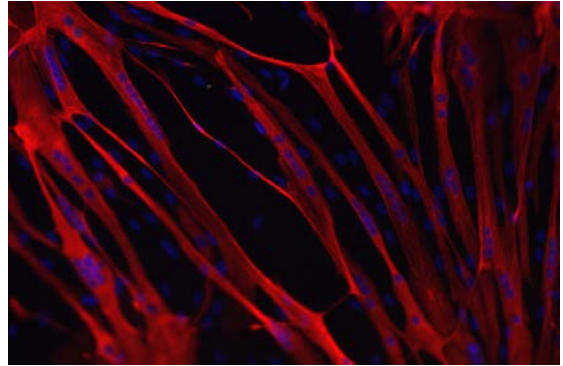
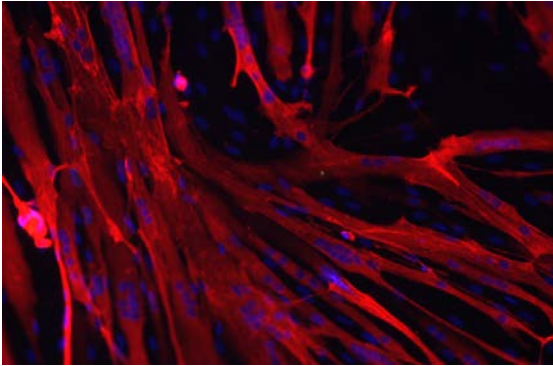
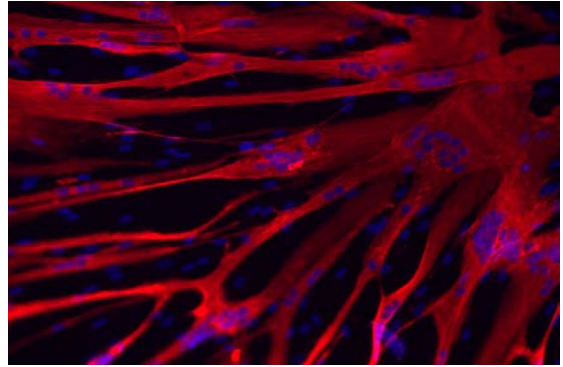
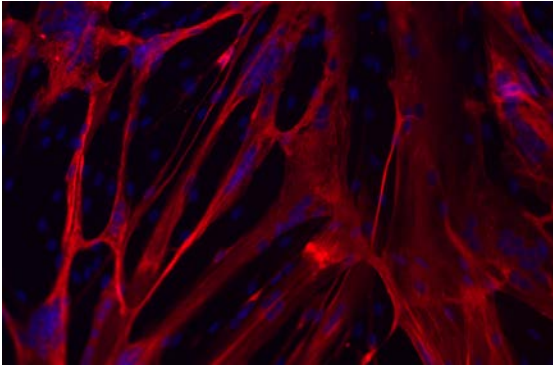
**Figure S6**

Source data Figure 2, A and B  
(primary 12A myoblasts)



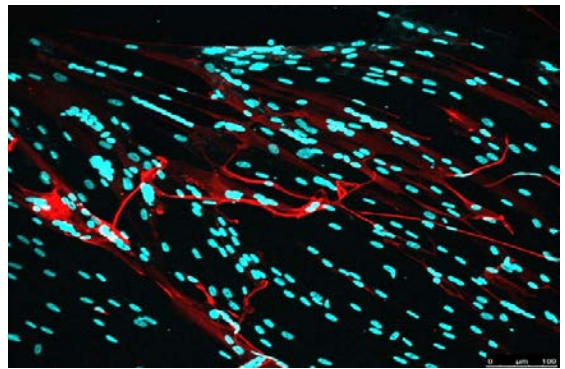
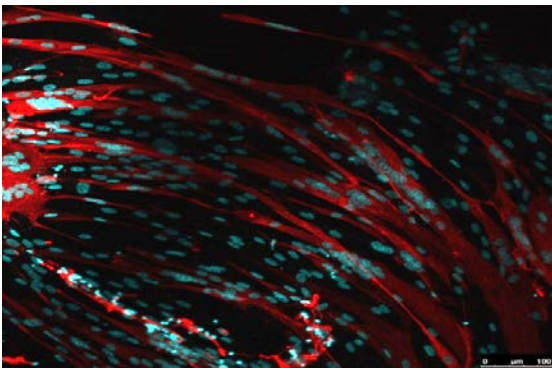
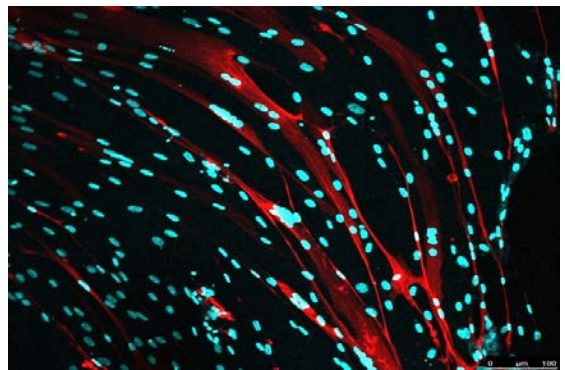
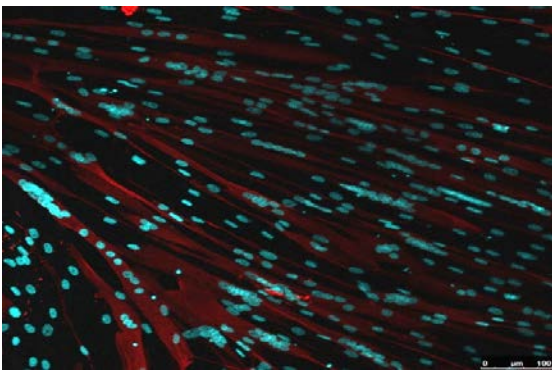
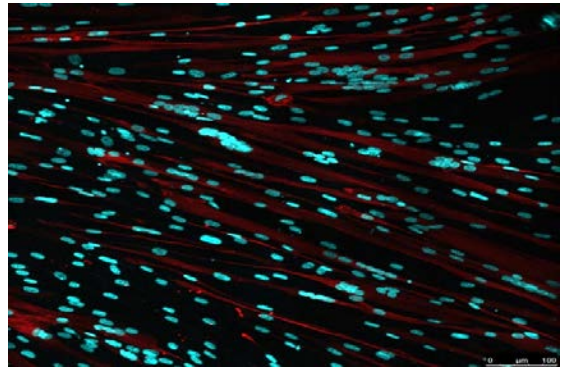

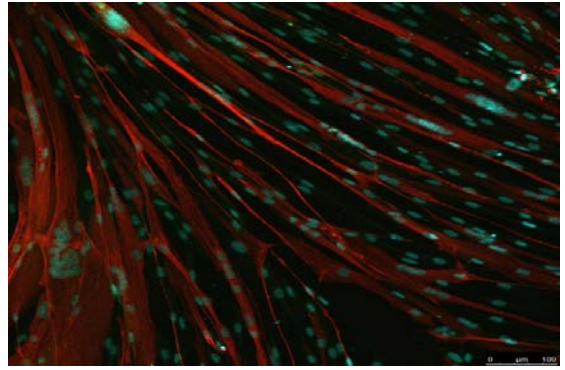
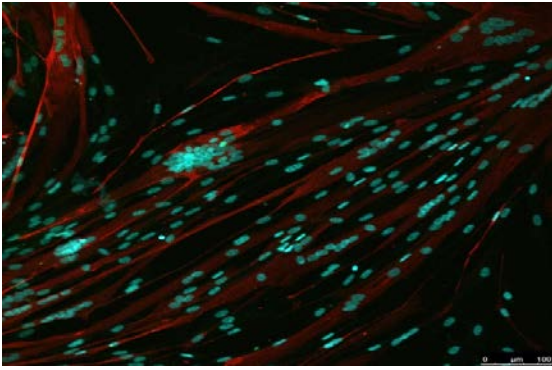
**Figure S6**

Source data Figure 2, A and B  
(primary 12A myoblasts +E<sub>2</sub>)



**Figure S6**

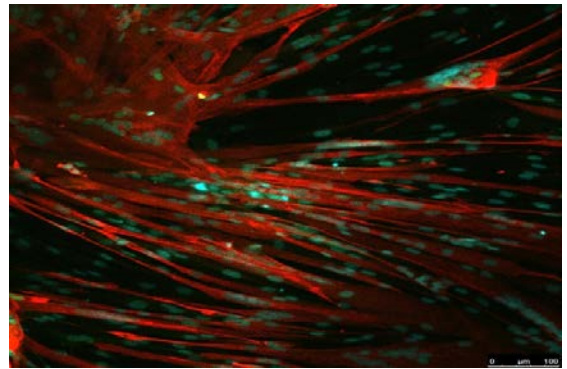
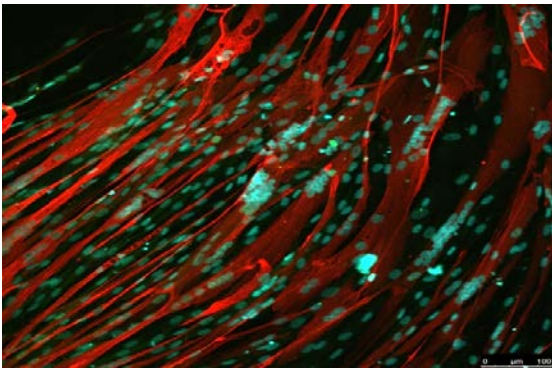
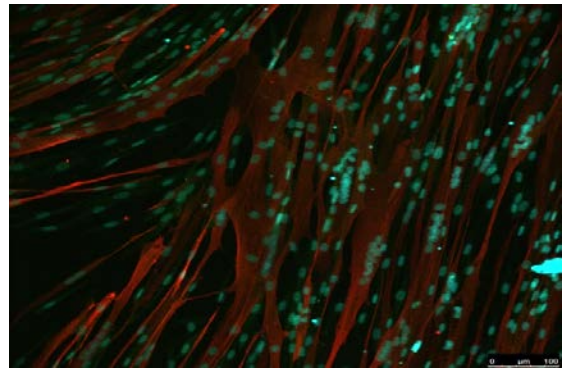
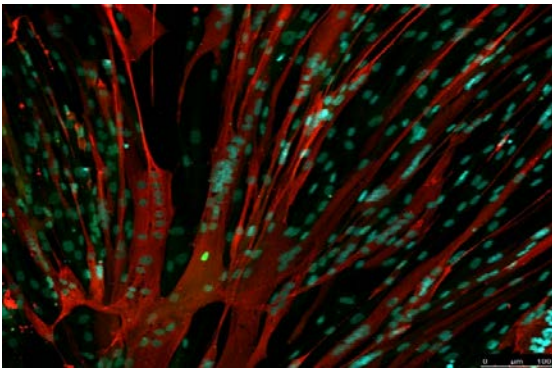
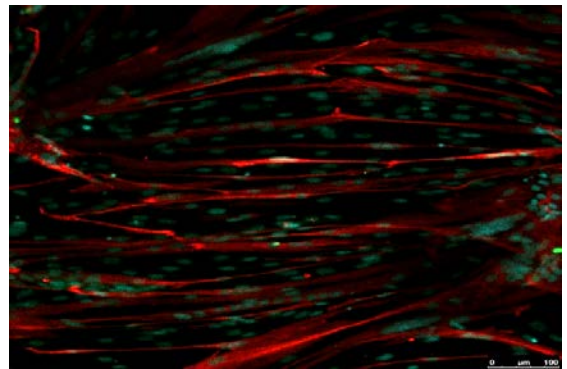
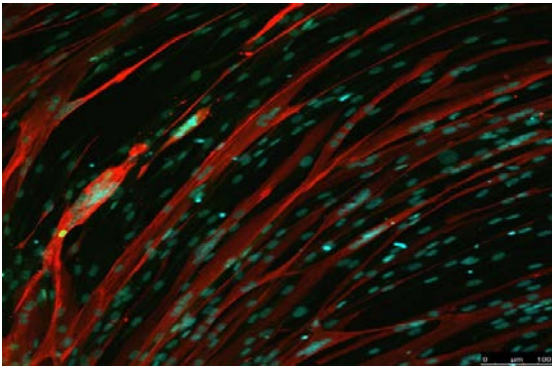
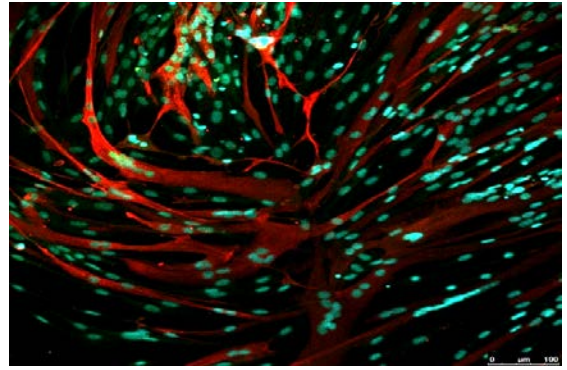
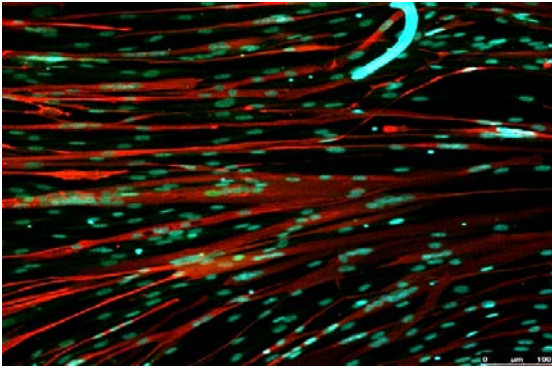
Source data Figure 2, A and B  
(primary 12B myoblasts)





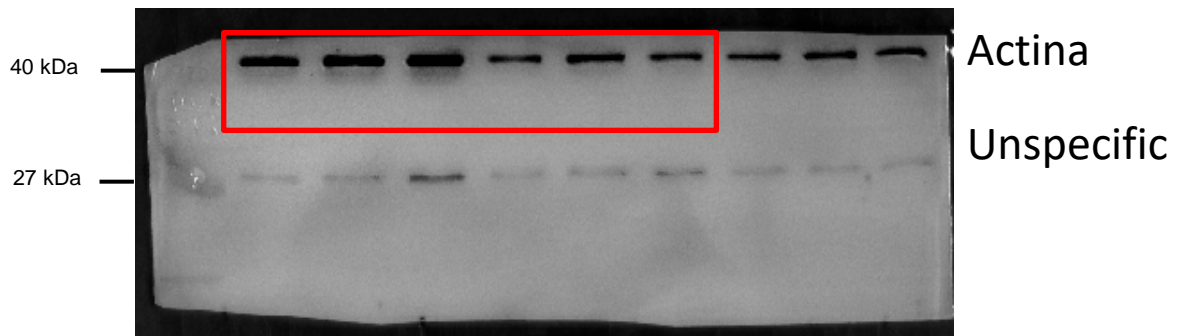
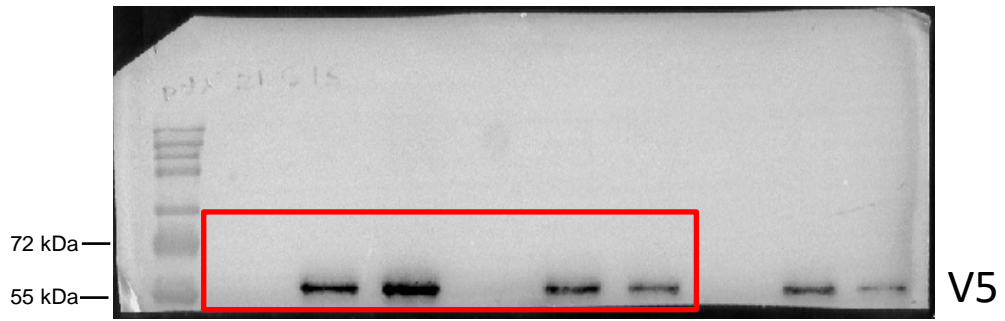
**Figure S6**

Source data Figure 2, A and B  
(primary 12B myoblasts +E<sub>2</sub>)



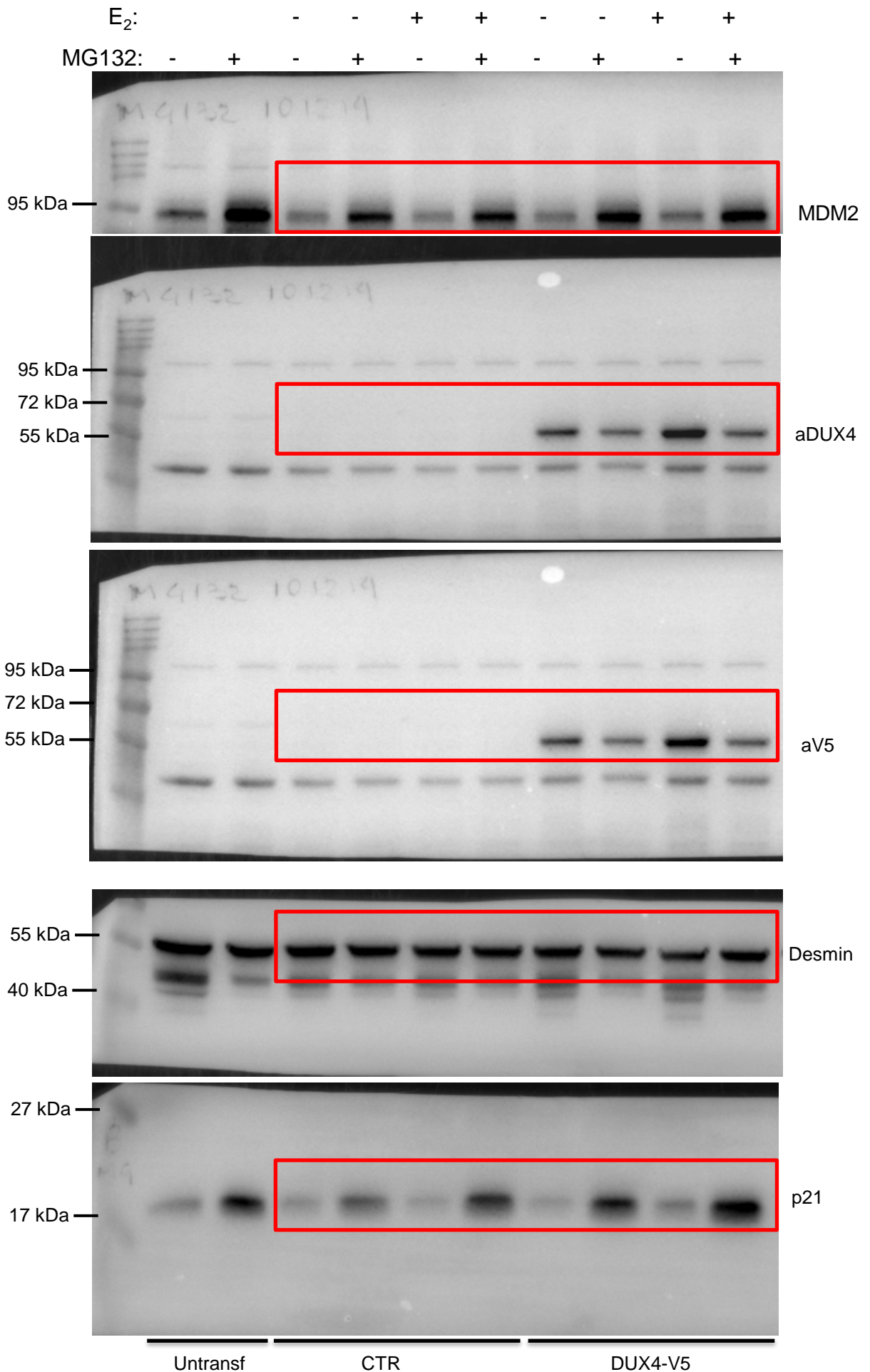
**Figure S7**

Full unedited gels for Figure 3C

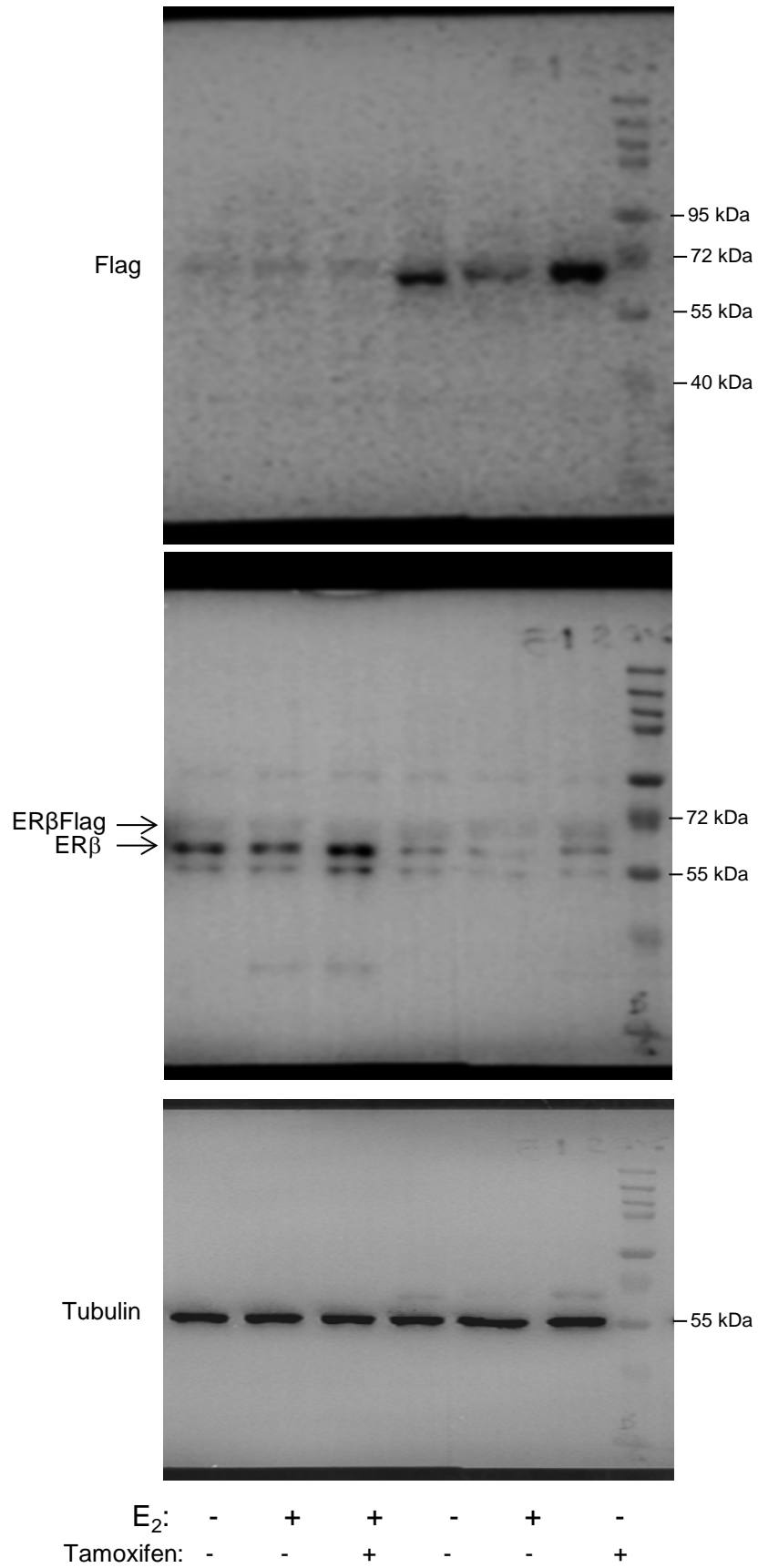


# Figure S7

Full unedited gels for Figure 3D

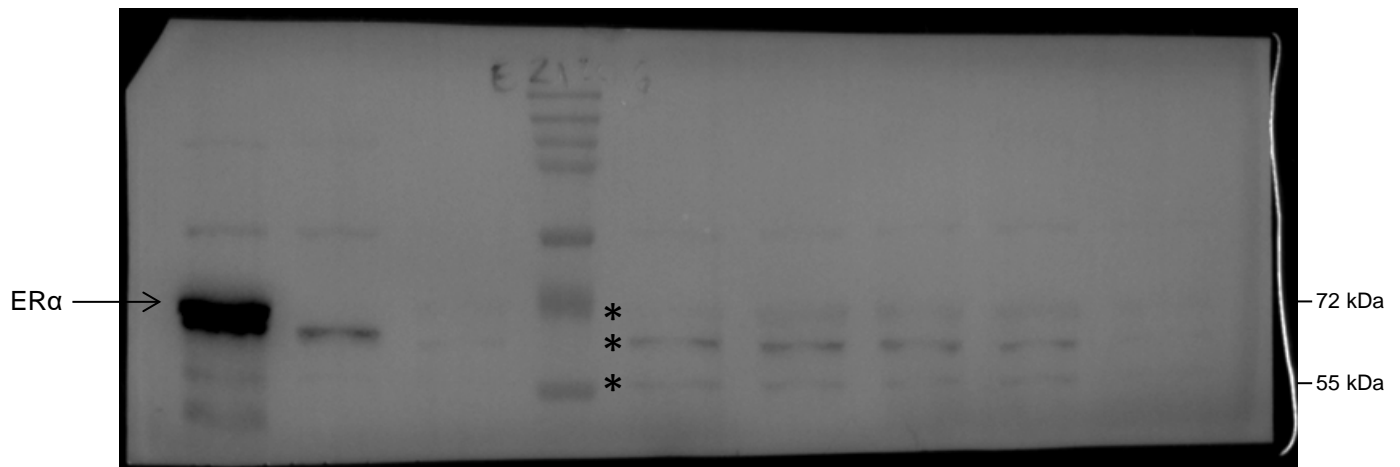
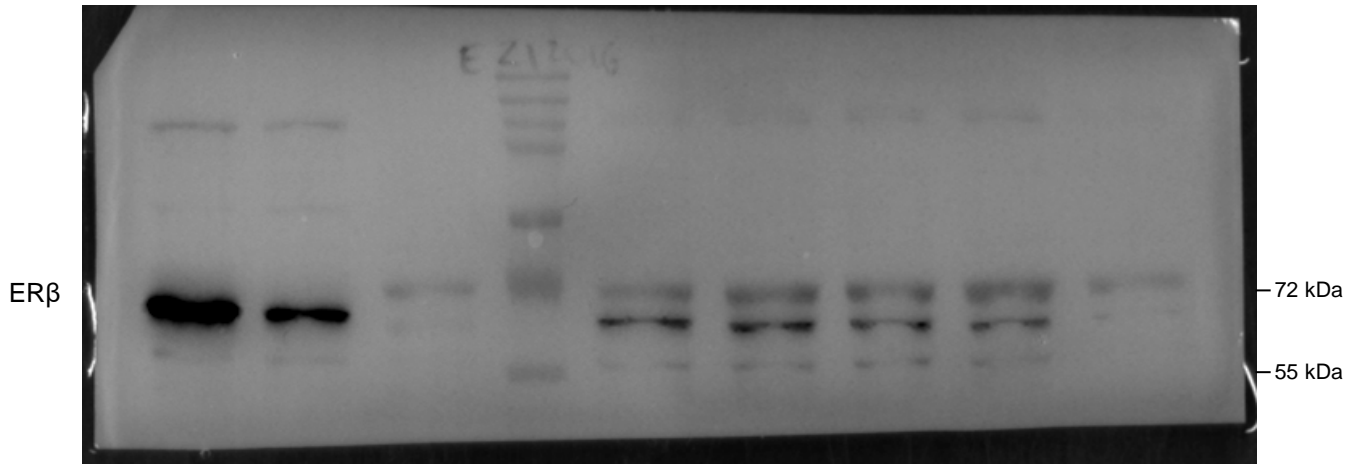


**Figure S7**  
Full unedited gels for Figure 4D




# Figure S7

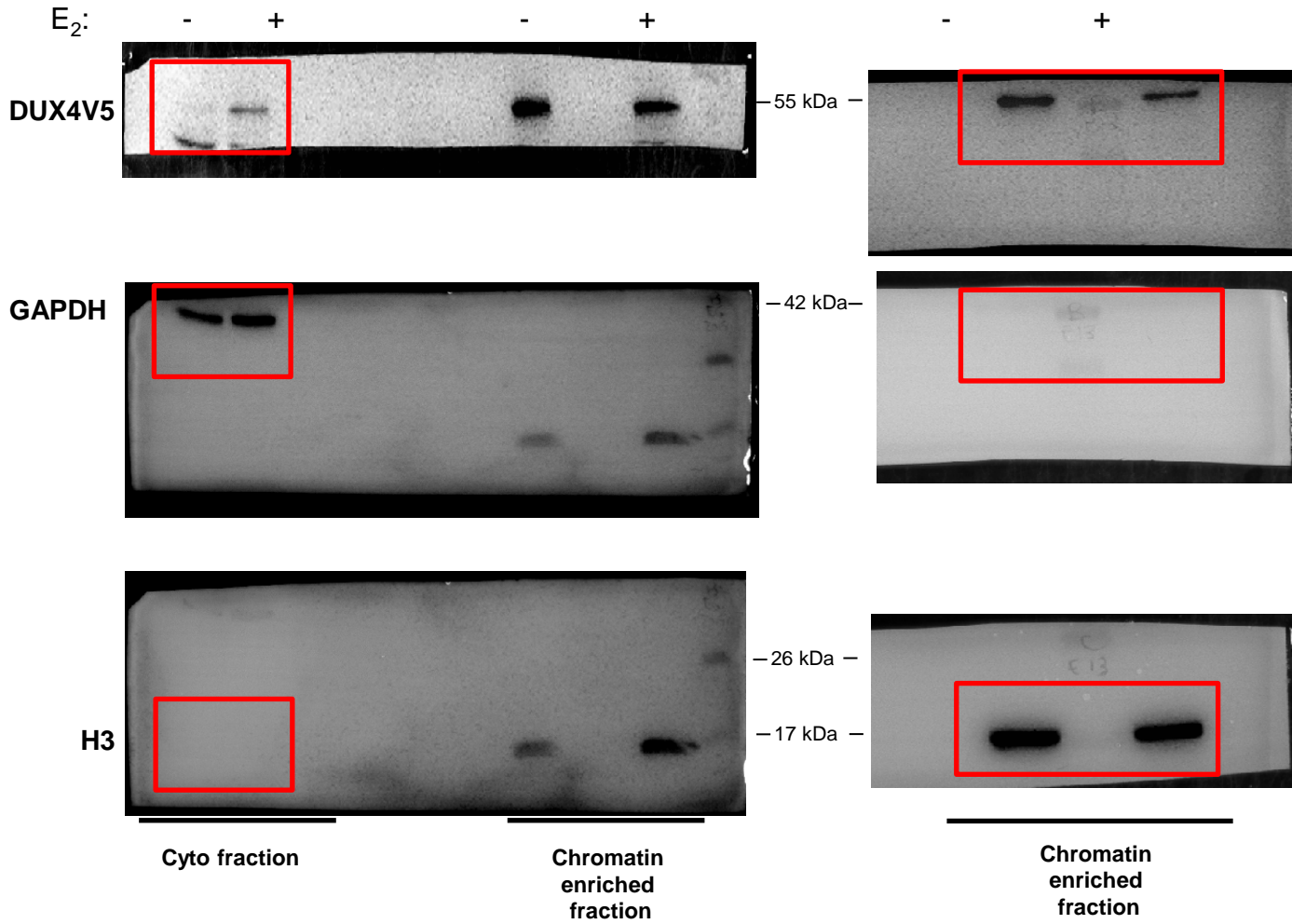
Full unedited gels for Supplemental Figure 4A



\* These signals correspond to the previous blotting with αERβ antibody. No additional bands were observed



**Figure S7**  
Full unedited gels for Figure 9A, left panels (Duff. Myo)



# Figure S7

Full unedited gels for Figure 9A right panel (Prol. Myo)

