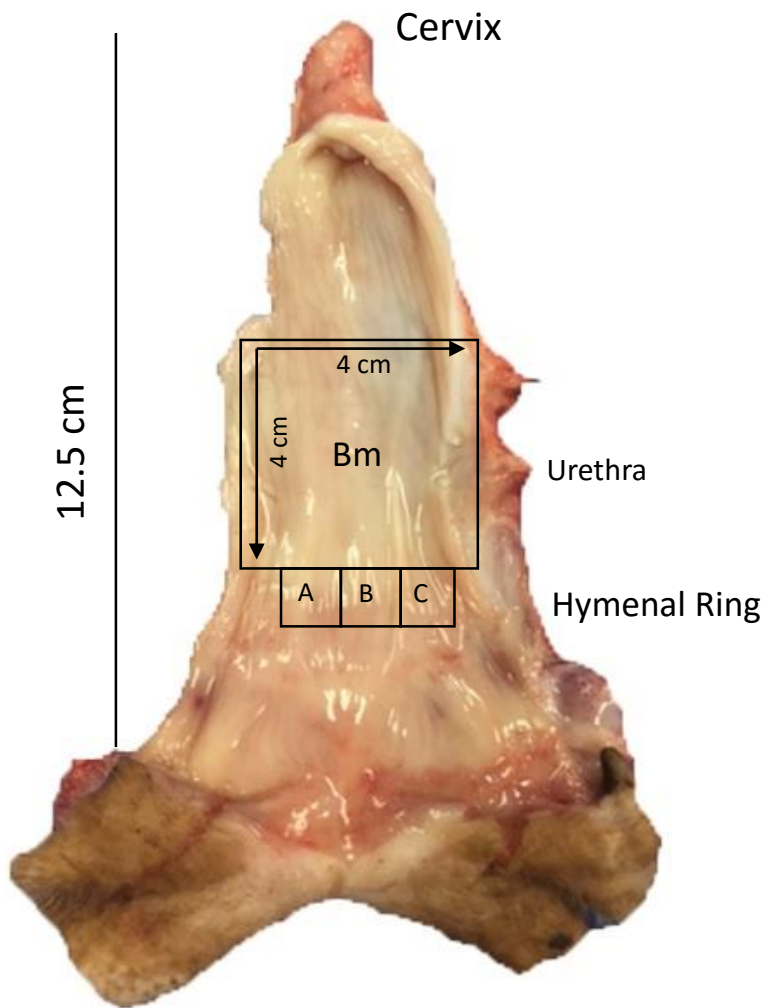


Ovine multiparity is associated with diminished vaginal muscularis, increased elastic fibres and vaginal wall weakness: implication for pelvic organ prolapse.

Stuart Emmerson, Natharnia Young, Anna Rosamilia, Luke Parkinson, Sharon L Edwards, Aditya V. Vashi, Miranda Davies-Tuck, Jacinta White, Kirstin Elgass, Camden Lo, John Arkwright, Jerome A Werkmeister, Caroline E Gargett



### Supplemental Figure 1: Tissue Dissection

Tissue was dissected from vaginal tissue for **A)** Frozen Sections in OCT, **B)** paraffin embedding, **C)** biochemical analysis and **Bm)** Biomechanical analysis.