

## Supplementary Materials: Can Early Rehabilitation Prevent Posttraumatic Osteoarthritis in the Patellofemoral Joint after Anterior Cruciate Ligament Rupture? Understanding the Pathological Features

Nai-Jen Chang, Ming-You Shie, Kuan-Wei Lee, Pei-Hsi Chou, Chih-Chan Lin and Chih-Jou Chu

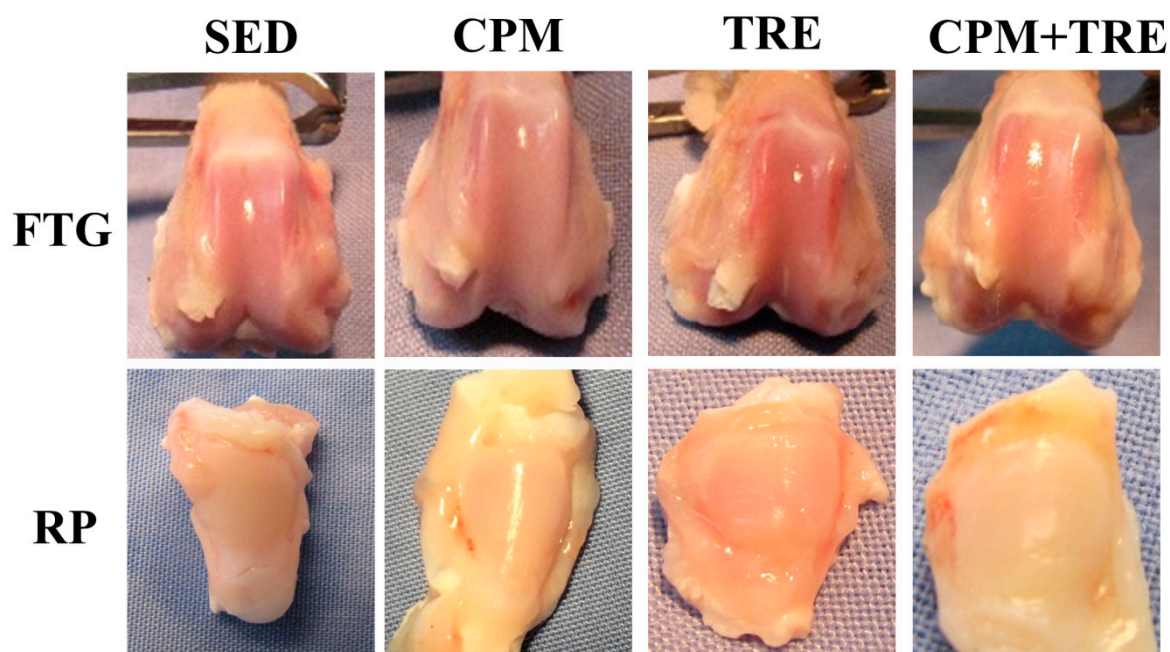


Figure S1. Evaluation of the gross appearance in the ACL transection (ACLT) knee.