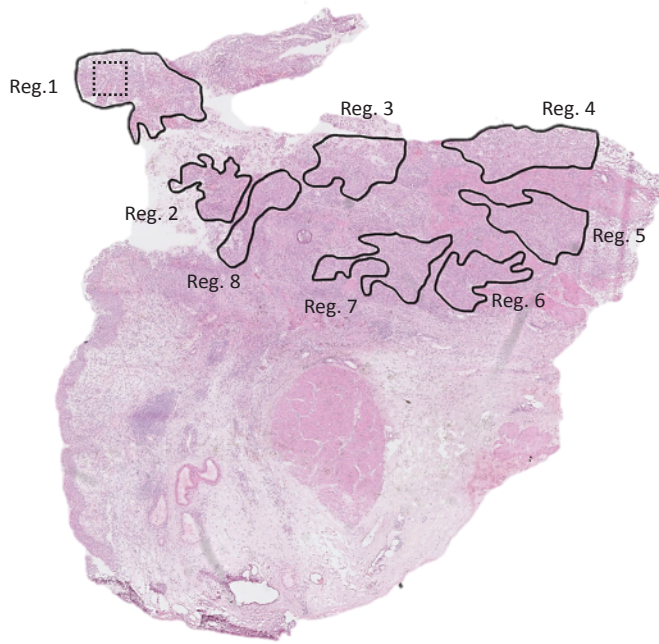
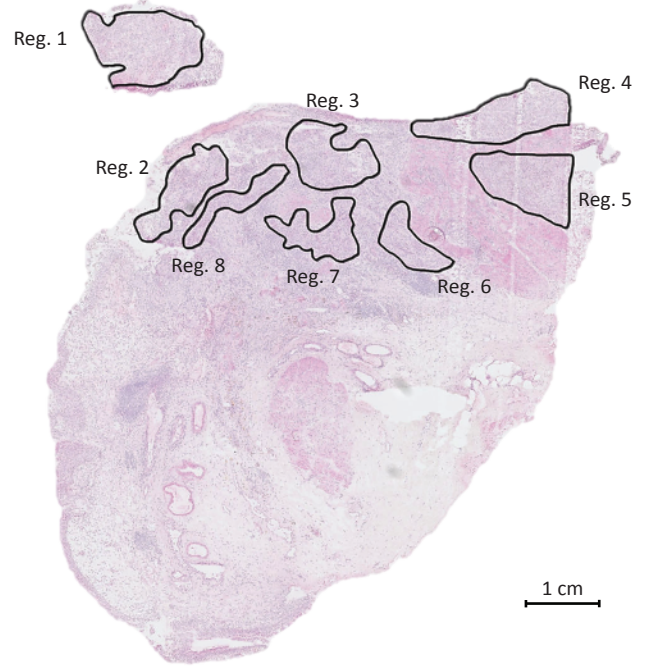

Supplementary Figure S1

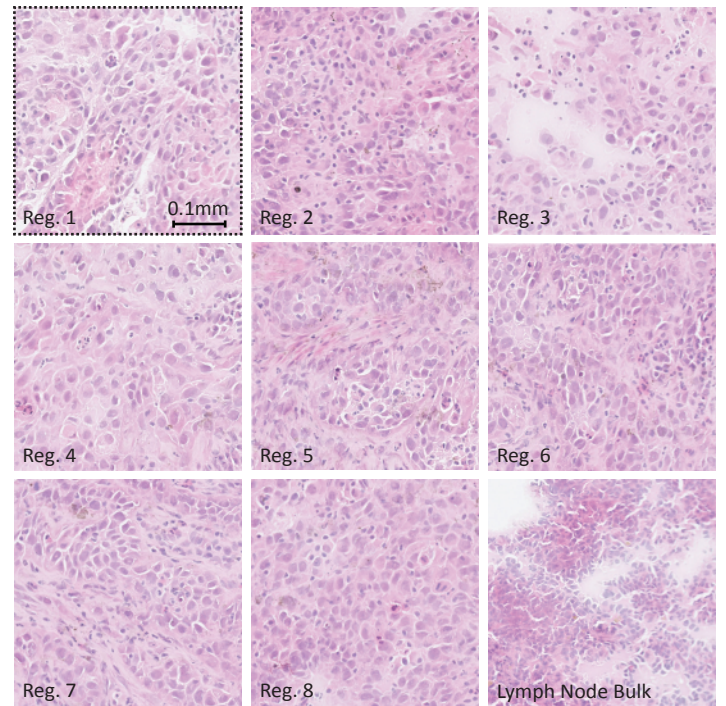
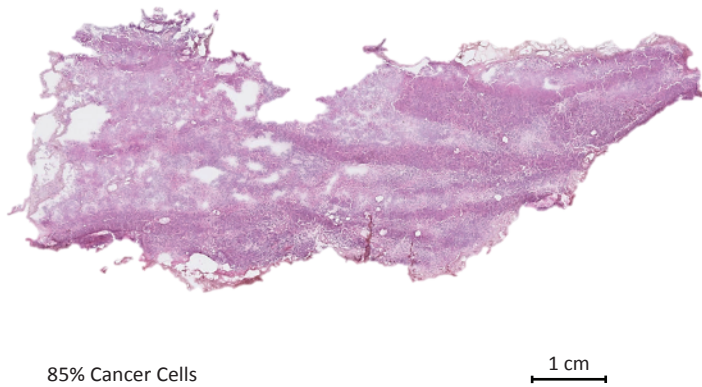
Patient 1 Primary Tumour - Top Section



Patient 1 Primary Tumour - Bottom Section



Patient 1 Lymph Node Metastasis



Supplementary Figure S1 - Laser micro dissection overview – Patient 1. Presented is a top and bottom section of the primary tumour (FF) of patient 1. Between the presented sections are 15 sections which have been subjected to laser micro dissection. The top and bottom sections illustrate, that the same region could be traced over 15 sections. A presentation of the lymph node metastasis (FF) is presented along with images of each region at 40x magnification. For comparison, a box has been placed in region 1. Scalebars are indicated in macro-figures.