
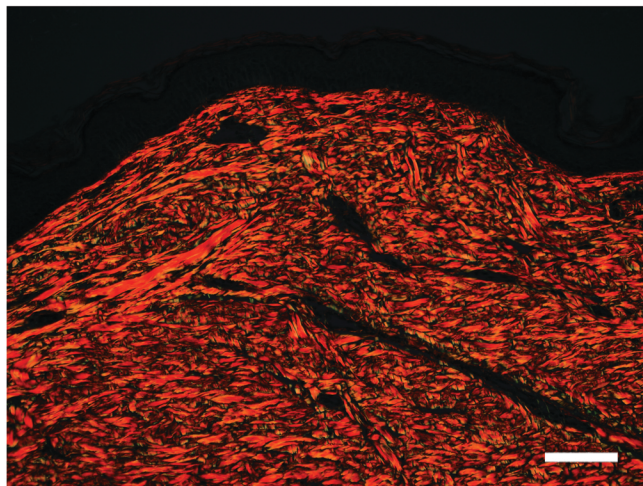


Human specimens

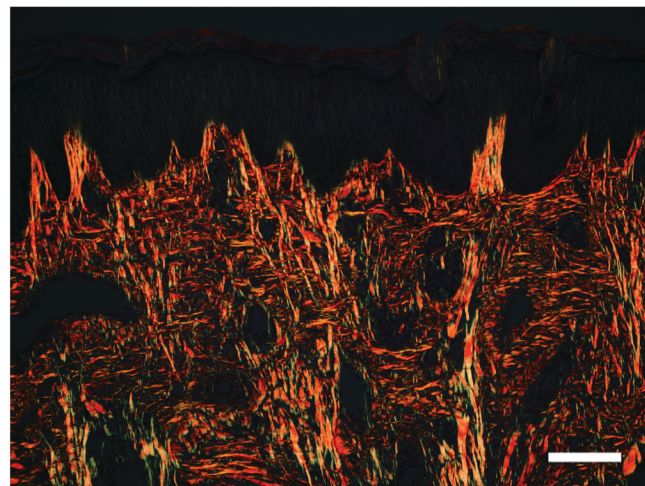
Normal skin



White scar



Keloid



Reconstituted skins

