

## APPENDIX 1. Tumor location & Preoperative and postoperative MRI images.

The tumor location and the correspondent pre- and postoperative T1WI+gadolinium MRI images are described for each patient, according to the following schema:

PATIENT NO.

Brief description of tumor location.

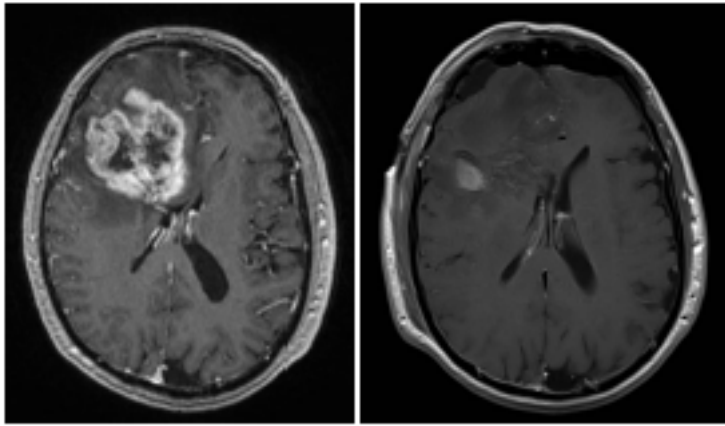
MRI images:

Left: Preoperative MRI. T1WI + GADO

Right: Early postoperative MRI. T1WI + GADO

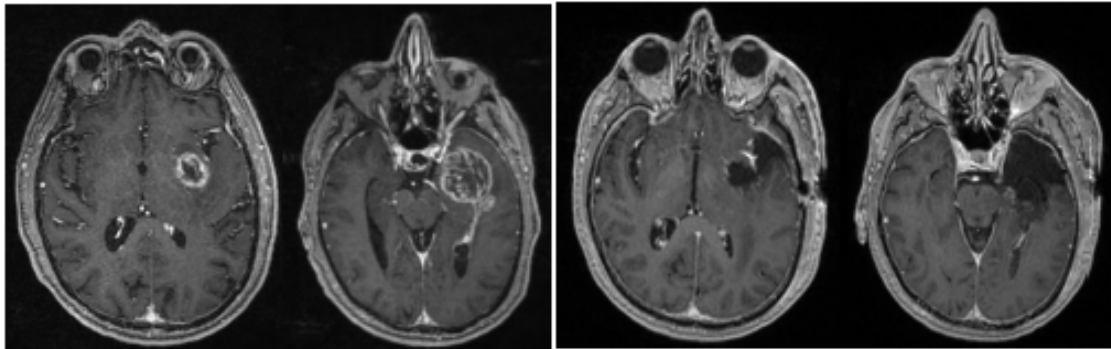
### PATIENT 1.

Right frontal lobe with mild corpus callosum involvement.



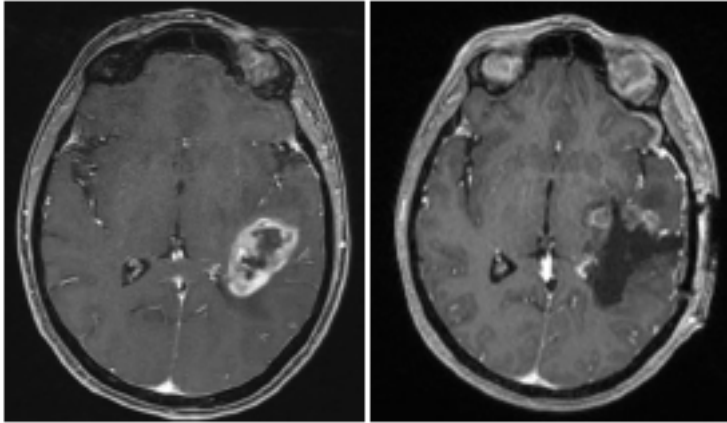
### PATIENT 2.

Left temporal lobe with subependymal involvement.



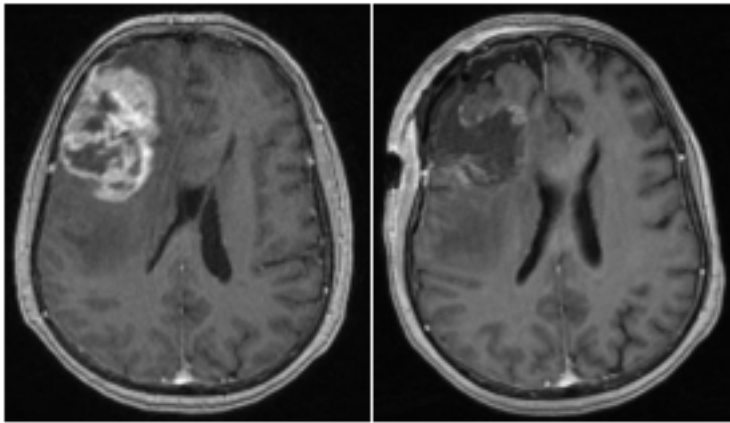
### PATIENT 3.

Left temporal lobe.



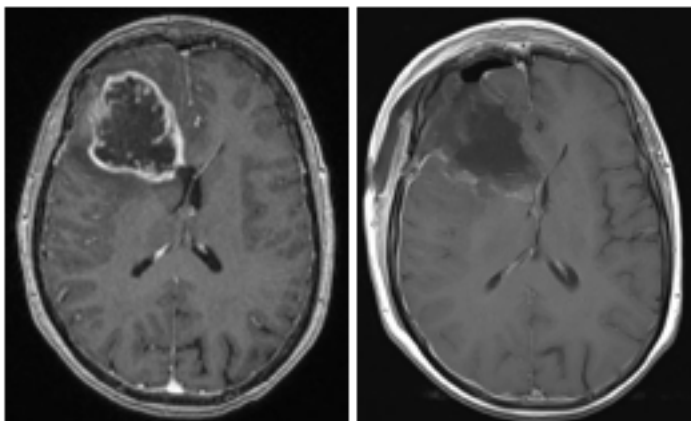
**PATIENT 4.**

Right frontal lobe.



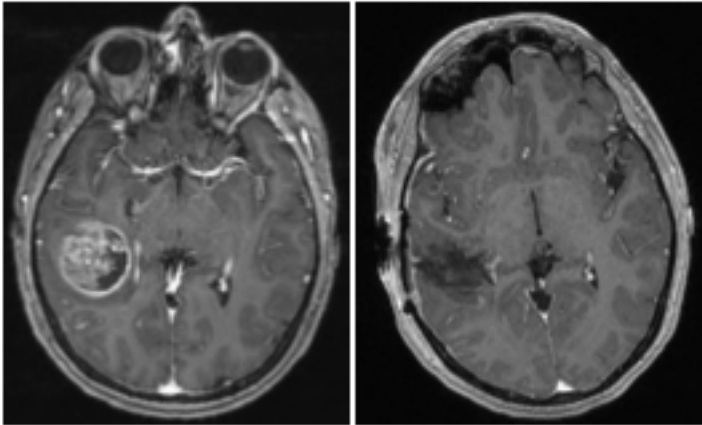
**PATIENT 5.**

Right frontal lobe.



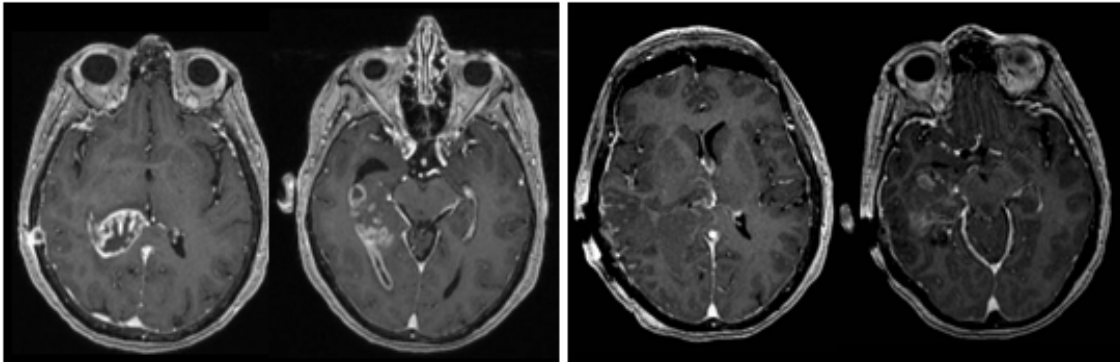
**PATIENT 6.**

Right temporal lobe.



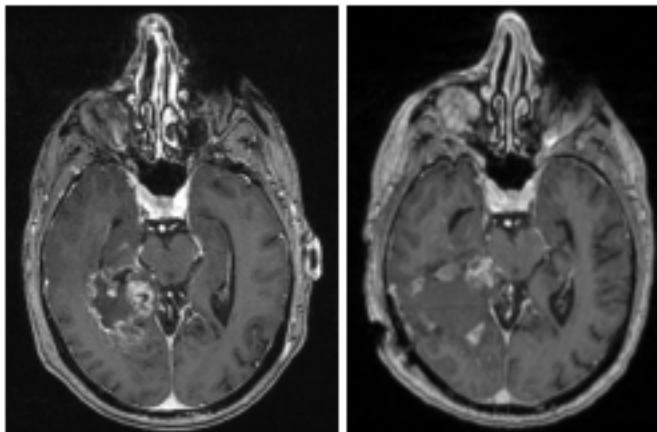
**PATIENT 7.**

Right medial temporal lobe with subependymal involvement.



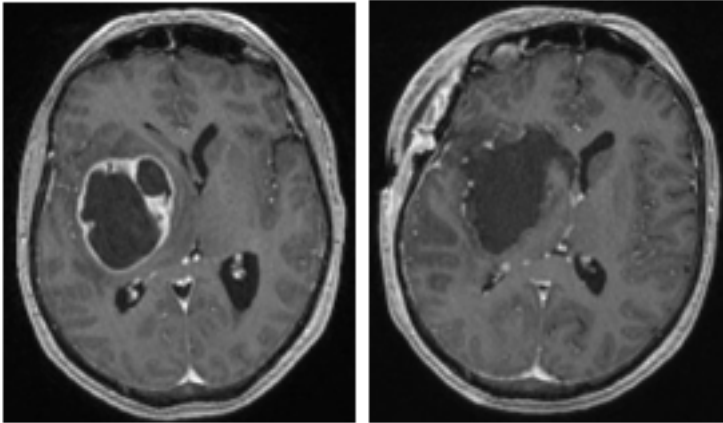
**PATIENT 8.**

Right temporal lobe.



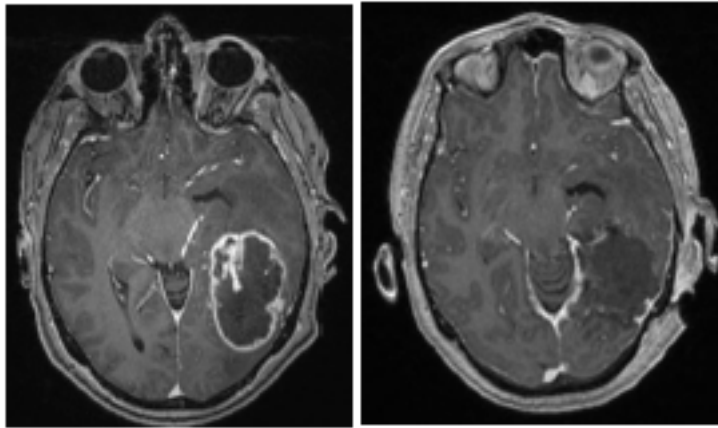
**PATIENT 9.**

Right frontal lobe with basal ganglia involvement.



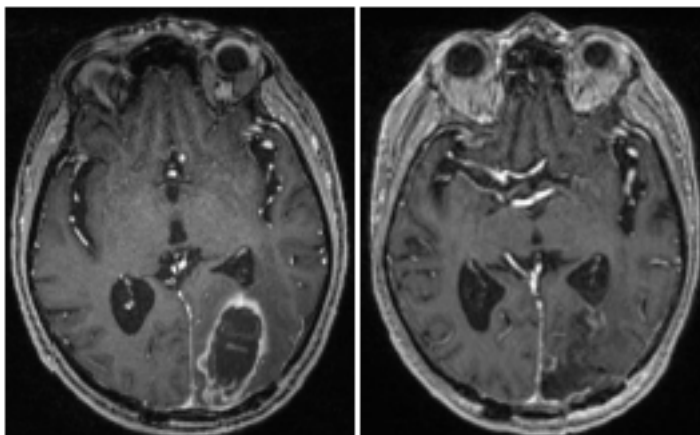
**PATIENT 10.**

Left temporo-occipital lobes.



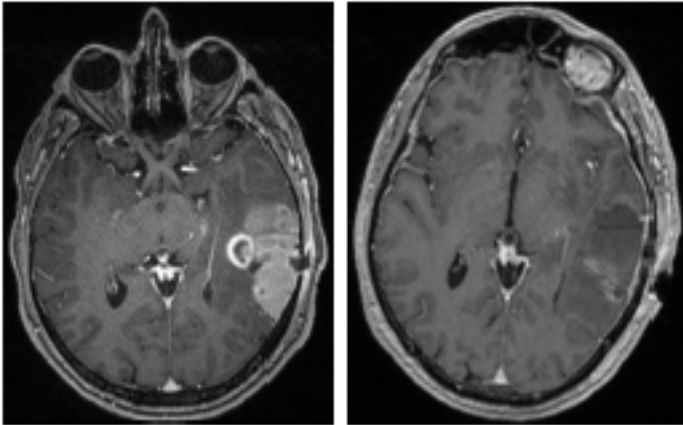
**PATIENT 11.**

Left parieto-occipital lobes.



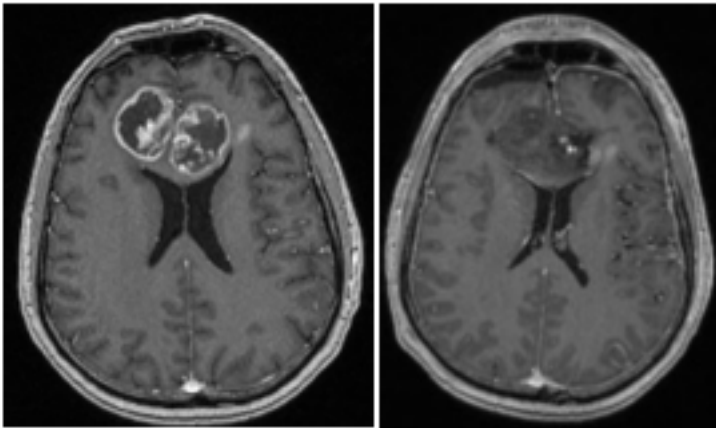
**PATIENT 12.**

Left temporal lobe.



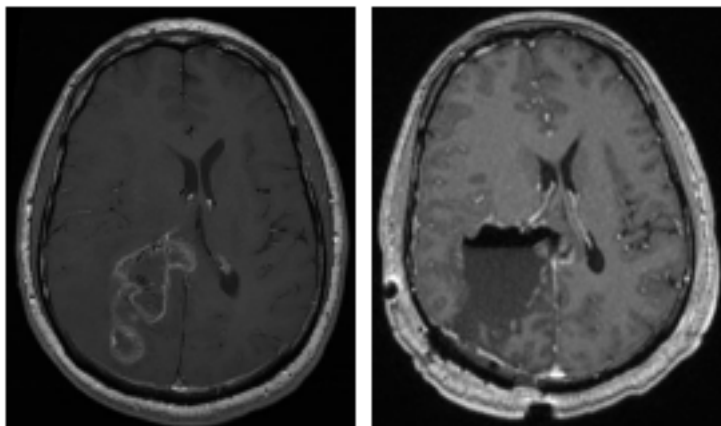
**PATIENT 13.**

Bilateral fronto-callosal location.



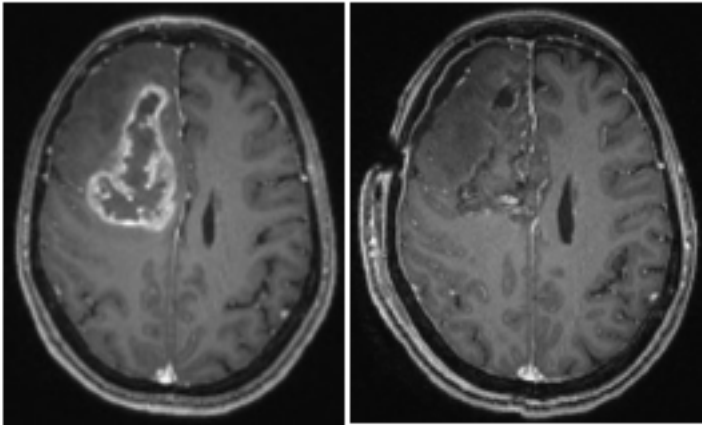
**PATIENT 14.**

Right parietal lobe.



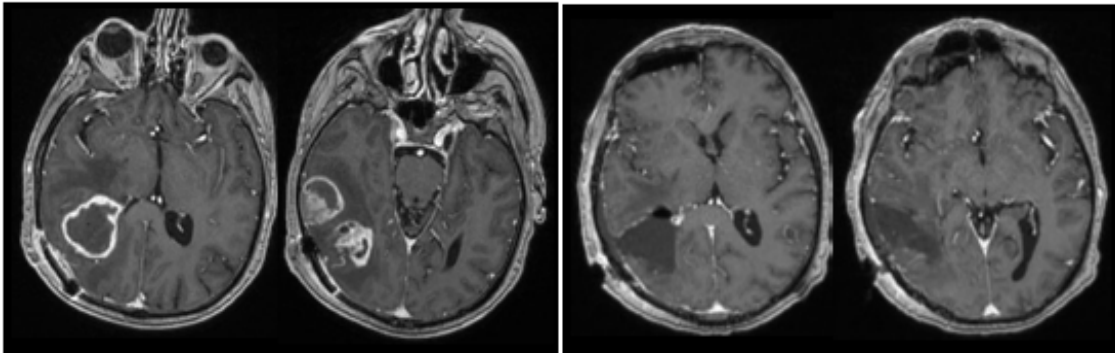
**PATIENT 15.**

Right frontal lobe.



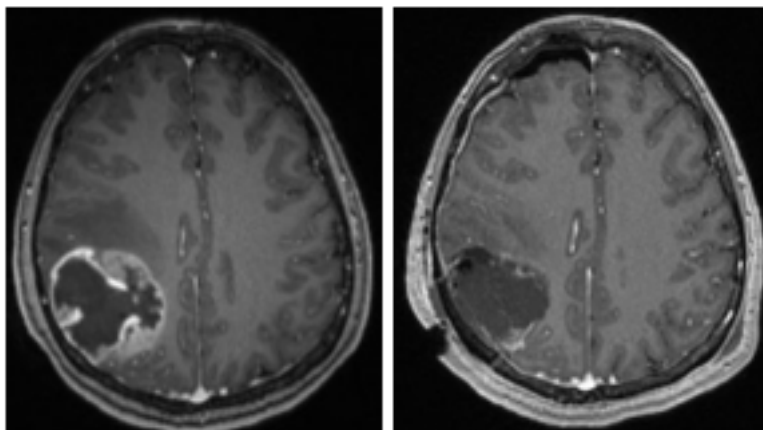
**PATIENT 16.**

Right temporo-parietal lobes.



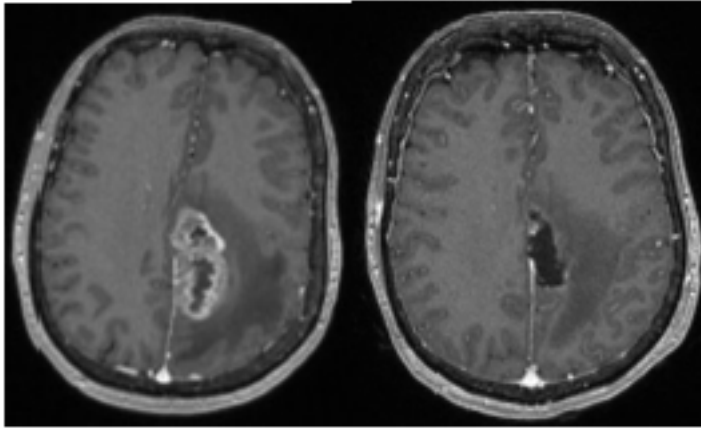
**PATIENT 17.**

Right parietal lobe.



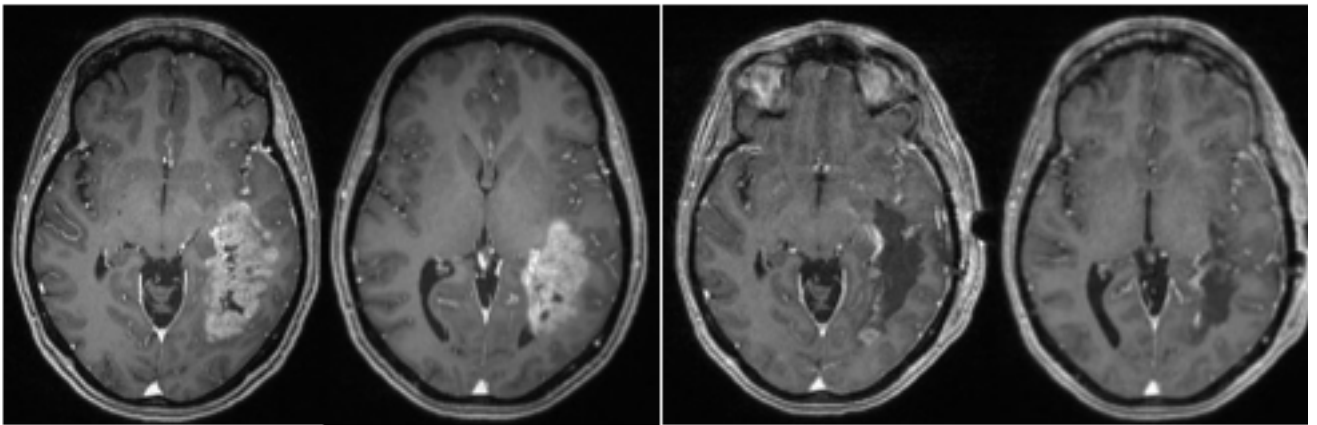
**PATIENT 18.**

Left medial frontoparietal lobes.



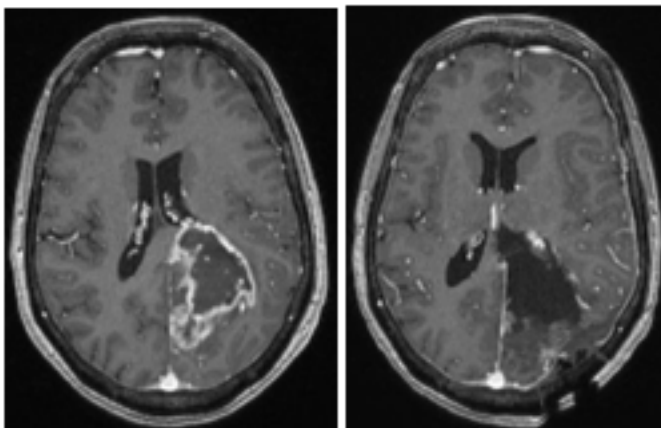
**PATIENT 19.**

Left temporo-occipital lobes.



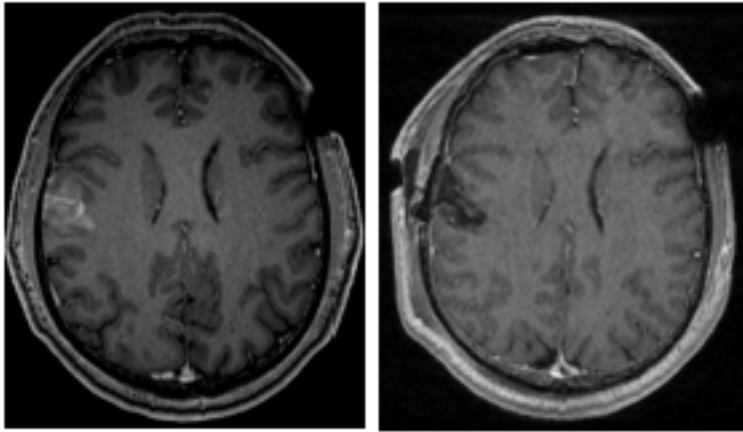
**PATIENT 20.**

Left parieto-occipital lobes.



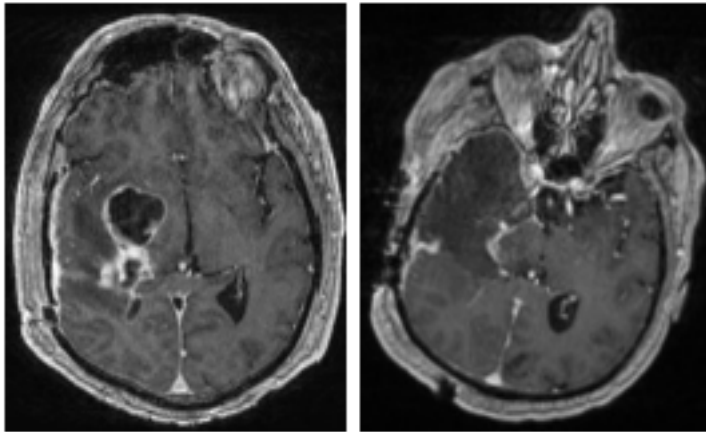
**PATIENT 21.**

Right frontal operculum área.



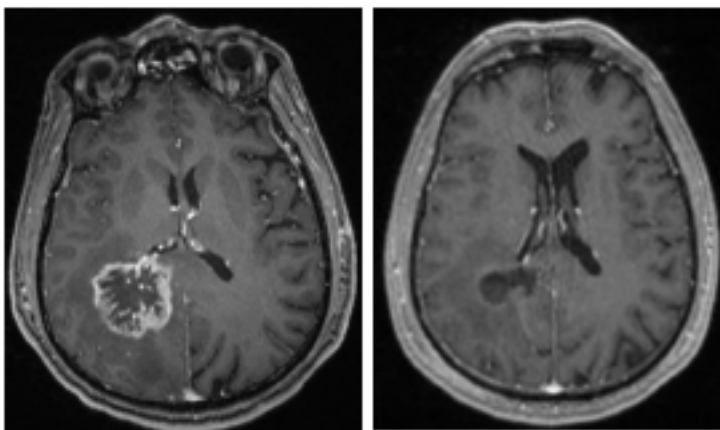
**PATIENT 22.**

Right fronto-temporal lobes.



**PATIENT 23.**

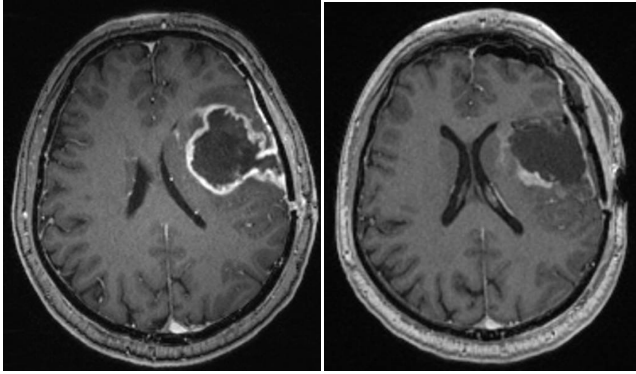
Right temporo-parietal lobes.



**PATIENT 24.**

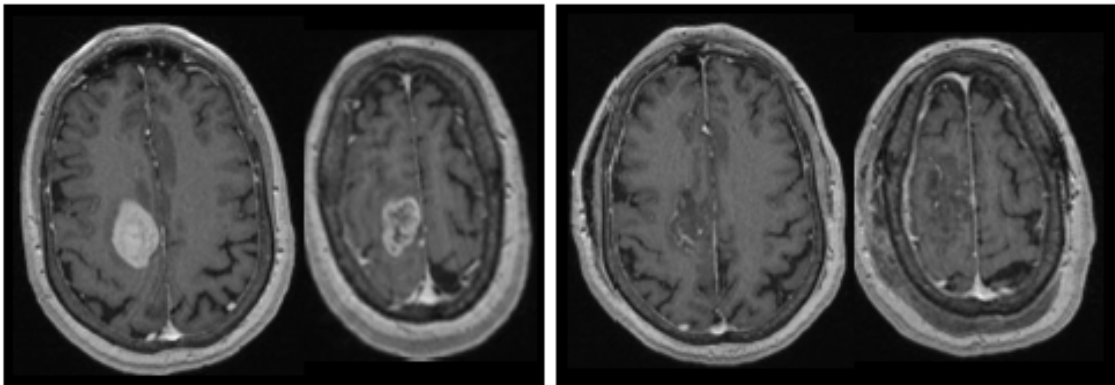
*Patient not included - screening failure (residual tumor > 1cc).*





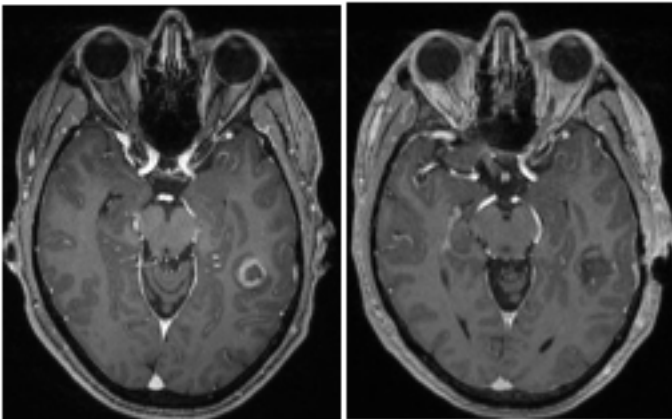
**PATIENT 25.**

Right frontal lobe.



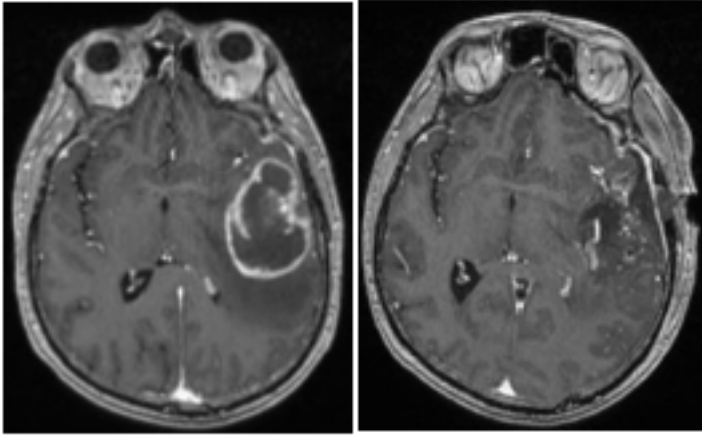
**PATIENT 26.**

Left temporal lobe.



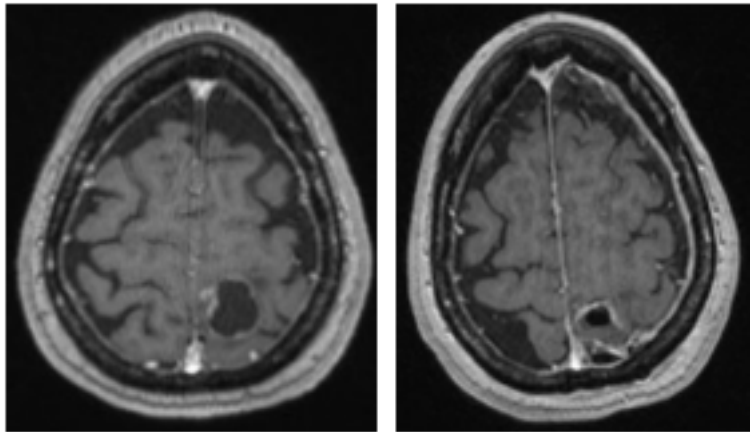
**PATIENT 27.**

Left temporal lobe.



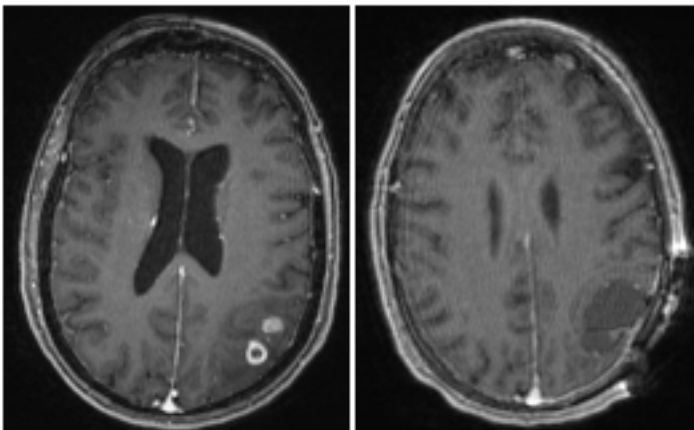
**PATIENT 28.**

Left fronto-parietal lobes.



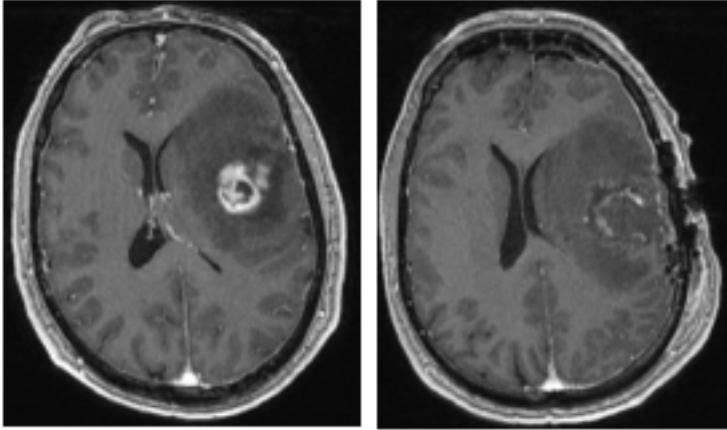
**PATIENT 29.**

Left parietal lobe.



**PATIENT 30.**

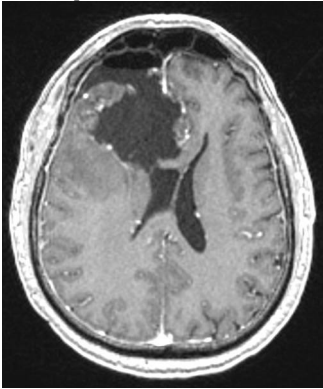
Left frontal lobe.



**PATIENT 31.**

Right frontal lobe with corpus callosum involvement.

*Pre-operative MRI not available.*



**PATIENT 32.**

Left parieto-occipital lobes.

